

We are IntechOpen, the world's leading publisher of Open Access books Built by scientists, for scientists

6,900

Open access books available

186,000

International authors and editors

200M

Downloads

Our authors are among the

154

Countries delivered to

TOP 1%

most cited scientists

12.2%

Contributors from top 500 universities



WEB OF SCIENCE™

Selection of our books indexed in the Book Citation Index
in Web of Science™ Core Collection (BKCI)

Interested in publishing with us?
Contact book.department@intechopen.com

Numbers displayed above are based on latest data collected.
For more information visit www.intechopen.com



Endovascular Repair of the Ruptured Aneurysm

Jane Cross, Peter Harris and Toby Richards
*University College Hospital,
 United Kingdom*

1. Introduction

Despite advances in the management of ruptured abdominal aortic aneurysms (RAAA), the mortality remains high. Approximately 6,000 men per year die from RAAA in England and Wales, accounting for 2% of deaths(1). In 2009 the UK National Vascular Database reported approximately 17% of aneurysms treated were ruptured, with an open mortality of 38%(2). The significant operative mortality for open repairs may reflect an irrecoverable physiological insult at the time of operation. Avoidance of laparotomy, retroperitoneal dissection and aortic cross clamping make endovascular techniques appealing for this high risk patient cohort.

Over the last decade, Endovascular Aneurysm Repair (EVAR) has become an established alternative to open surgery for the management of elective Abdominal Aortic Aneurysms (AAA). EVAR confers reduced early mortality(3), shorter operating time, fewer post-operative complications, reduced blood transfusion requirements, shorter ITU and hospital stay(4).

EVAR for RAAA was first reported in 1994(5). Currently its use is limited to specialist centres in the UK. The VASCUNET(6) multi-national database in 2008 reported 7466 RAAA of which 6468 were managed by open repair and only 478 by EVAR. The open mortality rate was 33% compared to 15% for EVAR. However, current published data for REVAR are subject to selection bias and the benefit of REVAR is unclear(7). EVAR is likely to be offered to stable patients or high surgical risk patients(8) and unstable patients are likely to have an open repair. Protocols and standard operating procedures are often reported incompletely or not at all making interpretation of results difficult. A pilot RCT was terminated early(9) due to slow recruitment at a single site and an over optimistic power calculation, and the evidence from single centre reports, systematic reviews and population based studies is weak.

This chapter outlines the patient selection, operative parameters, and post operative complications together with an evidence review for REVAR.

2. Patient selection

Indications for REVAR are variable between institutions. REVAR is used to treat all anatomically suitable RAAA in some centres, whereas its use is confined to haemodynamically stable patients in others; definitions of haemodynamic stability also vary(10). There are still many centres in the UK without a dedicated REVAR team and REVAR may not be routinely offered out of hours.

2.1 Haemodynamic parameters

Selection bias of previous studies suggested that REVAR was suitable only for stable patients. Hypotensive patients were considered unsuitable because of potential delays in obtaining a CT scan. However this has recently been challenged by the concept of "permissive hypotension" and hypotension is now not considered to preclude the use of EVAR.

Animal models of uncontrolled haemorrhage showed increased bleeding(11) and decreased survival when systolic blood pressure alone was the goal of resuscitation. In theory, increased fluid resuscitation leads to increased arterial and venous pressure, dilution of clotting factors and decreased blood viscosity. Permissive hypotension is the restrictive use of fluid therapy(12) to maintain SBP below normal physiological parameters with the aim of minimising blood loss prior to definitive intervention. Fluid input is titrated to maintain brain/vital organ perfusion. Whilst some authors advocate a SBP > 80mmHg to avoid cardiac, splanchnic, renal and brain ischaemia(13), others allow the SBP to fall to 50mmHg or less without fluid administration as long as the patient is moving and talking(14).

2.2 Anatomical criteria

Most centres require preoperative contrast enhanced CT to assess anatomical suitability for EVAR. Approximately 50% of patients presenting as an emergency are thought to be anatomically suitable for EVAR(15-16). Although, there is variability in the rapid availability of CT scans, pre procedural CT scans do not appear to significantly delay treatment or have an impact on outcome(9, 17) and the majority of patients who reach hospital with RAAA are stable enough to undergo a CT(18) prior to intervention. Newer "Hybrid" operating/angio suites often incorporate a CT scanner. This may decrease the delay between presentation and procedure commencement by reducing transfer time.

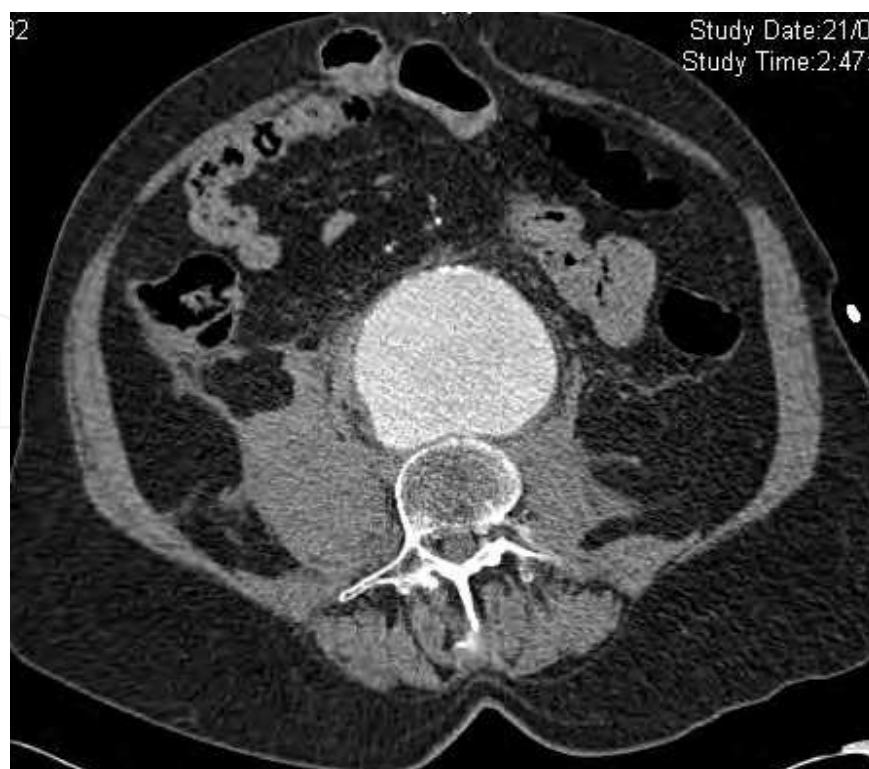


Fig. 1. A. CT scan of a contained ruptured AAA

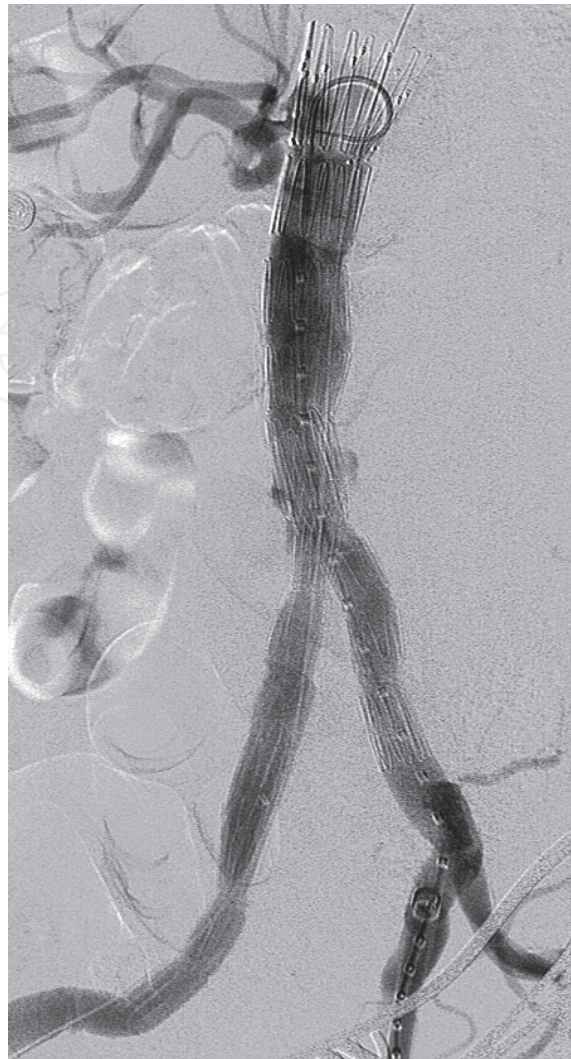

Fig. 1. B. The same patient following successful REVAR with a bifurcated graft. Note the right common iliac artery was aneurysmal necessitating coverage of the right internal iliac artery.

In unstable patients, CT may be avoided by performing intra-operative fluoroscopy to directly evaluate aneurysm morphology(10, 19). Graft sizing measurements are taken using calibrated catheters. However, this does not accurately show thrombus or atheroma lining the graft landing zones and was only able to predict the correct size of the graft in 60% of patients in an elective series.

RAAA usually present at a larger size with more adverse anatomical features than asymptomatic AAA(20). Data shows a significant increase in graft (procedural) related mortality in patients with adverse anatomy(8). In such cases open repair may be the preferred option. Although eligibility criteria are the same as those used for elective EVAR, the primary objective is survival and not long term durability of the device and it may be appropriate to consider less stringent anatomical criteria in patients with ruptured AAA(21-22). There is evidence that successful procedures can occur in the presence of adverse morphology. Alsac et al included neck angulation to 90° and reported EVAR to be suitable in 59% of cases(23), Moore advocated graft placement in necks of less than 10mm in length with the use of ancillary bare metal stenting of the pararenal neck(24). Metha et al accepted

necks as short as 5mm(21). Others have suggested electively covering the renal arteries in the emergency setting(22) a scenario that was fatal in the cases in this case series.

Another option for an unsuitable neck is to design and manufacture a fenestrated stent graft out of a commercially available device(25). However, it takes time to prepare the graft and some of the materials needed for construction e.g. fenestration markers are not routinely available. This is clearly not an option in the haemodynamically unstable patient. With the development of “off the shelf” fenestrated stent grafts, emergency fenestrated EVAR may become a more common future development.

Newer techniques such as “chimney” or “snorkel” procedures (fig 2) have been successfully reported for REVAR(25-26). This uses a technique of parallel stents for branching arteries and allows proximal placement of an endograft in the setting of a very short neck (2-3mm). Flow is secured to the branch arteries by inserting the renal artery stents simultaneous to the deployment of the aortic stent graft; this increases the number of short necked aneurysms that can be treated dramatically. This technique has also been used as a bail out option following inadvertent coverage of the renal arteries by converting to immediate laparotomy and retrogradely cannulating the renal arteries.

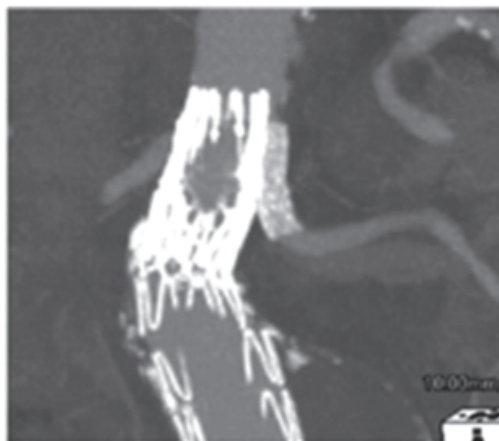


Fig. 2. CT showing a snorkel graft.

3. Procedure details

3.1 Theatre set up

Emergency EVAR should be undertaken in centres experienced and familiar with EVAR, where a multidisciplinary training programme and a pan-departmental protocol for the management of emergency EVAR can be effectively established. No individual factor leads to increased complications of emergency surgery, small errors often as a result of lack of familiarity, can compound to disrupt the normal planned sequential steps involved in graft placement. A dedicated REVAR team should therefore be available at all times with cross-departmental multidisciplinary training and rehearsal(21, 24).

Centres should have access to an endovascular suite with good quality imaging. A “Hybrid suite” is an ideal scenario and allows easy conversion to open surgery if necessary. Experience with adjunctive procedures and availability of different endograft options may facilitate EVAR in adverse anatomy(21, 27). Good imaging is vital for complex and /or ancillary procedures, cannulation and stenting of the renal arteries in case of pararenal top stent EVAR placement, placement of top cuff extension pieces, coiling of the internal iliac

artery for limb extension and potentially in the future for the use of iliac bifurcation devices or preloaded fenestrated devices.

In America EVAR has steadily increased for ruptured AAA. However, a reduction in mortality following REVAR was only seen in larger high volume centres. Lesperance et al showed a mortality of 21% in teaching hospitals compared to 55% at non-teaching hospitals(28). Other studies have also shown improved survival in experienced high volume centres(10) (26 v 46% mortality for REVAR(29)). Further, a 22.5% absolute risk reduction in mortality was seen after implementation of a structured protocol for management of RAAA and the use of an algorithm favouring endovascular repair(30). It is likely that the management of REVAR will be centralised to major regional vascular centres for optimal outcome.

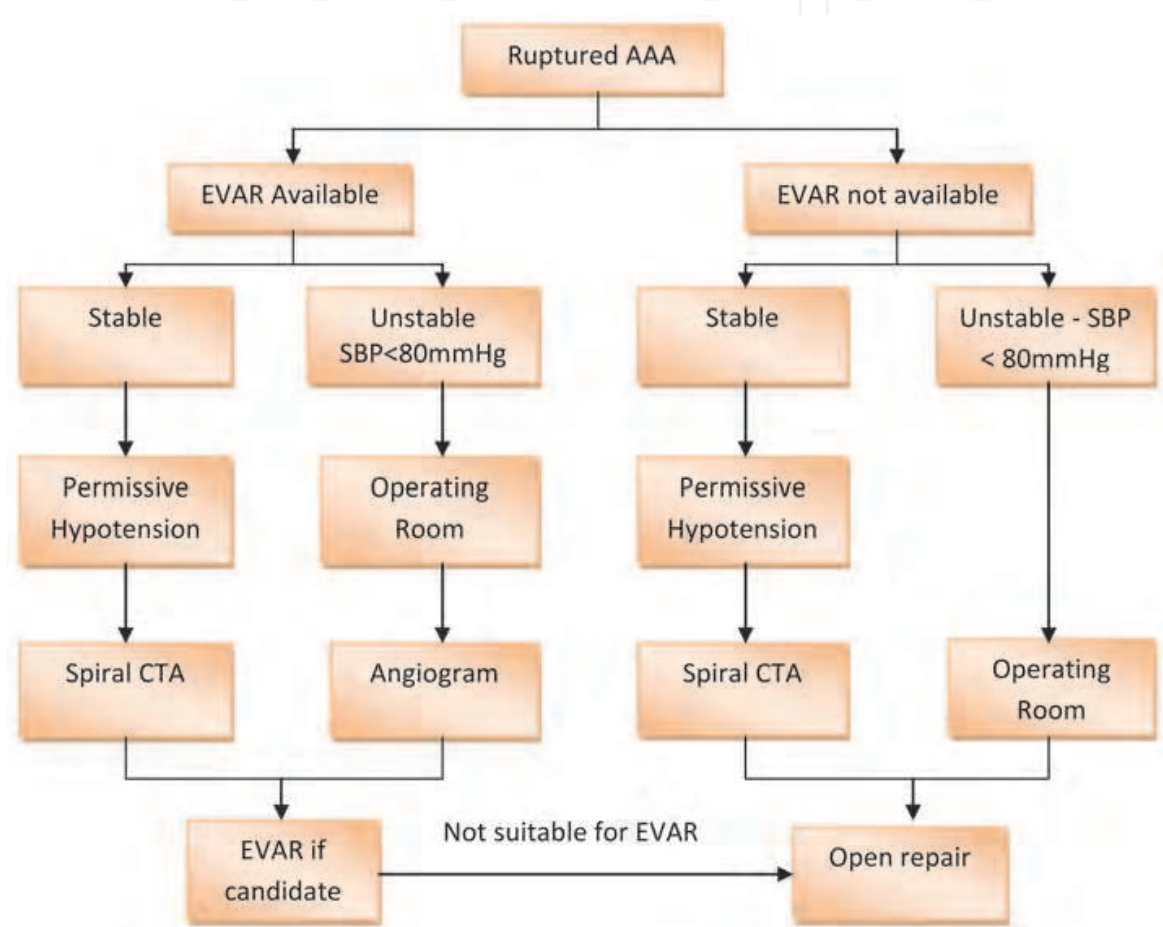


Fig. 3. An algorithm used by a centre in Canada(24).

3.2 Anaesthesia

REVAR may be performed under general anaesthesia, epidural or local anaesthesia with sedation(31). Induction of general anaesthesia inhibits the sympathetic vascular tone thereby inducing acute haemodynamic changes. It can also cause loss of abdominal muscle tone which may precipitate a free rupture from a previous aortic tamponade. REVAR under local anaesthetic is therefore often the preferred method and may improve patient outcome(32). Inadequate analgesia however may lead to restlessness and conversion to GA may be required. Although bifurcated grafts may be completed under local anaesthetic, AUI stent grafts require conversion to GA for the femoro-femoral bypass graft.

3.3 Haemorrhage control

Most patients who reach hospital with RAAA are stable and among those patients that reach hospital alive, around 90% of the deaths take place more than 2 hours after arrival(18). In the majority of cases swift deployment of the endograft results in successful haemorrhage control(13). However, patients with life threatening haemodynamic instability require immediate proximal occlusion of the aorta to control bleeding. This can be rapidly established by inflation of a compliant latex balloon placed via either the brachial or femoral routes to provide temporary haemostasis prior to definitive aneurysm exclusion(14).



Fig. 4. Aortic occlusion balloon

A brachial approach may prevent distal migration of the balloon and allow transfemoral insertion of the stent graft with the aortic balloon still inflated. However, percutaneous brachial/axillary puncture is difficult in a shocked patient and surgical cut down is time consuming. Descending aortic catheterisation from the right arm is associated with the risk of cerebral emboli and the left sided approach may interfere with positioning of the C-arm fluoroscope.

Percutaneous femoral puncture may be easier in the hypotensive patient(33). The descending aorta is catheterised and a sheath inserted into the supra-/para renal aorta. The

balloon is passed through the sheath and inflated. The sheath is advanced to support the inflated balloon from below and avoid distal dislocation when the blood pressure rises. The aortic stent graft is inserted from the contralateral groin via a stiff wire running outside the inflated balloon. The sheath that supports the balloon must also protrude above the stent graft to allow withdrawal of the balloon into the sheath after the endograft has been released; otherwise it is impossible to retrieve the balloon past the deployed stent graft. Conventional iodinated contrast may poorly delineate the aortic branches due to arrest of the blood flow. CO₂ angiography is a useful adjunct(33). The balloon itself may occlude the renal arteries and should be cranially repositioned if the renal arteries cannot be identified. A second aortic balloon is inflated inside the main body of the stent graft as soon as the main body has been deployed and the primary balloon and supporting sheath are removed. This minimises visceral branch ischaemia.

Complications of aortic occlusion balloons include renal and splanchnic ischaemia and embolisation(34). The majority of patients do not require an occlusion balloon and the balloon should only be used in life threatening haemorrhage. The indications for aortic balloon control vary between centres and it may be used in approximately 18-23% of patients(10).

3.4 Graft configuration

Both bifurcated and aortouni-iliac(AUI) devices can be successfully used. A recent survey found that approximately 75% of grafts used are modular and 25% are unibody(10). Although AUI devices require a GA for the subsequent femoro-femoral crossover, they can be used to exclude contralateral common iliac aneurysms, are quick and easy to deploy(35) and may produce faster haemorrhage control. An appropriate inventory of suitable grafts and accessories must be stocked and available for procedural and unexpected contingencies.

4. Morbidity and mortality

Current evidence suggests that REVAR may be of benefit in the reduction of peri-operative morbidity and mortality as compared with open repair, in particular for haemodynamically stable patients. Single centres have reported small series with a mortality for REVAR of 15.6-24%(23, 36-37) and two multi-centre studies reported similar results of 26-45%(29, 38) mortality. In a systematic review of 22 studies REVAR was associated with reduced mortality (odds ratio 0.624)(39) and a further review showed a pooled mortality of 21%(40). However a randomised controlled trial failed to demonstrate a benefit with a mortality rate of 53% for both open repair and REVAR.

REVAR may be associated with lower postoperative physiological complications, reduced ITU and hospital stay compared to open repair(29, 39). REVAR is associated with an increased mortality (OR 7.2) in high surgical risk patients(41) compared to REVAR in low risk patients and may not be the "easier option" for high risk patients. These results should be used to influence the consent process for such patients.

4.1 Visceral ischaemia

The incidence of ischaemic colitis in elective EVAR is around 1%(42). The cause is multifactorial and includes interruption of the inferior mesenteric artery, microembolisation, hypoperfusion, abdominal compartment syndrome and interruption of the hypogastric arteries. REVAR patients are likely to be more susceptible and the incidence of colonic ischaemia may be as high as 20%(43). This may be proportional to the level of pre-operative

hypotension(44). Although previous reports suggest that it is safe to cover one or even both internal iliac arteries in the elective setting(45-46), reports of colonic ischaemia have followed an occlusion of at least one internal iliac artery.

4.2 Compartment syndrome

Abdominal compartment syndrome is an important cause of multi organ failure and occurs in around 10 -12% of patients(10, 47). Some centres routinely measure the bladder pressure and open the abdomen in the absence of organ failure(32, 48). Other centres only perform laparostomies in the presence of deteriorating BP, lung and renal function(14, 49). The intra-abdominal pressure may be increased secondary to the retroperitoneal haematoma in REVAR patients and surgical decompression is occasionally needed. Successful outcome depends on early recognition, early conservative treatment to reduce intra-abdominal hypertension (diuretics, colloids and neuromuscular blockade) and decompression if abdominal compartment syndrome develops.

4.3 Endoleak

Although late technical failures are more likely with inaccurate graft placement, difficult anatomy in the emergency setting may mean acceptance of a potentially inadequate repair. It may be better to return the patient to theatre once stabilised in the post operative period, prior to discharge to improve the seal zone.

It is likely that the incidence of type 1 endoleak is higher for REAVR than elective EVAR. However, these are poorly reported and the true incidence is unclear. Most REVAR series are small with short term follow up only, making meaningful data extraction difficult. However published series have shown a type I endoleak rate of 11.7 – 15.7% and a type II rate of around 25%(13, 32) for REVAR. A type 1 endoleak in a RAAA is a potential cause of ongoing haemorrhage and should be treated urgently.

5. Future trials

Three randomised controlled trials are currently underway, the Dutch AJAX trial, the French ECAR trial and the UK IMPROVE Trial.

5.1 The AJAX trial

The Amsterdam Acute Aneurysm Trial(50) is a multi-centre randomised controlled trial. Stable, anatomically suitable patients are randomised to either open repair or REVAR. The primary endpoint is 30 day mortality and severe morbidity and the secondary endpoints are quality of life and cost effectiveness. Started in 2004, the trial was based on an initial recruitment of just 80 patients. No significant difference was seen and recruitment has therefore been extended twice and is still ongoing.

5.2 ECAR trial

The Endovasculaire vs Chirurgie dans les Anevrysmes Rompus is a multi centre randomised controlled trial(51). All consecutive patients with ruptured aorto-iliac aneurysms who are haemodynamically stable (SBP>80), and have favourable anatomy are included. The primary outcome is 30 day mortality. Secondary outcomes are cardiovascular, pulmonary, gastrointestinal, renal and neurological morbidity, time in ITU and volume of

blood transfused. All stable patients undergo CT scan and patients who are anatomically suitable are randomised to open repair or EVAR. The study started in 2008 and aims to recruit around 160 patients.

5.3 IMPROVE trial

The UK based Immediate Management of the Patient with Rupture: Open Versus Endovascular Repair (IMPROVE)(52) is a multi-centre international randomized controlled trial currently underway. This study differs from the previous two because it recruits “all comers”. Patients with a clinical diagnosis of RAAA are randomized to either immediate CT scan and endovascular repair whenever anatomically suitable, or to open repair with CT scan being optional. The protocol of permissive hypotension is incorporated. Recruitment started in October 2009 and it is anticipated 600 patients will be required to show a 14% survival benefit for EVAR. The trial addresses whether the anticipated reduced mortality and morbidity associated with EVAR is offset by the relatively greater ease of access and speed to conventional surgery.

6. Conclusion

The use of EVAR is feasible in patients who present with a ruptured or acutely symptomatic AAA. Current evidence is weak and has likely inclusion bias; however published mortality rates are lower for REVAR than for open repair. Patient selection for REVAR varies between centres but the concept of “permissive hypotension” has increased the patient cohort undergoing REVAR. Mortality rates are lower in high volume centres; this may reflect experience in centres familiar with emergency EVAR, experience with adjunctive procedures, establishing control in haemodynamically unstable patients by supra renal aortic occlusion balloon placement, and the use of large balloon mounted stents to reinforce a short or angulated neck. Availability of different endograft options may facilitate EVAR for adverse anatomy and access to an endovascular suite with good quality imaging is undeniably beneficial. REVAR may also be associated with lower postoperative physiological complications, reduced ITU and hospital stay compared to open repair. However further studies are needed to produce concrete evidence. Current international multi-centre trials are underway to determine the benefit.

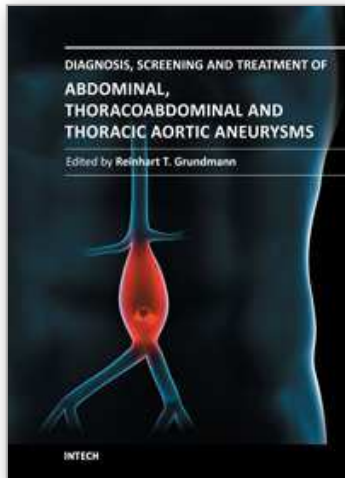
7. References

- [1] Earnshaw JJ, Shaw E, Whyman MR, Poskitt KR, Heather BP. Screening for abdominal aortic aneurysms in men. *BMJ*. 2004 May 8;328(7448):1122-4.
- [2] Lees S. The National Vascular Database Report 2009. 2009.
- [3] Endovascular aneurysm repair versus open repair in patients with abdominal aortic aneurysm (EVAR trial 1): randomised controlled trial. *Lancet*. 2005 Jun 25-Jul 1;365(9478):2179-86.
- [4] Prinssen M, Verhoeven EL, Buth J, Cuypers PW, van Sambeek MR, Balm R, et al. A randomized trial comparing conventional and endovascular repair of abdominal aortic aneurysms. *N Engl J Med*. 2004 Oct 14;351(16):1607-18.
- [5] Yusuf SW, Whitaker SC, Chuter TA, Wenham PW, Hopkinson BR. Emergency endovascular repair of leaking aortic aneurysm. *Lancet*. 1994 Dec 10;344(8937):1645.
- [6] Gibbons. The European Society for Vascular Surgery Second Vascular Surgery Database Report. 2008.

- [7] Dillon M, Cardwell C, Blair PH, Ellis P, Kee F, Harkin DW. Endovascular treatment for ruptured abdominal aortic aneurysm. *Cochrane Database Syst Rev*. 2007(1):CD005261.
- [8] Richards T, Goode SD, Hinchliffe R, Altaf N, Macsweeney S, Braithwaite B. The importance of anatomical suitability and fitness for the outcome of endovascular repair of ruptured abdominal aortic aneurysm. *Eur J Vasc Endovasc Surg*. 2009 Sep;38(3):285-90.
- [9] Hinchliffe RJ, Bruijstens L, MacSweeney ST, Braithwaite BD. A randomised trial of endovascular and open surgery for ruptured abdominal aortic aneurysm - results of a pilot study and lessons learned for future studies. *Eur J Vasc Endovasc Surg*. 2006 Nov;32(5):506-13; discussion 14-5.
- [10] Veith FJ, Lachat M, Mayer D, Malina M, Holst J, Mehta M, et al. Collected world and single center experience with endovascular treatment of ruptured abdominal aortic aneurysms. *Ann Surg*. 2009 Nov;250(5):818-24.
- [11] Holmes JF, Sakles JC, Lewis G, Wisner DH. Effects of delaying fluid resuscitation on an injury to the systemic arterial vasculature. *Acad Emerg Med*. 2002 Apr;9(4):267-74.
- [12] van der Vliet JA, van Aalst DL, Schultze Kool LJ, Wever JJ, Blankensteijn JD. Hypotensive hemostatis (permissive hypotension) for ruptured abdominal aortic aneurysm: are we really in control? *Vascular*. 2007 Jul-Aug;15(4):197-200.
- [13] Alsac JM, Kobeiter H, Becquemin JP, Desgranges P. Endovascular repair for ruptured AAA: a literature review. *Acta Chir Belg*. 2005 Apr;105(2):134-9.
- [14] Veith FJ, Ohki T. Endovascular approaches to ruptured infrarenal aorto-iliac aneurysms. *J Cardiovasc Surg (Torino)*. 2002 Jun;43(3):369-78.
- [15] Rose DF, Davidson IR, Hinchliffe RJ, Whitaker SC, Gregson RH, MacSweeney ST, et al. Anatomical suitability of ruptured abdominal aortic aneurysms for endovascular repair. *J Endovasc Ther*. 2003 Jun;10(3):453-7.
- [16] Hoornweg LL, Wisselink W, Vahl A, Balm R. The Amsterdam Acute Aneurysm Trial: suitability and application rate for endovascular repair of ruptured abdominal aortic aneurysms. *Eur J Vasc Endovasc Surg*. 2007 Jun;33(6):679-83.
- [17] Boyle JR, Gibbs PJ, Kruger A, Shearman CP, Raptis S, Phillips MJ. Existing delays following the presentation of ruptured abdominal aortic aneurysm allow sufficient time to assess patients for endovascular repair. *Eur J Vasc Endovasc Surg*. 2005 May;29(5):505-9.
- [18] Lloyd GM, Bown MJ, Norwood MG, Deb R, Fishwick G, Bell PR, et al. Feasibility of preoperative computer tomography in patients with ruptured abdominal aortic aneurysm: a time-to-death study in patients without operation. *J Vasc Surg*. 2004 Apr;39(4):788-91.
- [19] Peppelenbosch N, Zannetti S, Barbieri B, Buth J. Endograft treatment in ruptured abdominal aortic aneurysms using the Talent AUI stentgraft system. Design of a feasibility study. *Eur J Vasc Endovasc Surg*. 2004 Apr;27(4):366-71.
- [20] Szilagyi DE, Smith RF, DeRusso FJ, Elliott JP, Sherrin FW. Contribution of abdominal aortic aneurysmectomy to prolongation of life. *Ann Surg*. 1966 Oct;164(4):678-99.
- [21] Mehta M, Taggart J, Darling RC, 3rd, Chang BB, Kreienberg PB, Paty PS, et al. Establishing a protocol for endovascular treatment of ruptured abdominal aortic aneurysms: outcomes of a prospective analysis. *J Vasc Surg*. 2006 Jul;44(1):1-8; discussion
- [22] Lee RW, Rhodes JM, Singh MJ, Davies MG, Wolford HY, Diachun C, et al. Is there a selection bias in applying endovascular aneurysm repair for rupture? *Ann Vasc Surg*. 2008 Mar;22(2):215-20.

- [23] Alsac JM, Desgranges P, Kobeiter H, Becquemin JP. Emergency endovascular repair for ruptured abdominal aortic aneurysms: feasibility and comparison of early results with conventional open repair. *Eur J Vasc Endovasc Surg*. 2005 Dec;30(6):632-9.
- [24] Moore R, Nutley M, Cina CS, Motamedi M, Faris P, Abuznadah W. Improved survival after introduction of an emergency endovascular therapy protocol for ruptured abdominal aortic aneurysms. *J Vasc Surg*. 2007 Mar;45(3):443-50.
- [25] Resch T. Proportion of Ruptured AAAs Suitable for EVAR in view of Chimney and Homemade Fenestrated Endografts. www.veithsymposiumorg/pdf/vei/2624pdf.
- [26] Schlosser FJ, Aruny JE, Freiburg CB, Mojibian HR, Sumpio BE, Muhs BE. The chimney procedure is an emergently available endovascular solution for visceral aortic aneurysm rupture. *J Vasc Surg*. 2011 Jan 26.
- [27] Albertini JN, Perdikides T, Soong CV, Hinchliffe RJ, Trojanowska M, Yusuf SW. Endovascular repair of abdominal aortic aneurysms in patients with severe angulation of the proximal neck using a flexible stent-graft: European Multicenter Experience. *J Cardiovasc Surg (Torino)*. 2006 Jun;47(3):245-50.
- [28] Lesperance K, Andersen C, Singh N, Starnes B, Martin MJ. Expanding use of emergency endovascular repair for ruptured abdominal aortic aneurysms: disparities in outcomes from a nationwide perspective. *J Vasc Surg*. 2008 Jun;47(6):1165-70; discussion 70-1.
- [29] Greco G, Egorova N, Anderson PL, Gelijns A, Moskowitz A, Nowygrod R, et al. Outcomes of endovascular treatment of ruptured abdominal aortic aneurysms. *J Vasc Surg*. 2006 Mar;43(3):453-9.
- [30] Starnes BW, Quiroga E, Hutter C, Tran NT, Hatsukami T, Meissner M, et al. Management of ruptured abdominal aortic aneurysm in the endovascular era. *J Vasc Surg*. 2010 Jan;51(1):9-17; discussion -8.
- [31] Lachat ML, Pfammatter T, Witzke HJ, Bettex D, Kunzli A, Wolfensberger U, et al. Endovascular repair with bifurcated stent-grafts under local anaesthesia to improve outcome of ruptured aortoiliac aneurysms. *Eur J Vasc Endovasc Surg*. 2002 Jun;23(6):528-36.
- [32] Mayer D, Pfammatter T, Rancic Z, Hechelhammer L, Wilhelm M, Veith FJ, et al. 10 years of emergency endovascular aneurysm repair for ruptured abdominal aortoiliac aneurysms: lessons learned. *Ann Surg*. 2009 Mar;249(3):510-5.
- [33] Malina M, Veith F, Ivancev K, Sonesson B. Balloon occlusion of the aorta during endovascular repair of ruptured abdominal aortic aneurysm. *J Endovasc Ther*. 2005 Oct;12(5):556-9.
- [34] Low RB, Longmore W, Rubinstein R, Flores L, Wolvek S. Preliminary report on the use of the Percutaneous Occluding Aortic Balloon in human beings. *Ann Emerg Med*. 1986 Dec;15(12):1466-9.
- [35] Chuter TA, Faruqi RM, Reilly LM, Kerlan RK, Sawhney R, Wall SD, et al. Aortomonoiliac endovascular grafting combined with femorofemoral bypass: an acceptable compromise or a preferred solution? *Semin Vasc Surg*. 1999 Sep;12(3):176-81.
- [36] Kubin K, Sodeck GH, Teufelsbauer H, Nowatschka B, Kretschmer G, Lammer J, et al. Endovascular therapy of ruptured abdominal aortic aneurysm: mid- and long-term results. *Cardiovasc Intervent Radiol*. 2008 May-Jun;31(3):496-503.
- [37] Chagpar RB, Harris JR, Lawlor DK, DeRose G, Forbes TL. Early mortality following endovascular versus open repair of ruptured abdominal aortic aneurysms. *Vasc Endovascular Surg*. 2010 Nov;44(8):645-9.
- [38] Peppelenbosch N, Geelkerken RH, Soong C, Cao P, Steinmetz OK, Teijink JA, et al. Endograft treatment of ruptured abdominal aortic aneurysms using the Talent

- aortouniiliac system: an international multicenter study. *J Vasc Surg.* 2006 Jun;43(6):1111-23; discussion 23.
- [39] Sadat U, Boyle JR, Walsh SR, Tang T, Varty K, Hayes PD. Endovascular vs open repair of acute abdominal aortic aneurysms--a systematic review and meta-analysis. *J Vasc Surg.* 2008 Jul;48(1):227-36.
- [40] Mastracci TM, Garrido-Olivares L, Cina CS, Clase CM. Endovascular repair of ruptured abdominal aortic aneurysms: a systematic review and meta-analysis. *J Vasc Surg.* 2008 Jan;47(1):214-21.
- [41] Jordan WD, Alcocer F, Wirthlin DJ, Westfall AO, Whitley D. Abdominal aortic aneurysms in "high-risk" surgical patients: comparison of open and endovascular repair. *Ann Surg.* 2003 May;237(5):623-9; discussion 9-30.
- [42] Miller A, Marotta M, Scordi-Bello I, Tammaro Y, Marin M, Divino C. Ischemic colitis after endovascular aortoiliac aneurysm repair: a 10-year retrospective study. *Arch Surg.* 2009 Oct;144(10):900-3.
- [43] Champagne BJ, Lee EC, Valerian B, Mulhotra N, Mehta M. Incidence of colonic ischemia after repair of ruptured abdominal aortic aneurysm with endograft. *J Am Coll Surg.* 2007 Apr;204(4):597-602.
- [44] Bast TJ, van der Biezen JJ, Scherpenisse J, Eikelboom BC. Ischaemic disease of the colon and rectum after surgery for abdominal aortic aneurysm: a prospective study of the incidence and risk factors. *Eur J Vasc Surg.* 1990 Jun;4(3):253-7.
- [45] Mehta M, Veith FJ, Ohki T, Cynamon J, Goldstein K, Suggs WD, et al. Unilateral and bilateral hypogastric artery interruption during aortoiliac aneurysm repair in 154 patients: a relatively innocuous procedure. *J Vasc Surg.* 2001 Feb;33(2 Suppl):S27-32.
- [46] Wolpert LM, Dittrich KP, Hallisey MJ, Allmendinger PP, Gallagher JJ, Heydt K, et al. Hypogastric artery embolization in endovascular abdominal aortic aneurysm repair. *J Vasc Surg.* 2001 Jun;33(6):1193-8.
- [47] Djavani Gidlund K, Wanhainen A, Bjorck M. Intra-abdominal Hypertension and Abdominal Compartment Syndrome after Endovascular Repair of Ruptured Abdominal Aortic Aneurysm. *Eur J Vasc Endovasc Surg.* 2011 Mar 14.
- [48] Hechelhammer L, Lachat ML, Wildermuth S, Bettex D, Mayer D, Pfammatter T. Midterm outcome of endovascular repair of ruptured abdominal aortic aneurysms. *J Vasc Surg.* 2005 May;41(5):752-7.
- [49] Mehta M, Darling RC, 3rd, Roddy SP, Fecteau S, Ozsvath KJ, Kreienberg PB, et al. Factors associated with abdominal compartment syndrome complicating endovascular repair of ruptured abdominal aortic aneurysms. *J Vasc Surg.* 2005 Dec;42(6):1047-51.
- [50] Amsterdam Acute Aneurysm trial: background, design, and methods. *Vascular.* 2006 May-Jun;14(3):130-5.
- [51] Desgranges P, Kobeiter H, Castier Y, Senechal M, Majewski M, Krimi A. The Endovasculaire vs Chirurgie dans les Anevrysmes Rompus PROTOCOL trial update. *J Vasc Surg.* 2010 Jan;51(1):267-70.
- [52] Powell JT, Thompson SG, Thompson MM, Grieve R, Nicholson AA, Ashleigh R, et al. The Immediate Management of the Patient with Rupture: Open Versus Endovascular repair (IMPROVE) aneurysm trial--ISRCTN 48334791 IMPROVE trialists. *Acta Chir Belg.* 2009 Nov-Dec;109(6):678-80.



Diagnosis, Screening and Treatment of Abdominal, Thoracoabdominal and Thoracic Aortic Aneurysms

Edited by Prof. Reinhart Grundmann

ISBN 978-953-307-466-5

Hard cover, 414 pages

Publisher InTech

Published online 12, September, 2011

Published in print edition September, 2011

This book considers mainly diagnosis, screening, surveillance and treatment of abdominal, thoracoabdominal and thoracic aortic aneurysms. It addresses vascular and cardiothoracic surgeons and interventional radiologists, but also anyone engaged in vascular medicine. The high mortality of ruptured aneurysms certainly favors the recommendation of prophylactic repair of asymptomatic aortic aneurysms (AA) and therewith a generous screening. However, the comorbidities of these patients and their age have to be kept in mind if the efficacy and cost effectiveness of screening and prophylactic surgery should not be overestimated. The treatment recommendations which will be outlined here, have to regard on the one hand the natural course of the disease, the risk of rupture, and the life expectancy of the patient, and on the other hand the morbidity and mortality of the prophylactic surgical intervention. The book describes perioperative mortality after endovascular and open repair of AA, long-term outcome after repair, and the cost-effectiveness of treatment.

How to reference

In order to correctly reference this scholarly work, feel free to copy and paste the following:

Jane Cross, Peter Harris and Toby Richards (2011). Endovascular Repair of the Ruptured Aneurysm, Diagnosis, Screening and Treatment of Abdominal, Thoracoabdominal and Thoracic Aortic Aneurysms, Prof. Reinhart Grundmann (Ed.), ISBN: 978-953-307-466-5, InTech, Available from:
<http://www.intechopen.com/books/diagnosis-screening-and-treatment-of-abdominal-thoracoabdominal-and-thoracic-aortic-aneurysms/endovascular-repair-of-the-ruptured-aneurysm>

INTeCH
open science | open minds

InTech Europe

University Campus STeP Ri
Slavka Krautzeka 83/A
51000 Rijeka, Croatia
Phone: +385 (51) 770 447
Fax: +385 (51) 686 166
www.intechopen.com

InTech China

Unit 405, Office Block, Hotel Equatorial Shanghai
No.65, Yan An Road (West), Shanghai, 200040, China
中国上海市延安西路65号上海国际贵都大饭店办公楼405单元
Phone: +86-21-62489820
Fax: +86-21-62489821

© 2011 The Author(s). Licensee IntechOpen. This chapter is distributed under the terms of the [Creative Commons Attribution-NonCommercial-ShareAlike-3.0 License](https://creativecommons.org/licenses/by-nc-sa/3.0/), which permits use, distribution and reproduction for non-commercial purposes, provided the original is properly cited and derivative works building on this content are distributed under the same license.

IntechOpen

IntechOpen