

We are IntechOpen, the world's leading publisher of Open Access books Built by scientists, for scientists

6,900

Open access books available

185,000

International authors and editors

200M

Downloads

Our authors are among the

154

Countries delivered to

TOP 1%

most cited scientists

12.2%

Contributors from top 500 universities



WEB OF SCIENCE™

Selection of our books indexed in the Book Citation Index
in Web of Science™ Core Collection (BKCI)

Interested in publishing with us?
Contact book.department@intechopen.com

Numbers displayed above are based on latest data collected.
For more information visit www.intechopen.com



12-year Experience with the Endologix Powerlink^R Device in Endovascular Repair of Abdominal Aortic Aneurysms

Ziheng Wu¹, Lefeng Qu², Dieter Raithel³ and Konstantinos Xiromeritis³

¹*Department of Vascular Surgery, First Affiliated Hospital, College of Medicine, Zhejiang University, Hangzhou*

²*Department of Vascular Surgery, Changhai Hospital Affiliated to the Second Military Medical University*

³*Department of Vascular and Endovascular Surgery, Nuremberg Southern Hospital, ^{1,2}China ³Germany*

1. Introduction

Since Parodi reported the first successful endovascular aneurysm repair procedure in 1991, this procedure has gained wide acceptance for the treatment of abdominal aortic aneurysms in the past two decades. This minimally invasive approach has been proven effective and safe in the treatment of abdominal aortic aneurysm patients with lower early morbidity and mortality rates compared to open surgery repair. Meanwhile, dozens of endografts have been designed for endovascular aneurysm repair, and most of them are now still undergoing modification and improvement. Although these devices have been improved over time, secondary procedures are required in up to 27% of patients following endovascular aneurysm repair. Complications of stent-graft migration, endoleaks, stent rupture/fracture, aortic neck dilatation and development of other aortoiliac aneurysms mandate lifelong patient follow-up.

Among these complications the most prevalent and concerning complications are distal migration (defined by the Society for Vascular Surgery as device movement of greater than 10 mm or lesser device movement necessitating secondary intervention) and Type I endoleak, putting the patients under an increasing risk of aneurysm rupture. Migration has a reported incidence of up to 45%, and has been shown in biomechanical analyses to be the result of both persistent downward flow upon the stent-graft bifurcation (affecting neck fixation), and transverse forces, resulting in device lateral movement (affecting neck fixation, component stability, and iliac fixation). Type I endoleak is closely associated with migration, and is certainly the most significant predictor of aneurysm increase, risk of rupture, and need for secondary intervention or open conversion repair.

Therefore, the most favorable design of endovascular aneurysm repair endograft should theoretically support to counteract the downward force of pulsatile blood flow and possibly prevent distal migration. Now on the market most of the endovascular aneurysm repair endografts are modular devices and deployed from proximal to distal. The Endologix

(Irvine, CA, USA) Powerlink^R device is the only unibody endograft which is deployed at the aortic bifurcation (“anatomical fixation”). From our nearly 16 years experience of more than 1700 (ending in November 2009) endovascular aneurysm repair cases with 13 different endografts, we prefer the Powerlink^R unibody bifurcated device for this challenge. Ending in December 2008, 612 cases of endovascular aneurysm repair were performed using the Powerlink^R device in our single center, in 513 patients the devices were implanted “anatomically” from the aortoiliac bifurcation to the renal artery level with or without proximal cuff and/or additional Palmaz^R stent. We have published our outcomes with the Powerlink^R for abdominal aortic aneurysms in the last years. In one article, the results included the cases that deployed not “anatomically”. The objective of this report is to summarize our 12-year experience of endovascular aneurysm repair for abdominal aortic aneurysm with the Powerlink^R stent-graft deployed “anatomically”.

2. Methods

2.1 Patient sample

From February 1999 to December 2008, 612 patients with infrarenal abdominal aortic aneurysm were evaluated for endovascular aneurysm repair treatment with the Endologix Powerlink^R endograft in our center. Of this cohort in 513 patients the devices were implanted “anatomically” from the aortoiliac bifurcation to the renal artery level with or without proximal cuff and/or additional Palmaz^R stent. According to the American Society of Anesthesiologists’ physical status classification there were 60.8% (312/513) cases in ASA III/IV stage. The follow-up imaging was performed at 1 month, 6 months and yearly thereafter. Computed tomography angiograms with a 2.5-mm slice thickness were routinely performed to determine endovascular aneurysm repair eligibility. Data of these 513 patients were retrospectively analyzed in the study. Of these 513 patients, a special analysis was also made of data from 117 cases with short and/or angulated necks (from February 1999 to December 2007) (Table 1).

	Short neck (11-15 mm)	Very short neck (< 10 mm)	Angulated neck (> 60°)
Number of cases	54	26	37
Mean age, years	72.2	73.1	72.7
Male	50 (93%)	23 (88%)	32 (86%)
Mean AAA diameter, cm	5.8	6.1	6.3
ASA class III/IV	44 (81%)	21 (81%)	31 (84%)

Table 1. Demographics and Patients Characteristics

2.2 Endologix Powerlink^R system

The Powerlink^R main body device is an unibody bifurcated endograft consisting of a fully supported, high density, low porosity expanded polytetrafluoroethylene (ePTFE) graft with an endoskeleton constructed as a single-wire, cobalt chromium alloy body with limbs. The graft is attached to the stent only at the proximal and distal ends using surgical suture, a feature that results in excellent resistance to stent fracture or fatigue. Accessory proximal

extensions are constructed in like manner, with both infrarenal configurations and suprarenal PowerFit[™] configurations available (Figure 1). Accessory limb extensions in straight, stepped, flared, and tapered configurations are available to permit customization to patient anatomy as needed (Figure 2). Device availability permits the treatment of patients with proximal aortic neck diameters of 18 to 32 mm, and distal iliac seal zone diameters of 10 to 23 mm. The low profile 19 Fr delivery system introducer requires only one surgically exposed femoral artery for deployment. Unique to this device, contralateral access is obtained percutaneously (9Fr) through a pre-cannulated contralateral limb. These features enable use of the device in patients with one small or severely diseased iliac access vessel, where with available proximal fixation devices, this is not possible. The Powerlink[®] design and access flexibility thus increase the number of patients that can be electively treated by endovascular aneurysm repair. Moreover, the use of the integrated introducer sheath for accessory delivery and deployment and ancillary device introduction reduces the need for exchanges, thereby minimizing the potential for vessel intimal injury (Figure 3).

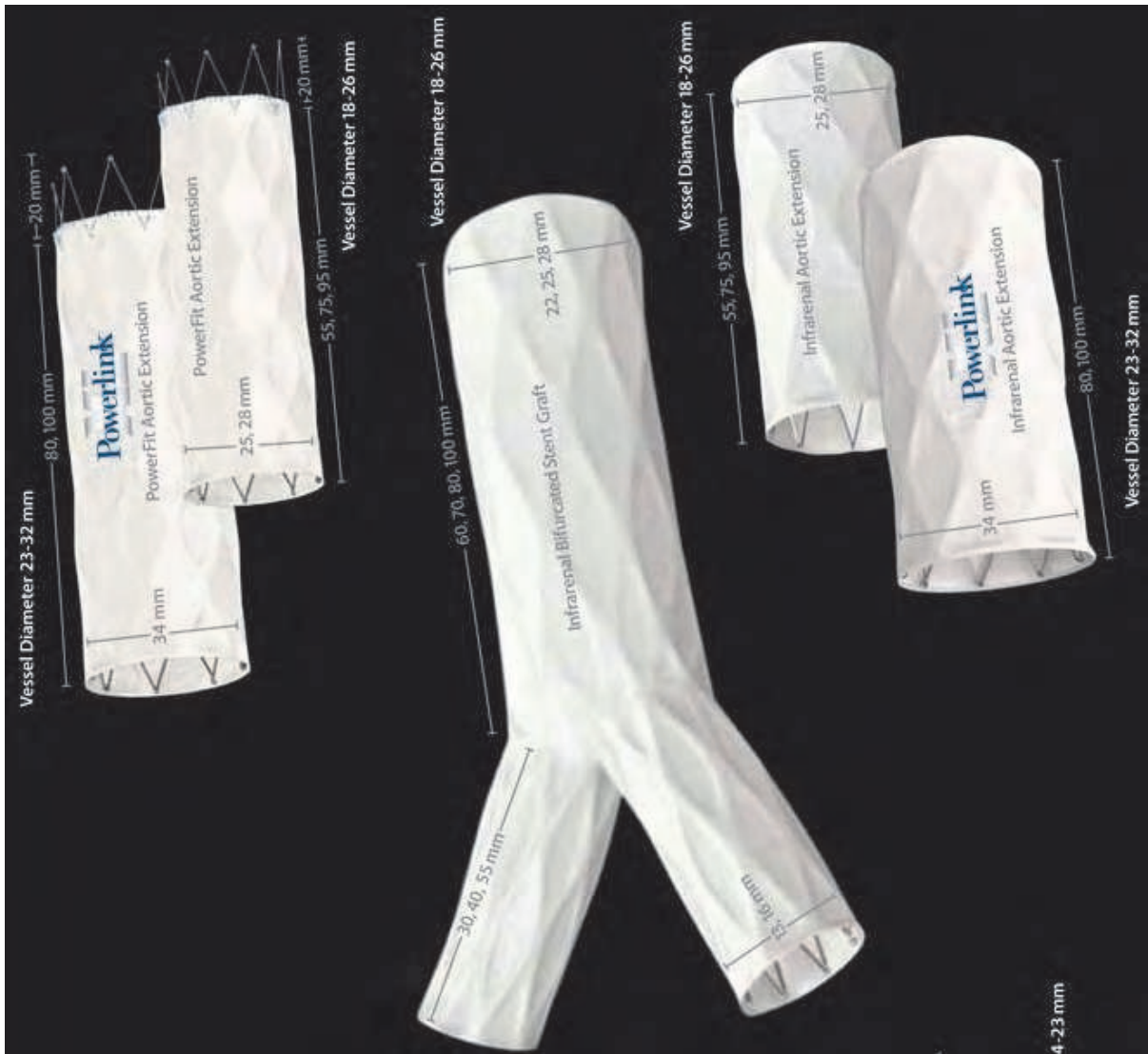

Fig. 1. Powerlink[®] Endografts (Unibody bifurcated, PowerFit[™])



Fig. 2. Powerlink[®] Endografts Accessory limb extensions (straight, tapered, flared and stepped extensions)

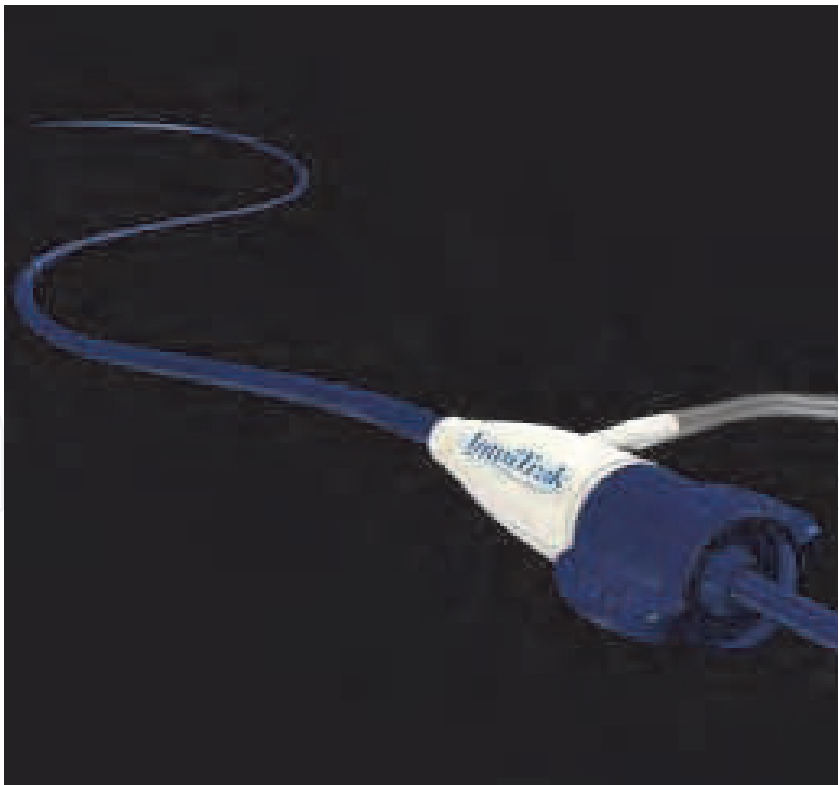


Fig. 3. IntuiTrak endovascular abdominal aortic aneurysm system (Flexible, low profile delivery system, anatomical fixation, Pre-cannulated 9F contralateral limb, Hydrophilic coated sheath, Simple and controlled deployment)

2.3 EVAR procedure with the Powerlink[®] system

Stent-graft selection is based on pre-operative and intra-operative measurements of aortic non-aneurysmal neck diameter, aortic length from the most caudal renal artery to the aortic bifurcation, and length from the aortic bifurcation to the hypogastric arteries. Procedures are performed in suitably equipped operating rooms or endovascular suites with operating room availability. Proper fluoroscopic imaging equipment and tools include a mobile C-arm, automated contrast injector, intraoperative angiography, and if preferred, intravascular ultrasound. Bifurcated and, as needed, proximal extension stent-graft models are chosen per established sizing algorithms, while achieving proximal seal and fully lining the infrarenal aorta. After angiography and aortic length verification with a marker catheter, the bifurcated stent graft delivery system contralateral guidewire is placed, and the integrated 19Fr introducer sheath is advanced over the stiff guidewire into the aorta. Under fluoroscopic visualization, the introducer sheath is retracted to expose the constrained bifurcated stent graft. The constrained device is then placed upon the aortoiliac bifurcation, after which the main body and each limb of the device are deployed using a simple yet metered control cord mechanism. This results in implantation of the device at the aortoiliac bifurcation (i.e., anatomical fixation). Based on the patient anatomy and intraoperative angiography, an accessory proximal extension is placed as needed to achieve adequate overlap with the bifurcated device and seal in the proximal neck (Figure 4). Limb extensions can similarly be placed as needed to accommodate patient anatomical needs. Balloon dilatation may be performed if desired.

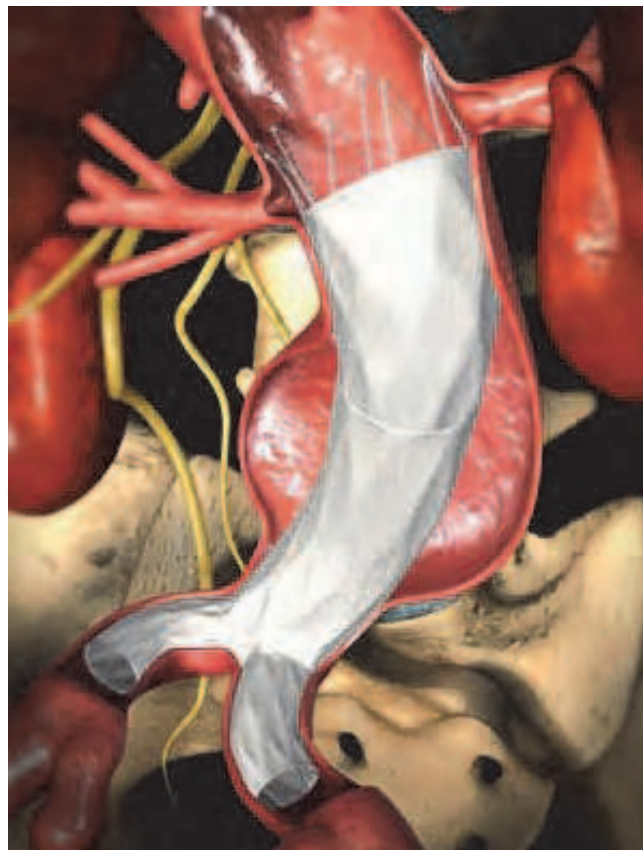


Fig. 4. Image of the Anatomically Fixed Powerlink[®] Implant. Full aortic relining and proximal seal are completed with the PowerFit[™] proximal extension.

2.4 Palmaz^R stent and deployment procedure

Palmaz^R stents are inserted through a 14-F Check-Flo Performer introducer (Cook, Bloomington, IN, USA). The stent can be expanded to 14-25 mm correspondingly the length from 37.79-30.58 mm. The stent was advanced and deployed across the renal arteries and top of the graft with a MAXI LD PTA balloon dilation catheter (Cordis, Miami, FL, USA). We usually choose a P4014 Palmaz^R stent, a 25mm-diameter expandable balloon and a 45cm-long 14F sheath (Figure 5). The balloon had better be inflated one time whose surface is relatively coarse to prevent the stent from dislocation in the course of deployment. The Palmaz^R stent was asymmetrically hand-crimped on an expandable balloon that ensures that the proximal (cranial) aspect will expand first. A long sheath is placed distal to the target area. We regularly deploy the Palmaz^R stent with one third above the renal artery, since when we dilate the Palmaz^R stent, it shortens. Once the balloon and stent assembly is in position, the sheath is partially retracted to allow only the proximal (cranial) half of the balloon to expand, flaring the unsheathed proximal stent. The expanded proximal balloon prevents cranial stent migration. The sheath prevents distal (caudal) stent migration. Full retraction of the sheath allows the distal balloon and stent to expand, completing the stent deployment (Figure 6).




Fig. 5. A P4014 Palmaz^R stent and a MAXI LD PTA expandable balloon

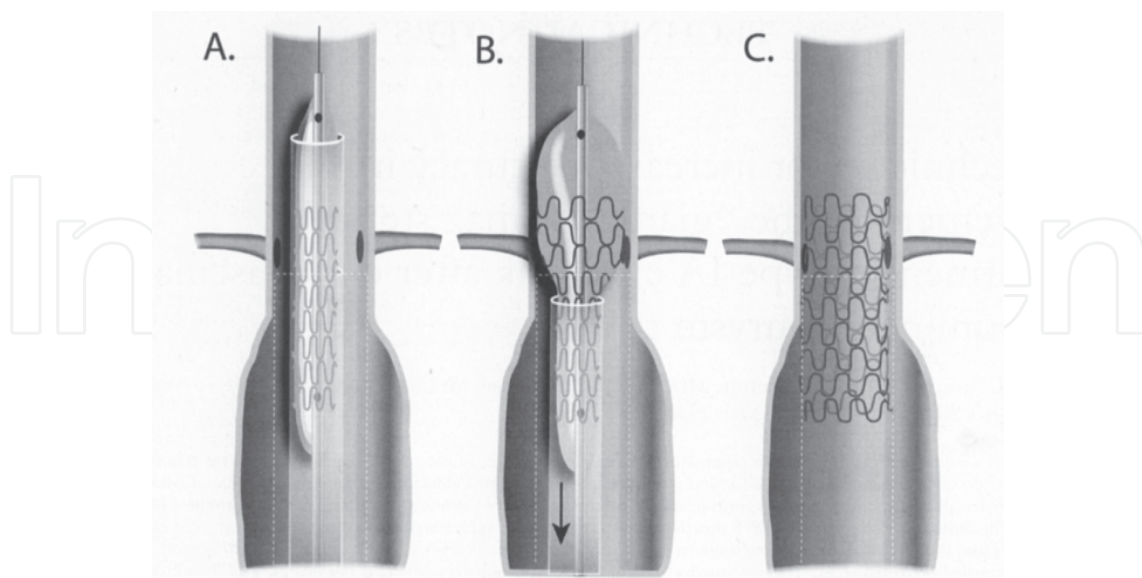


Fig. 6. Details of the deployment procedure of Palmaz^R stent. (A) The stent loaded off-center on the balloon is positioned at the intended area of deployment through the sheath under fluoroscopic guidance. (B) The sheath is partially retracted and the balloon is insufflated, deploying the proximal (cranial) portion of the stent. (C) Fully deployed stent.

2.5 Follow-up

All patients were evaluated before discharge; at 1 and 6 months; and annually thereafter to assess clinical symptoms, potential endoleaks, and aneurysm size. Computed tomography angiogram was performed at each visit; digital subtract angiography was used selectively in special cases, such as visible endoleak or aneurysm sac enlargement seen on computed tomography angiograms.

3. Results

This study cohort included 513 consecutive patients (mean age 72.9±8.0 years, male 461); the mean maximal aneurysm diameter was 54.6±8.9 mm. 86 (16.8%) cases underwent preliminary hypogastric embolisation in the presence of common iliac artery and/or hypogastric artery aneurysm or a too short common iliac artery. The technical success rate was 98.4% (505/513), emergent open conversion occurred in 8 cases (1.6%) because of delivery access problem. The proximal cuff was used in 61.0% (308/505), Palmaz[®] stent in 20.6% (104/505), limb extension in 14.3% (72/505), retrograde iliac artery endarterectomy and femoral patchplasty in 27 (5.3%) cases, iliac-femoral graft interposition in two cases. Primary type Ia endoleak occurred in 20 cases (4.0%) and all were remedied intraoperatively by Palmaz[®] stent or the endoleaks were considered so minimal that spontaneous vanish would be expected in close follow-up. 18 (3.5%) cases had type II endoleak and were under routine observation. Mean procedure time was 55±21 min. The 30-day mortality rate was 0.4% (2/513) (Table 2).

	Whole group	Short and/or angulated neck group
Case number	513	117
Range time	2/1999-12/2008	2/1999-12/2007
Technical success rate	98.4% (505/513)	97.4% (114/117)
Emergent conversion rate	1.6% (8/513)	2.6% (3/117)
Proximal cuff	61.0% (308/505)	100% (114/114)
Palmaz [®] stent	20.6% (104/505)	72.8% (83/114)
Primary type Ia endoleak	4.0% (20/505)	5.3% (6/114)
Type II endoleak	3.5% (18/505)	4.4% (5/114)
30-day mortality rate	0.4% (2/513)	1.7% (2/117)

Table 2. Procedure details and perioperative complications

503 cases were followed up for mean 5.2 years (range, 2 months–9.5 years). Proximal type I endoleak existed in 6 cases (1.2%), all of them were primary type Ia endoleaks, 4 were revised with proximal cuff and/or Palmaz[®] stent and 2 by selective open conversion. Type II endoleak existed in 22 cases (4.4%), limb occlusion rate was 1.0% (5/503), partial renal infarction occurred in 9 cases (1.8%) and selective open conversion rate was 1.6% (8/503). There were no aneurysms rupture, no device migration, no type III/IV endoleak and stent-graft rupture/fracture. A reduction in mean aneurysm sac diameters and volumes has been noted at every follow-up interval (Table 3).
Of the 117 patients with short and/or angulated neck, the technical success rate was 97.4% (114/117). Intraoperative complications included 3 (2.6%) emergent open conversions due to

delivery access problem, 6 (5.3%) primary type Ia endoleaks and 5 (4.4%) type II endoleaks. The 30-day mortality was 1.7% (2/117) (Table 2, 4). The 2.6-year follow-up results showed 4 (3.6%) primary type Ia endoleaks, which were revised with proximal cuff and/or Palmaz^R stent. Limb occlusion occurred in 2 (1.8%) cases. There were no open conversion, no aneurysm rupture, no device migration, no type III/IV endoleaks and stent-graft rupture/fracture (Table 3, 5).

	Whole group	Short and/or angulated neck group
Case number	513	117
Follow-up case number	503	112
Follow-up mean period	5.2 years	2.6 years
Type Ia endoleak	1.2% (6/503)	3.6% (4/112)
Type II endoleak	4.4% (22/503)	2.7% (3/112)
Limb occlusion rate	1.0% (5/503)	1.8% (2/112)
Partial renal infarction	1.8% (9/503)	2.7% (3/112)
Selective conversion rate	1.6% (8/503)	0.0% (0/112)
Aneurysm rupture	0	0
Device migration	0	0
Type III/IV endoleak	0	0
Stent-graft rupture	0	0

Table 3. Intraoperative and postoperative results

	Short neck (n=54)	Very short neck (n=26)	Angulated neck (n=37)
Successful implantation	52 (96.3%)	26 (100%)	37 (97.3%)
Delivery access problem	2	0	1
One proximal cuff	50 (96.2%)	22 (84.6%)	29 (80.6%)
Two proximal cuffs	2 (3.8%)	4 (15.4%)	7 (19.4%)
Proximal Palmaz stent	42 (80.8%)	23 (88.5%)	18 (50.0%)
Limb extension	6 (11.5%)	3 (11.5%)	3 (8.3%)
Suprarenal fixation	48 (92.3%)	26 (100%)	33 (91.7%)
Infrarenal fixation	4 (7.7%)	0	3 (9.3%)
Retrograde iliac TEA	3 (5.8%)	1 (3.8%)	2 (5.6%)
Femoral patch/angioplasty	3 (5.8%)	2 (7.6%)	3 (8.3%)
Iliac-fem bypass	0	0	1
Proximal type I endoleak	3 (5.8%)	1 (3.8%)	2 (5.6%)
Type II	2 (3.8%)	1 (3.8%)	2 (5.6%)
Type III/IV	0	0	0

Table 4. Procedure details and intraoperative complications in the hostile neck anatomy group

	Short neck (n=54)	Very short neck (n=26)	Angulated neck (n=37)
Proximal type I endoleak	2 (3.8%)	1 (3.8%)	1 (2.8%)
Type II endoleak	2 (3.8%)	0	1 (2.8%)
Partial renal infarction	2 (3.8%)	0	1 (2.8%)
Distal migration	0	0	0
Stent kinking	0	0	0
Limb occlusion	1 (1.9%)	0	1 (2.8%)

Table 5. Mean 2.6 years follow-up results in hostile neck anatomy group

4. Discussions

The applicability of endovascular aneurysm repair in abdominal aortic aneurysms mainly depends on the aortoiliac anatomy and morphology. Among all the challenging factors limiting application of this minimally invasive technique, the infrarenal aortic aneurysm neck morphology is still the most important determinant. The infrarenal neck length and angulation are the first parameters we should consider in the indication for endovascular aneurysm repair. Some clinical studies have made it clear that abdominal aortic aneurysms with short and/or angulated necks for endovascular aneurysm repair have a high risk of stent-graft distal migration and proximal type I endoleak, which make up the exact criteria in challenging cases. In one EUROSTAR study, 5183 patients underwent endovascular aneurysm repair from October 1996 to January 2006. Incidence of stent-graft migration, proximal type I endoleak, proximal neck dilatation, secondary interventions, aneurysm rupture, and all-cause and aneurysm-related mortality were compared between patients with and without severe infrarenal neck angulation (> 60 degrees angle between the infrarenal aortic neck and the longitudinal axis of the aneurysm). In the short term (before discharge), stent-graft migration (OR 2.17, 95% CI 1.20 to 3.91, p=0.0105) and proximal type I endoleak (OR 2.32, 95% CI 1.60 to 3.37, p<0.0001) were observed more frequently in patients with severe infrarenal neck angulation. Over the long term, proximal type I endoleak (HR 1.80, 95% CI 1.25 to 2.58, p=0.0016), higher incidences of proximal neck dilatation (> or =4 mm) (HR 1.26, 95% CI 1.11 to 1.43, p=0.0004) and need for secondary interventions (HR 1.29, 95% CI 1.00 to 1.67, p=0.0488) were seen in the severe infrarenal neck angulation group. All-cause mortality, rupture of the aneurysm and aneurysm-related mortality were similar in patients with and without severe infrarenal neck angulation. In the subgroup of patients with an Excluder endograft, proximal endoleak at the completion angiogram (OR 4.49, 95% CI 1.31 to 15.32, p=0.0166) and long-term proximal neck dilatation (HR 1.67, 95% CI 1.20 to 2.33, p=0.0026) were more frequently observed in patients with severe infrarenal neck angulation.

The endovascular aneurysm repair mechanism is to construct an endoluminal exclusion channel inside the native aortoiliac artery to exclude the aneurysm from the dynamic blood flow to prevent rupture, and the endoluminal exclusion channel must be stable and sealed. But short necks are unable to provide sufficient proximal landing zone for secure fixation and seal; angulated necks are unable to provide proper anchoring adaptation for secure fixation and seal. Is there an optimal device to adapt to these challenging anatomies? Most of the authors and the currently available devices emphasize the proximal fixation with

bars/hooks/crimps and suprarenal fixation, but device distal migration is still unavoidable. Interestingly, all the currently available modular devices were designed to implant starting just below the renal arteries, which will result in hanging the device inside the aneurysm sac. From the dynamic mechanism, it is not stable, as the blood flow through the stent-graft acts as a displacing force, and the endograft is normally held in position by friction dependant on the radial force of the graft against the aortic wall and the contact surface between the graft material and the artery wall.

Completely contrary to these modular devices, the Powerlink[®] one-piece long main body bifurcated stent-graft was designed to be implanted sitting on the native abdominal aortic bifurcation. We have termed this technique "Anatomical Fixation", which proved effective in eradicating distal migration. Mimicking construction of a building, the endoluminal exclusion channel can be built up to the renal artery level with an oversized long suprarenal proximal cuff. After endograft stability has been achieved, more attention should be paid to the proximal fixation and seal. A compulsory ballooning of the neck and the conjunction part was routinely carried out for better adaptation. Palmaz[®] stent implantation depends on the angiogram outcome. We normally implant the Palmaz[®] stent only if there is a high risk of proximal type I endoleak. A Palmaz[®] stent is used in the neck to strengthen the radial fixation force and to adapt the graft to the aortic wall for better seal. Balloon-expandable Palmaz[®] stent has been proven to provide better seal as well as fixation in treating hostile necks.

Qu et al reported their results of 612 eligible abdominal aortic aneurysm patients underwent endovascular aneurysm repair between 1999 and 2008 using the Powerlink[®] System in our center. Of the 612 patients, 99 cases (16%) completed between 1999 and 2004 had the endograft deployed from the renal artery downward. The remaining 513 cases (84%) completed afterwards had the bifurcated stent-graft deployed onto the native aortoiliac bifurcation. Among the 513 cases, 146 cases (28%) were deemed as challenging anatomy with short and/or angulated neck. Technical success was achieved in 98.5% of patients (603/612). Intraoperative emergent open conversion occurred in 9 patients, 8 of which were due to delivery access problems and 1 due to rupture. 3 deaths and 2 limb occlusions were encountered perioperatively. During the follow-up (mean: 5.2 years; maximum: 9.5 years), 1 rupture and 7 migrations occurred, all of which were in patients in whom the device was fixed at the level of the renal arteries. The rates of late selective open conversion in the renal fixation and anatomical fixation groups were 4.0% and 1.9%, respectively. Likewise, the cumulative rates of proximal type I endoleak in the groups of renal fixation and anatomical fixation were 5.0% and 1.2%, respectively. Remarkably, no stent fracture, graft disruption and type III/type IV endoleaks were observed in any patient. Harlin et al also reported the new results of 44 consecutive eligible patients enrolled in eight US sites between 2006 and 2008. Each patient underwent a Powerlink[®] infrarenal bifurcated stent-graft with anatomical fixation onto the native aortoiliac bifurcation and a suprarenal proximal cuff to achieve proximal sealing. Challenging infrarenal aortic neck anatomy was present in 93% of patients. Technical success rate was 100%. No aneurysm-related deaths, open conversions, migrations, or type III/IV endoleaks were observed. The majority of endoleaks (80%) observed during follow up were type II. The primary clinical success rate was 93%. Two secondary endovascular procedures were performed for type Ia or type Ib endoleak, and one surgical intervention was performed for resolution of limb occlusion. Significant reduction in sac diameter has been observed to up to 2 years. Between September 2005 and June 2008, a prospective, multicenter, pivotal US Food and Drug Administration trial of the Powerlink XL System for endovascular aneurysm repair was conducted at 13 centers. A total of 78 patients presenting with abdominal aortic aneurysm

and an infrarenal aortic neck up to 32 mm in diameter received the bifurcated stent-graft with anatomical fixation onto the native aortoiliac bifurcation and proximal sealing with a Powerlink XL infrarenal proximal extension stent-graft. Challenging infrarenal aortic neck anatomy was present in 85% of patients. Technical success was achieved in 98.7% of patients, with one patient requiring femoral-femoral bypass intraoperatively. Aneurysm exclusion was achieved in 100% of patients. At the one-month CT scan, the independent core lab identified a Type II endoleak in 13 patients, Type Ib and Type II endoleaks in one patient, and unknown endoleak in three patients. At 30 days, there were no deaths, open conversions, ruptures, or migrations. Through one year follow-up, Type II endoleak predominated (9/10 patients with endoleak), with one proximal Type I endoleak and no Type III/IV; no conversions, ruptures, or migrations have been observed. The one-year all-cause mortality rate was 6.4%, with 100% freedom from aneurysm-related mortality. Secondary procedures were performed within one year in five patients (6.4%) for treatment of proximal Type I endoleak (n = 2), proximal Type I/Type II endoleak (n = 1), and distal Type I endoleak (n = 2). Reduced or stable aneurysm sac diameter at one year was observed in 96% of patients. All these results suggest that anatomical fixation at the native aortic bifurcation can provide secure fixation for cases with hostile proximal aortic necks.

Short-term results suggested the use of the prophylactic adjunctive balloon-expandable Palmaz[®] stents may decrease the incidence of secondary interventions related to challenging neck anatomy when used as an adjunctive measure with endovascular aneurysm repair. Cox et al reviewed their experience of endovascular aneurysm repair with use of the Palmaz[®] stents in patients with hostile neck anatomy and type I endoleaks. Of 140 patients who underwent endovascular aneurysm repair between 2000 and 2004, they reviewed data of 19 patients in whom they used the proximal balloon-expandable stents. Palmaz[®] stents were deployed in the proximal graft with transrenal extension. AneuRx (18/19) and Zenith (1/19) endografts were used in all of the patients. Of the 19 patients, 15 had the prophylactic stent placement for known hostile neck anatomy and 4 patients had stent placement for type I endoleak. Assisted primary technical success was achieved in all patients. Three patients had maldeployment of the endograft or proximal stent requiring additional endovascular interventions at the time of surgery. No endografts were deployed too low requiring stent placement. Procedure-related complications occurred in 2 of 19 patients. These included 1 operative death secondary to pneumonia and 1 patient who developed progressive renal failure. Short-term clinical success was achieved in 17 of 19 patients. Two patients required secondary interventions, 1 due to device migration with secondary conversion to open repair, and an endoleak, which, on angiogram, was a large type II endoleak successfully treated with coiling of the inferior mesenteric artery. One patient was observed to have a type II endoleak with no associated aneurysm enlargement. Another retrospective review was made of 250 consecutive abdominal aortic aneurysm cases with hostile necks that underwent commercially available endograft treatment adjunctive with the Palmaz[®] stent in Arizona heart institute and Nuremberg south hospital from September 2005 to November 2009. The primary technical success rate was 83.6% (209/250). The mean time of follow-up was 23.4 months; the overall clinical success rate was 95.2% (238/250). The overall conversion rate was 2.4% (6/250) due to large proximal type I endoleak and sac enlargement. There was no neck dilation or graft migration. These results showed deployment of the Palmaz[®] stent in hostile necks has proved to be easy, effective and safe. At the beginning, most of the abdominal aortic aneurysm cases in our center were performed according to the publicly accepted anatomical criteria for endovascular aneurysm repair. With

accumulation of experience, the indication of endovascular aneurysm repair has been widely broadened. Abiding by the above philosophy, approximately 90%-95% of infrarenal abdominal aortic aneurysms in our unit can be treated with endovascular aneurysm repair, and we are treating more and more challenging cases (such as short neck, angulated neck, thrombus-affiliated neck, calcified neck and surface-irregular neck, et al) in this way.

In the whole group, with a mean 5.2-year long-term follow-up, the type Ia endoleak rate was only 1.2% (6/503). Even in the short and/or angulated neck group with mean 2.6-year mid-term follow-up, the proximal type I endoleak rate was 3.6% (4/112), without open conversion and distal migration. Our results have strongly demonstrated that the Endologix Powerlink^R endograft with “anatomical fixation” is very effective to prevent migration and type Ia endoleak for abdominal aortic aneurysms with challenging neck anatomy.

After building upon the foundation of the bifurcated endograft, a suprarenal proximal cuff with a long overlapping segment inside the bifurcated main body endograft is built up to the renal artery level. In our whole group, proximal long cuff was used in 61.0% (308/505) cases, and in the hostile neck group, all the patients had the proximal long cuff. This long cuff is not only used for prevention of type III endoleak but also useful for stretching the angulated segment of the infrarenal aorta, namely remodeling and straightening the proximal angulated neck. 20.6% (104/505) and 72.8% (83/114) patients had proximal Palmaz^R stents in the whole group and the hostile neck group, respectively, resulting in further remodeling of the infrarenal aorta with more contact area for better fixation and seal (Figure 7).

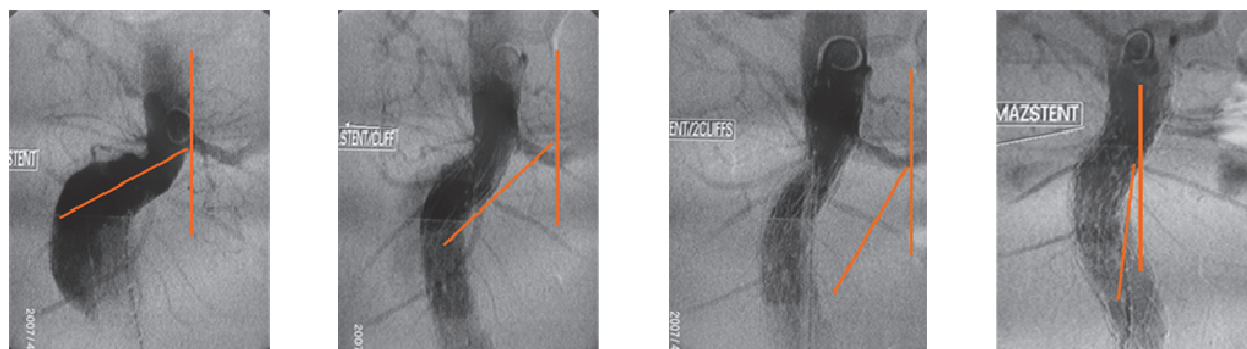


Fig. 7. Angiography-pictures after deployment of the Powerlink^R bifurcated main body stent, the first PowerFitTM proximal cuff, the second PowerFitTM proximal cuff, the Palmaz^R stent in turn

Regarding the device size choice, the Powerlink^R unibody bifurcated stent-graft is different from the modular devices. The distance from the lowest renal artery to the abdominal aortic bifurcation, and the distance from the aortic bifurcation to the hypogastric artery are important parameters for the size choice. Graft length is determined by the lengths of the native abdominal aorta and the common iliac artery. Graft diameter is determined by oversizing the endograft by 10-20% in excess of the measured neck diameter. Due to the several standard sizes of the main body, proximal cuff and limb extension, this system proved simple and easy for size selection. The most commonly used main body size in our unit is 25 mm in neck diameter, 10 cm in main body length, 16 mm in limb diameter, and 5.5 cm in limb length. The most commonly used suprarenal proximal cuff is 28 mm in diameter and 75 mm or 95 mm in length.

Common iliac aneurysm and/or hypogastric artery aneurysm or a too short common iliac artery can prevent safe and successful anchoring of the distal end of the limb of the stent. Some

studies reported that common iliac artery aneurysms exist in about 20% to 30% of patients with abdominal aortic aneurysms who were examined for endovascular aneurysm repair. In our study, the applicability of endovascular aneurysm repair was increased by 16.8% (86/513) after preliminary hypogastric aneurysm embolization. Therefore, preliminary embolization of hypogastric artery with additional extension of the graft to the external iliac artery may expand the indication of endovascular aneurysm repair. But we all know that hypogastric artery embolization will cause pelvic ischemic complications such as buttock claudication, sexual dysfunction and other pelvic ischemia symptoms (e.g., gluteal necrosis, spinal cord ischemia, rectosigmoid ischemia, or limb ischemia). In our center, a retrospective review was conducted of all 101 consecutive patients (91 men; mean age 73.4 ± 8.7 years) who underwent preliminary embolization of 133 hypogastric arteries about 4 to 6 weeks prior to endovascular aneurysm repair from January 2005 to August 2009. Fourteen patients with 19 hypogastric arteries were treated using coils, while 87 patients were treated with Amplatzer Vascular Plugs in 114 hypogastric arteries. In the coil group, complete occlusion was achieved in 16 (84.2%) of 19 procedures. There were no acute pelvic ischemic symptoms after hypogastric artery embolization or endovascular aneurysm repair. Five (35.7%) patients had buttock claudication and 2 (16.7%) of 12 men experienced new erectile dysfunction after embolization. At a mean 42.2-month follow-up (range 14-58), 3 (21.4%) patients had a type II endoleak via retrograde flow in the hypogastric artery without aneurysm growth and were under observation. In the Amplatzer Vascular Plugs group, all 114 hypogastric arteries in 87 patients were successfully occluded; there was no device dislodgment or limb ischemia observed. Buttock claudication and new sexual dysfunction developed in 12 (13.8%) patients and 4 (5.1%) of 79 men after the procedure, respectively. During a mean 26.4-month follow-up (range 4-54), 2 (2.3%) patients developed distal type I endoleaks after endovascular aneurysm repair, but angiography confirmed that neither of the endoleaks was related to the vessel embolized with the Amplatzer Vascular Plugs. Comparing the outcomes of the treatment groups, the Amplatzer Vascular Plugs was placed with fewer intraoperative complications ($p=0.013$) and more complete occlusion ($p=0.01$) than coil embolization. The rate of buttock claudication was lower in the Amplatzer Vascular Plugs group ($p=0.042$). Our clinical researches showed that hypogastric aneurysm embolization prior to endovascular aneurysm repair is safe and effective. The Amplatzer[®] Vascular Plug affords easier and more precise placement and provides more complete occlusion, with fewer intraoperative and postoperative ischemic complications than coil embolization.

For proximal type I endoleak, balloon angioplasty is first recommended in our experience. If it does not work, a Palmaz[®] stent in the aneurysm neck is able to cure the endoleak. There were 20 cases and 6 cases of primary proximal type I endoleaks in the whole group and the short and/or angulated neck group after balloon angioplasty, respectively. But after the deployment of the palmaz[®] stent, all of them were remedied or minimal that spontaneous vanish was expected by operators in the follow-up. During the mid-term or long-term follow-up, only 6 and 4 primary proximal type I endoleak still existed in the two groups. If there is still some space between the renal artery and the top of the stent-graft, a suprarenal proximal cuff with or without Palmaz[®] stent can achieve a good result. Only 2 cases in the whole group underwent selective open conversion, the other 4 were all remedied by endovascular re-intervention.

Delivery access problems were the main reasons for emergent open conversion. In our study, all of the intraoperative emergent open conversion occurred because of the delivery access problems. But with the accumulation of our experience, for most stenotic iliac

arteries, pre-dilatation with an 8 mm or 10 mm angioplasty balloon can usually solve the problem. If not, we preferred retrograde iliac artery endarterectomy with Moll Ring cutter.

9 (1.8%) cases in the whole group suffered from partial renal infarction found on computed tomography scan, but the renal function was not impaired. Though all these 9 cases had suprarenal fixation, a controlled study from two pivotal US Food and Drug Administration trials using the Powerlink^R bifurcated stent-graft revealed that suprarenal fixation does not lead to a significant increase in acute renal events, renal impairment, or alteration in blood pressure compared with infrarenal fixation. During the trials, 283 patients underwent endovascular aneurysm repair with the Powerlink^R bifurcated stent-graft. A comparison of preoperative, perioperative (1 ~ 7 days), and postoperative (>7 days) alterations in serum creatinine, creatinine clearance and blood pressure was done. Renal adverse events were determined by computed tomography scan and clinical chart review and included renal infarction, renal artery stenosis (either progressive or requiring renal stent placement) and renal artery occlusion. Both suprarenal fixation and infrarenal fixation groups showed a significant increase in serum creatinine and a decrease in creatinine clearance over time. No significant difference in serum creatinine or creatinine clearance existed between groups during any time period. There were no differences in postoperative renal impairment (infrarenal, 10.2%; suprarenal, 7.6%, $P = 0.634$), the need for hemodialysis (infrarenal, 0.7%; suprarenal, 0%, $P = 1.00$), systolic and diastolic blood pressure during subsequent follow-up between treatment groups. There was no significant difference in the number of renal adverse events detected by computed tomography between the infrarenal fixation (10, 6.8%) group and the suprarenal fixation (3, 3.8%) group ($P = 0.550$).

Proximal fixation devices artificially elevate the aortoiliac bifurcation, requiring contralateral limb cannulation some distance from the patient's native aortoiliac bifurcation. In the case of a narrow distal aorta, bi-lobed or saccular aneurysms, such maneuvers can be challenging or unachievable. An example of this is highlighted in a recent report regarding a newer device, where the distal aortic diameter averaged 33mm in enrolled patients, more than 50% increased over that of patients enrolled in the Powerlink^R anatomical fixation trials. Even with this large distal aortic diameter, intraoperative limb stenosis requiring stenting occurred in 11% of patients, with intervention within 30 days for limb occlusion or thrombosis performed in 2.2% of patients, leading the authors to suggest prophylactic intraoperative limb stenting. It is not known if the long-term rate of limb kinking/occlusion will be similar to the 4.3% rate reported for other currently available devices. Interestingly, endografts with fully supported limbs (e.g., Excluder, Powerlink^R) appear to have greater resistance to intraoperative stenosis and kinking and the lowest reported rates of limb kinking or occlusion with long-term follow-up (1.7%, 1.2%). Because the Powerlink^R device includes a pre-cannulated contralateral limb requiring only 9Fr percutaneous access, anatomical fixation implantation eliminates the cannulation problem.

In a multinational registry analysis of patients presenting with coronary artery disease, cerebrovascular disease, or peripheral arterial disease, patients with abdominal aortic aneurysms were found to have a three-fold increased incidence of peripheral artery disease than those without abdominal aortic aneurysms. One cannot deny that preserving the native aortoiliac bifurcation after endovascular aneurysm repair to enable future peripheral interventions is an important consideration. The anatomically fixed Powerlink^R device relining the abdominal aorta offers the opportunity for such subsequent peripheral interventions post-endovascular aneurysm repair.

The complexity of abdominal aortic aneurysm is commonly characterized based on location and involvement of visceral vessels. Infrarenal aneurysms generally involve the infrarenal

aorta and may involve the aortoiliac vasculature. A subset of infrarenal aneurysms extend up to the level of but do not involve the renal arteries (juxtarenal aneurysms) or extend further to involve one or both of the renal arteries (pararenal aneurysms). As noted previously, a substantial proportion of infrarenal aneurysms are not suitable for endovascular aneurysm repair due to unfavorable proximal neck anatomy (e.g., severely angulated, dilated, short, or encroaching on or involving the renal arteries). In regulatory studies of infrarenal endovascular aneurysm repair, patients were carefully selected to ensure neck length and angulation requirements were met in order to optimize outcomes. Shorter length or greater angulation has been reported since the original trials to increase the risk of migration and Type Ia endoleak and associated with need for intervention. Owing to the increased risk of renal complications, mesenteric ischemia and other complications following open repair of juxtarenal or pararenal aneurysms compared to infrarenal aneurysms, researchers have sought to extend a totally endovascular technique to repair these aneurysms. In this treatment, it is essential to maintain the patency of the renal arteries and other visceral vessels. Up to now, only homemade or customized fenestrated stent-grafts with the use of commercially available uncovered or covered vascular stents have been used for the repair of juxtarenal aneurysms. The key limitation to this approach is the need to customize the design and manufacture of each stent-graft to a particular patient anatomy. This requires a lengthy period of time for planning, manufacture, and delivery of the device, and is very costly. As a result, physicians have begun to seek other options, such as hybrid debranching techniques or chimney techniques. However, these options remain suboptimal. The concept of an off the shelf alternative to customization has been postulated; however this has yet to be realized. More recently, an off-the-shelf fenestrated stent-graft system has been developed based on the Powerlink[®] stent-graft. Integral to this system is the bifurcated stent-graft, anatomically fixed at the aortoiliac bifurcation, a fenestrated proximal extension with proprietary design, and compatible covered renal stents. All devices are constructed from cobalt chromium alloy for exceptional durability, and have a high density ePTFE covering. Initial estimates suggest this system will be applicable to 80% or more of patients with juxtarenal or pararenal aneurysm, without need for customization. Initial clinical experience will be available by the end of this year. Multicenter clinical trials are expected to commence in 2011, and if successful, would significantly increase the numbers of patients who could be treated endovascularly, would significantly reduce the time from diagnosis to treatment, and would represent significant improvement in cost effectiveness over the currently available options.

The field of endovascular aneurysm repair for abdominal aortic aneurysm has matured in recent years and is progressing into ever more challenging anatomy than treated in early trials. The problems of distal migration or endoleak remain, particularly in the more challenging anatomies. Clearly utilization of the native aortoiliac bifurcation as a strong foundation on which to place the Powerlink[®] bifurcated stent-graft followed by achievement of proximal seal with an aortic extension if needed is a simple yet elegant way of mitigating the risk of migration and endograft destabilization. The emergence of anatomical fixation with the availability of a well designed off the shelf proximal extension and visceral branch grafts, starting clinical evaluation at this time, has strong potential to not only address a significant unmet clinical need, but to address global demands for cost-effective options for these patients. Furthermore, the prospective clinical validation of a totally percutaneous approach to endovascular aneurysm repair will serve to advance this technique and its use

in properly selected patients. Other proximal fixation devices are in development or available in some regions that feature lower profile delivery systems and enhanced proximal fixation attachment mechanisms. A novel sac anchoring endovascular prosthesis (the Nellix device) is in final stages of regulatory review in Europe. This technology obliterates the aneurysm sac with a polymer-filled endobag and paving endoframe lumens. Although it has the potential to significantly reduce or eliminate the incidence of any endoleak, and thus reduce the surveillance necessary with other endovascular prostheses. Broader and longer term study will be necessary to validate this fully.

The next horizon yet to be addressed is the thoracic aorta, particularly the ascending aorta, where no adequate endovascular options yet exist. Although in final proprietary development at this time, a novel endografting approach utilizing a thoracic anatomical fixation technique with in situ fenestration and branch preservation is on the future horizon.

5. Conclusions

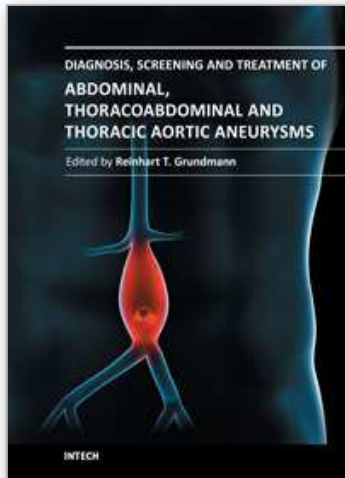
Our experience demonstrated that building up the endovascular exclusion system in the abdominal aortic aneurysms using the unibody Powerlink^R device with proximal cuff and/or additional Palmaz^R stent showed a satisfactory long-term outcome, even proved safe and effective in treating abdominal aortic aneurysms with short and/or angulated neck. With this intuitive approach, stent graft migration and its related potential complications are virtually eliminated. However, prospective longer follow-up in multicenter randomized controlled larger series are necessary to confirm these encouraging outcomes.

6. References

- Armon, MP; Wenham, PW. & Whitaker, SC. (1998). Common iliac artery aneurysms in patients with abdominal aortic aneurysms. *Eur J Vasc Endovasc Surg*, Vol. 15, No. 3, (March 1998), pp. 255-257, ISSN 1078-5884
- Alterman, DM. & Stevens, SL. (2008). The Excluder aortic endograft. *Perspect Vasc Surg Endovasc Ther.* Vol. 20, No. 2, (June 2008), pp. 136-148, ISSN 1531-0035
- AbuRahma, AF; Campbell, J. & Stone, PA. (2009). The correlation of aortic neck length to early and late outcomes in endovascular aneurysm repair patients. *J Vasc Surg*, Vol. 50, No. 4, (October 2009), pp. 738-748, ISSN 0741-5214
- Baumgartner, I; Hirsch, AT. & Abola, MT. (2008). Cardiovascular risk profile and outcome of patients with abdominal aortic aneurysm in out-patients with atherothrombosis: data from the reduction of atherothrombosis for continued health (REACH) registry. *J Vasc Surg*, Vol. 48, No. 4, (October 2008), pp. 808-814, ISSN 0741-5214
- Brinster, CJ; Fairman, RM. & Woo, EY. (2011). Late open conversion and explantation of abdominal aortic stent grafts. *J Vasc Surg*, Epub ahead of print, (February 2011), ISSN 0741-5214
- Cox, DE; Jacobs, DL. & Motaganahalli, RL. (2006). Outcomes of endovascular AAA repair in patients with hostile neck anatomy using adjunctive balloon-expandable stents. *Vasc Endovasc Surg*, Vol. 40, No. 1, (January-February 2006), pp. 35-40, ISSN 1538-5744
- Cochennec, F; Becquemin, JP. & Desgranges, P. (2007). Limb graft occlusion following EVAR: clinical pattern, outcomes and predictive factors of occurrence. *Eur J Vasc Endovasc Surg*, Vol. 34, No. 1, (June 2007), pp. 59-65, ISSN 1078-5884

- Chaikof, EL; Brewster, DC. & Dalman, RL. (2009). The care of patients with an abdominal aortic aneurysm: The Society for Vascular Surgery practice guideline. *J Vasc Surg*, Vol. 50, No. 4 Suppl, (October 2009), pp. S2-49, ISSN 0741-5214
- Carpenter, JP; Garcia, MJ. & Harlin, SA. (2010). Contemporary results of Endovascular repair of abdominal aortic aneurysms: effect of anatomical fixation on outcomes. *J Endovasc Ther*, Vol. 17, No. 2, (April 2010), pp. 153-162, ISSN 1526-6028
- Dillavou, ED; Muluk, SC. & Rhee, RY. (2003). Does hostile neck anatomy preclude successful endovascular aortic aneurysm repair? *J Vasc Surg*, Vol. 38, No. 4, (October 2003), pp. 657-663, ISSN 0741-5214
- Donayre, CD; Zarins, CK. & Krievins, DK. (2011). Initial clinical experience with a sac-anchoring endoprosthesis for aortic aneurysm repair. *J Vasc Surg*, Vol. 53, No. 3, (March 2011), pp. 574-582, ISSN 0741-5214
- Fulton, JJ; Farber, MA. & Marston, WA. (2005). Endovascular stent-graft repair of pararenal and type IV thoracoabdominal aortic aneurysms with adjunctive visceral reconstruction. *J Vasc Surg*, Vol. 41, No. 2, (February 2005), pp. 191-198, ISSN 0741-5214
- Greenhalgh, RM; Brown, LC. & Kwong, GP. (2004). Comparison of endovascular aneurysm repair with open repair in patients with abdominal aortic aneurysm (EVAR trial 1), 30-day operative mortality results: randomized controlled trial. *Lancet*, Vol. 364, No. 9437, (September 2004), pp. 843-848, ISSN 0140-6736
- Henretta, JP; Karch, LA. & Hodgson, KJ. (1999). Special iliac artery considerations during aneurysm endografting. *Am J Surg*, Vol. 178, No. 3, (September 1999), pp. 212-218, ISSN 0002-9610
- Hobo, R; Buth, J. & Eurostar collaborators. (2006). Secondary interventions following endovascular abdominal aortic aneurysm repair using current endografts. A EUROSTAR report. *J Vasc Surg*, Vol. 43, No. 5, (May 2006), pp. 896-902, ISSN 0741-5214
- Hobo, R; Kievit, J. & Leurs, LJ. (2007). Influence of severe infrarenal aortic neck angulation on complications at the proximal neck following endovascular AAA repair: a Eurostar study. *J Endovasc Ther*, Vol. 14, No. 1, (February 2007), pp. 1-11, ISSN 1526-6028
- Harlin, SA; Beasley, RE. & Feldman, RL. (2010). Endovascular abdominal aortic aneurysm repair using an anatomical fixation technique and concomitant suprarenal orientation: results of a prospective, multicenter trial. *Ann Vasc Surg*, Vol. 24, No. 7, (October 2010), pp. 921-929, ISSN 0890-5096
- Jordan, WD Jr; Moore, WM Jr. & Melton, JG. (2009). Secure fixation following EVAR with the Powerlink XL System in wide aortic necks: results of a prospective, multicenter trial. *J Vasc Surg*, Vol. 50, No. 5, (November 2009), pp. 979-986, ISSN 0741-5214
- Lee, ES. & Zarins, CK. (2004). Endograft migration: incidence, causes, and clinical significance. *Perspect Vasc and Endovasc Surg*, Vol. 16, No. 3, (September 2004), pp. 187-191, ISSN 1531-0035
- Li, Z. & Kleinstreuer, C. (2006). Analysis of biomechanical factors affecting stent-graft migration in an abdominal aortic aneurysm model. *J Biomechanics*, Vol. 39, No. 12, (September 2005), pp. 2264-2273, ISSN 0021-9290
- Leurs, LJ; Kievit J. & Dagnelie, PC. (2006). Influence of infrarenal neck length on outcome of endovascular abdominal aortic aneurysm repair. *J Endovasc Ther*, Vol. 13, No. 5, (October 2006), pp. 640-648, ISSN 1526-6028

- Mehta, M; Sternbach, Y. & Taggert, JB. (2010). Long-term outcomes of secondary procedures after endovascular aneurysm repair. *J Vasc Surg*, Vol. 52, No. 6, (December 2010), pp. 1442-1449, ISSN 0741-5214
- Nordon, IM; Hinchcliffe, RJ. & Manning, B. (2010). Toward an "off-the-shelf" fenestrated endograft for management of short-necked abdominal aortic aneurysms: an analysis of current graft morphological diversity. *J Endovasc Ther*, Vol. 17, No. 1, (February 2010), pp. 78-85, ISSN 1526-6028
- Parodi, JC.; Palmaz, JC. & Barone, HD. (1991). Transfemoral intraluminal graft implantation for abdominal aortic aneurysms. *Ann Vasc Surg*, Vol.6, No. 4, (November 1991), pp. 491-499, ISSN 0890-5096
- Prinssen, M; Verhoeven, EL. & Buth, J. (2004). A randomized trial comparing conventional and endovascular repair of abdominal aortic aneurysms. *N Engl J Med*, Vol.351, No. 16, (October 2004), pp. 1607-1618, ISSN 0028-4793
- Parmer, SS. & Carpenter, JP. (2006). Endovascular aneurysm repair with suprarenal vs infrarenal fixation: a study of renal effects. *J Vasc Surg*, Vol. 43, No. 1, (January 2006), pp. 19-25, ISSN 0741-5214
- Peterson, BG; Matsumura, JS. & Brewster, DC. (2007). Five-year report of a multicenter controlled clinical trial of open versus endovascular treatment of abdominal aortic aneurysms. *J Vasc Surg*, Vol. 45, No. 5, (May 2007), pp. 885-890, ISSN 0741-5214
- Qu, LF; Hetzel, G. & Raithel, D. (2007). Seven years' single center experience of Powerlink unibody bifurcated endograft for endovascular aortic aneurysm repair. *J Cardiovasc Surg (Torino)*, Vol. 48, No. 1, (February 2007), pp. 13-19, ISSN 0021-9509
- Qu, L. & Raithel, D. (2008) Experience with the Endologix Powerlink endograft in endovascular repair of abdominal aortic aneurysms with short and angulated necks. *Perspect Vasc Surg Endovasc Ther*. Vol. 20, No. 2, (June 2008), pp. 158-166, ISSN 1531-0035
- Qu, L. & Raithel, D. (2009) From clinical trials to clinical practice: 612 cases treated with the Powerlink stent-graft for endovascular repair of AAA. *J Cardiovasc Surg (Torino)*, Vol. 50, No. 2, (April 2009), pp. 131-137, ISSN 0021-9509
- Raithel, D; Qu, Lefeng. & Hetzel, G. (2006). A new concept in EVAR, In: *Endovascular Today*, May 2006, Available from http://www.bmctoday.net/evtoday/2006/05/article.asp?f=EVT0506_08.html
- Raithel, D. (2011). Endovascular Abdominal Aortic Aneurysm Repair: An Overview of the Anatomical Fixation Technique and Associated Outcomes with the Powerlink^R Device. *J Interv Cardiol*, Epub ahead of print, (April 2011), ISSN 0896-4327
- Stanley, BM; Semmens, JB. & Mai, Q. (2001) Evaluation of patient selection guidelines for endoluminal AA A repair with the Zenith stent-graft: the Australasian experience. *J Endovasc Ther*, Vol. 8, No. 5, (October 2001), pp. 457-464, ISSN 1526-6028
- Schermerhorn, M; O'Malley, J. & Jhaveri, A. (2008). Endovascular vs. open repair of abdominal aortic aneurysms in the Medicare population. *N Engl J Med*, Vol.358, No. 5, (January 2008), pp. 464-474, ISSN 0028-4793
- Torsello, G; Troisi, N. & Tessarek, J. (2010). Endovascular aortic aneurysm repair with the Endurant stent graft: early and 1-year results from a European multicenter trial. *J Vasc Interv Radiol*, Vol. 21, No. 1, (January 2010), pp. 73-80, ISSN 1051-0443
- Wu, Z; Qu, L. & Ramaiah, V. (2011). Controversies and Updates in Vascular Surgery, Edizioni minerva medica, ISBN 13: 978-88-7711-701-4, TORINO, ITALY
- Wu, Z; Raithel, D. & Ritter, W. (2011). Preliminary embolization of the hypogastric artery to expand the applicability of endovascular aneurysm repair. *J Endovasc Ther*, Vol. 18, No. 1, (February 2011), pp. 114-120, ISSN 1526-6028



Diagnosis, Screening and Treatment of Abdominal, Thoracoabdominal and Thoracic Aneurysms

Edited by Prof. Reinhart Grundmann

ISBN 978-953-307-466-5

Hard cover, 414 pages

Publisher InTech

Published online 12, September, 2011

Published in print edition September, 2011

This book considers mainly diagnosis, screening, surveillance and treatment of abdominal, thoracoabdominal and thoracic aortic aneurysms. It addresses vascular and cardiothoracic surgeons and interventional radiologists, but also anyone engaged in vascular medicine. The high mortality of ruptured aneurysms certainly favors the recommendation of prophylactic repair of asymptomatic aortic aneurysms (AA) and therewith a generous screening. However, the comorbidities of these patients and their age have to be kept in mind if the efficacy and cost effectiveness of screening and prophylactic surgery should not be overestimated. The treatment recommendations which will be outlined here, have to regard on the one hand the natural course of the disease, the risk of rupture, and the life expectancy of the patient, and on the other hand the morbidity and mortality of the prophylactic surgical intervention. The book describes perioperative mortality after endovascular and open repair of AA, long-term outcome after repair, and the cost-effectiveness of treatment.

How to reference

In order to correctly reference this scholarly work, feel free to copy and paste the following:

Ziheng Wu, Lefeng Qu, Dieter Raithel and Konstantinos Xiromeritis (2011). 12-year Experience with the Endologix PowerlinkR Device in Endovascular Repair of Abdominal Aortic Aneurysms, Diagnosis, Screening and Treatment of Abdominal, Thoracoabdominal and Thoracic Aortic Aneurysms, Prof. Reinhart Grundmann (Ed.), ISBN: 978-953-307-466-5, InTech, Available from: <http://www.intechopen.com/books/diagnosis-screening-and-treatment-of-abdominal-thoracoabdominal-and-thoracic-aortic-aneurysms/12-year-experience-with-the-endologix-powerlinkr-device-in-endovascular-repair-of-abdominal-aortic-a>

INTECH
open science | open minds

InTech Europe

University Campus STeP Ri
Slavka Krautzeka 83/A
51000 Rijeka, Croatia
Phone: +385 (51) 770 447
Fax: +385 (51) 686 166
www.intechopen.com

InTech China

Unit 405, Office Block, Hotel Equatorial Shanghai
No.65, Yan An Road (West), Shanghai, 200040, China
中国上海市延安西路65号上海国际贵都大饭店办公楼405单元
Phone: +86-21-62489820
Fax: +86-21-62489821

© 2011 The Author(s). Licensee IntechOpen. This chapter is distributed under the terms of the [Creative Commons Attribution-NonCommercial-ShareAlike-3.0 License](https://creativecommons.org/licenses/by-nc-sa/3.0/), which permits use, distribution and reproduction for non-commercial purposes, provided the original is properly cited and derivative works building on this content are distributed under the same license.

IntechOpen

IntechOpen