

We are IntechOpen, the world's leading publisher of Open Access books Built by scientists, for scientists

6,900

Open access books available

185,000

International authors and editors

200M

Downloads

Our authors are among the

154

Countries delivered to

TOP 1%

most cited scientists

12.2%

Contributors from top 500 universities



WEB OF SCIENCE™

Selection of our books indexed in the Book Citation Index
in Web of Science™ Core Collection (BKCI)

Interested in publishing with us?
Contact book.department@intechopen.com

Numbers displayed above are based on latest data collected.
For more information visit www.intechopen.com



Incidence and Predictors of Clinical Failures Following Catheter-Based Treatment of Abdominal Aortic Aneurysms

Daniel R. Watson, Angela Kruse, Jeffrey Weiner and Christina Prabhu
*Riverside Methodist Hospital
 United States*

1. Introduction

An abdominal aortic aneurysm (AAA) is a balloon-like bulge or weakened area in the wall of aorta. The larger the aneurysm becomes, the more likely it will rupture which could lead to life-threatening bleeding, and potentially death. Surgical repair of the aneurysm prior to rupture is often life-saving. This can be performed either as an open procedure or endoluminal with a stent graft.

The management of abdominal aortic aneurysms (AAA), whether discovered incidentally on imaging studies or by an astute physician on physical exam, continues to have a huge impact on clinical practice and the lives of patients. Through research, the art of medicine, and extensive patient counseling, surveillance versus elective repair continues to be a dynamic and changing science. When indications for elective repair arise, such as worsening symptoms, increased or rapid growth of the aneurysm, or a diameter greater than 5 cm is present, a decision regarding surgical options are brought to the forefront.

Open AAA repair was the sole form of surgical treatment until endoluminal repair was introduced into practice in 1991. Much research has been publicized supporting the decreased recovery time and the short term morbidity of endoluminal repair compared to open repair. However, some authors suggest that the benefits of endoluminal repair with respect to mortality rate achieved in the early postoperative period disappear in the long term recovery scheme (Zeebregts et al., 2004).

The controversies surrounding endoluminal repair of AAA have involved defining the ideal candidate based on risk factor stratification and overcoming challenging anatomy of the aorta. According to Steinmetz et al, "the ideal candidate for endovascular repair [is] still to be defined" (Steinmetz et al., 2010). However, with new improvements to detect complications intraoperatively, and advances in technology to prevent/treat migration and endoleaks, the quest to determine the ideal candidate may be unnecessary. The presence of an intraoperative endoleak may increase the likelihood of an endoleak being seen during the follow-up period, but not necessarily the likelihood of an additional reintervention or operative procedure (Sampaio et al., 2009). The ultimate goal is to enable the applicability of this elective, minimally invasive approach to prevent the catastrophic event of a ruptured AAA to be widespread.

Endoluminal AAA repair obviates the three major physiologic insults associated with open repair laparotomy, aortic cross-clamping, and ischemia reperfusion injury (Halak et al.,

2007). In addition, the majority of the patients undergoing endovascular aneurysmal repair (EVAR) had regional anesthesia, thus reducing perioperative morbidity associated with sedative medication utilization in patients with multiple co-morbidities. Furthermore, this study determined that the duration of operation was shorter, blood loss was significantly less, and there was decreased hospital stay in the EVAR verses open repair (Zeebregts et al., 2004).

For these reasons, uncertainty remains regarding the long-term effectiveness of endoluminal AAA repair and its proper role in the management of patients with AAA. In particular, debate continues as to whether or not younger patients at good risk should be treated in this fashion or whether small aneurysms should be treated at an earlier interval in a more aggressive approach with stent grafts. To examine outcome data that might impact decisions on these issues, we reviewed a 12-year experience with 807 primary AAA endografts to determine the frequency of beneficial outcome and the incidence and causes of clinical failures of endovascular repair.

2. Materials and methods

Over 12 years ending in 2010, 807 patients underwent endovascular repair of infrarenal AAA. Five devices were used over this period: Ancure (Guidant, Menlo Park, Calif), AneuRx (Medtronic/AVE, Santa Rosa, Calif), Excluder (W. L. Gore, Flagstaff, Ariz), Quantum (Cordis Corp., NJ) and Zenith (Cook Inc, Bloomington, Ind). All procedures were performed in a Hybrid operating room environment, where Radiologic imaging was performed with a high-quality, fixed C-arm fluoroscopic unit with digital imaging and road mapping capability on a radiolucent operating room table with movable top.

Patient selection for the procedure and decisions regarding devices used were based on radiologic imaging studies. Preoperative helical computed tomography (CT) was performed with 3 mm axial reconstruction. If initial measurements and morphology of the aneurysm were favorable for endovascular repair, multiplanar contrast angiography was performed with a special catheter with radiopaque markers at 1-cm intervals (Cook, Inc) to allow for precise length measurements and assessment of renal and pelvic anatomy, particularly in regard to device access and deployment. Intravascular ultrasound studies were also performed when measurements were deemed inaccurate on the basis of these studies, or in the presence of suspected renal or iliac occlusive disease. Except in patients with contraindications to contrast material, postoperative CT scans included non-contrast-enhanced, contrast-enhanced, and 3-minute to 5-minute delayed post-contrast-enhanced images.

Outcome was assessed with physical examination, lower extremity arterial studies, plain abdominal radiography, and computed tomography at discharge, at 1, 6, and 12 months postoperatively, and annually thereafter.

Data were collected from a review of operative imaging reports and physician chart notes. Any significant discrepancy between these two data sources prompted an interrogation of the source imaging studies. Outcome reporting adhered to the standards outlined by the Ad Hoc Committee for Standardized Reporting Practices in Vascular Surgery of The Society for Vascular Surgery/American Association for Vascular Surgery (SVS/AAVS) (Chaikof et al., 2002)

Clinical failures of endovascular AAA repair were defined as the following events: peri-procedural death (<30 days), late (>30 days) or late conversion of endograft repair to

conventional open surgical repair, increase in maximal AAA sac diameter of 5 mm or greater after endograft exclusion, and AAA rupture after endoluminal aneurysm treatment. All perioperative deaths occurred as a result of aneurysm rupture or after a primary or secondary procedure directed at treating the aneurysm or complications thereof.

Secondary procedures were defined as any subsequent procedure (exclusive of diagnostic angiography), whether percutaneous or open surgical, related to aneurysm repair or complications thereof. While procedures performed because of wound complications were tabulated for descriptive purposes, they were excluded from statistical analysis.

Endoleak was classified on the basis of serial imaging studies. CT findings, although most influential, composed only one factor. Presumed type I leak observed on CT scans was invariably followed up with angiographic confirmation. A leak was considered type II when the contrast collection was posterior or at the orifice of the inferior mesenteric artery. Type II and IV endoleaks noted only on an intraoperative or predischARGE imaging study were excluded from analysis. Leakage through enlarged suture holes or fabric tears was classified as type III endoleak, as were defects related to separation of modular components. An endoleak was suspected to be type III when it directly abutted the graft fabric or was associated with obvious disunion of components; half of these were confirmed at angiography or at open surgical conversion.

Migration was defined with clinical and radiographic parameters, as suggested by the SVS/AAVS document on endovascular reporting standards (Chaikof et al., 2002). Migration included caudal movement of the proximal attachment site or cranial movement of a distal attachment site. A device was considered to have migrated when at least 1 cm of movement was noted relative to anatomic landmarks, when the patient experienced symptoms, or when an intervention was undertaken to treat migration, irrespective of distance.

Aneurysm shrinkage or growth was determined with a pre-procedural CT scan performed 3 months or less before the date of the procedure as the baseline. A predischARGE imaging study was used as the reference scan when a preoperative study was not available. Size measurements were made on the CT scan with the greatest minor sac dimension on any axial image. Aneurysm shrinkage was defined as decrease of 5 mm or more in the minor dimension of the sac; enlargement was defined as increase of 5 mm or more in this dimension.

The individual clinician responsible for the patient's determined the need for secondary procedures. Certain clinical events mandated intervention, including post-implant aneurysm rupture or symptomatic graft limb occlusion. Most, however, were less catastrophic, and the need for secondary intervention was subjective. Basic treatment paradigms were, however, standard at the institution.

Treatment of types I and III endoleaks was always recommended. Type II endoleak was treated when the aneurysm sac was observed to enlarge over time. As well, patients with type II leak received treatment when the aneurysm failed to contract despite observation for more than 12 months after the initial endovascular repair. Type II leak in patients with a shrinking sac was not treated. Device migration was treated when it was associated with a type I leak or when the remaining length of sealing was deemed inadequate, usually when reduced to less than 10 mm.

3. Results

Eighty percent of treated patients were men. The mean age was 72.6 years (range, 44 to 87 years), and the mean AAA sac maximal diameter was 5.7 cm (range, 4.1 to 10.2 cm). Risk

factors and co-morbidities were typical of patients undergoing vascular surgical procedures. Patient demographics are displayed in Table 1.

In the 12-year experience, one or more clinical failures, as defined previously, were observed in a total of 74 patients (9.2%). Because some patients had more than one adverse event denoting failure, the number of such events exceeded the number of patients sustaining them.

Patient Demographics (n = 807)	Mean/n (range/%)
Age (years)	72.6 (range 44-87)
Gender	
Male	646 (80)
Female	161 (20)
Average sac diameter (cm)	5.7 (range 4.1-10.2)
Comorbidities	
HTN	480 (59)
CAD	451 (56)
Tobacco use	407 (50)
Diabetes	159 (20)
Hyperlipidemia	255 (32)
COPD	201 (25)
Renal insufficiency	79 (10)
Notes: HTN = Hypertension, CAD = coronary artery disease; COPD = chronic obstructive pulmonary disease	

Table 1. Patient demographics

3.1 Operative deaths

Eight periprocedural deaths (1%) occurred in the total of 807 AAA stent graft repairs (Table 2.) One death occurred as the result of an acute myocardial infarction on day 3 after implant in a patient with a symptomatic AAA at high risk with known extensive coronary artery disease not amenable to surgical or catheter-based repair. This mortality occurred early in our experience after the procedure had been prolonged with a series of vascular access, device introduction, and deployment difficulties. Although eventually a technically successful implant was achieved, in retrospect, more prompt conversion to standard open repair would likely have resulted in a more favorable outcome.

Diffuse atheroembolization was the most common cause of death in our series after endoluminal stent graft placement. Uniformly, the 4 patients afflicted by this complication expired secondary to severe multisystem organ failure. All patients had significant thrombus burden within either the proximal landing zone or suprarenal aorta (or both). The complication was seen irrespective of graft type or fixation mechanism. In each case the potential for this complication had been recognized preoperatively. However, endoluminal therapy was chosen for AAA repair due to patient/family demand (2 cases), hostile abdominal status for open repair (1 case), or severe concomitant pulmonary disease which precluded the likelihood of postoperative extubation (1 case). In three cases the primary inciting event was the discovery of inoperable small bowel (2 cases) or colonic (1 case) ischemia. All patients had arteriographic demonstration of proximal, branch vessel patency when the complication was initially suspected. But the distal vascular “pruning” was resistant to all attempts at pharmacologic rescue. In the remaining case the insult was rendered to the parenchyma of a lone kidney. The family refused dialysis and withdrew supportive care 10 days after surgery.

One sudden early death occurred at home 8 days after discharge and was presumed to be the result of rupture of a large symptomatic AAA. No evidence of a proximal attachment leak had been suspected on pre-discharge CT scanning, but the patient had a short, angulated proximal AAA neck and was high-risk for graft migration. We elected to schedule this patient for frequent surveillance for a period of several months. Although no autopsy was performed to confirm rupture, this seems the likely cause, as the patient had severe back and abdominal pain before collapse.

Another patient became hypotensive in the hospital 12 hours after an endoluminal repair during which a persistent endoleak was evident at the distal fixation zone. The leak appeared resistant to all conventional means of resolution (ballooning, additional cuff, stents, etc) and it was elected to inject biologic glue into the coaptation zone. Emergency CT scan showed complete thrombosis of the entire pelvic vasculature, emanating from the affected internal iliac artery in the landing zone. Limb and lower extremity ischemia ensued soon thereafter. Despite operative exploration and fem-fem bypass, the patient died of renal and pulmonary insufficiency after a prolonged and complex 2-week postoperative course. In retrospect, more prompt conversion to standard open repair would likely have undoubtedly resulted in a more favorable outcome.

The remaining early death occurred after an early complication of attempted sheath insertion for endograft implantation, resulting in external iliac rupture and severe retroperitoneal hemorrhage. Attempt at open repair failed due to prolific calcification throughout the patient’s aorto-iliac system, confounding conventional attempts at vascular clamping or suture repair.

A common thread in most of these cases was technical complications occurring in patients who were elderly, fragile, and at high risk for perioperative morbidity.

Cause	n (%)
MI after surgery	1 (0.1)
Massive atheroemboli	4 (0.4)
Died at home 8 days after discharge	1 (0.1)
Limb /pelvic thrombosis-rhabdomyolysis	1 (0.1)
Avulsion EIA	1(0.1)
Notes: MI=myocardial infarction, EIA=external iliac artery	

Table 2. Perioperative deaths (30 days)

3.2 Early conversions

During the 12-year study period, twelve patients (1.5%) needed early conversion to open repair within the first 48 hours after the procedure. Successful endograft implantation was achieved in the remaining 795 patients, for an overall procedural technical success rate of 98.5%. Two patients treated early in our experience had small, calcified iliac arteries that sustained severe traumatic injury during attempted passage of large-caliber stents or devices. In retrospect, these cases were examples of inappropriate judgments and poor patient selection, typical of grappling with a formidable “learning curve” associated with a new, paradigm-changing technology. One of the patients had a 360-degree twist in the limbs of an unsupported Ancure bifurcated device (Guidant, Santa Clara, Calif) that could not be corrected, requiring fem-fem bypass. Another patient needed immediate conversion when acute migration of the proximal attachment system occurred in a short and heavily calcified aortic neck, resulting in the endograft falling into the AAA sac. Seven patients required fem-fem bypass for access site complications ranging from uncontrollable hemorrhage to occlusion, not amenable to conventional repair secondary to vessel fragility, small size, or calcification. The final patient in this subgroup had acute rupture of his aneurysm on postoperative day 8, as already described in the previous section detailing periprocedural deaths.

3.3 Late conversions

Nine patients (1.1%) needed late (30 days) conversion to standard open graft repair for a variety of clinical scenarios. Conversions were performed at a mean of 20 months after the original endograft procedure (range, 9 to 32 months). Six of nine conversions in our series were caused by AAA sac growth with demonstrated endoleak (“endotension”). Two endoluminal grafts needed late conversion as the result of graft infection. Both were presumed to be caused by septicemic seeding of the endoluminal device. Although these cases might conceivably be the result of primary endograft infections, this is much less likely in our opinion. One conversion in our series was caused by continued AAA sac growth *without* demonstrated endoleak. At the time of laparotomy and explantation, numerous small leaks were evident at the suture-fixation points of the stents to the graft.

As outlined above, conversion was necessary in seven patients because of continued AAA growth. Endoleak was present in all but one patient in this subgroup. One patient had a persistent proximal type 1 attachment leak, four had persistent type 2 leaks from lumbar arteries, and one patient an acute late type 3 endoleak caused by a fabric hole erosion in a Zenith endograft implanted 20 months previously. The patient had done well, with sac shrinkage and no demonstrable endoleak, up to the 6-month interval. The patient then was seen with sudden back pain, and CT scanning showed a type 3 leak with acute sac re-expansion. Emergent open operation and repair proceeded uneventfully. One patient did well until 32 months after the original procedure when he was seen at an outside facility with a septic left ankle joint. The patient underwent treatment with drainage and antibiotics. Within several months, however, the patient returned again with bilateral septic hips and septic shoulder joint. Blood cultures grew methicillin-resistant *Staphylococcus aureus*. The patient again underwent treatment with drainage and antibiotics. Despite this, a psoas muscle abscess developed that was drained percutaneously. However, subsequent CT scans showed communication with the endograft and the area of abscess.

Further, evidence of bone destruction developed of vertebral bodies lumbar 3 and 4. Subsequently, the patient underwent a staged procedure of axillobifemoral bypass grafting followed by removal of the infected endograft with radical debridement of vertebral body osteomyelitis. The patient was discharged from the hospital after a prolonged hospital course.

One patient needed late conversion at 27 months for acute thrombosis of the entire endograft, resulting in severe lower extremity ischemia. Prior follow-up CT scans had shown good AAA exclusion, with sac shrinkage and no endoleak. However, distortion and slight kinking of the endograft limbs was noted and believed attributable to the morphologic sac changes caused by its shrinkage. The patient was asymptomatic with intact pulses, so observation and continued surveillance was elected. Presumably, limb kinking increased, resulting in thrombosis. Emergent axillobifemoral bypass grafting was performed, with a satisfactory result.

3.4 Sac growth

In the series, follow-up CT imaging revealed 82 patients with sac growth of the aneurysm of 5 mm or greater, despite endoluminal repair of the AAA.

All of these patients had at least 90 days of follow-up. Of the 82 patients, 64 thus far have undergone successful treatment with endovascular therapies. Further secondary interventions are planned for most of the remaining patients with AAA sac growth but had not yet been performed when the study period was terminated. Such secondary procedures included a variety of catheter-based therapies, including insertion of proximal or distal extender cuffs, branch or sac embolization, or related interventions as deemed appropriate with angiography or other diagnostic methods. None of the patients with sac growth are symptomatic, and no ruptures, thromboses, or conversions have occurred in this cohort.

3.5 Ruptures

During the 12-year experience, seven patients (0.9%) are believed to have had AAA rupture after their endoluminal repair. five patients, all with unproven but presumed rupture at home at varying intervals (5-17 months) after surgery and a sixth with post-discharge

rupture on postoperative day 5 have already been described previously in the sections detailing periprocedural deaths and early conversions.

A final rupture occurred at 2 years after the original endovascular procedure.

The patient had undergone three interval CT scans that had shown no leak and a decrease in maximal AAA diameter from 5 to 4.6 cm. Shortly after the most recent follow-up CT scan, the patient was seen acutely with abdominal and back pain. Emergency CT scan showed a large endoleak and acute re-expansion of the AAA sac to greater than the original 6-cm diameter, with an adjacent retroperitoneal hematoma. At emergency operation, acute detachment of the proximal stent attachment mechanism was found, with the distal endograft lying free in the AAA sac. We presumed the shrinking AAA sac wall had become atretic and ruptured when acutely repressurized. The patient survived operative conversion to open repair. After a prolonged hospitalization, the patient was discharged to a rehabilitation facility.

Despite often extensive and emergent operations needed for late conversion of endovascular to open repairs, no deaths occurred as a result of such procedures in our series.

3.6 Secondary reinterventions

A variety of problems after endograft repair were identified at various intervals during clinical and radiologic postimplant follow-up surveillance. These included persistent primary endoleaks, late secondary leaks, instances of graft migration, kinking, or thrombosis, and other problems that were believed to threaten endoluminal repair and expose the patient to possible conversion or rupture or both. For this reason, reinterventions were believed necessary.

During the 12-year study period, 81 patients (10%) needed a total of 109 secondary procedures. The vast majority of these were catheter-based reinterventions, including percutaneous angioplasty, pharmacologic lysis of limb thrombosis, insertion of additional vascular stents in native vessels, proximal or distal extensions of the original stent graft device, embolization of branch vessels or the AAA sac itself, or similar related procedures. These were judged clinically effective in correcting or eliminating the problem needing reintervention in 94% (n=76) of the 81 patients. Patients who underwent such success reinterventions were not classified as having clinical failures but rather as having assisted-primary successes.

4. Discussion

This series summarizes the data from our 12-year experience with 807 patients with AAAs treated with endoluminal stent graft repair.

Our results confirm an extensive number of reports from other centers that clearly document that endovascular AAA repair is safe and can be successfully performed in patients with suitable anatomy (Blum et al., 1997; Brewster et al., 1998; Brewster et al., 2003; Dillavou et al., 2006; May et al., 1998; Moore et al., 1999; Moore et al., 2001; Zarins et al., 1999).

The implant success in most centers, as in our series, is now approaching 99%. This and other outcome parameters are likely to further improve with newer generation devices, namely as such devices involve lower profile technology and the bulk of our complications stemmed from access challenges. In addition to low mortality and only a 1% early conversion rate, our results document quite effective treatment of the AAA relative to its

anticipated natural history, albeit with a relatively short 2.5-year mean follow-up period. The AAA has remained stable in size or actually diminished in maximal diameter in 92% of cases, and serious late problems, such as conversion to open repair and AAA rupture, remain infrequent.

The mortality rate of our series was 1%. The less invasive characteristics of endoluminal repair are clearly reflected by this as well as the low morbidity and mortality rates reported in the aforementioned series. Although this rate is not significantly different from results from several high-volume single institution reports involving traditional open repair, we believe many of the patients in our series who underwent endoluminal repair were frail, high-risk patients, often with advanced cardiopulmonary problems or other comorbidities, who would very likely have had considerably higher mortality rates if treated with conventional open operation.

This contention remains unproven, of course, because no truly randomized prospective studies exist in this regard. It is worthwhile emphasizing that most of the deaths in our series occurred after procedural challenges during the endovascular stent access, introduction or deployment. These difficulties invariably occurred in elderly, fragile patients with adverse and challenging anatomic features. We believe this underscores the need for careful patient selection and adherence to accepted anatomic selection criteria.

The presence of endoleaks, defined as a failure to totally exclude the AAA from continued perfusion and pressurization, may be associated with the subsequent expansion of the aneurysm and possible rupture. However, the patient is unaware of an endoleak and not really concerned unless an undesirable outcome results. Thus, endoleaks remain a potential concern, but we have not regarded these as a mode of clinical failure unless adverse sequelae, such as continued AAA enlargement, AAA rupture, or other problems, resulted. This position may be challenged by some who believe that any demonstrated endoleak is a criteria of failure. Indeed, the clinical significance of endoleak remains uncertain and poorly understood (Chuter et al., 2001; Makaroun et al., 1999; Matsumura & Moore, 1998; Steinmetz et al., 2004; Timaran et al., 2005).

Two factors indendently favored an increased incidence of endoleak in our series: advanced age and female gender. Increasing age may be associated with more complex anatomy, although none of the anatomic variables investigated were found to be predictive of endoleaks. The higher incidence of endoleak associated with female gender may be related to as yet undetermined factors, intrinsic to the aneurysm, to the vessel wall, or to the blood. In addition, the coagulation profile, on which we have no information in this study, may be a significant factor, especially with respect to type 2 endoleaks. Importantly, many authorities believe the most common variety of endoleak (type 2 retrograde branch leak) rarely causes clinical consequences, and several studies have shown poor correlation between endoleak and outcome. (Baum et al., 2002; Gilling-Smith et al., 2000; Jones et al., 2007; Resch et al., 1998; Velazquez et al., 2000; Zarins et al., 2000).

However, it should be acknowledged that almost all type III endoleaks will need some form of reintervention or conversion and that type I attachment leaks are well recognized as more hazardous in terms of AAA enlargement and rupture risk. Further, it should be noted that, in our series, all patients with AAA sac growth resulting in conversion to open repair did have some type of endoleak, including one patient with a type II branch leak alone, which was visualized at open repair. Our conclusion, that endoleak is not a desirable or benign phenomenon seems justified, but we do not regard its presence alone as reliable prognostic predictor or a clear-cut indicator of clinical failure of endoluminal repair.

Similarly, in our opinion, an indicator of clinical failure of endoluminal AAA repair should not be the need for limited secondary reinterventions on this patient population. As illustrated by our series in which a relatively modest 10% of patients needed secondary procedures, almost all catheter-based endovascular interventions rather than surgical procedures, the vast majority were believed clinically successful in correcting the presumed cause of sac growth or other clinical problems, thereby maintaining the integrity and success of the endograft repair. Similar success rates have been reported by other investigators with respect to secondary interventions (Dattilo et al., 2002; Giles et al., 2011; Hobo et al., 2006; Laheij et al., 2000; May et al., 2000).

As long as successful endovascular treatment of their aneurysm can be maintained and major surgical repair avoided, we believe the concept of primary-assisted success, achieved by means of such limited re-interventions, is valid and well accepted by patients.

Although our re-intervention rate was a 10%, our relatively short mean follow-up period of 33 months must be recognized. In the large European collaborative registry (Eurostar) experience of more than 1000 patients followed for 12 or more months, 18% have needed secondary interventions at a mean follow-up interval of 20 months (Laheij et al., 2000). It appears reasonable to assume that secondary interventions will be necessary within this patient population at a cumulative rate of approximately 10-20% per year. Similar Eurostar data have emphasized the ongoing and cumulative incidence of both late conversions and aneurysm rupture, noting cumulative rates of approximately 2%/year for conversion to open repair and a rupture risk of approximately 1%/year (Harris et al., 2000).

Application of this procedure has increased rapidly in many centers around the world, and many investigators now urge more widespread use. The less invasive nature of this approach, and the generally good and beneficial early results of treatment, clearly have made endovascular AAA repair an appealing, if not compelling, therapeutic alternative to many patients with AAA. Some regard it as the procedure of choice for all AAAs that are anatomically suitable and believe it is reasonable to use even in young patients at good risk. Other advocates urge prophylactic repair of small (5 cm) AAA, with the belief that the safer and less invasive treatment would justify earlier treatment and potentially improve long-term outcomes (Becquemin et al., 2000; Holzenbein et al., 2001; Ouriel et al., 2003; Peppelenbosch et al., 2004; Zarins et al., 2006).

Thoughtful concern in this regard should be considered, given that long-term effectiveness and durability of endovascular repair clearly appears to be less than that anticipated by most surgeons after standard open operative repair. This is supported by our results, as well as the mid-term results reported by other investigators. (Bush et al., 2001; Buth & Laheij, 2000; Chaikof et al., 2009; Crawford et al., 1981; Hallett et al., 1997; Johnston, 1994).

Although it must be acknowledged that conventional surgical repair is rarely subjected to the intense scrutiny and post-implant surveillance common to endovascular repair, nonetheless long-term effectiveness of endograft repair as we now know cannot match the late outcome and reliability of standard AAA operative repair, based on the finding of the aforementioned investigators.

Theoretically, newer-generation, lower profile devices may improve endoluminal outcomes. Further, future device advances and improvements may reduce device structural failures and may enable the endoluminal grafts to better accommodate to morphologic AAA sac changes that have been recognized by many authorities and that contribute to late failures by causing endograft kinking, migration, component separation, and other adverse consequences. However, this remains to be established. Most series to date, including this

report, are dominated by results of earlier, first-generation endografts. (Beebe et al., 2001; Chaikof et al., 2009; Harris et al., 1999; Rutherford & Krupski, 2004).

We believe the clinical implications of our study are several. First, endoluminal AAA repair has clearly been a major advance in the treatment of aortic aneurismal disease. Its safety, efficacy, feasibility and generally good early and mid-term results have been well shown in our series and many other published reports. It appears particularly advantageous to more elderly patients at high risk and patients with hostile abdominal characteristics, many of whom may have previously been denied repair. In such patients with suitable vascular anatomy for delivery and deployment, it is reasonable and appropriate in our opinion to consider endovascular repair the procedure of choice (Brewster, 2001; Dattilo et al., 2002; Visser et al., 2006).

However, it should be recognized that the actual definition of “high-risk” remains debatable and not well defined in the literature. Further, endoluminal repair seems advantageous in patients with a “hostile” abdomen because of a variety of factors and also an appealing and likely beneficial option in patients with other unusual conditions that may cause technical difficulties and challenges for conventional open repair, such as para-anastomotic aneurysms after previous aortic surgery, AAA in the presence of a horseshoe kidney, and AAA in patients with prior renal transplants.

Secondly, because of current concerns related to device structural stability and long-term reliability of this form of repair, in our opinion, more widespread use of endografts to repair small AAA cannot be supported (Finlayson et al., 1999).

Similarly, because failure modes of endoluminal repair such as endoleak, graft migration, and other are much more frequent in patients with adverse anatomy, this procedure should not be used in a wonton fashion in patients who do not have well-defined appropriate aneurysmal anatomic features for potential rupture. This is particularly true in patients at very high risk because the need for conversion in these circumstances is likely to be associated with truly excessive morbidity and mortality rates (Cuypers et al., 2000; Goodney et al., 2010; May et al., 1997; Starnes et al., 2006).

5. Conclusion

Despite the minimal invasive nature of endovascular aneurysm repair, a variety of complications do occur with considerable frequency. The patient’s age, anatomy, and cardiac and general medical status have a compelling influence on the risk of morbidity and mortality. The experience of the operating team is an important factor influencing the risk of device-related or procedure-related adverse events. These findings underline the importance of adequate training and may help to guide the selection of patients and devices for endovascular AAA repair in the future. One cannot overemphasize the importance of proper and appropriate patient selection to ensure procedural success.

6. Acknowledgment

Thanks to John O. Elliott for editorial assistance.

7. References

Baum, R. A., Carpenter, J. P., Golden, M. A., Velazquez, O. C., Clark, T. W., Stavropoulos, S. W., et al. (2002). Treatment of type 2 endoleaks after endovascular repair of

- abdominal aortic aneurysms: Comparison of transarterial and translumbar techniques. *Journal of Vascular Surgery*, Vol. 35, No.1, pp. 23-29, ISSN 0741-5214
- Becquemin, J., Bourriez, A., D'Audiffret, A., Zubilewicz, T., Kobeiter, H., Allaire, E., et al. (2000). Mid-term results of endovascular versus open repair for abdominal aortic aneurysm in patients anatomically suitable for endovascular repair. *European Journal of Vascular and Endovascular Surgery*, Vol.19, No.6, pp. 656-661, ISSN 1078-5884
- Beebe, H. G., Cronenwett, J. L., Katzen, B. T., Brewster, D. C., Green, R. M., & Vanguard Endograft Trial Investigators. (2001). Results of an aortic endograft trial: Impact of device failure beyond 12 months. *Journal of Vascular Surgery*, Vol.33, No.2 (Suppl), pp. S55-63, ISSN 0741-5214
- Blum, U., Voshage, G., Lammer, J., Beyersdorf, F., Tollner, D., Kretschmer, G., et al. (1997). Endoluminal stent-grafts for infrarenal abdominal aortic aneurysms. *The New England Journal of Medicine*, Vol.336, No.1, pp. 13-20, ISSN 0028-4793
- Brewster, D. C. (2001). Presidential address: What would you do if it were your father? Reflections on endovascular abdominal aortic aneurysm repair. *Journal of Vascular Surgery*, Vol.33, No.6, pp. 1139-1147, ISSN 0741-5214
- Brewster, D. C., Cronenwett, J. L., Hallett, J. W., Jr, Johnston, K. W., Krupski, W. C., Matsumura, J. S., et al. (2003). Guidelines for the treatment of abdominal aortic aneurysms. Report of a subcommittee of the joint council of the American association for vascular surgery and society for vascular surgery. *Journal of Vascular Surgery*, Vol.37, No.5, pp. 1106-1117, ISSN 0741-5214
- Brewster, D. C., Geller, S. C., Kaufman, J. A., Cambria, R. P., Gertler, J. P., LaMuraglia, G. M., et al. (1998). Initial experience with endovascular aneurysm repair: Comparison of early results with outcome of conventional open repair. *Journal of Vascular Surgery*, Vol.27, No.6, pp. 992-1003; discussion pp. 1004-1005, ISSN 0741-5214
- Bush, R. L., Lumsden, A. B., Dodson, T. F., Salam, A. A., Weiss, V. J., Smith, R. B., 3rd, et al. (2001). Mid-term results after endovascular repair of the abdominal aortic aneurysm. *Journal of Vascular Surgery*, Vol.33, No.2 (Suppl), pp. S70-76, ISSN 0741-5214
- Buth, J., & Laheij, R. J. (2000). Early complications and endoleaks after endovascular abdominal aortic aneurysm repair: Report of a multicenter study. *Journal of Vascular Surgery*, Vol.31, No.1 (Pt 1), pp. 134-146, ISSN 0741-5214
- Chaikof, E. L., Blankensteijn, J. D., Harris, P. L., White, G. H., Zarins, C. K., Bernhard, V. M., et al. (2002). Reporting standards for endovascular aortic aneurysm repair. *Journal of Vascular Surgery*, Vol.35, No.5, pp. 1048-1060, ISSN 0741-5214
- Chaikof, E. L., Brewster, D. C., Dalman, R. L., Makaroun, M. S., Illig, K. A., Sicard, G. A., et al. (2009). The care of patients with an abdominal aortic aneurysm: The society for vascular surgery practice guidelines. *Journal of Vascular Surgery*, Vol.50, No.4 (Suppl), pp. S2-49, ISSN 0741-5214
- Chuter, T. A., Faruqi, R. M., Sawhney, R., Reilly, L. M., Kerlan, R. B., Canto, C. J., et al. (2001). Endoleak after endovascular repair of abdominal aortic aneurysm. *Journal of Vascular Surgery*, Vol.34, No.1, pp. 98-105, ISSN 0741-5214
- Crawford, E. S., Saleh, S. A., Babb, J. W., 3rd, Glaeser, D. H., Vaccaro, P. S., & Silvers, A. (1981). Infrarenal abdominal aortic aneurysm: Factors influencing survival after

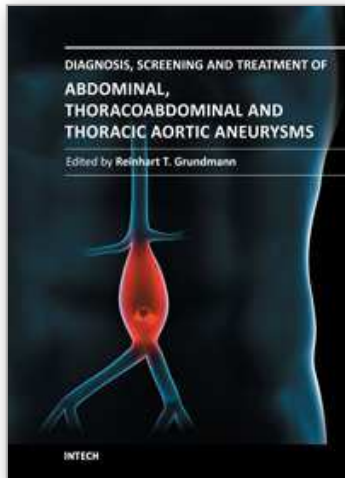
- operation performed over a 25-year period. *Annals of Surgery*, Vol.193, No.6, pp. 699-709, ISSN 0003-4932
- Cuypers, P. W., Laheij, R. J., & Buth, J. (2000). Which factors increase the risk of conversion to open surgery following endovascular abdominal aortic aneurysm repair? The EUROSTAR collaborators. *European Journal of Vascular and Endovascular Surgery*, Vol.20, No.2, pp. 183-189, ISSN 1078-5884
- Dattilo, J. B., Brewster, D. C., Fan, C. M., Geller, S. C., Cambria, R. P., Lamuraglia, G. M., et al. (2002). Clinical failures of endovascular abdominal aortic aneurysm repair: Incidence, causes, and management. *Journal of Vascular Surgery*, Vol.35, No.6, pp. 1137-1144, ISSN 0741-5214
- Dillavou, E. D., Muluk, S. C., & Makaroun, M. S. (2006). Improving aneurysm-related outcomes: Nationwide benefits of endovascular repair. *Journal of Vascular Surgery*, Vol.43, No.3, pp. 446-452, ISSN 0741-5214
- Finlayson, S. R., Birkmeyer, J. D., Fillinger, M. F., & Cronenwett, J. L. (1999). Should endovascular surgery lower the threshold for repair of abdominal aortic aneurysms? *Journal of Vascular Surgery*, Vol.29, No.6, pp. 973-985, ISSN 0741-5214
- Giles, K. A., Landon, B. E., Cotterill, P., O'Malley, A. J., Pomposelli, F. B., & Schermerhorn, M. L. (2011). Thirty-day mortality and late survival with reinterventions and readmissions after open and endovascular aortic aneurysm repair in Medicare beneficiaries. *Journal of Vascular Surgery*, Vol.53, No.1, pp.6-13, ISSN 0741-5214
- Gilling-Smith, G. L., Martin, J., Sudhindran, S., Gould, D. A., McWilliams, R. G., Bakran, A., et al. (2000). Freedom from endoleak after endovascular aneurysm repair does not equal treatment success. *European Journal of Vascular and Endovascular Surgery*, Vol.19, No.4, pp. 421-425, ISSN 1078-5884
- Goodney, P. P., Tavis, D., Lucas, F. L., Gross, T., Fisher, E. S., & Finlayson, S. R. (2010). Causes of late mortality after endovascular and open surgical repair of infrarenal abdominal aortic aneurysms. *Journal of Vascular Surgery*, Vol.51, No.6, pp. 1340-1347, ISSN 0741-5214
- Halak, M., McDonnell, C. O., Muhlmann, M. D., & Baker, S. R. (2007). Open surgical treatment of aneurysmal sac expansion following endovascular abdominal aneurysm repair: Solution for an unresolved clinical dilemma. *Vascular*, Vol.15, No.4, pp. 201-204, ISSN 1708-5381
- Hallett, J. W., Jr, Marshall, D. M., Petterson, T. M., Gray, D. T., Bower, T. C., Cherry, K. J., Jr, et al. (1997). Graft-related complications after abdominal aortic aneurysm repair: Reassurance from a 36-year population-based experience. *Journal of Vascular Surgery*, Vol.25, No.2, pp.277-84; discussion pp. 285-286, ISSN 0741-5214
- Harris, P., Brennan, J., Martin, J., Gould, D., Bakran, A., Gilling-Smith, G., et al. (1999). Longitudinal aneurysm shrinkage following endovascular aortic aneurysm repair: A source of intermediate and late complications. *Journal of Endovascular Surgery*, Vol.6 No.1, pp. 11-16, ISSN 1074-6218
- Harris, P. L., Vallabhaneni, S. R., Desgranges, P., Becquemin, J. P., van Marrewijk, C., & Laheij, R. J. (2000). Incidence and risk factors of late rupture, conversion, and death after endovascular repair of infrarenal aortic aneurysms: The EUROSTAR experience. European collaborators on Stent/graft techniques for aortic aneurysm repair. *Journal of Vascular Surgery*, Vol.32, No.4, pp. 739-749, ISSN 0741-5214

- Hobo, R., Buth, J., & EUROSTAR collaborators. (2006). Secondary interventions following endovascular abdominal aortic aneurysm repair using current endografts. A EUROSTAR report. *Journal of Vascular Surgery*, Vol.43, No.5, pp. 896-902, ISSN 0741-5214
- Holzenbein, T. J., Kretschmer, G., Thurnher, S., Schoder, M., Aslim, E., Lammer, J., et al. (2001). Midterm durability of abdominal aortic aneurysm endograft repair: A word of caution. *Journal of Vascular Surgery*, Vol.33, No.2 (Suppl), pp. S46-54, ISSN 0741-5214
- Johnston, K. W. (1994). Nonruptured abdominal aortic aneurysm: Six-year follow-up results from the multicenter prospective Canadian aneurysm study. Canadian society for vascular surgery aneurysm study group. *Journal of Vascular Surgery*, Vol.20, No.2, pp. 163-170, ISSN 0741-5214
- Jones, J. E., Atkins, M. D., Brewster, D. C., Chung, T. K., Kwolek, C. J., LaMuraglia, G. M., et al. (2007). Persistent type 2 endoleak after endovascular repair of abdominal aortic aneurysm is associated with adverse late outcomes. *Journal of Vascular Surgery*, Vol.46, No.1, pp. 1-8, ISSN 0741-5214
- Laheij, R. J., Buth, J., Harris, P. L., Moll, F. L., Stelter, W. J., & Verhoeven, E. L. (2000). Need for secondary interventions after endovascular repair of abdominal aortic aneurysms. intermediate-term follow-up results of a European collaborative registry (EUROSTAR). *The British Journal of Surgery*, Vol.87, No.12, pp. 1666-1673, ISSN 0007-1323
- Makaroun, M., Zajko, A., Sugimoto, H., Eskandari, M., & Webster, M. (1999). Fate of endoleaks after endoluminal repair of abdominal aortic aneurysms with the EVT device. *European Journal of Vascular and Endovascular Surgery*, Vol.18, No.3, pp. 185-190, ISSN 1078-5884
- Matsumura, J. S., & Moore, W. S. (1998). Clinical consequences of periprosthetic leak after endovascular repair of abdominal aortic aneurysm. endovascular technologies investigators. *Journal of Vascular Surgery*, Vol.27, No.4, pp. 606-613, ISSN 0741-5214
- May, J., White, G. H., Waugh, R., Petrusek, P., Chaufour, X., Arulchelvam, M., et al. (2000). Life-table analysis of primary and assisted success following endoluminal repair of abdominal aortic aneurysms: The role of supplementary endovascular intervention in improving outcome. *European Journal of Vascular and Endovascular Surgery*, Vol.19, No.6, pp. 648-655, ISSN 1078-5884
- May, J., White, G. H., Yu, W., Ly, C. N., Waugh, R., Stephen, M. S., et al. (1998). Concurrent comparison of endoluminal versus open repair in the treatment of abdominal aortic aneurysms: Analysis of 303 patients by life table method. *Journal of Vascular Surgery*, Vol.27, No.2, pp. 213-221, ISSN 0741-5214
- May, J., White, G. H., Yu, W., Waugh, R., Stephen, M., Sieunarine, K., et al. (1997). Conversion from endoluminal to open repair of abdominal aortic aneurysms: A hazardous procedure. *European Journal of Vascular and Endovascular Surgery*, Vol.14, No.1, pp. 4-11, ISSN 1078-5884
- Moore, W. S., Brewster, D. C., & Bernhard, V. M. (2001). Aorto-uni-iliac endograft for complex aortoiliac aneurysms compared with tube/bifurcation endografts: Results of the EVT/Guidant trials. *Journal of Vascular Surgery*, Vol.33, No.2 (Suppl), pp. S11-20, ISSN 0741-5214

- Moore, W. S., Kashyap, V. S., Vescera, C. L., & Quinones-Baldrich, W. J. (1999). Abdominal aortic aneurysm: A 6-year comparison of endovascular versus transabdominal repair. *Annals of Surgery*, Vol.230, No.3, pp. 298-308, ISSN 0003-4932
- Ouriel, K., Srivastava, S. D., Sarac, T. P., O'hara, P. J., Lyden, S. P., Greenberg, R. K., et al. (2003). Disparate outcome after endovascular treatment of small versus large abdominal aortic aneurysm. *Journal of Vascular Surgery*, Vol.37, No.6, pp. 1206-1212, ISSN 0741-5214
- Peppelenbosch, N., Buth, J., Harris, P. L., van Marrewijk, C., Fransen, G., & EUROSTAR Collaborators. (2004). Diameter of abdominal aortic aneurysm and outcome of endovascular aneurysm repair: Does size matter? A report from EUROSTAR. *Journal of Vascular Surgery*, Vol.39, No.2, pp. 288-297, ISSN 0741-5214
- Resch, T., Ivancev, K., Lindh, M., Nyman, U., Brunkwall, J., Malina, M., et al. (1998). Persistent collateral perfusion of abdominal aortic aneurysm after endovascular repair does not lead to progressive change in aneurysm diameter. *Journal of Vascular Surgery*, Vol.28, No.2, pp. 242-249, ISSN 0741-5214
- Rutherford, R. B., & Krupski, W. C. (2004). Current status of open versus endovascular stent-graft repair of abdominal aortic aneurysm. *Journal of Vascular Surgery*, Vol.39, No.5, pp. 1129-1139, ISSN 0741-5214
- Sampaio, S. M., Shin, S. H., Panneton, J. M., Andrews, J. C., Bower, T. C., Cherry, K. J., et al. (2009). Intraoperative endoleak during EVAR: Frequency, nature, and significance. *Vascular and Endovascular Surgery*, Vol.43, No.4, pp. 352-359, ISSN 1538-5744
- Starnes, B. W., Andersen, C. A., Ronsivalle, J. A., Stockmaster, N. R., Mullenix, P. S., & Statler, J. D. (2006). Totally percutaneous aortic aneurysm repair: Experience and prudence. *Journal of Vascular Surgery*, Vol.43, No.2, pp. 270-276, ISSN 0741-5214
- Steinmetz, E., Abello, N., Kretz, B., Gauthier, E., Bouchot, O., & Brenot, R. (2010). Analysis of outcome after using high-risk criteria selection to surgery versus endovascular repair in the modern era of abdominal aortic aneurysm treatment. *European Journal of Vascular and Endovascular Surgery*, Vol.39, No.4, pp. 403-409, ISSN 1078-5884
- Steinmetz, E., Rubin, B. G., Sanchez, L. A., Choi, E. T., Geraghty, P. J., Baty, J., et al. (2004). Type II endoleak after endovascular abdominal aortic aneurysm repair: A conservative approach with selective intervention is safe and cost-effective. *Journal of Vascular Surgery*, Vol.39, No.2, pp. 306-313, ISSN 0741-5214
- Timaran, C. H., Ohki, T., Veith, F. J., Lipsitz, E. C., Gargiulo, N. J., 3rd, Rhee, S. J., et al. (2005). Influence of type II endoleak volume on aneurysm wall pressure and distribution in an experimental model. *Journal of Vascular Surgery*, Vol.41, No.4, pp. 657-663, ISSN 0741-5214
- Velazquez, O. C., Baum, R. A., Carpenter, J. P., Golden, M. A., Cohn, M., Pyeron, A., et al. (2000). Relationship between preoperative patency of the inferior mesenteric artery and subsequent occurrence of type II endoleak in patients undergoing endovascular repair of abdominal aortic aneurysms. *Journal of Vascular Surgery*, Vol.32, No.4, pp. 777-788, ISSN 0741-5214
- Visser, J. J., Bosch, J. L., Hunink, M. G., van Dijk, L. C., Hendriks, J. M., Poldermans, D., et al. (2006). Endovascular repair versus open surgery in patients with ruptured abdominal aortic aneurysms: Clinical outcomes with 1-year follow-up. *Journal of Vascular Surgery*, Vol.44, No.6, pp. 1148-1155, ISSN 0741-5214

- Zarins, C. K., Crabtree, T., Bloch, D. A., Arko, F. R., Ouriel, K., & White, R. A. (2006). Endovascular aneurysm repair at 5 years: Does aneurysm diameter predict outcome? *Journal of Vascular Surgery*, Vol.44, No.5, pp. 920-931, ISSN 0741-5214
- Zarins, C. K., White, R. A., Hodgson, K. J., Swarten, D., & Fogarty, T. J. (2000). Endoleak as a predictor of outcome after endovascular aneurysm repair: AneuRx multicenter clinical trial. *Journal of Vascular Surgery*, Vol.32, No.1, pp. 90-107, ISSN 0741-5214
- Zarins, C. K., White, R. A., Swarten, D., Kinney, E., Diethrich, E. B., Hodgson, K. J., et al. (1999). AneuRx stent graft versus open surgical repair of abdominal aortic aneurysms: Multicenter prospective clinical trial. *Journal of Vascular Surgery*, Vol.29, No.2, pp. 292-305; discussion pp. 306-308, ISSN 0741-5214
- Zeebregts, C. J., Geelkerken, R. H., van der Palen, J., Huisman, A. B., de Smit, P., & van Det, R. J. (2004). Outcome of abdominal aortic aneurysm repair in the era of endovascular treatment. *The British Journal of Surgery*, Vol.91 No.5, pp. 563-568, ISSN 0741-5214

IntechOpen



Diagnosis, Screening and Treatment of Abdominal, Thoracoabdominal and Thoracic Aneurysms

Edited by Prof. Reinhart Grundmann

ISBN 978-953-307-466-5

Hard cover, 414 pages

Publisher InTech

Published online 12, September, 2011

Published in print edition September, 2011

This book considers mainly diagnosis, screening, surveillance and treatment of abdominal, thoracoabdominal and thoracic aortic aneurysms. It addresses vascular and cardiothoracic surgeons and interventional radiologists, but also anyone engaged in vascular medicine. The high mortality of ruptured aneurysms certainly favors the recommendation of prophylactic repair of asymptomatic aortic aneurysms (AA) and therewith a generous screening. However, the comorbidities of these patients and their age have to be kept in mind if the efficacy and cost effectiveness of screening and prophylactic surgery should not be overestimated. The treatment recommendations which will be outlined here, have to regard on the one hand the natural course of the disease, the risk of rupture, and the life expectancy of the patient, and on the other hand the morbidity and mortality of the prophylactic surgical intervention. The book describes perioperative mortality after endovascular and open repair of AA, long-term outcome after repair, and the cost-effectiveness of treatment.

How to reference

In order to correctly reference this scholarly work, feel free to copy and paste the following:

Daniel R. Watson, Angela Kruse, Jeffrey Weiner and Christina Prabhu (2011). Incidence and Predictors of Clinical Failures Following Catheter-Based Treatment of Abdominal Aortic Aneurysms, Diagnosis, Screening and Treatment of Abdominal, Thoracoabdominal and Thoracic Aortic Aneurysms, Prof. Reinhart Grundmann (Ed.), ISBN: 978-953-307-466-5, InTech, Available from: <http://www.intechopen.com/books/diagnosis-screening-and-treatment-of-abdominal-thoracoabdominal-and-thoracic-aortic-aneurysms/incidence-and-predictors-of-clinical-failures-following-catheter-based-treatment-of-abdominal-aortic>

INTECH
open science | open minds

InTech Europe

University Campus STeP Ri
Slavka Krautzeka 83/A
51000 Rijeka, Croatia
Phone: +385 (51) 770 447
Fax: +385 (51) 686 166
www.intechopen.com

InTech China

Unit 405, Office Block, Hotel Equatorial Shanghai
No.65, Yan An Road (West), Shanghai, 200040, China
中国上海市延安西路65号上海国际贵都大饭店办公楼405单元
Phone: +86-21-62489820
Fax: +86-21-62489821

© 2011 The Author(s). Licensee IntechOpen. This chapter is distributed under the terms of the [Creative Commons Attribution-NonCommercial-ShareAlike-3.0 License](https://creativecommons.org/licenses/by-nc-sa/3.0/), which permits use, distribution and reproduction for non-commercial purposes, provided the original is properly cited and derivative works building on this content are distributed under the same license.

IntechOpen

IntechOpen