

# We are IntechOpen, the world's leading publisher of Open Access books Built by scientists, for scientists

6,900

Open access books available

186,000

International authors and editors

200M

Downloads

Our authors are among the

154

Countries delivered to

TOP 1%

most cited scientists

12.2%

Contributors from top 500 universities



WEB OF SCIENCE™

Selection of our books indexed in the Book Citation Index  
in Web of Science™ Core Collection (BKCI)

Interested in publishing with us?  
Contact [book.department@intechopen.com](mailto:book.department@intechopen.com)

Numbers displayed above are based on latest data collected.  
For more information visit [www.intechopen.com](http://www.intechopen.com)



## Types and Subtypes of the Posterior Part of the Cerebral arterial Circle in Human Adult Cadavers

Ljiljana Vasović<sup>1</sup>, Milena Trandafilović<sup>2</sup>, Ivan Jovanović<sup>1</sup>,  
Slađana Ugrenović<sup>1</sup>, Slobodan Vlajković<sup>1</sup> and Jovan Stojanović<sup>3</sup>

*University of Niš,*

*<sup>1-3</sup>Faculty of Medicine,*

*<sup>1</sup>Department of Anatomy,*

*<sup>3</sup>Institute of Forensic Medicine*

*Serbia*

### 1. Introduction

The main cerebral distribution center of 15-20% blood flow from the cardiac output is the cerebral arterial circle or circle of Willis, a nonagon of collateral vessels on the human brain base.

At about 4 mm stage of the embryo, the primitive internal carotid arteries, which develop as cranial extensions of the paired dorsal aorta, are formed. Paired longitudinal neural arteries appear along the hindbrain and coalesce to form the basilar trunk at the 7- to 12-mm stage. The caudal division of the primitive internal carotid artery anastomoses with ipsilateral neural artery and becomes the posterior communicating artery. At the 40-mm stage the posterior cerebral arteries are as extensions of the posterior communicating arteries. The vertebrobasilar system develops and thus participates in the supply of the posterior cerebral artery through the segment between the basilar artery and the post-communicating part of the posterior cerebral artery. In that phase, the component vessels of the circle of Willis all have the same caliber (Silver & Wilkins, 1991).

The posterior cerebral artery originates from the basilar bifurcation within the interpeduncular cistern. From its origin the artery curves superior to the corresponding oculomotor nerve in relation to the antero-medial portion of the cerebral peduncle and joins ipsilateral posterior communicating artery (Yasargil, 1984).

The posterior communicating artery takes origin from the infero-lateral wall of the cerebral part of the internal carotid artery. It is encased in a sleeve of arachnoid along the course from the carotid cistern to the piercing of the interpeduncular cistern and junction with posterior cerebral artery (Yasargil, 1984).

Topographically, the circle of Willis is divided on anterior and posterior parts. The anterior part composes five vascular components – bilateral cerebral parts of internal carotid arteries (communicating and choroid subparts) and the pre-communicating part of anterior cerebral arteries interconnected by the anterior communicating artery; the posterior part composes

four vascular components. As a rule, the posterior part of the circle of Willis is normal as it is formed with posterior communicating artery and the pre-communicating part of the posterior cerebral artery on both sides, where the left and right pre-communicating parts of the posterior cerebral arteries have normal calibres which are larger in relation to posterior communicating arteries, as well as that posterior communicating arteries are not hypoplastic (Saeki & Rhoton, 1977). In the fetal period, the posterior circle part develops into one of three variants: an adult configuration, a transitional configuration or a fetal configuration (Silver & Wilkins, 1991).

It has been assumed that the arrangement of the arteries at the base of the brain is symmetrical and that the architecture of the circle of Willis provides a structural basis for free anastomotic flow (Riggs & Rupp, 1963). The collateral potential of the circle of Willis is believed to be dependent with the presence and size of its component vessels, which vary among normal individuals. The anterior communicating artery and posterior communicating arteries are designated as primary collateral pathways (Hartkamp et al., 1999). The integrity of the circle of Willis may be critical because anomalies and hypoplasia of the circle of Willis are frequent (Merkkola et al., 2006). Anomalies found in a pattern of the posterior part of the circle of Willis result due to persistence of vessels that normally disappear or disappearance of normal vessels (Vasović, 2004; Kapoor et al., 2008; Vasović et al., 2010). Although the association of variations and aneurysms had been used as an argument in favor of a congenital theory of aneurismal development, it should be interpreted in terms of the hemodynamic stress caused by variations (Kayembe et al., 1984). However, a significantly higher percentage of complete posterior circle configurations were demonstrated on magnetic resonance angiograms in some patients rather than in the controlled subjects (Hartkamp et al., 1999). The size and patency of primary collateral pathways may be risk factors for cerebral infarction in patients with severe stenosis or occlusion of a carotid artery (Schomer et al., 1994).

The purpose of the present morphologic study is to obtain wider, more precise and more detailed information about the relationship between caliber variations in the posterior part of the circle of Willis forming different (sub) types of its posterior part, as well as to compare those results with previous literature data.

## 2. Material and methods

Examination was carried out on the brains of human adult cadavers, during the period between 2006 and 2010. Approval was granted by the Research Ethics Committee (No. 01-9068-1) of the Faculty of Medicine of Niš. All subjects had died from natural or violent death and were candidates for autopsy for medico-legal reasons in Institute of Forensic Medicine of Niš, Serbia. The brain base with blood vessels was photographed on each cadaver; the ventral side of the brainstem and diencephalon was specially zoomed. Each case was recorded as the schematic drawing in the workbook. External morphology (calibre of the arteries, possible abnormalities) was inspected using magnifying glass. We used only cases with complete Willis' circle (Figure 1). These circles originated from 110 cadavers of both sexes (62 male and 48 female) and of different ages (from 20 to 95). The numbers of cadavers in each age deciles were as follows: 2nd decade, two cadavers; 3rd decade, three cadavers; 4th decade, seven cadavers; 5th decade, 16 cadavers; 6th decade, six cadavers; 7th decade, 23 cadavers; 8th decade, 35 cadavers, 9th decade, 17 cadavers; and 10th decade, one cadaver.

Only one cadaver had cerebral infarction, while the others were on autopsy because of cardiac, respiratory, incidental and other causes of no cerebral pathology.

Measurement of the outer diameter of the pre-communicating part of the posterior cerebral artery and the posterior communicating artery of both sides, as well basilar bifurcation angle was performed using ImageJ (<http://rsb.info.nih.gov/ij/index.html>). Statistical analysis of quantitative data is performed with PASW statistical software SPSS version 15. According to Kamath (1981), values of  $\leq 0.5$  and 1.0 mm for the posterior communicating and pre-communicating part of the posterior cerebral arteries are respectively used as hypoplastic calibers.

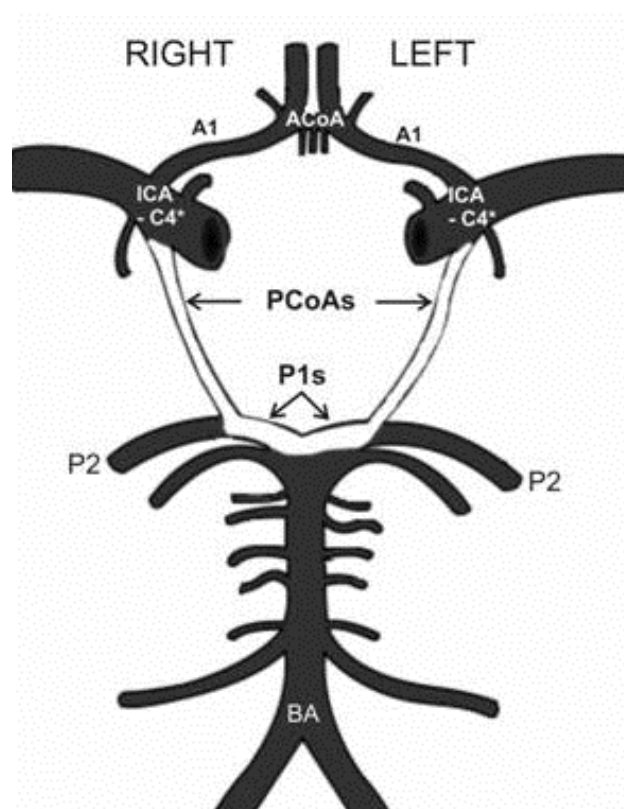


Fig. 1. Diagram of vessels of the carotid and vertebrobasilar systems. Vascular components of the circle of Willis (choroids and communicating subparts of the cerebral part of the internal carotid artery, ICA-C4\*; pre-communicating part of the anterior cerebral artery, A1; anterior communicating artery, ACoA; posterior communicating artery, PCoA; pre-communicating part of the posterior cerebral artery, P1), and some of other arteries of the vertebrobasilar system (post-communicating part of the posterior cerebral artery, P2; basilar artery, BA) are marked. Vessels (PCoAs and P1s) of the circle posterior part are white colored.

Form of types and subtypes of the posterior part of 110 circles of Willis follows their previous description in human fetuses (Vasović et al., 2008a). Bilateral fetal or FF-type is characterized with the larger diameter of the posterior communicating arteries in relation to the pre-communicating part of the posterior cerebral arteries (normal or hypoplastic); bilateral adult or AA-type is characterized with bilaterally larger diameter of the pre-communicating part of the posterior cerebral arteries in relation to the posterior

communicating arteries (normal or hypoplastic); bilateral transitory or TT-type is characterized with the same diameter (normal or hypoplastic) of the pre-communicating part of the posterior cerebral artery and the posterior communicating artery on both sides; the fetal-transitory or transitory-fetal type (FT/TF) is characterized with the same size of the posterior communicating and pre-communicating part of the posterior cerebral artery on one side and the larger posterior communicating artery in relation to the pre-communicating part of the posterior cerebral artery on the right or left side; the adult-transitory or transitory-adult type (AT/TA) is characterized with the same size of the posterior communicating artery and pre-communicating part of the posterior cerebral artery on one side and the larger pre-communicating part of the posterior cerebral artery in relation to the posterior communicating artery on the right or left side; the adult-fetal or fetal-adult type (AF/FA) is characterized with the larger diameter of the pre-communicating part of the posterior cerebral artery in relation to the posterior communicating artery and the larger diameter of the posterior communicating artery in relation to the pre-communicating part of the posterior cerebral artery on the right or left side. Subtypes with the ideal caliber relations are marked with zero in the subscript. The mark of every next subtype retains the first letters of the basic type but in the subscript contains Arabic numerals starting from number 1. To differentiate the side of the TT, FF, and AA subtypes in schemes, we emphasize that the numeral in the subscript designates right side and the numeral with the apostrophe designates left side (as the images in the mirror). To differentiate the side on FT/TF, AT/TA, and AF/FA schemes, we emphasize that the first letter in the designation marks right-sided origin, and the second marks left-sided origin of arteries. The lines of different thicknesses and broken lines on the schemes of the circle posterior part show the difference in the caliber size, independently from whether the caliber of an artery was normal and/or (slightly) hypoplastic or hyperplastic.

Macroscopic visualization of atheromatous plaques in vessels' wall of the circle of Willis is graduated according to personal proposes (grade 0 – without atheromatous changes; grade 1 - atheromatous plaques at vessels bifurcations; grade 2 - atheromatous plaques at bifurcations and up to half vessels length; grade 3 - islands or diffuse atheromatous plaques).

### 3. Results

Basic statistic analysis of calibres of the pre-communicating part of the posterior cerebral artery and posterior communicating artery on both sides in the circle of Willis of human cadavers of different ages and genders is presented in Table 1.

The least caliber of the pre-communicating parts of the right and left posterior cerebral arteries (0.89 and 0.80 mm) is found in a 75-year-old female and a 42-year-old male, while their largest caliber (3.69 and 3.60 mm) is found in 47-year-old and 80-year-old males. The least caliber of the right and left posterior communicating arteries (0.30 and 0.45 mm) is found in a 44-year-old and in a 64-year-old woman, while the largest caliber (2.86 and 3.31 mm) is found in 80-year old woman. Average values of the caliber and the standard deviations for right and left pre-communicating part of the posterior cerebral artery are 2.17 ( $\pm 0.58$ ) mm and 2.29 ( $\pm 0.48$ ) mm, as well 1.19 ( $\pm 0.54$ ) mm and 1.22 ( $\pm 0.57$ ) mm for the right and left posterior communicating artery, respectively (Table 1).



Total					
Parameter	Age	Right PCA-P1	Left PCA-P1	Right PCoA	Left PCoA
Mean	65.59	2.17	2.20	1.19	1.22
SE	1.66	0.06	0.05	0.06	0.06
Median	71	2.17	2.21	1.05	1.03
Mode	78	2.50	2.43	0.98	1.43
SD	17.62	0.58	0.48	0.54	0.57
Range	75	2.80	2.80	2.60	2.86
Minimum	20	0.89	0.80	0.30	0.45
Maximum	95	3.69	3.60	2.90	3.31
CI (95.0%)	3.28	0.12	0.10	0.11	0.12
Male					
Mean	63.12	2.26	2.22	1.22	1.23
SE	2.30	0.08	0.07	0.07	0.07
Median	70	2.24	2.28	1.16	1.06
Mode	70	2.50	2.29	1.35	1.43
SD	18.71	0.58	0.50	0.54	0.51
Range	70	2.75	2.63	2.40	2.84
Minimum	20	0.94	0.80	0.50	0.47
Maximum	90	3.69	3.43	2.90	3.31
CI (95.0%)	4.60	0.16	0.14	0.15	0.14
Female					
Mean	69.06	2.04	2.17	1.15	1.21
SE	2.26	0.09	0.08	0.09	0.11
Median	74	1.95	2.13	1.00	0.99
Mode	78	1.81	1.84	0.98	0.71
SD	15.49	0.56	0.46	0.55	0.64
Range	68	2.04	2.33	2.47	2.41
Minimum	27	0.89	1.27	0.30	0.45
Maximum	95	2.93	3.60	2.77	2.86
CI (95.0%)	4.55	0.19	0.15	0.18	0.21

Table 1. Statistical parameters of caliber values of the pre-communicating part (P1) of the posterior cerebral artery (PCA) and posterior communicating artery (PCoA) on both sides in the posterior circle part of human cadavers

We established four (two symmetric and two asymmetric) types. The incidences of types in adult specimens are as follow: 8 cases (7.27%) of the FF-type (four subtypes), 75 cases (68.18%) of the AA-type (six subtypes), 15 cases (13.63%) of the AF-type (four subtypes) and 12 cases (10.91%) of the AT-type (three subtypes). Sequences of same or special subtypes in fetal and adult specimens are compared and showed in Table 2.

FETAL CASES* - SUBTYPES -		ADULT CASES** - SUBTYPES -	
Mark	%	Mark	%
TTo	17.95		
TT1 / TT1'			
FFo	10.10	FFo	7.27
FF1 / FF1'		FF1 / FF1'	
		FF2'	
		FF4'	
AAo	32.55	AAo	68.18
AA1 / AA1'		AA1 / AA1'	
AA2 / AA2'		AA2 / AA2'	
AA3'		AA3 / AA3'	
AA4		AA4 / AA4'	
		AA5 / AA5'	
FTo / TFo	5.95		
FT2			
AFo / FAo	19.55	AFo / FAo	13.63
AF1 / FA1			
AF3 / FA3			
AF4 / FA4		FA4	
		AF5 / FA5	
FA6			
AF7		AF7	
AF8			
ATo / TAo	13.85	ATo / TAo	10.91
AT1		AT1	
AT2 / TA2			
AT3 / TA3		AT3 / TA3	

Table 2. Sequences of subtypes of the posterior part of fetal and adult circles of Willis.

Special subtypes are in gray rows;  
\*Vasović et al. (2008a);  
\*\*recent findings.

It is obvious that an incidence of bilateral adult type dominates (68.18%) and that the cases of bilateral transitory and fetal-transitory types as well some subtypes of bilateral fetal and adult types are missing; an unilateral adult configuration is associated with fetal or transitory configuration in about 25% of these adult cases; there is the least incidence (7.27) of bilateral fetal configuration in relation to other three patterns of posterior circle part (Table 2).

Distribution of cases of corresponding subtypes according to causes of death in female and male adults cadavers is showed in Table 3. A presence of atheromatous plaques in carotid and vertebrobasilar systems on the brain base is noted according to age and graduated independently from cause of death (Table 4).

Types / Subtypes		N	Myoca- rdial infarction	Cardiorespira- tory arrest	Polytrau- ma	Intoxica- tion	Singular cases of no cerebral patho- logy	Cerebral patho- logy
			(females + males)					
AA	AA <sub>0</sub>	29	3 + 0	5 + 2	2 + 5	2 + 2	3 + 4	0 + 1
	AA <sub>1</sub> /AA <sub>1'</sub>	7		0 + 1	2 + 2	0 + 1	0 + 1	
	AA <sub>2</sub> /AA <sub>2'</sub>	27	1 + 4	3 + 3	1 + 6	0 + 1	5 + 3	
	AA <sub>3</sub> /AA <sub>3'</sub>	2	0 + 1		0 + 1			
	AA <sub>4</sub> /AA <sub>4'</sub>	7	0 + 3		1 + 2		1 + 0	
	AA <sub>5</sub> /AA <sub>5'</sub>	3	1 + 0	1 + 1				
FF	FF <sub>0</sub>	3	0 + 1		1 + 0		1 + 0	
	FF <sub>1</sub> /FF <sub>1'</sub>	3		1 + 1	0 + 1			
	FF <sub>2'</sub>	1				0 + 1		
	FF <sub>4'</sub>	1		1 + 0				
AF/FA	AF <sub>0</sub> /FA <sub>0</sub>	8	1 + 3		0 + 2		2 + 0	
	FA <sub>4</sub>	1	0 + 1					
	AF <sub>5</sub> /FA <sub>5</sub>	5	1 + 0	1 + 1			2 + 0	
	AF <sub>7</sub>	1	0 + 1					
AT/TA	AT <sub>0</sub> /TA <sub>0</sub>	8	0 + 1		1 + 2	0 + 1	2 + 1	
	AT <sub>1</sub>	1				0 + 1		
	AT <sub>3</sub> /TA <sub>3</sub>	3	1 + 0	1 + 0		1 + 0		

Table 3. Sex distribution of number of cases of the posterior circle subtypes according to causes of death

Atheromatous changes (grade 1) were first visualized in a 34-years old male (AA2 subtype), as well as, in five cases (one in FF2' , two in AAo and two in AA2 subtype) of the fifth decade of life. Atheromatous changes of grades 2 and 3 were first visualized in 42-years old and 47-years old males, respectively. Incidences of atheromatous changes are as follow: Grade 1: Five (2 females and 3 males) or 62.5% of the FF-type cases; 24 (8 females and 16 males) or 32% of the AA-type cases; four (2 females and 2 males) or 26.6% of the AF/FA-type cases, and two (males) or 16.6% of the AT/TA-type cases. Grade 2: Two (female and male) or 25% of the FF-type cases; 26 (12 females and 14 males) or 34.6% of the AA-type cases; three (two females and one male) or 20% of the AF/FA-type cases, and two (males) or 16.6% of the AT/TA-type cases. Grade 3: One (male) or 12.5% of the FF-type cases; four (two females and two males) or 5.3% of the AA-type cases; four (two females and two males) or 26.6% of the AF/FA-type cases, and one (female) or 8.3% of the AT/TA-type cases. There are 21 (9 females and 12 males) or 28% of the AA-type cases from the 20th to 78th year, then four (two females and two males) or 26.6% of the AF/FA-type cases from the 28th to 54th year, and seven (two females and five males) or 58.3% of the AF/FA-type cases from the 35th to 82nd year without atheromatous changes.

Diagrams and appropriate pictures are showed at Figures 2-5. General incidences of types and/or subtypes are compared with other literature data in Table 5.



Types	Subtypes		Grade 0	Grade 1	Grade 2	Grade 3	N
FF	FF <sub>0</sub>	f		78		80	2
		m		84			1
	FF <sub>1</sub> /FF <sub>1'</sub>	f		75			1
		m		79	70		2
	FF <sub>2'</sub>	f					0
		m		41			1
	FF <sub>4'</sub>	f			79		1
		m					0
AA	AA <sub>0</sub>	f	27,34,58,67	46,72,85	68,74,75,80,95	71,87	15
		m	20, 37,45,47,50,60,75	45,52,81,83	70,86	70	14
	AA <sub>1</sub> /AA <sub>1'</sub>	f	34,43				2
		m	70	69	78,80,90		5
	AA <sub>2</sub> /AA <sub>2'</sub>	f	44,44,61	45,71,82	65,74,76,80		10
		m	23,51,78	34,43,54,61,70,79,81	68,69,72,77,78,79,82		17
	AA <sub>3</sub> /AA <sub>3'</sub>	f					0
		m		63,65			2
	AA <sub>4</sub> /AA <sub>4'</sub>	f		79	64		2
		m	20	80,84	70	85	5
	AA <sub>5</sub> /AA <sub>5'</sub>	f		64	85		2
		m			42		1
AF/FA	AF <sub>0</sub> /FA <sub>0</sub>	f	45,54			81	3
		m	28,42	80	74	82	5
	FA <sub>4</sub>	f					0
		m		89			1
	AF <sub>5</sub> /FA <sub>5</sub>	f		68,70	78	78	4
		m				47	1
	AF <sub>7</sub>	f					0
		m			74		1
AT/TA	AT <sub>0</sub> /TA <sub>0</sub>	f	82	78	72		3
		m	39,50,76,80			61	5
	AT <sub>1</sub>	f					0
		m	35				1
	AT <sub>3</sub> /TA <sub>3</sub>	f	40	73	67		3
		m					0

Table 4. Graduation of atheromatosis according to gender (female - f and male - m) and age

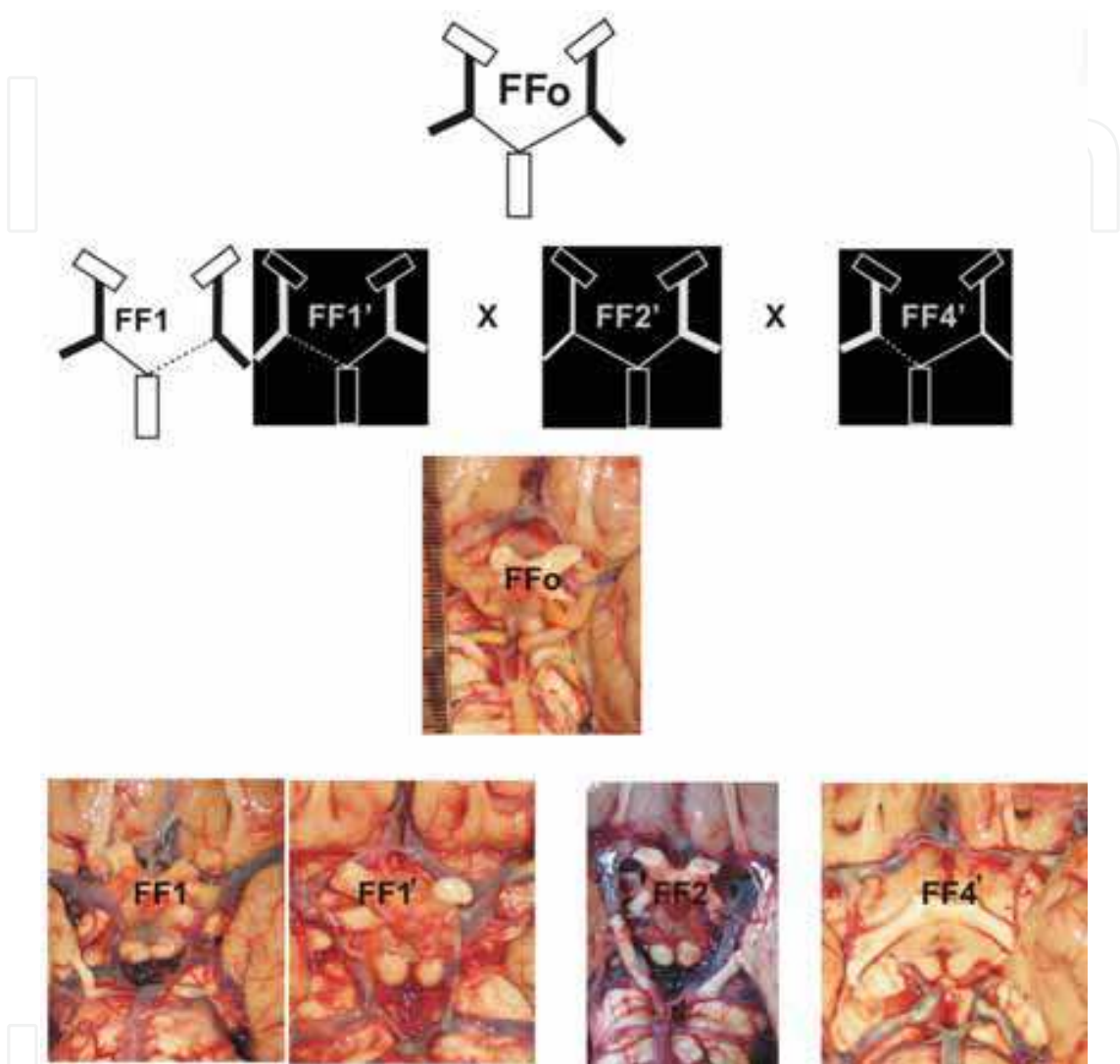


Fig. 2. Diagrams and corresponding photos of subtypes of the bilateral fetal (FF) type.

Right or left posterior communicating artery, rPCoA or lPCoA; right or left pre-communicating part of the posterior cerebral artery, rP1 or lP1.

FFo ( $rPCoA > rP1 = lP1 < lPCoA \wedge lPCoA = rPCoA$ ): 3 cases (37.5%).

FF1/FF1' ( $lP1 < rP1 < rPCoA = lPCoA$ ) or ( $rP1 < lP1 < lPCoA = rPCoA$ ): 3 cases (37.5%).

FF2' ( $lP1 = rP1 < rPCoA < lPCoA$ ): 1 case.

FF4' ( $rP1 < lP1 < lPCoA < rPCoA$ ): 1 case. Note: PCoAs are accidentally broken.

In FF-type, more frequent are the cases where calibers of paired posterior communicating arteries and pre-communicating parts of the posterior cerebral arteries are equaled, respectively with larger caliber of posterior communicating arteries (FFo-subtype), as well as the cases with same relationship of posterior communicating arteries and caliber difference of pre-communicating parts of the posterior cerebral arteries (FF1/FF1' subtype).

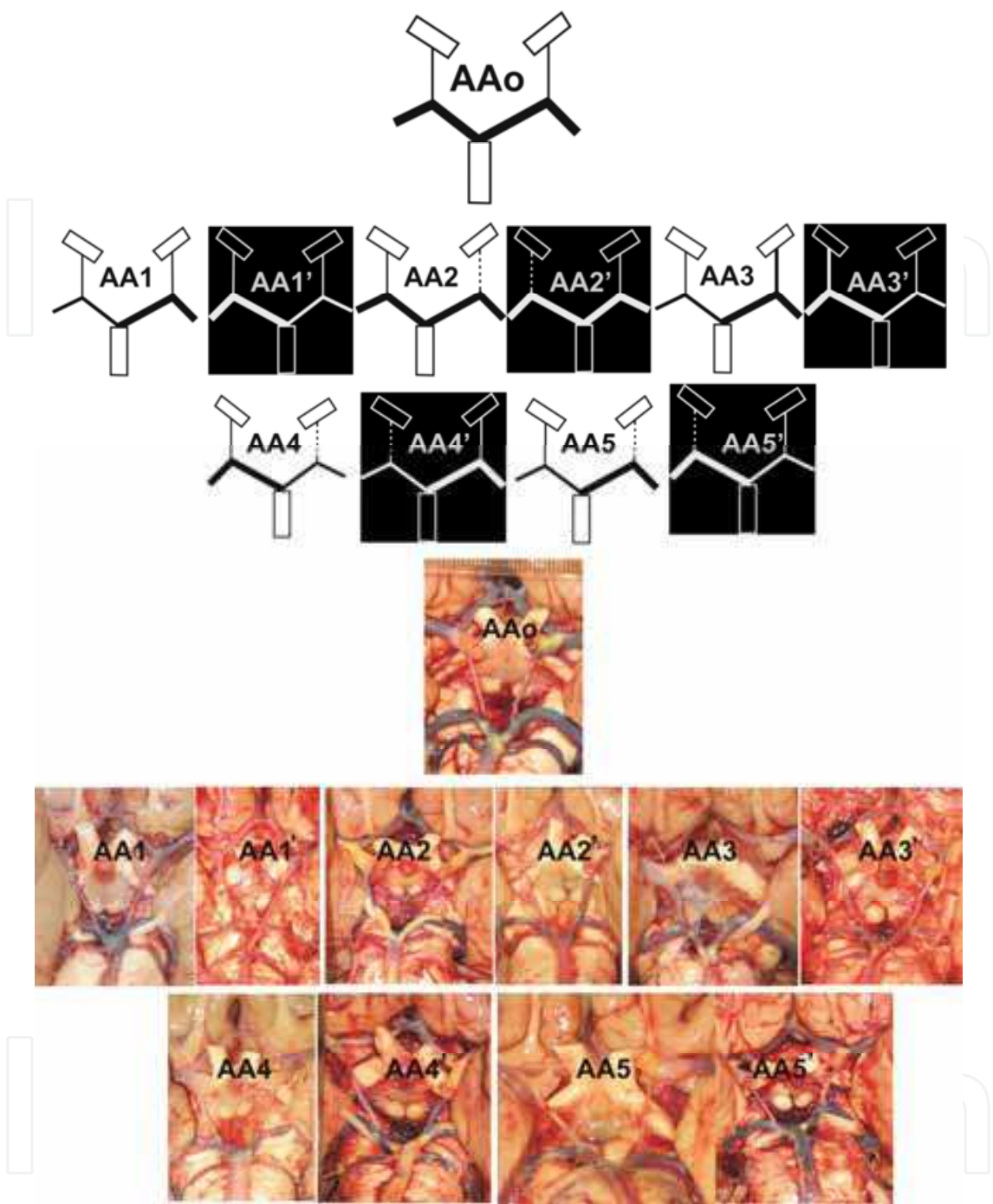


Fig. 3. Diagrams and corresponding photos of subtypes of the bilateral adult (AA) type.

Right or left posterior communicating artery, rPCoA or lPCoA; right or left pre communicating part of the posterior cerebral artery, rP1 or lP1.

AAo ( $rPCoA < rP1 = lP1 > lPCoA \wedge lPCoA = rPCoA$ ): 29 cases (38.6%).

AA1/AA1' ( $lPCoA = rPCoA < rP1 < lP1$ ) or ( $rPCoA = lPCoA < lP1 < rP1$ ): 7 cases (9.3%).

AA2/AA2' ( $lPCoA < rPCoA < rP1 = lP1$ ) or ( $rPCoA < lPCoA < lP1 = rP1$ ): 27 cases (36%).

AA3/AA3' ( $rPCoA < rP1 = lPCoA < lP1$ ) or ( $lPCoA < rPCoA = lP1 < rP1$ ): 2 cases.

Note: left PCoA is accidentally broken in AA3 subtype.

AA4/AA4' ( $lPCoA < rPCoA < lP1 < rP1$ ) or ( $rPCoA < lPCoA < lP1 < rP1$ ): 7 cases (9.3%).

AA5/AA5' ( $lPCoA < rPCoA < rP1 < lP1$ ) or ( $rPCoA < lPCoA < lP1 < rP1$ ): 3 cases.

In AA-type, more frequent are the cases where calibers of paired pre-communicating parts of posterior cerebral arteries are equaled and larger in relation to equaled caliber of posterior communicating arteries (AAo-subtype), as well as the cases with same relationship of posterior cerebral arteries and caliber difference of posterior communicating arteries (AA2/AA2' subtype). Cases of two subtypes (AA1/AA1' and AA4/AA4') have same frequency (9.3%), while cases of AA3/AA3' (2/75) and AA5/AA5' (3/75) have the least frequency.

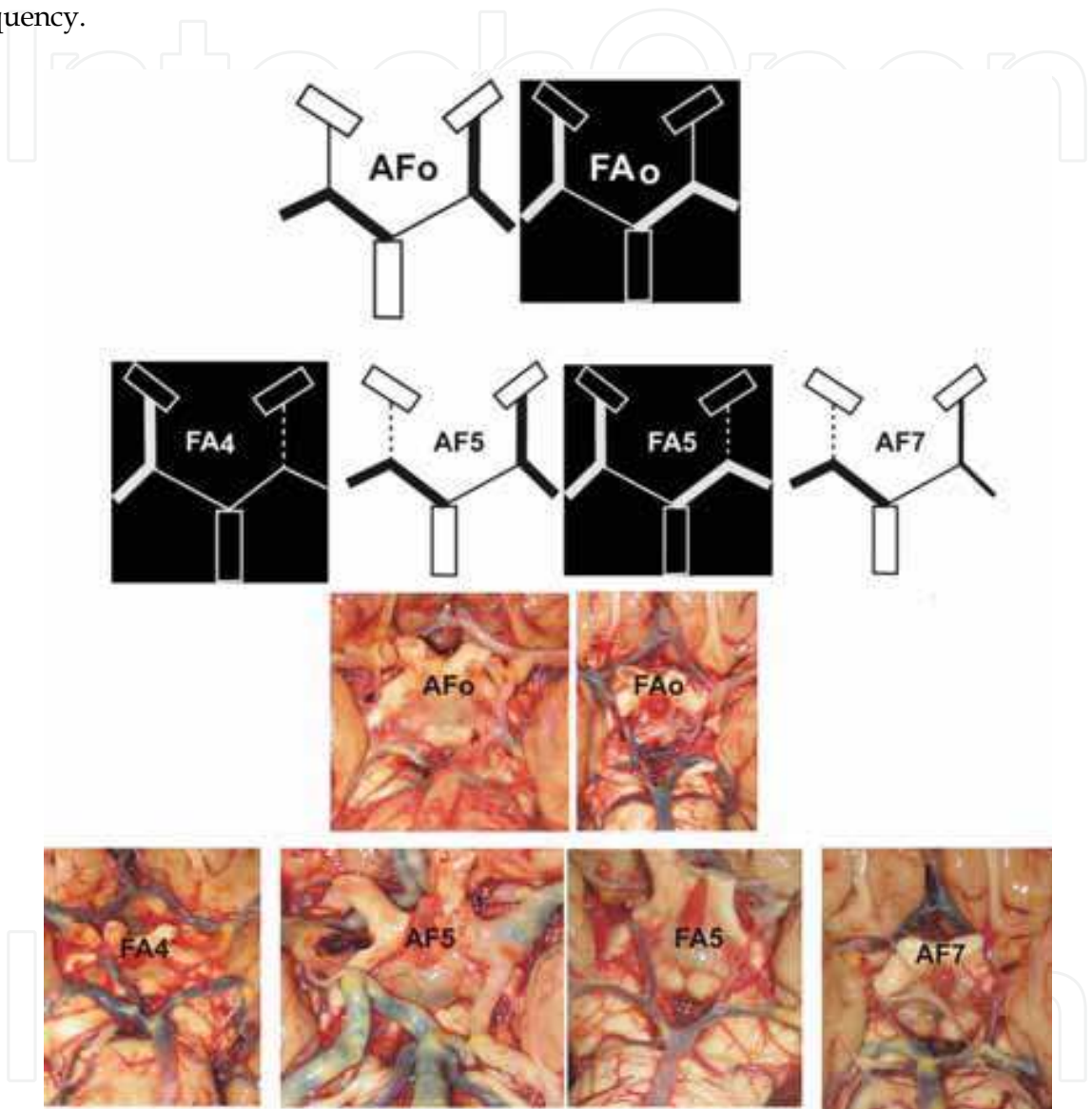


Fig. 4. Diagrams and corresponding photos of subtypes of the adult-fetal or fetal-adult (AF/FA) type.

Right or left posterior communicating artery, rPCoA or lPCoA; right or left pre communicating part of the posterior cerebral artery, rP1 or lP1.  
AFo/FAo ( $rP1 > rPCoA = lP1 < lPCoA \wedge lPCoA = rP1$ ) or ( $rPCoA > rP1 = lPCoA < lP1 \wedge lP1 = rPCoA$ ): 8 cases (53.3%).  
Note: rPCoA and lP1 are accidentally broken in AFo.  
FA4 ( $lPCoA < lP1 = rP1 < rPCoA \wedge lPCoA < rPCoA$ ): 1 case.  
AF5/FA5 ( $lPCoA = rP1 > lP1 > rPCoA$ ) or ( $rPCoA = lP1 > rP1 > lPCoA$ ): 5 cases (33.3%).  
AF7 ( $rP1 > lP1 > lPCoA > rPCoA$ ): 1 case.



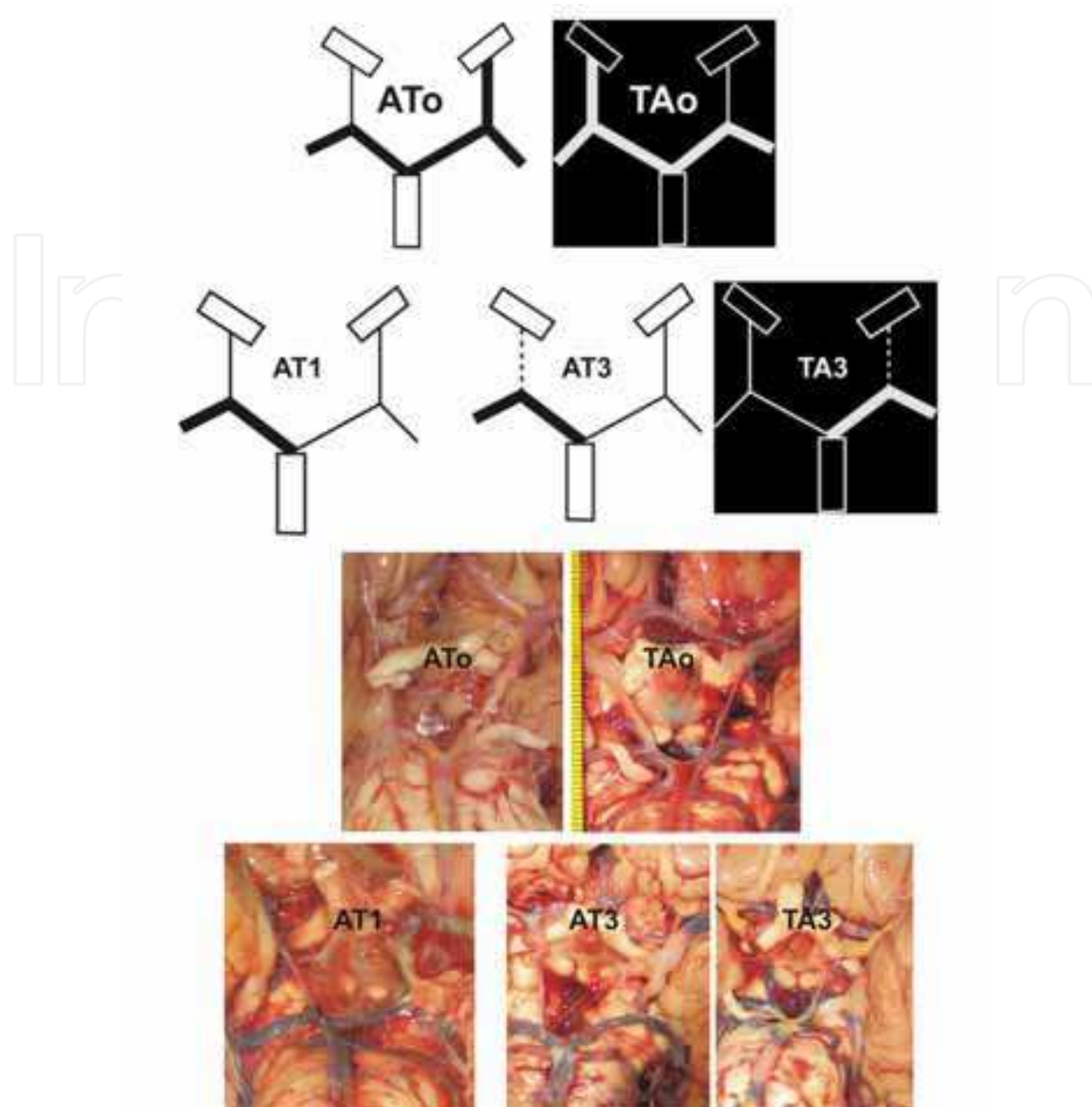


Fig. 5. Diagrams and corresponding photos of subtypes of the adult-transitory or transitory-adult (AT/TA) type.

Right or left posterior communicating artery, rPCoA or lPCoA; right or left pre-communicating part of the posterior cerebral artery, rP1 or lP1.

ATo/TAo ( $rPCoA < rP1 = lP1 = lPCoA$ ) or ( $rP1 = rPCoA = lPCoA < lP1$ ): 8 cases (66.6%).

Note: rPCoA and lP1 are accidentally broken.

AT1 ( $rP1 > lP1 = lPCoA = rPCoA$ ): 1 case.

AT3/TA3 ( $rP1 > lP1 = lPCoA > rPCoA$ ) or ( $lP1 > rP1 = rPCoA > lPCoA$ ): 3 cases (25%).

Note: Left PCoA origin is infundibular.

In AF/FA-type, more frequent are the cases where calibers of the posterior communicating artery and pre-communicating part of the posterior cerebral artery are equaled on opposite sides (AFo/FAo subtype), as well as cases with same caliber of the left or right posterior communicating artery and pre-communicating part of the posterior cerebral artery on corresponding opposite side simultaneously with larger caliber of the left or right pre-communicating part of the posterior cerebral artery in relation to opposite posterior communicating artery (AF5/FA5 subtype). Cases of two subtypes (FA4 and AF7) are singular.



In AT/TA-type, more frequent are the cases where calibers of the left or right posterior communicating artery and pre-communicating part of both posterior cerebral arteries are equaled and larger in relation to opposite posterior communicating artery (ATo/TAo subtype), as well cases where the left or right pre-communicating part of posterior cerebral artery is larger than corresponding opposite pre-communicating part of posterior cerebral artery and posterior communicating artery, simultaneously with their larger caliber than ipsilateral posterior communicating artery (AT3/TA3 subtype).

AUTHORS	N	COUNTRY	AGE*	METHOD	TYPES OF POSTERIOR PART OF THE CIRCLE OF WILLIS (%)										UNKNOWN UNILATERAL OR BILATERAL		
					BILAT ADULT (AA)	BILAT FETAL (FF)	BILAT TRANSIT (TT)	ADULT-FETAL (AF)	ADULT-TRANSIT (AT)	UNILAT ADULT	UNILAT FETAL	UNILAT TRANSIT			Adult	Fetal	Transitory
Riggs and Rupp (1993)	994	USA	ADULTS	AUTOPSY	72.8	5.6	5.4	~16									
Saeiki and Rihoton (1977)	50	USA	ADULTS	AUTOPSY	60	2		8			20						
Zeal and Rihoton (1978)	25	USA	ADULTS	AUTOPSY											58	40	20
Zada et al. (2007)	271	USA	ANEURYSMATIC SERIE	RETROSPECTIVE REVIEW		10					11						
Kayembe et al. (1984)	44	Japan	ADULTS	AUTOPSY		9.1					6.8						
	148		ANEURYSMATIC AND CONTROL SERIE			6					8.3						
Tanaka et al. (2006)	117	Japan	20-29	MRI	~95												
Chen et al. (2004)	111	China	<40	MRA	27.9	5.4		~9									
	396		>40		10.6	6		~4									
	45		CHILDREN								6.6						
Sahni et al. (2007)	280	India	ADULTS	AUTOPSY		0.3					6.8						
Krishnamurthy et al. (2008)	89	India	ADULTS	AUTOPSY		2.2											
Pai et al. (2007)	25	India	40-84	AUTOPSY											78	10	12
Poudel and Bhattarai (2010)	35	Nepal	ADULTS	AUTOPSY	91.4	8.6											
De Silva et al. (2010)	225	Sri Lanka	ADULTS	AUTOPSY	88	1.3	0.8			8.8	6.1	2.6					
Efekhtar et al. (2006)	102	Iran	15-75 (male)	AUTOPSY							26 (right)						
											28 (left)						
Songur et al. (2008)	110	Turkey	17-58	AUTOPSY											35.4		
Al-Hussaini et al. (2001)	50	Jordan	20-55	AUTOPSY											77	15	8
Alawad et al. (2009)	143	Sudan	40-65	MRA	97.5												
Malamateriou et al. (2009)	94	UK	INFANTS (PRETERM-AT-TERM AND TERM-BORN)	MRA		25.5	~8										
Van Overbeke et al. (1991)	100	Netherlands	ADULTS	AUTOPSY											84	14	2
Hartkamp et al. (1999)	175	Netherlands	PATIENTS	MRA		54	1			8							
			CONTROLS			25	8			14							
Yasargil (1984)	200	Switzerland	ADULTS	AUTOPSY											67.5	24.5	8
Gabrovsky (2002)	35	Bulgaria		AUTOPSY												41.4	11.4
Papantchev et al. (2007)	99	Bulgaria	ADULTS	AUTOPSY												30.4	9.1
RECENT STUDY	110	Serbia	20-95	AUTOPSY	68.18	7.27		13.63	10.91								

Table 5. Incidences of (sub) types of the circle posterior part in human specimens in same and/or different countries on four continents.

Thicker black lines separate corresponding continents;  
N (number of investigated specimens);  
\*population group or years.

There are about 65% of hypoplastic posterior communicating arteries ( $\leq 0.5$  mm + 1SD) in AA type; about one half of the cases are bilateral. There is about 44% of unilaterally hypoplastic posterior communicating artery in AF/FA and AT/TA types with relatively more frequency on the left side. Generally, about 60% of hypoplastic posterior communicating arteries are in adults after 65. There are 6.6% of bilaterally and about 14% of unilaterally hypoplasia of the pre-communicating part of the posterior cerebral artery ( $\leq 1$  mm + 1SD) in FF, AF/FA and AT/TA types, respectively.

There is significant correlation ( $R=0.51$ ,  $p<0.01$ ) between right and left pre-communicating parts of the posterior cerebral arteries calibers, between the right pre-communicating part of the posterior cerebral artery and left posterior communicating artery caliber ( $R=0.39$ ,  $p<0.01$ ) and between right and left posterior communicating arteries caliber ( $R=0.44$ ,  $p<0.01$ ) in AA type. In AF type, significant correlation is present between right pre-communicating part of the posterior cerebral artery and left posterior communicating artery caliber ( $R=0.76$ ,

p<0.01). Significant correlation is present between right pre-communicating part of the posterior cerebral artery and right posterior communicating artery ( $R=-0.87$ ,  $p=0.012$ ) and left posterior communicating artery ( $R=0.87$ ,  $p=0.011$ ) caliber, as well as, right and left posterior communicating artery caliber ( $R=0.86$ ,  $p=0.013$ ) in AT type of cases. Correlations between calibers of right and left pre-communicating parts of the posterior cerebral arteries, as well as, right and left posterior communicating arteries of AA and corresponding arteries of both AF and AT types are not statistically significant (Fig. 6).

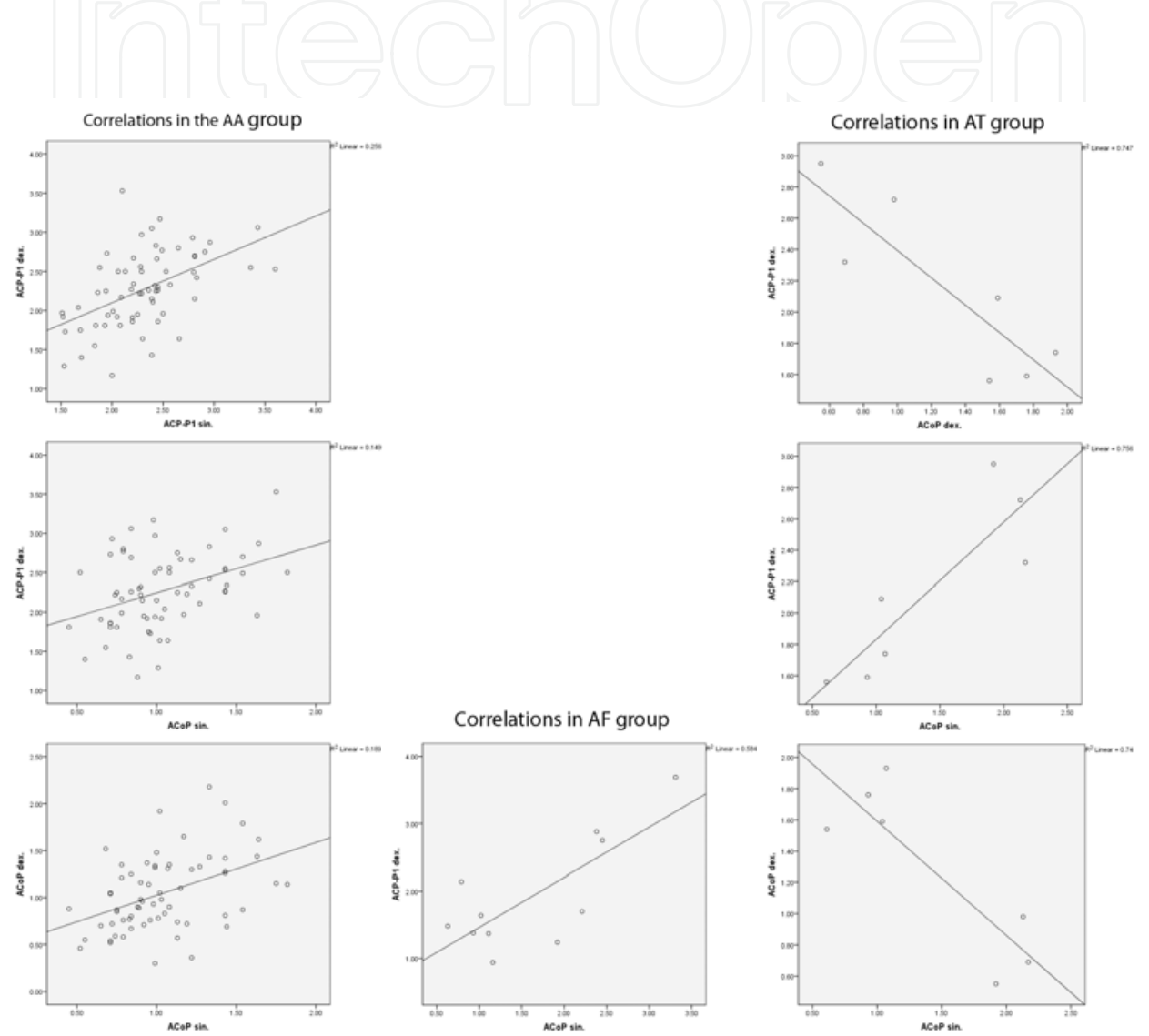


Fig. 6. Correlation of calibers of the left and right pre-communicating parts of the posterior cerebral arteries (PCAs-P1) and posterior communicating arteries (PCoAs) in corresponding type (group) of the circle posterior part

In our specimens, basilar bifurcation angle ranges from 63.4-168.1° (111.9°) in AA type and from 37.8-154.6° (96.6°) in FF type, as well from 67.3-142.2° (111.6°) and from 71.4-161.1° (128.4°) in AT/TA and AF/FA types, respectively; in average, it is 109.68° (Fig. 7). We found only one case of the basilar aneurysm originating from an obtuse basilar bifurcation angle in AAo subtype.

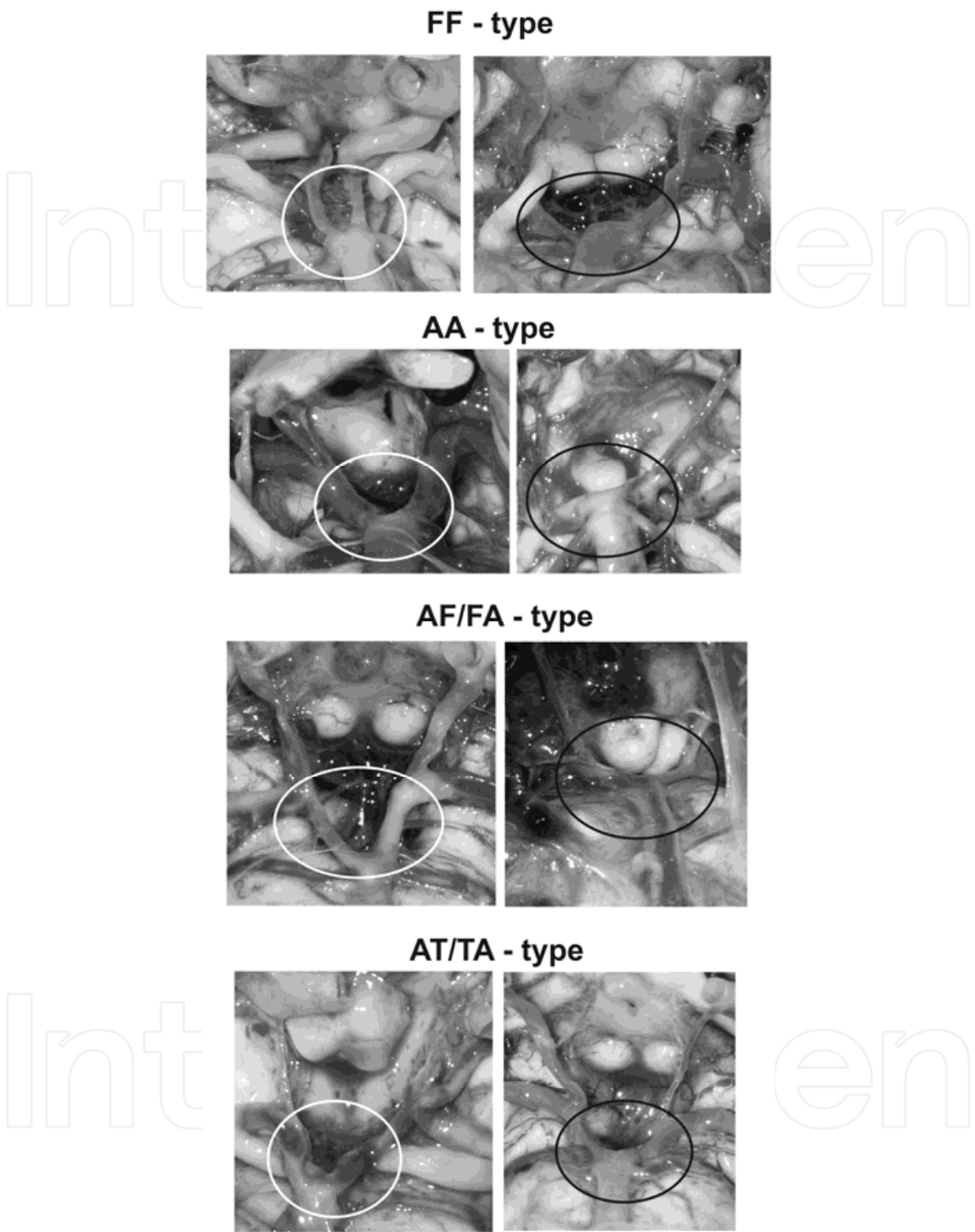


Fig. 7. The basilar bifurcation angle in corresponding type of the posterior circle part. The least and the greatest angle are encircled by white and black lines.

4. Discussion

We selected 110 circles of Willis according to the presence of four vascular components (posterior communicating and pre-communicating parts of the posterior cerebral arteries) in

the circle posterior part. The "typical" circle of Willis was defined with respect to its components as a closed circuit in which fluid may circulate from any entrance point back to the same point with all vessels more than 1 mm in external diameter and with no excess vessels (Kayembe et al., 1984). Variable five vascular components in the circle posterior part are previously described in fetuses and adults (Vasović, 2004; Vasović et al., 2010). Many authors worldwide have studied about the length, diameter and anomalies in the origin of vascular components of the circle of Willis and found that the parameters in different geographical limits were different. However, Efekhtar et al. (2006) concluded that there is no evidence that the distributions of the variations of the circle of Willis varied in different populations. Our selection of authors in Table 5 had the aim to check previous data. Different incidences of types of the circle posterior part are obvious as from continent to continent, as from the city to city in same country. Many years ago, Kayembe et al. (1984) found that the incidence of variations in the circle of Willis was significantly higher in the aneurysm series than in the control. Hartcamp et al. (1999) noted that several factors may explain a significantly higher percentage of entirely complete circle anterior or posterior configurations in different patients, including population selection, adaptation of circle morphology and improved detection of vessels with increased flow on magnetic resonance angiograms. Recently, in a study of volume flow rates of the basilar and bilateral internal carotid arteries in 125 healthy volunteers, Tanaka et al. (2006) found that the relative contribution of each of the proximal arteries correlated significantly with variations in the circle of Willis.

Average diameter of the posterior cerebral artery was seen to be 1.7 mm (Krishnamurthy et al., 2008) or 1.8 mm (Chen et al., 2004) on both sides, or 2.76 mm on the right and 2.5 mm on the left side (Pai et al., 2007), as well 1.83 mm on the right and 1.88 mm on the left side (Songur et al., 2008). Many years ago, Kamath (1981) noted that average diameter of the posterior cerebral artery was 2.1 mm on the right and 2.2 mm on the left side. Similar to these data, average diameter of the pre-communicating part of the posterior cerebral artery were 2.17 mm on the right and 2.20 mm on the left in our specimens. We found the least caliber of the pre-communicating parts of the right and left posterior cerebral arteries in a 75-year-old female and a 42-year-old male, as well the largest caliber in 47-year-old and 80-year-old males, respectively. Average diameter of the posterior communicating artery was seen to be 1.5 mm on the right and 1.4 mm on the left side (Kamath, 1981). The diameter of the posterior communicating artery varied from hypoplastic (less than 0.5 mm) to 4 mm (fetal circulation) on the right side (average 1.25 mm) and 0.5 mm to 3 mm (average 1.12 mm) on the left side (Pai et al., 2007). In our specimens, average diameter of this artery was similar on both sides (1.22 mm on the right and 1.23 mm on the left). We found the least caliber of posterior communicating arteries in 44-year-old and in a 64-year-old woman, respectively, while the largest caliber in 80-year-old woman, too. However, values of calibers of these vascular components in our study were in the function of forming basic types and their subtypes of the posterior circle part.

Al-Hussain et al. (2001) noted a possibility that the circle of Willis may have different configurations of the posterior bifurcation of the posterior communicating artery on both sides. In that case, two primary visual areas of the same individual may receive their blood from different sources; one from the basilar artery through the pre-communicating segment (adult configuration) and the other from the internal carotid artery through the posterior communicating artery (fetal configuration).

Because of many anatomical variations of the circle of Willis, its classification into clearly arranged groups is hardly possible. Urbanski et al. (2008) divided arterial variations into three groups in regard to the possible impact on the cerebral cross-perfusion. In the first group, there was only one location of hypoplasia or aplasia within the circle of Willis. In the second group, the abnormalities existed within the posterior pre-communicating or communicating arteries. In the third group, the pathologies were found in both anterior and posterior vascular components of the circle of Willis. According to Saeki & Rhoton (1977) the posterior part of the circle of Willis is normal if the posterior communicating arteries are not hypoplastic. However, we include those arteries during formation different subtypes because of no cerebral cause of death, oldest of cadavers and the presence of posterior communicating side branches. In continuation of the study on fetuses (Vasović et al., 2008a), we accepted a classification of the circle posterior part into bilateral adult (AA-), fetal (FF-) and transitory (TT-) types and their three combinations. We presented incidences of some patterns of the circle part in Table 5. According to the fact that many authors have noted incidence of one of three configurations (adult or fetal or transitory) without data about unilateral or bilateral pattern (Zeal & Rhoton, 1978; Al-Houssain et al., 2001; Gabrovsky, 2002; Pai et al., 2007; Papantchev et al., 2007; Songur et al., 2008), complete comparison is difficult. We calculated the percentages of different configurations according to diameters of the vessels, and presented in Table 5. We found four (two symmetric and two asymmetric) types and labeled with initial letters of their marks, opposite to the authors listing in Table 5. As early as seven weeks after conception, a preliminary form of the circle of Willis is present with approximately equal diameters of all vessels. As fetal growth occurs, the relative sizes of the various components of the circle of Willis change significantly to assume the eventual adult morphology (Cuchiara & Detre, 2007). Adult configurations occur in the majority of circles of Willis through further fetal and newborn life (Van Overbeeke et al., 1991), as well in majority of other and our study of adults, except in the studies of Chen et al. (2004) and Songur et al. (2008). No sexual prevalence or prevalence for the right or left side of the adult or fetal configuration was noted in a study of complete circles of Willis of 53 brains taken from fetuses and neonates aged 12 to 60 weeks after conception (Van Overbeeke et al., 1991). The preterm infants born after 30 weeks' gestation age have more significantly increased prevalence in the bilateral fetal-type origin of the posterior cerebral artery (83.3%) than those infants born before 30 weeks (Malamateniou et al., 2009). We found bilateral adult and fetal (AA and FF) types in 68.18% and 7.27%, respectively, while De Silva et al. (2010) noted in 88.8% and 1.3%, respectively in Sri Lankan population. Hendrikse et al. (2005) cited literature data that in the circle posterior part, the variant type with a unilateral fetal-type posterior cerebral artery is present on up to 25% of angiograms, and a bilateral fetal-type posterior cerebral artery present on up to 10% of angiograms. Zada et al. (2008) noted that the overall incidence of the fetal-type posterior circulation has been reported to occur in 4 to 29% of patients, whereas bilaterally occurring fetal posterior cerebral arteries have been reported to occur in 1 to 9% of patients. We also found unilateral adult configuration associated with opposite fetal (AF/FA) or transitory pattern (AT/TA) in 13.63% and 10.91%, respectively. A central hypothesis is that the circle of Willis anomalies correlates with alterations in cerebral hemodynamic. Songur et al. (2008) described that cerebral blood flow was in direct proportion to vessel diameter and thus there is more blood flow in larger vessels. In addition, a large posterior communicating artery may protect against watershed infarction in patients with ipsilateral occlusion of the internal carotid artery, while a very



small or absent ipsilateral posterior communicating artery increases the risk of a watershed infarction in these patients (Schomer et al., 1994). The patients with fetal type could be more prone to develop vascular insufficiency (Van Raamt et al., 2006) or internal carotid-posterior communicating aneurysms (Zada et al., 2008). According to De Silva et al. (2010), fetal configuration has been reported in adults at 4% to 46% on the basis of anatomical and angiographic studies, and a higher percentage of on the basis of anatomical studies has been reported in older fetuses and newborns: 35% and 56%, while only a minority of circles showed a transitional configuration, 14% and 20%, respectively. In our adult cases there was not bilateral transitory configuration as in other studies of infants or adults (Riggs & Rupp, 1963; Hartkamp et al., 1999; Malamateniou et al., 2009, De Silva et al., 2010) or fetuses (Van Overbeeke et al., 1991; Vasović et al., 2008a; De Silva et al., 2010).

Anastomotic flow between carotid and basilar arteries is limited when one or both posterior communicating arteries are hypoplastic, while effective circulation across the circle and between its anterior and posterior components is restricted when both anterior and posterior anastomotic stems are hypoplastic, as well similar limitation of collateral flow results when all component stems of the circle are hypoplastic (Riggs and Rupp, 1963). The resistance to flow across the posterior communicating artery is greater than across the anterior communicating artery, because the posterior communicating artery is usually a longer vessel (Hartkamp et al., 1999). Arteries of less than 1 mm diameter were considered abnormal, barring the communicating arteries, where less than 0.5 mm diameter was considered abnormal (Kamath, 1981; Pai et al., 2007). The relative importance of the caliber values of the brain arteries have thus been assessed, although no clear consensus is found among reports. One of limitations is also potential minor changes in the diameter of the vessels during time (Efekhtar et al., 2006). Hypoplastic vessels were defined to be those with external diameters less than 0.8 mm (Hartkamp et al., 1999; Chen et al., 2004) or 1.0 mm (Schomer et al., 1994; Gabrovsky, 2002; Efekhtar et al., 2006; Tanaka et al., 2006). When taking into account only static anatomic observations, Merkkola et al. (2006) hypothesized that the circulation to the left hemisphere would be sufficient in the majority of patients when using a threshold of 0.5 mm. The results of Hoksbergen et al. (2000) indicate that the threshold diameter for collateral function of the posterior communicating artery lies between 0.4 and 0.6 mm. This threshold diameter might be used in future studies evaluating the influence of its collateral ability in symmetric or asymmetric circle posterior part. The most common anatomic variation in the group without vascular-related abnormalities was the absence or hypoplasia of the posterior communicating artery (Malamateniou et al., 2009). Dysregulation of cerebral blood flow may allow relative ischemia to develop in the setting of increased metabolic demand related to neuronal hyper excitability, may trigger cortical spreading depression, and may predispose individuals to ischemic lesions and stroke (Cucchiara and Detre, 2008).

The study of Sahni et al. (2007) was conducted on brains of 280 adults and 45 children. The hypoplastic posterior communicating artery on the right side was present in 2 children and 17 adults, whereas on left side, it was seen in 1 child and 6 adults; bilateral hypoplastic posterior communicating artery was observed in 4 children and 17 adults. Fetal type on the right side was observed in 2 children and 12 adults, whereas on the left side, it was in 1 child and in 7 adults; bilaterally, it was found to be present only in 1 adult male. In the literature it was also noted that absence/hypoplasia of the posterior communicating artery was more

common in preterm boys than in girls, while absence/hypoplasia of the pre-communicating part of the posterior cerebral artery occurred twice as often in term-born girls than in boys (Malamateniou et al., 2009). In a study of 1000 brains, the pre-communicating part of the posterior cerebral artery was hypoplastic in 10.6% and the posterior communicating artery in 16.4% of cases (Kapoor et al., 2008). There are about 65% of hypoplastic posterior communicating arteries in bilateral adult (AA) group, and about 44% of unilaterally hypoplastic posterior communicating artery in asymmetric groups with relative more frequency on the left side in our study. Generally, about 60% of hypoplastic posterior communicating arteries are in adults aging after 65. There are 6.6% of bilaterally and about 14% of unilaterally hypoplasia of the pre-communicating part of the posterior cerebral artery in bilateral fetal (FF), adult-fetal (AF/FA) and adult-transitory groups (AT/TA), respectively. We evidenced percentile of hypoplastic pre-communicating part of the posterior cerebral and posterior communicating arteries in corresponding type and subtype, while other authors presented it as general data, except of Gabrowsky (2002). He noted that the mean diameter of the adult and fetal types of the posterior communicating artery was 1.28 and 2.33 mm, respectively. He also found that a reduction of the diameter from the anterior to the posterior third of this artery in both configurations and more frequently for the hypoplastic (51%), than for the adult type (37%). A hypoplasia of the right posterior communicating artery in 16% and left posterior communicating artery in 11%, as well of both arteries in 33% of males were seen (Efekhtar et al., 2006). Incidence of a hypoplastic pre-communicating segment of the posterior cerebral artery, according to Tanaka et al. (2006), ranges from 4% to 14% of subjects. However, a hypoplasia of the pre-communicating segment of the posterior cerebral artery and posterior communicating artery was 1% and 33%, respectively (Al-Houssain et al., 2001). A hypoplasia of the posterior cerebral artery also was noted in 2.1% on the right and in 1.4% on the left side (Alawad et al., 2009).

Since a significant inverse relationship existed between the diameters of ipsilateral posterior cerebral and posterior communicating arteries, as well as a smaller posterior communicating artery on the left would be associated with a larger posterior cerebral artery on that side (Kamath, 1981). In our study there was significant correlation between right and left pre-communicating parts of the posterior cerebral arteries calibers, between the right pre-communicating part of the posterior cerebral artery and left posterior communicating artery caliber, and between right and left posterior communicating arteries caliber in AA group. In AF group, significant correlation is present between right pre-communicating part of the posterior cerebral artery and left posterior communicating artery caliber. It was also present between right pre-communicating part of the posterior cerebral artery and right posterior communicating artery and left posterior communicating artery caliber, as well as, right and left posterior communicating artery caliber in AT group of cases.

Atheromatous changes (grade 1) were first visualized in a 34-years old male (AA2 subtype) and in five cases (one in FF2', two in AAo and two in AA2 subtype) of the fifth decade of life. We did not visualize atheromatous changes in 21 adults (9 female and 12 male) of the fifth decade and older. Atheromatous changes of grades 2 and 3 were first visualized in 42 and 47-years old males, respectively, as well as in females of the seventh decade of life (Table 4). Ravensbergen et al. (1998) noted that a strong argument for the (causal) relationship between hemodynamics and atherosclerosis can be found if variations of the geometry result in changes of the location of the atheromatous lesions, which

correspond to the changes of the flow force distribution. Songur et al. (2008) established atheromatous plaques in the basilar artery in 30% of cases. We visualized these plaques particularly for every type. Very interesting findings were that atheromatous changes of Grade 1 and 3 were the most frequent in FF (62.5) and AF/FA (26.6%) types, while the least frequency was observed both in AT/TA (16.6%) and AA- (5.3%) types. Atheromatous changes of grade 1 for male gender were more frequent in AA type; a relation was 2:1.

In our adult specimens, basilar bifurcation angle ranged from 37.8-168.1°, in average, it was 109.68°. The average basilar angle in adults was 109 degrees and ranged between 30 and 180 degrees in a study of Caruso et al. (1990). The average basilar bifurcation angle of 98 patients aging from 12 to 78 years was determined to be 117.7° (30.93°-172.2°) (Žurada et al., 2008). During a study of fetal specimens, this angle ranged from 35 to 175 degrees (Vasović et al., 2008b). Žurada et al. (2008) described three types of the basilar bifurcation angle in which a type "T" is with an angle greater than 145°, a type "Y" with an angle being equal or less than 145° but greater than 100° and a type "V" for angles less than 100°. Ingebrigsten et al. (2004) hypothesized that normal bifurcations of cerebral arteries beyond the circle of Willis would follow optimality principles of minimum work and that the presence of aneurysms would be associated with deviations from optimum bifurcation geometry. We found only one case of basilar tip aneurysm arising from an obtuse basilar bifurcation angle. However Valleé et al. (2003) showed two basilar apex aneurysms originating from bifurcation angles of about 90 degrees and 180 degrees.

We presented six AA-subtypes of the AA-type, four subtypes of the FF-type, three subtypes of the AT/TA-type and four subtypes of the AF/FA-type of the posterior part of the circle of Willis. Van Raamt et al. (2006) proposed to define a partial fetal-type posterior circle of Willis, in which a small pre-communicating part between the basilar artery and the post-communicating part of the posterior cerebral artery is present, and a full fetal-type posterior circle of Willis, in which the pre-communicating part is absent. Besides our study confirms a domination of bilateral adult configuration of the circle posterior part as other authors, we are the first who classified and marked posterior circle subtypes, as well as new subtypes, which missing in fetal status (Vasović, 2004). We found some similar schemes of (sub) types in Riggs' paper (Riggs & Rupp, 1963) and Yasargil's book (Yasargil, 1984); however, we can not do precise comparison with them. It is difficult confirm that some subtypes of the posterior circle part is a feature of Serbian population. This study offers a possibility to evaluate that angioarchitecture in different health population groups or in patients with or without cerebral pathology wide our or other countries, especially if proposed (sub) types of the circle posterior part many authors could be accept.

## 5. Acknowledgment

Contract grant sponsor: Ministry of Science and Technological Development of Republic of Serbia (No: 41018 and 175092).

## 6. References

- Alawad, A.H.M.; Hussein, M.A. & Hassan, M.A. (2009). Morphology and Normal Variations of the Cerebral Arterial Circle "of Willis" in Khartoum Diagnostic Centre. *Khartoum Medical Journal*, Vol.2, No.2, (May 2009), pp. 215-219, ISSN 0491-4481

- Al-Hussain, S.M.; Shoter, A.M. & Bataina, Z.M. (2001). Circle of Willis in Adults. *Saudi Medical Journal*, Vol.22, No.10, (October 2001), pp. 895-898, ISSN 0379-5284
- Caruso, G.; Vincentelli, F.; Guidicelli, G.; Grisoli, F.; Xu, T. & Gouaze, A. (1990). Perforating Branches of the Basilar Bifurcation. *Journal of Neurosurgery*, Vol.73, No.2, (August 1990), pp. 259-265, ISSN 0022-3085
- Chen, H-W.; Yen, P-S.; Lee, C-C.; Chen, C-C.; Chang, P-Y.; Lee, S-K.; Lee, W-H.; Ling, C-M. & Chou, A.S-M. (2004). Magnetic Resonance Angiographic Evaluation of Circle of Willis in General Population: A Morphologic Study in 507 Cases. *Chinese Journal of Radiology*, Vol.29, No.5, (October 2004), pp. 223-229, ISSN 1018-8940
- Cucchiara, B. & Detre, J. (2008). Migraine and Circle of Willis Anomalies. *Medical Hypotheses*, Vol.70, No.4, (January 2008), pp. 860-865, ISSN 0306-9877
- De Silva, K.R.D.; Silva, R.; De Silva, C.; Gunasekera, W.S.L. & Jayasekera, P.D.R.W. (2010). Comparison of the Configuration of the Posterior Bifurcation of the Posterior Communicating Artery between Fetal and Adult Brains: A Study of a Sri Lankan Population. *Annals of Indian Academy of Neurology*, Vol.13, No.3, (October 2010), pp.198-201, ISSN 0972-2327
- Eftekhari, B.; Dadmehr, M.; Ansari, S.; Ghodsi, M.; Nazparvar, B. & Ketabchi, E. (June 2006). Are the Distributions of Variations of Circle of Willis Different in Different Populations? – Results of an Anatomical Study and Review of Literature, In: *BMC Neurology*, 24.06.2006, Available from <http://www.ncbi.nlm.nih.gov/pmc/articles/PMC1543654/>
- Gabrovsky, N. (2002). Microanatomical Bases for Intraoperative Division of the Posterior Communicating Artery. *Acta Neurochirurgica*, Vol.144, No.11, (November 2002), pp.1205-1211, ISSN 0001-6268
- Hartkamp, M.J.; Van der Grond, J.; Van Everdingen, K.J.; Hillen, B. & Mali, W.P.T.M. (1999). Circle of Willis Collateral Flow Investigated by Magnetic Resonance Angiography. *Stroke*, Vol.30, No.12, (September 1999), pp.2671-2678, ISSN 0039-2499
- Hendrikse, J.; Van Raamt, A.F.; Van der Graaf, J.; Mali, W.P.T.M. & Van der Grond, J. (2005). Distribution of Cerebral Blood Flow in the Circle of Willis. *Radiology*, Vol.235, No.1, (April 2005), pp.184-189, ISSN 0033-8419
- Hoksbergen, A.W.J.; Fülesdi, B.; Legemate, D.A. & Csiba, L. (2000). Collateral Configuration of the Circle of Willis Transcranial Color-Coded Duplex Ultrasonography and Comparison with Postmortem Anatomy. *Stroke*, 2000; Vol.31, No.6, (June 2000), pp. 1346-1351, ISSN 0039-2499
- Ingebrigtsen, T.; Morgan, M.K.; Faulder, K.; Ingebrigtsen, L.; Sparr, T. & Schirmer, H. (2004). Bifurcation Geometry and the Presence of Cerebral Artery Aneurysms. *Journal of Neurosurgery*, Vol.101, No.1, (July 2004), pp. 108-113, ISSN 0022- 3085
- Kamath, S. (1981). Observations on the Length and Diameter of Vessels Forming the Circle of Willis. *Journal of Anatomy*, 1981; Vol.133, No.3, (October 1981), pp. 419-423, ISSN 0021-8782
- Kapoor, K.; Singh, B. & Dewan, L.I.J. (2008). Variations in the Configuration of the Circle of Willis. *Anatomical Science International*, Vol.83, No.2, (June 2008), pp. 96-106, ISSN 1447-6959
- Kayembe, K.N.; Sasahara, M. & Hazama, F. (1984). Cerebral Aneurysms and Variations in the Circle of Willis. *Stroke*, Vol.15, No.5, (September-October 1984), pp. 846-850, ISSN 0039-2499



- Krishnamurthy, A.; Nayak, S.R.; Kumar, C.G.; Jetti, R.; Prabhu, L.V.; Ranade, A.V. & Rai, R. (2008). Morphometry of Posterior Cerebral Artery: Embryological and Clinical Significance. *Romanian Journal of Morphology and Embryology*, Vol.49, No.1, (January 2008), pp. 43-45, ISSN 1220-0522
- Malamateniou, C.; Adams, M.E.; Srinivasan, L.; Allsop, J.N.; Counsell, S.J.; Cowan, F.M.; Hajnal, J.V. & Rutherford, M.A. (2009). The Anatomic Variations of the Circle of Willis in Preterm-at-Term and Term-Born Infants: An MR Angiography Study at 3T. *ANR American Journal of Neuroradiology*, Vol.30, No.10, (November-December 2009), pp.1955- 1962, ISSN 0195-6108
- Merkkola, P.; Tulla, H.; Ronkainen, A.; Soppi, V.; Oksala, A.; Koivisto, T. & Hippeläinen, M. (2006). Incomplete Circle of Willis and Right Axillary Artery Perfusion. *The Annals of Thoracic Surgery*, Vol.82, No.1, (July 2006), pp.74-80, ISSN 0003-4975
- Pai, B.S.; Varma, R.G.; Kulkarni, R.N.; Nirmala, S.; Manjunath, L.C. & Rakshith, S. (2007). Microsurgical Anatomy of the Posterior Circulation. *Neurology India*, Vol.55, No.1, (November 2006), pp. 31-41, ISSN 0028-3886
- Papantchev, V.; Hristov, S.; Todorova, D.; Naydenov, E.; Paloff, A.; Nikolov, D.; Tschirkov, A. & Ovtcharoff, W. (2007). Some Variations of the Circle of Willis, Important for Cerebral Protection in Aortic Surgery – A Study in Eastern Europeans. *European Journal of Cardio-thoracic Surgery*, Vol.31, No.6, (June 2007), pp. 982-989, ISSN 1010-7940
- Poudel, P.P. & Bhattarai, C. (Jun 2010). Anomalous Formation of the Circulus Arteriosus and its Clinico-anatomical Significance, In: *Nepal Medical College Journal: NMCJ* 01.06.2010, Available from [http://www.nmcth.edu/nmcj\\_articles\\_pdf/volume\\_wise/nmcj\\_vol12\\_no2\\_june2010/p\\_paudel.pdf](http://www.nmcth.edu/nmcj_articles_pdf/volume_wise/nmcj_vol12_no2_june2010/p_paudel.pdf)
- Ravensbergen, J.; Ravensbergen, J.W.; Krijger, J.K.B.; Hillen B. & Hoogstraten, H. W. (1998). Localizing Role of Hemodynamics in Atherosclerosis in Several Human Vertebrobasilar Junction Geometries. *Arteriosclerosis, Thrombosis, and Vascular Biology*, Vol.18; No. 5, (May 1998), pp.708-716, ISSN 1524-4636
- Riggs, H.E. & Rupp, C. (1963). Variation in Form of Circle of Willis. *Archives of Neurology*, Vol.8, No.1, (January 1963), pp. 8-14, ISSN 0003-9942
- Saeki, N. & Rhoton, A.L. (1977). Microsurgical Anatomy of the Upper Basilar Artery and the Posterior Circle of Willis. *Journal of Neurosurgery*, Vol.46, No.5, (May 1977), pp. 563-578, ISSN 0022-3085
- Sahni, D.; Jit, I. & Lal, V. (2007). Variations and Anomalies of the Posterior Communicating Artery in Northwest Indian Brains. *Surgical Neurology*, Vol.68, No.4, (October 2007), pp. 449-453, ISSN 0035-6336
- Schomer, D.F.; Marks, M.P.; Steinberg, G.K.; Johnstone, I.M.; Boothroyd, D.B.; Ross, M.R.; Pelc, N.J. & Enzmann, D.R. (1994). The Anatomy of the Posterior Communicating Artery as a Risk Factor for Ischemic Cerebral Infarction. *The New England Journal of Medicine*, Vol.330, No.22, (June 1994), pp.1565-1570, ISSN 0028-4793
- Silver, J.M. & Wilkins, R.H. (1991). Arterial Embryology, In: Persistent Embryonic Intracranial and Extracranial Vessels, In: *Neurosurgery Update II: Vascular, Spinal, Pediatric, and Functional Neurosurgery*, R.H. Wilkins, S.S. Rengachary, (Eds), 50-51, McGraw-Hill, Health Professions Divisions, ISBN 9780070798298, New York, USA




- Songur, A.; Gonul, Y.; Ozen, O.A.; Kucuker, H.; Uzun, I.; Bas, O. & Toktas, M. (2008). Variations in the Intracranial Vertebrobasilar System. *Surgical and Radiologic Anatomy*, Vol.30, No.3, (May 2008), pp. 257-264, ISSN 0930-1038
- Tanaka, H.; Fujita, N.; Enoki, T.; Matsumoto, K.; Watanabe, Y.; Murase, K. & Nakamura, H. (2006). Relationship between Variations in the Circle of Willis and Flow Rates in Internal Carotid and Basilar Arteries Determined by Means of Magnetic Resonance Imaging with Semiautomated Lumen Segmentation: Reference Data from 125 Healthy Volunteers. *AJNR American Journal of Neuroradiology*, Vol.27, No.8, (September 2006), pp. 1770 -1775, ISSN 0195-6108
- Urbanski, P.P.; Lenos, A.; Blume, J.C.; Ziegler, V.; Griewing, B.; Schmitt, R.; Diegeler, & Dinkel, M. (2008). Does Anatomical Completeness of the circle of Willis Correlate with Sufficient Cross-perfusion during Unilateral Cerebral Perfusion? *European Journal of Cardio-thoracic Surgery*, Vol.33, No.3, (December 2007), pp. 402-408, ISSN 1010-7940
- Van Overbeeke, J.J.; Hillen, B. & Tulleken, C.A.F. (1991). A Comparative Study of the Circle of Willis in Fetal and Adult Life. The Configuration of the Posterior Bifurcation of the Posterior Communicating Artery. *Journal of Anatomy*, Vol.176, No.1, (June 1991), pp. 45-54, ISSN 0021-8782
- Vallee, J-N.; Aymard, A.; Vicaut, E.; Reis, M. & Merland, J-J. (2003). Endovascular Treatment of Basilar Tip Aneurysms with Guglielmi Detachable Coils: Predictors of Immediate and Long-term Results with Multivariate Analysis- 6-year Experience. *Radiology*, Vol.226, No.3, (March 2003), pp. 867-879, ISSN 0033-8419
- Van Raamt, A.F.; Mali, W.P.T.M.; Van Laar, P.J. & Van der Graaf, Y. (2006). The Fetal Variant of the Circle of Willis and Its Influence on the Cerebral Collateral Circulation. *Cerebrovascular Disease*, Vol.22, No.4, (Jun 2006), pp. 217-224, ISSN 1015-9770
- Vasović, L.P. (2004). The Tenth Vascular Component in a Rare Form of the Cerebral Arterial Circle of Fetuses. *Cells Tissues Organs*, Vol. 178, No.4, (November 2004), pp. 231-238, ISSN 1422-6405
- Vasović, L.P.; Jovanović, I.D.; Ugrenović, S.Z. & Andjelković, Z.P. (2008a). Normal Subtypes of the Posterior Part of the Cerebral Arterial Circle in Human Fetuses. *Surgical Neurology*, Vol.70, No.3, (September 2008), pp. 287-294, ISSN 0035-6336
- Vasović, L.; Jovanović, I.; Ugrenović, S.; Stojanov, D. & Radovanović, Z. (2008b). Basilar Bifurcation: A Comparison of Prenatal and Postnatal Cases. *Neuroanatomy*, Vol.7, (December 2008), pp. 66-71, ISSN 1303-1783
- Vasović, L.; Trandafilović, M.; Jovanović, I.; Antović, A.; Stojanović, J.; Zdravković, M. & Milić M. (June 2010). An Excess
- Vessel in the Posterior Part of the Human Cerebral Arterial Circle (CAC): A Case Series, In: *BioMedCentral Neurology*, 23.06.2010, Available from <http://www.ncbi.nlm.nih.gov/pmc/articles/PMC2909942/>
- Yasargil, M.G. (1984). Intracranial Arteries, In: Operative Anatomy, In: Microneurosurgery Vol I, M.G. Yasargil, (Ed.), 54-158, Thieme, ISBN: 3136448014, Stuttgart-New York, Germany-USA
- Zada, G.; Breault, J.B.A.; Liu, C.Y.; Khalessi, A.A.; Larsen, D.W.; Teitelbaum, G.P. & Giannotta, S.L. (2008). Internal Carotid Artery Aneurysms Occurring At the Origin of Fetal Variant Posterior Cerebral Arteries: Surgical and Endovascular Experience. *Neurosurgery*, Vol.63, Suppl.1, (July 2008), pp. 55-62, ISSN 0148-396X

- Zeal, A.A. & Rhoton, A.L. (1978). Microsurgical Anatomy of the Posterior Cerebral Artery. *Journal of Neurosurgery*, Vol.48, No.4, (April 1978), pp. 534-559 ISSN 0022-3085
- Żurada, A., Gielecki, J.S.; Baron, J.; Zawiliński, J. & Kozłowska H. (2008). Interactive 3D stereoscopic digital-image analysis of the basilar artery bifurcation. *Clinical Anatomy*, Vol.21, No.2, (March 2008), pp. 127-137, ISSN 0897-3806

IntechOpen

IntechOpen



## **Forensic Medicine - From Old Problems to New Challenges**

Edited by Prof. Duarte Nuno Vieira

ISBN 978-953-307-262-3

Hard cover, 382 pages

**Publisher** InTech

**Published online** 12, September, 2011

**Published in print edition** September, 2011

Forensic medicine is a continuously evolving science that is constantly being updated and improved, not only as a result of technological and scientific advances (which bring almost immediate repercussions) but also because of developments in the social and legal spheres. This book contains innovative perspectives and approaches to classic topics and problems in forensic medicine, offering reflections about the potential and limits of emerging areas in forensic expert research; it transmits the experience of some countries in the domain of cutting-edge expert intervention, and shows how research in other fields of knowledge may have very relevant implications for this practice.

### **How to reference**

In order to correctly reference this scholarly work, feel free to copy and paste the following:

Ljiljana Vasović, Milena Trandafilović, Ivan Jovanović, Slađana Ugrenović, Slobodan Vlajković and Jovan Stojanović (2011). Types and Subtypes of the Posterior Part of the Cerebral arterial Circle in Human Adult Cadavers, Forensic Medicine - From Old Problems to New Challenges, Prof. Duarte Nuno Vieira (Ed.), ISBN: 978-953-307-262-3, InTech, Available from: <http://www.intechopen.com/books/forensic-medicine-from-old-problems-to-new-challenges/types-and-subtypes-of-the-posterior-part-of-the-cerebral-arterial-circle-in-human-adult-cadavers>

**INTECH**  
open science | open minds

### **InTech Europe**

University Campus STeP Ri  
Slavka Krautzeka 83/A  
51000 Rijeka, Croatia  
Phone: +385 (51) 770 447  
Fax: +385 (51) 686 166  
[www.intechopen.com](http://www.intechopen.com)

### **InTech China**

Unit 405, Office Block, Hotel Equatorial Shanghai  
No.65, Yan An Road (West), Shanghai, 200040, China  
中国上海市延安西路65号上海国际贵都大饭店办公楼405单元  
Phone: +86-21-62489820  
Fax: +86-21-62489821

© 2011 The Author(s). Licensee IntechOpen. This chapter is distributed under the terms of the [Creative Commons Attribution-NonCommercial-ShareAlike-3.0 License](https://creativecommons.org/licenses/by-nc-sa/3.0/), which permits use, distribution and reproduction for non-commercial purposes, provided the original is properly cited and derivative works building on this content are distributed under the same license.

IntechOpen

IntechOpen