

We are IntechOpen, the world's leading publisher of Open Access books Built by scientists, for scientists

6,900

Open access books available

186,000

International authors and editors

200M

Downloads

Our authors are among the

154

Countries delivered to

TOP 1%

most cited scientists

12.2%

Contributors from top 500 universities



WEB OF SCIENCE™

Selection of our books indexed in the Book Citation Index
in Web of Science™ Core Collection (BKCI)

Interested in publishing with us?
Contact book.department@intechopen.com

Numbers displayed above are based on latest data collected.
For more information visit www.intechopen.com



Gynoid Lipodystrophy Treatment and Other Advances on Laser-Assisted Liposuction

Alberto Goldman¹, Sufan Wu², Yi Sun²,
Diego Schavelzon³ and Guillermo Blugerman³

¹*Clinica Goldman of Plastic Surgery, Porto Alegre, RS*

²*Department of Plastic and Reconstructive Surgery
Zhejiang Provincial People's Hospital, Hangzhou, Zhejiang*

³*Centro B&S de Excelencia en Cirugía Plástica, Buenos Aires*

¹*Brazil*

²*China*

³*Argentina*

1. Introduction

Localized adiposis invariably disturbs the natural contours of the face and body, and can further cause the inferiority of the patients. Moreover, excessive obesity could be harmful for the health. Therefore, removal of the excess adipose tissue to keep the perfect shape and maintain a healthy physical state is now a common pursuit. Many methods have been used to treat the local adiposis and general obesity, including diet, medication, exercise and liposuction. For the purpose of improving the body contour, liposuction is the most widely used due to its long lasting result and positive effect. Over the past 30 years, liposuction has become an increasingly popular procedure and one of the most frequent aesthetic surgical operations.

At the earlier stage of the liposuction in the 1980s, the operation was usually performed as a hospital in-patient procedure, under general anesthesia and often required blood transfusion due to the blood lost during the operation. The procedure was usually related to a lot of potential complications. In 1988, Klein [1] published his important scientific contribution on the tumescent technique, administering large quantities of very dilute buffered lidocaine and epinephrine which could significantly reduce intra-operative bleeding and post-operative ecchymoses [2]. Although Klein's tumescent technique dramatically improved the safety and recovery of patients, it has some shortages and the complications after liposuction, including bleeding, pain, operative trauma, slow recovery with weeks down time to the patients, and hard work for the surgeons.

On the other hand, Liposuction can work well for treating large areas of adiposis with thicker layers and looser texture, but it is less effective for the compact adipose tissues found in some localized positions such as the neck, in secondary procedures or in cases of gynecomastia. The adiposis in these locations consists of firm fibrous connective tissue and compact adipose tissues, which makes conventional liposuction more difficult to perform. It is difficult to insert and move the suction cannula within the compact tissues, and the

compact adipose tissues are not easily aspirated. If force is exerted repeatedly, it causes great damage to the tissues. For these reasons, surgeons are continuing to refine the procedures and seek more advanced procedures with less injury, shorter down time, and more effective, such as interventional ultrasound-assisted liposuction [3-5], external ultrasound-assisted lipoplasty [6] and power-assisted lipoplasty [7]. In the search for a better solution, laser lipolysis was used to treat localized adiposis instead of conventional liposuction.

Laser is an important innovation and has become a popular device in surgery, which is mainly used to treat hemangioma, tattoo, pigmentation, scars and so on. By its thermal effects on the tissue, laser was also studied on the lipolysis. From the 1990s, several papers have discussed the effects and results of different types of lasers on adipose tissues. Apfelberg [8-10] was beginning to study laser-assisted liposuction; this preliminary investigation utilized a YAG optical fiber contained within a liposuction cannula. The investigators concluded that no clear benefit was demonstrated with the laser. Since FDA did not approve the technique, the researchers did not pursue the study. In the late 1990s, Neira and colleagues began studying the effects of low-level laser on adipose tissue [11-14]. At the same time, Blugerman [15] /, Schavelzon [16] and Goldman [17-18] were studying 1064 nm neodymium:yttrium-aluminum-garnet (Nd:YAG) laser on the lipolysis. They found that the laser could cause adipocytes lysis effectively and had less side-effect. The characteristics of laser lipolysis are less intra-operative blood loss, less post-operative ecchymoses and improved skin tightening and skin re-draping during the recovery process [19, 20]. The procedures of lipolysis made small tunnels in the adipose tissue, resulted in small blood vessels coagulation and coagulation of reticular dermis [21-24].

The accumulated experience and scientific publications of the senior author and colleagues during the last 10 years enhance the knowledge about laser and tissue interactions, as well as the possibility of obtaining not only fat-cell disruption but also tissue tightening, supports the efficacy and safety of subdermal laser-assisted use in the body and facial treatments. Current laser-assisted liposuction is designed to provide more selective adipose damage, facilitate fat removal, enhance hemostasis, and increase tissue tightening. Recent advances demonstrating the use of the laser in direct contact with targets like the fat, sweat glands, vessels and dermis layers opened up new applications on different conditions. Although some negative or neutral views have been reported, most of the results have shown that laser lipolysis has the advantages of less bleeding, pain, and edema, a quicker recovery and better comfort. Most of the patients obtained satisfactory results, with significant reduction of their adiposes. The clinical results have proved that laser lipolysis is an effective therapy for these patients. In subsequent histologic studies, the findings showed that the adipose cells had been damaged and "melted." Their cell membranes had shrunk, curled, or ruptured, leading to loss of integrity and shape of the cells, with consequent loss of cellular content.

The purpose of the chapter is to demonstrate the evolution and new indications of laser lipolysis as well as new concepts and trends related to this technique. Treatment of localized fat, skin and tissue flaccidity, cellulite, lipomas, hyperhidrosis and osmidrosis, vascular alterations, treatment of complications related to permanent fillers, combine treatments with traditional surgeries and new indications will be described in the chapter.

2. Laser biology

A laser (light amplification by stimulated emission of radiation) is a device which generates a coherent beam of stimulated emission light resulted from a quantum mechanical effect. The first working laser was a ruby laser with a wavelength of 694nm, invented by Maiman in 1969, who later received the Albert Einstein Award. There are several properties of laser beams: 1) monochromatic: all of the waves of a laser having the same wavelength; 2) collimated: a laser generally emits photons in a narrow direction, and the waves parallel and have minimal variation in convergence or divergence; 3) coherent: describes the property of having waves that are in phase with on another in both space and time; 4) high brightness: a laser light can be highly intense, and to be focused to very high intensities and used for cutting, burning or even vaporizing materials.

The tissue interactions produced by lasers are 1) photothermal effect: converting light energy into heat energy, which then heat tissue up to be coagulated and even be vaporized; 2) photochemical effect: the light of laser making target cells to produce chemical reactions, such as photodynamic reactions; 3) photobiological effect, 4) electromechanical effect: dielectric breakdown in tissue caused by shock wave plasma expansion resulting in localized mechanical rupture. The processes of laser after arrival on the tissue are transmission, absorption, reflection, and scatter. There are several important parameters determining the action level of laser on the tissue: 1) wavelength: it is the primary parameter of the laser, which affects the absorption of laser by tissues; 2) power density: related to the power and spot size, and plays a critical role in determining tissue interaction; 3) exposure time: the more exposure time, the more energy acted on the tissue; 4) laser types: Q-switched, pulsed and continuous wave (CW), which was used for different purposes clinically. Laser is an important innovation and has become a popular device in surgery. Nd:YAG laser produces a beam in the near-infrared region, with a wavelength of 1064nm. Its main effect on the tissue is coagulation, which could be used to destroy tumors or to coagulate vascular vessels, for the treatment of hemangioma, tattoo, pigmentation, scars and so on. The Nd:YAG laser could be transmitted through flexible quartz fiber optics, making its use in endoscopy possible.

The Nd:YAG laser beam scatters in tissue to create the coagulation and can also produce retrograde scatter. The YAG lasers using in the lipolysis usually have high output power of 6 to 30 watts, which are highly dangerous of safety classes IV. Because of its danger, special eye protection is necessary. All personnel should wear glasses with side panels or goggles that are appropriated for the laser in use, since the eye is the most delicate organ commonly exposed to laser injury. Green filter glass is needed for the Nd: YAG laser. Moreover, during tissue vaporization, smoke is produced, which contains nonviable particles, and so should be avoided to be breathed in.

3. Histological study of laser lipolysis

Observed by the optical microscope and SEM, lipocytes were separated into fat lobules in normal adipose tissue (Fig. 1-3). They were spherical, surrounded by vessels and connective tissues. Small nucleus was located at the edges of cells. After irradiated by the laser, the adipose tissues became loose and messy, blank areas were observed that the closer to the blank areas the more serious destruction appeared. Fibers were broken. Some crater-like

depressions were seen. Lipocytes shrunk, broke and melted, and a large number of lipid droplets leaked. Connective tissues melted, twisted and adhered.

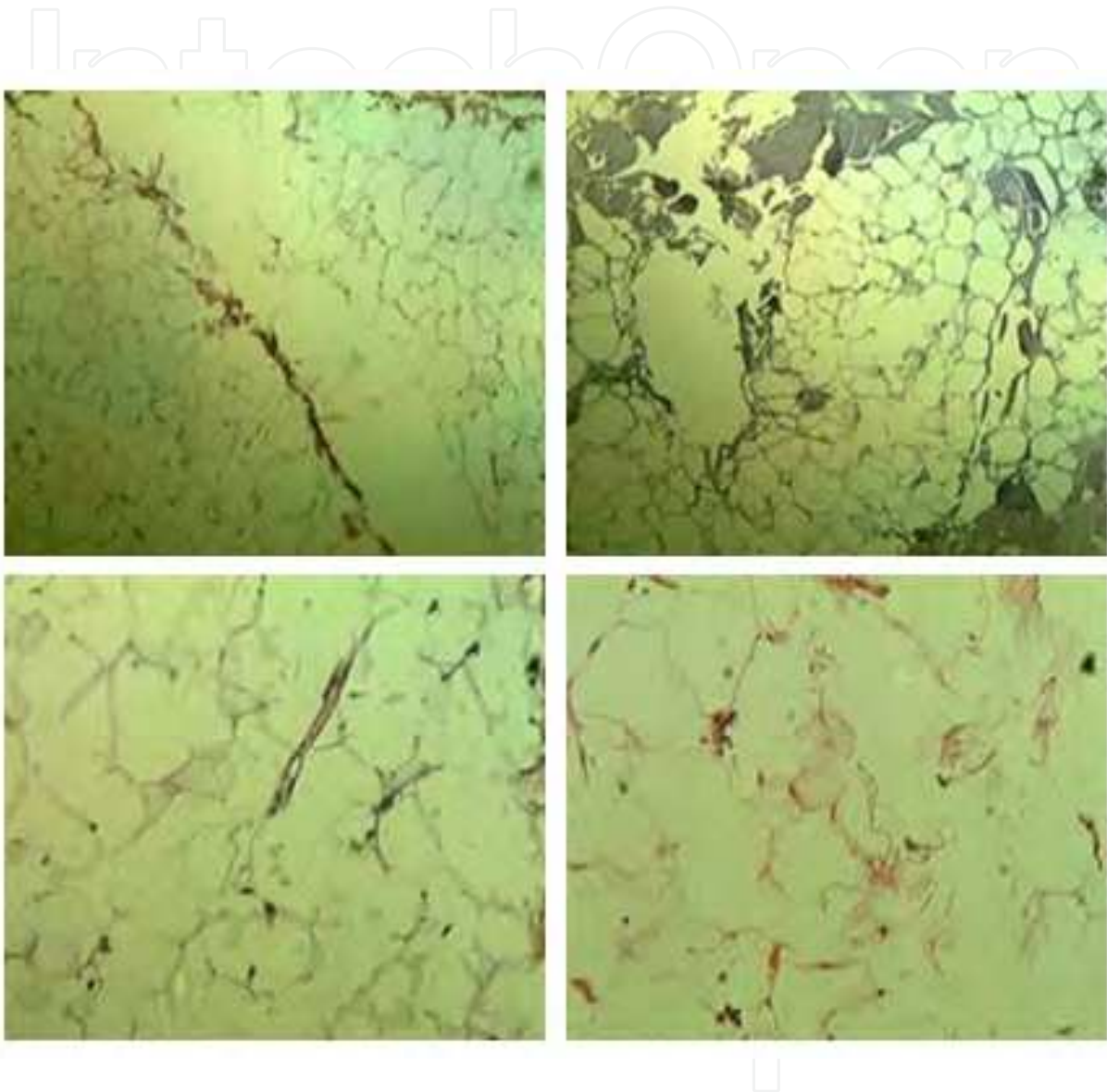


Fig. 1. Adipose tissues irradiated by the laser (optical microscope). The adipose tissues became loose and messy, blank areas were observed that the closer to the blank areas the more serious destruction appeared. Fibers were broken. Some crater-like depressions were seen. Lipocytes shrunk, broke and melted.




Fig. 2. Normal adipose tissues (SEM). Lipocytes were separated into fat lobules in normal adipose tissue. They were spherical, surrounded by vessels and connective tissues.




Fig. 3. a. The adipose tissue after laser treatment is examined by the scanning electron microscope. Adiposis is melted, and a channel is made. The arrow indicates that the diameter of the channel is approximately 1 mm (bar = 1 mm). b. Adipose cells are damaged and melted by the laser treatment, with the cell membrane shrunken, curled, and ruptured (asterisks). The shape of the cells is not intact (bar = 0.1 mm)

3. Fundamentals of laser lipolysis

As the laser has the biothermal effect on tissues, it is expected can overcome the shortage of traditional surgical method, disrupt adipose tissues selectively, shorten surgery and recovery time, enhance hemostasis, promote tissue retraction, and reduce complications. From the 1990s, several papers have discussed the effects and results of different types of

lasers on adipose tissues. The accumulated experience and scientific publications of the authors and colleagues enhance the knowledge about laser and tissue interactions, as well as the possibility of obtaining not only fat-cell disruption but also tissue tightening, supports the efficacy and safety of subdermal laser-assisted use in the body and facial treatments. Current laser-assisted liposuction is designed to provide more selective adipose damage, facilitate fat removal, enhance hemostasis, and increase tissue tightening. Recent advances demonstrating the use of the laser in direct contact with targets like the fat, sweat glands, vessels and dermis layers opened up new applications on different conditions.

Adipose tissue distribution is dependent on genetic and environmental factors. The total and regional masses of adipose tissue are dependent on the number of adipocytes as well as their degree of filling with depot fat. [25] The subcutaneous tissue consists of a superficial and deep adipose layer. The superficial adipose layer is contained within organized, compact fascial septa. The deep adipose layer demonstrates regional variations, but is contained within a relatively loose, less organized, and more widely spaced fascial septa. Energy substrate, storage of lipids and vitamins, protection of vital organs, physical support and insulation, maintenance of serum lipids, source of hormones and generation of heat are some of important functions related to the adipose tissue. The adipocyte represents one of the most important targets in laser lipolysis process. These adipose cells store lipids and are normal constituents of connective tissue. Adipose tissue is composed mostly of fat cells organized into lobules. Lobules of fat are separated and supported by loose connective tissue called septa.

Dermis represents another important target to be treated in the laser-assisted liposuction (laser lipolysis). The primary function of the dermis is to sustain and support the epidermis. Dermis is a complex structure and is composed of two layers, the more superficial papillary dermis and the deeper reticular dermis. The papillary dermis is thinner, consisting of loose connective tissue and some collagen. The reticular dermis consists of a thicker layer of dense connective tissue containing larger blood vessels, closely interlaced elastic fibers, fibroblasts and coarse bundles of collagen fibers arranged in layers parallel to the surface. Other targets related to this surgical procedure are represented by small blood vessels, eccrine and apocrine glands, fibrous tissue presented in cellulite and body regions previously submitted to surgical procedures like liposuction. The mechanism of action on a cellular level is due to a specific laser-tissue interaction that is defined by the process of selective photothermolysis [26]; some features of this interaction are wavelength-dependent and some are independent of wavelength used.

The progresses of laser lipolysis are: 1. melting adipose tissue into liquid state by heating adipocytes; 2. heating adipocytes to disrupt their membrane and allow extracellular drainage and facilitated suctioning; 3. heating collagenous fibrous septae and reticular dermis for enhanced tissue tightening; 4. coagulating microvasculature to improve hemostasis and to reduce postoperative bleeding. 5. minimal intervention of the procedure improving rapid recovery.

4. Instruments of laser lipolysis

The instrument of laser lipolysis consists of 3 main parts: laser machine, transfer system, and control system.

4.1 Laser machine

The effects of laser-assisted lipolysis are caused by photothermal energy as well as photomechanic effect. The various wavelengths for laser-assisted liposuction have been

selected based on the theory of selective photothermolysis. There are several wavelengths (1032nm, 1064nm) that have recently been studied, in which the Nd:YAG laser is the main option. The laser machine is usually a pulsed (40-80 Hz) Nd:YAG laser, with a wavelength of 1064nm and an output power ranging from 6 to 18 watts.

4.2 Transfer system

The transfer system basically includes optical fiber, handpiece, and cannula. The laser is conducted via an optical fiber, covered by a 1 mm introducer cannula, which could inserted into the body and directly treat the adipose tissue. The fiber extends beyond the end of the cannula by 2-3 mm (Fig. 4). This 2-3 mm extension enables the direct reaction of laser energy within the adipose tissue. The laser is conducted through a very fine (small diameter around 300um) optical fiber. Lipolysis and tissue coagulation occur during the laser irradiation. The transillumination of the 3mW diode laser beam associated with the system allows for precise localization of the fiber tip so that the surgeon is constantly aware of the location of laser activity.



Fig. 4. One-millimeter cannula containing fiber optic extended approximately 2mm from the distal end and emitting laser energy.

4.3 Control system

The total energy of laser acted on the tissue depends on power and time. The lipolyses laser machine can display and record total irradiation energy automatically (accumulated energy). The moving speed of handpiece is also important for the clinical effect: too high speed will decrease the photothermal effect on the tissue, whereas to lower speed will damage the tissue due to the thermal effect remained in small part. The authors experience of the speed is about 3-5 cm/second [31]. The laser emission is usually controlled by a foot switch. During the laser irradiation, the handpiece should be kept moving within the tissues, otherwise the tissue will be injured by the laser heating. In some modified system, the laser emission could be shut off automatically once the handpiece stopped.

5. Techniques of operation

5.1 Pre-operative preparation

Medical and psychosocial evaluation plays a fundamental role in safe and successful laser-assisted liposuction treatment. Physical evaluation includes assessment of the general medical health of the patient. A well documented medical history, physical examination, and appropriate laboratory analysis based upon the patient's general health and age must be performed on all candidates. Special attention must be paid to the skin quality, laxity and texture, presence and distribution of fat, and previous scars and treatments. Considering that body sculpturing is primarily an aesthetic procedure, patients should be of good general health. Laser-assisted liposuction is contraindicated in patients who are pregnant or lactating; patients with severe cardiovascular disease or with coagulation disorders including thrombophilia. The medical history must be evaluated in any history of bleeding disorders, emboli, thrombophlebitis, infectious diseases, previous surgical procedures and complications, poor wound healing and metabolic diseases. Psychosocial evaluation and patient's expectations are also important factors to consider. Laboratory studies must be performed (blood count with quantitative platelet assessment, prothrombin time, partial thromboplastin time and chemistry profile including liver function tests and hepatitis screen) prior to any elective surgery. Clinical examination should include planning and evaluation of all regions being treated, including the presence of hernias, scars, asymmetries, cellulite, sweat gland disease and stretch marks. The quality and texture of the skin and, particularly, its elasticity or the presence of flaccidity must also be carefully evaluated. Finally, digital photographic documentation is required for all patients.

5.2 Operative procedures

Laser-assisted liposuction may be performed under local anesthesia alone, or supplemented with intravenous sedation, epidural block or general anesthesia. The patient is marked in the standing position. The sites of laser lipolysis are marked by contour lines in ring form, and the central point of the localized adiposis is emphasized. If treatment is for cellulite, it is helpful to use various markers of different colors in order to mark areas of elevation and depression [27]. The patients were placed in appropriate positions according to the lipolysis sites. External pneumatic compression devices are placed on the legs and the patient is sedated if desired. The operation areas are cleaned and draped in the usual fashion. Subcutaneous infiltration of warmed Klein's tumescent solution, or some similar solution combining buffered lidocaine and epinephrine, precedes laser application to the areas of unwanted fat. The total volume of subcutaneous infiltration depends upon the surgeon preference and the overall size of the treatment area. The solution is warmed to minimize any discomfort associated with a temperature difference between the tissue and the fluid. Warming also helps to maintain core body temperature. The solution is injected into the subcutaneous adipose layer, and should be well distributed until the target areas are turgid. The procedure is initiated following a 10 to 20 minute delay to allow for appropriate diffusion of the fluid and adequate vasoconstriction. According to the location of the adiposis, appropriate entry points are chosen for insertion of the cannula, such as the corner of the mouth, the preauricular, or nasolabial fold for face access, or beneath the chin for neck access. More incisions are made if the treatment area is large. Direct laser application into the adipose tissue occurs via an optical fiber. This fiber (200 – 600 μm in diameter) is

conducted within a stainless steel microcannula of 1-1.5 mm external diameter using a pulsed 1064nm Nd-YAG laser (Smartlipo, Deka, Italy). Lasers have biologic effects on living tissues in the form of thermal, mechanical, electromagnetic, and photochemical reactions. Laser lipolysis melts and liquefies the adipose cells mostly by its thermal effect. The wavelength of the Nd:YAG laser is 1,064 nm, which has great penetration in soft tissue of about 8 mm and can be transmitted through an optic fiber. It frequently is used in tissue vaporization, vessel coagulation, and dissection, which enable it to be used effectively for melting adipose tissues.

Based on the photothermal effect of the laser, the localized adiposis is melted and liquefied, resulting in multiple fan-shaped channels in the adipose tissue. Various insertion routes are used, allowing the fan-shaped delivery of laser heat (irradiation) to overlap, resulting in a three-dimensional lipolysis. The movement of the cannula in the adipose tissue should be gentle and slow to avoid penetrating the skin and breaking the optic fiber. When encountering compact adipose tissues, the movement of the cannula should be slowed down until the compact fat has been broken up. It is important to keep the coordination between the moving of the handle and the control of the footswitch. The laser fiber optic should be kept moving as long as the laser emission is switched on to prevent energy accumulation at any one spot that might burn the skin. The duration of laser activity in the tissues is highly variable and depends upon the overall size of the treatment area, the thickness and volume of fat being removed, the degree of skin laxity and the presence of previous internal scarring. The surgeon senses a diminishing resistance to cannula movement as the procedure progresses. This indicates lipolysis and the presence of more liquefied fat (lysate) and less normal, untreated fat. The "pinch test" is another important method in determining the clinical endpoint of treatment.

The laser energy was related to the treatment region. The larger the region was, the greater the laser energy was needed. In different parts of the body, parts with more fibrous tissues required more laser energy. When the local adipose thickness is reduced to the expected grade, the laser irradiation is stopped. The resultant product of laser-assisted lipolysis is an oily lysate which contains ruptured adipocytes and cellular debris mixed with tumescent solution. Aspiration of this lysate is the surgeon's choice. If the surgeon chooses to remove the mixture, it is removed by gentle aspiration using a 2 mm or 3 mm external diameter cannula and a negative pressure of 0.3 to 0.5 atm (<50 kPa or 350 mm Hg). It is the authors' experience that very small areas of treatment with low volumes of lysate do well without aspiration. In larger areas such as the upper arms or abdomen, a vacuum liposuction machine could be used to remove the liquid adipose mixture. This may be the case, for example, in the treatment of the anterior cervical area or in the improvement of prominent malar fat pad. In situations when minimal lipolysis is desired, and the laser is being used mainly for the photostimulatory effect of collagen contraction, here, too, it may not be necessary to aspirate. This latter example often applies to the treatment of cellulite.

5.3 Post-operative care

Following surgery, tight garments are usually helpful in reducing edema and improving skin re-draping. During the first week following the procedure, the patient may be started on a post-operative physiotherapeutic routine to hasten the resolution of edema. Antibiotics should be used for 1 week.

6. Indications of laser lipolysis

Based on the senior authors' experience using the subdermal laser treatment with a 1064nm Nd-YAG laser, the most frequent conditions could be treated with this technique are:

6.1 Local fat deposits

Localized fat deposits in the body and face is the most frequent condition treated with this technique. The procedure is usually performed under local tumescent anesthesia. Combining laser-assisted liposuction with traditional techniques can improve the result and decrease the surgical trauma and complications. The technique is not indicated for treatment in obese subjects and severe skin flaccidity. Mild to moderate cases of skin and tissue laxity can be adequately treated and attenuated with the use of the subdermal laser-assisted application. The laser can be used even in cases without localized fat, with the intention of inducing neo-collagenesis production and a consequent tightening effect.

Cellulite, also known as gynoid lipodystrophy and edematous fibrosclerotic panniculopathy, is an alteration in the surface contour of the skin in which areas of lumpy bumpiness seem to alternate with areas of skin dimpling. This uneven skin texture is most prevalent in the abdomen, hips, thighs, and buttocks. It is estimated that 85% of postpubertal women have some degree of cellulite. The anatomic basis of cellulite has been determined through histology and, more recently, by magnetic resonance imaging studies that further revealed the ultrastructure of the subcutaneous tissue in women and men. In men, the septa are arranged in a criss-cross pattern, dividing the fat cell chambers into small, polygonal units. In women, fat cell chambers, or papillae adiposae, are sequestered by septa of connective tissue, positioned in a radial or diagonal manner, anchoring the dermis to the muscle fascia via the subcutaneous fat. The papillae adiposae of the subcutis bulge up into the dermis (sometimes close to the dermoepidermal junction), changing the gross appearance of the skin surface [31]. This condition (cellulite) can also be treated with laser lipolysis. In this latter indication, the use of the laser with other techniques such as physiotherapy, external ultrasound and autologous fat injections can lead to a greater improvement.

6.2 Laser-assisted lipoabdominoplasty

The lipoabdominoplasty is a relatively new surgical procedure based on the selective undermining of the abdominal flap in the superior medium line, preserving the perforating and lymph vessels almost completely, reducing the complications. The use of the internal laser represents another useful tool in this technique. The laser builds tunnels in the tissue facilitating the flap mobilization; disrupts the fat cells, and induces new collagen production with a consequent tissue retraction.

6.3 Lipomas and flaps

Large and giant lipomas can be effectively treated with the laser. Two effects are especially improved in these cases: cellular lysis and skin tightening. This is an alternative and less invasive option for the treatment of lipomas. Non-esthetic use of the internal Nd-YAG laser includes the treatment of fat flaps (it refines and contours flaps according to specific anatomical characteristics). This indication can be applied to breast reconstruction using the

rectus abdominal technique or in the improvement of tumoral and traumatic lesions previously reconstructed with cutaneous and adipose flaps to thin or to contour these flaps.

6.4 Sweat gland diseases

The subdermal approach for axillary hyperhidrosis, osmidrosis and bromidrosis treatment using a 1064 nm Nd-YAG laser results in significant clinical improvement. It is an alternative treatment option for these sweat gland disorders. Patients suffering from this condition indicate that their sweating is difficult to tolerate and frequently interferes in their daily activities or is intolerable and always interferes in their daily activities. Axillary hyperhidrosis, osmidrosis and bromidrosis has a strong negative impact on different domains of quality of life. It often interferes with patient's daily activities with occupational, emotional, social, and physical implications. Numerous treatments have been described to improve this condition. Topical antiperspirants such as acids, aldehydes, and metal salts; iontophoresis; botulinum toxin injections; anticholinergic and other drugs; surgeries; curettage; liposuction; and open or endoscopic sympathectomy represent some of the main treatment options. Each treatment presents advantages and limitations and, so far, there is no ideal option. Among the surgical methods, minimal skin excision combined with subcutaneous curettage is the gold standard in many countries, yet a major disadvantage of this method is the formation of operative scar and hematoma. Suction curettage in tumescent anesthesia is a less invasive method although the number of recurrences is higher. Sympathectomy has been reported to cause compensatory hyperhidrosis in up to 90% of patients. This highlights the need for further improvement of surgical treatments for the more severe cases. The laser energy acts directly on the anatomical location of the sweat glands. Subdermal action of laser is better than transcutaneous action, since the laser could reach its target directly and by only one small hole on the skin.

6.5 Gynecomastia

This is another interesting indication for the use of the subdermal Nd-YAG laser. The laser facilitates cannula penetration (very important mainly in glandular and fibrous tissue treatment). There is effective cellular disruption (lipolysis), and the small tunnels in the male breast tissue as well as the new collagen stimulation, help tissue retraction and attenuation of small breast ptosis or skin laxity. Also, in the case of glandular tissue (mixed gynecomastia), the laser can be applied with traditional glandular excision with limited scarring.

6.6 Wrinkles

The same principle – new collagen stimulation – can be applied to the improvement of wrinkles (subdermal application).

6.7 Treatment of permanent filler injections

Polymethylmethacrylate and other products have been used as synthetic permanent fillers for soft-tissue augmentation in the face and body. Complications related to these injections include tissue necrosis, local infections, granulomas, chronic inflammatory reactions, etc. Preliminary studies have shown excellent results using the intralesional application of the 1064 nm Nd-YAG laser in the treatment of these granulomas related to permanent fillers.

7. Typical cases of laser lipolysis

Case 1. Congenital localized adiposis.

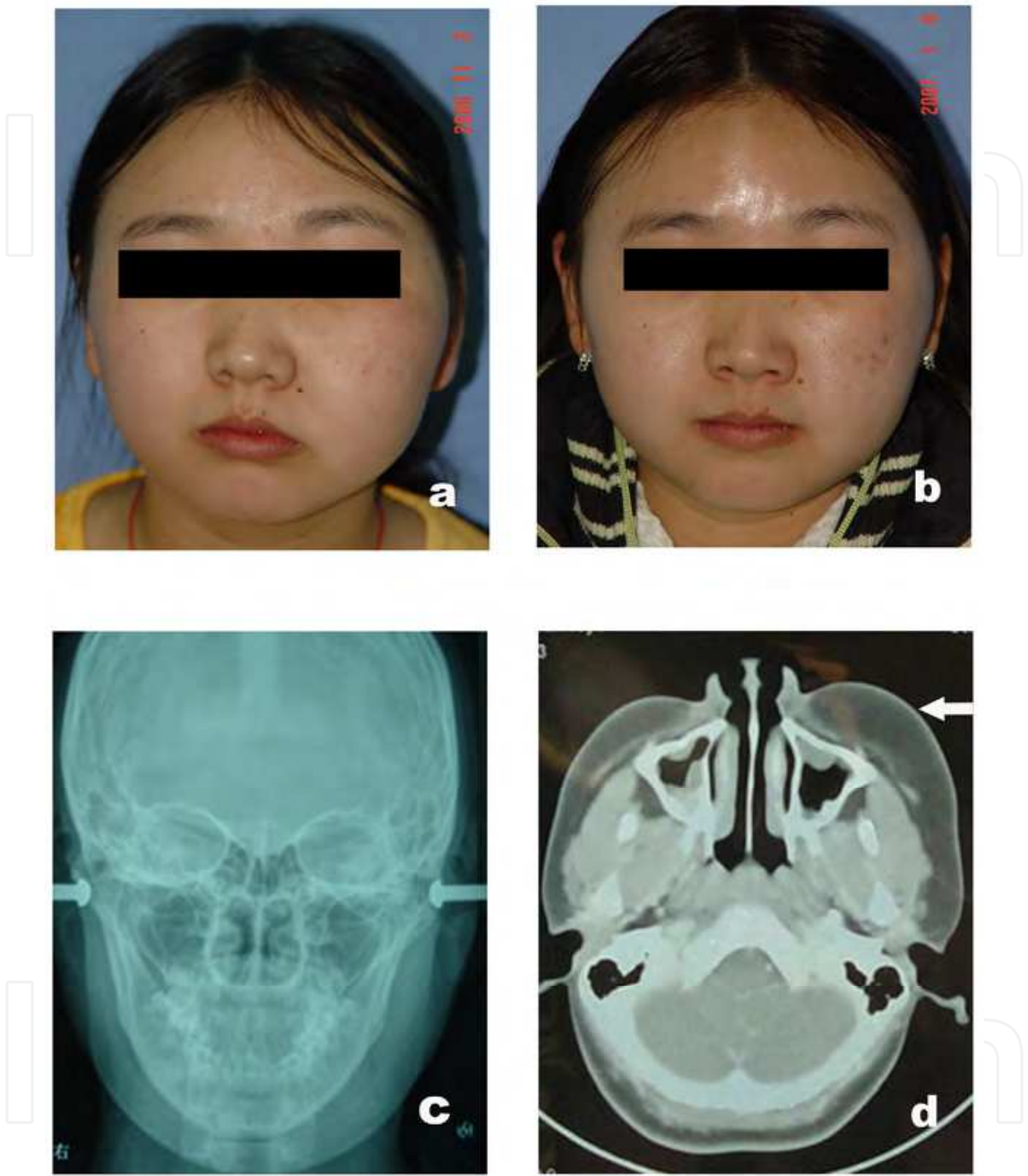


Fig. 5. a. The facial contour is asymmetric due to the congenital localized adiposis in the left face. Note that the left corner of the mouth is moved down. b. At 2 months after laser lipolysis, the enlarged adipose tissue has been removed; the asymmetry is significantly improved; and the corners of the mouth are symmetric. c. Anteroposterior x-ray of the skull before the operation. The bilateral maxilla and mandible are symmetric (arrows), whereas the soft tissues of the left face (asterisk) are obviously thicker than those of the right side. d. Magnetic resonance imaging (MRI) indicates the enlarged soft tissue on the left side of the face (asterisk), which basically consists of adipose tissue

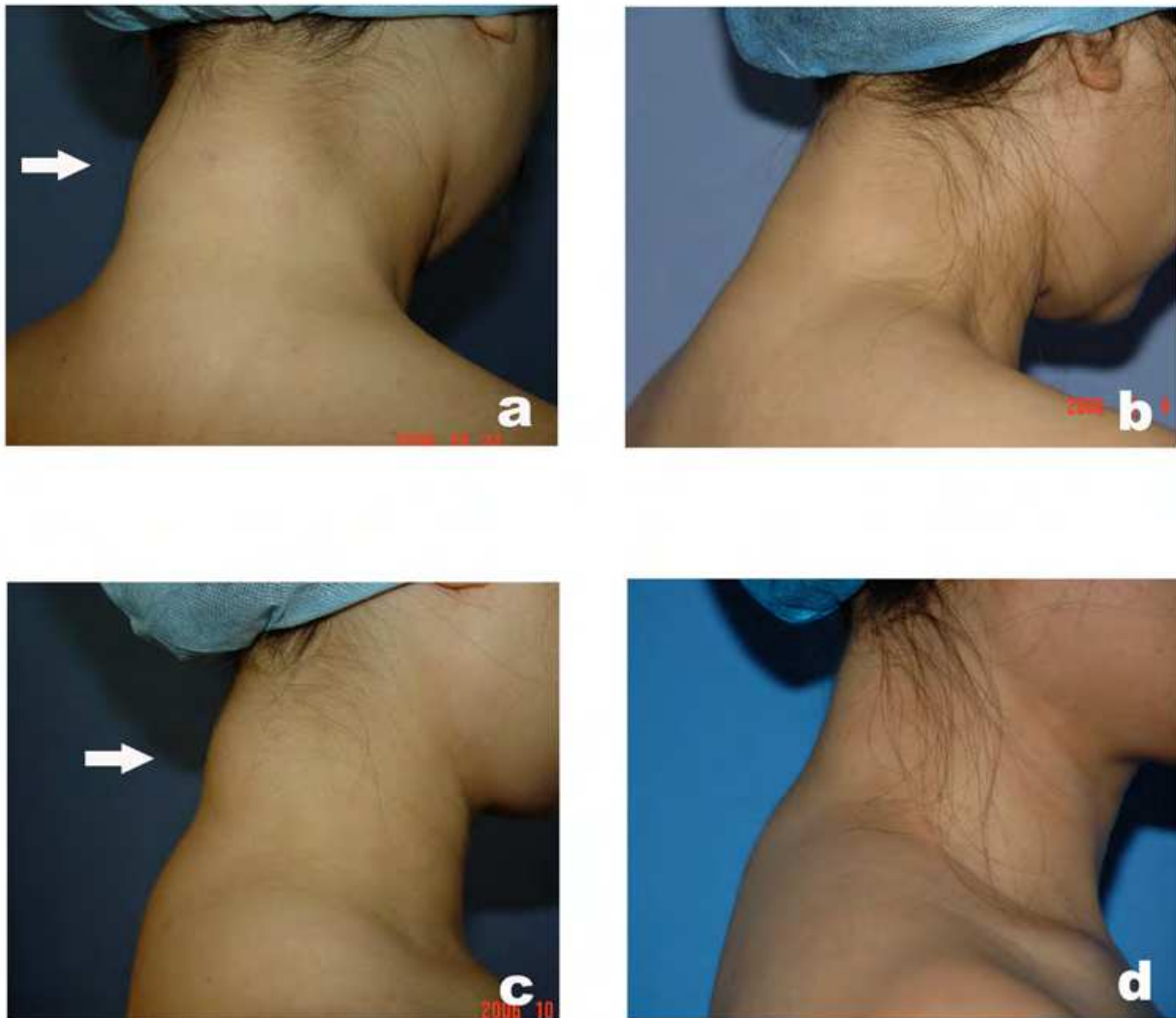
Case 2. Congenital subcutaneous fat pad in the neck.

Fig. 6. a Oblique view of the congenital subcutaneous fat pad in the neck (arrow). There is a prominent swelling in the middle part of the neck from the inferior border of the hairline to the superior border of the seventh cervical vertebrae. The swelling is hemispheric in shape. b Oblique view 20 months after laser lipolysis showing that the prominence of the fat pad is eliminated and that the overall contour is normal. c Lateral view of the congenital subcutaneous fat pad in the neck (arrow). d Lateral view of the patient 20 months after laser lipolysis

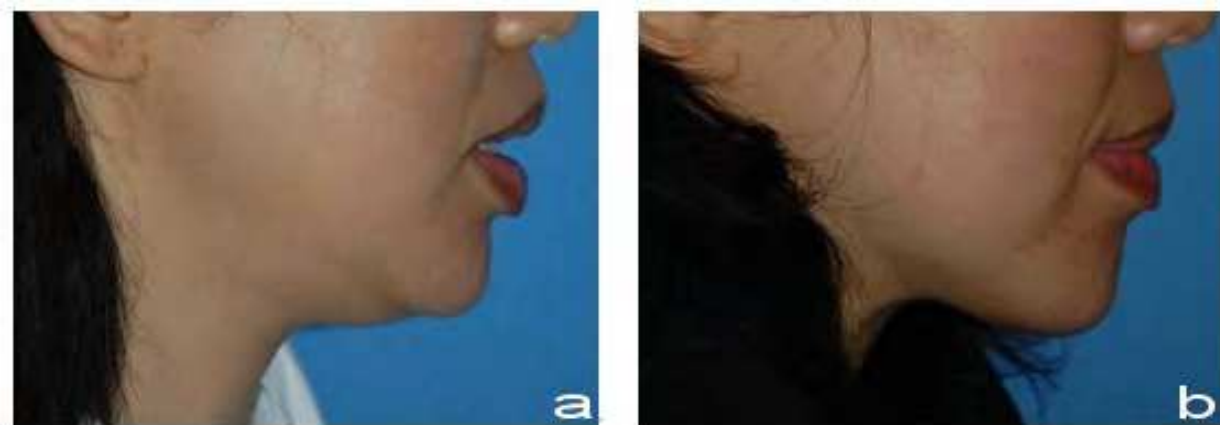Case 3. Submental adipose deposit.

Fig. 7. a. A female patient with adipose tissues deposit in her submental. b. Seven days after laser lipolysis shows great appearance.

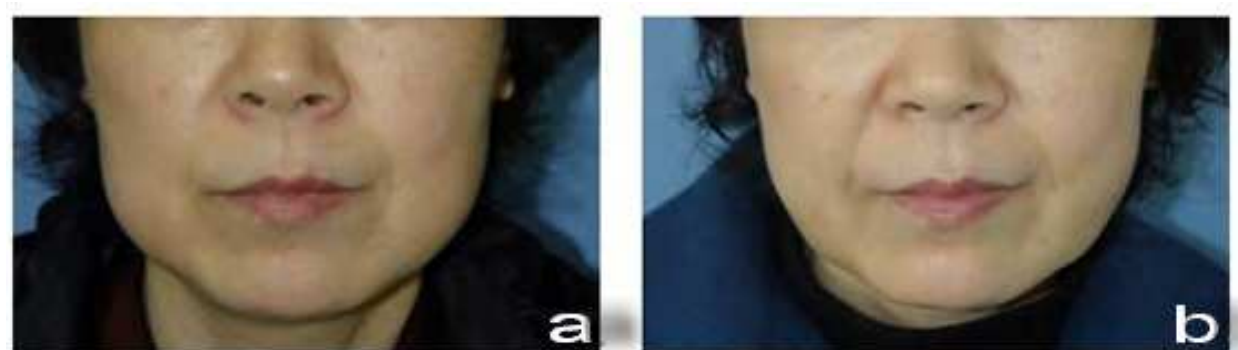
Case 4. Facial adipose deposit

Fig. 8. a. A female patient with adipose tissues deposit in her cheeks. b. The face contour of hers is tighten up after laser lipolysis.

Case 5. Adipose deposit in neck

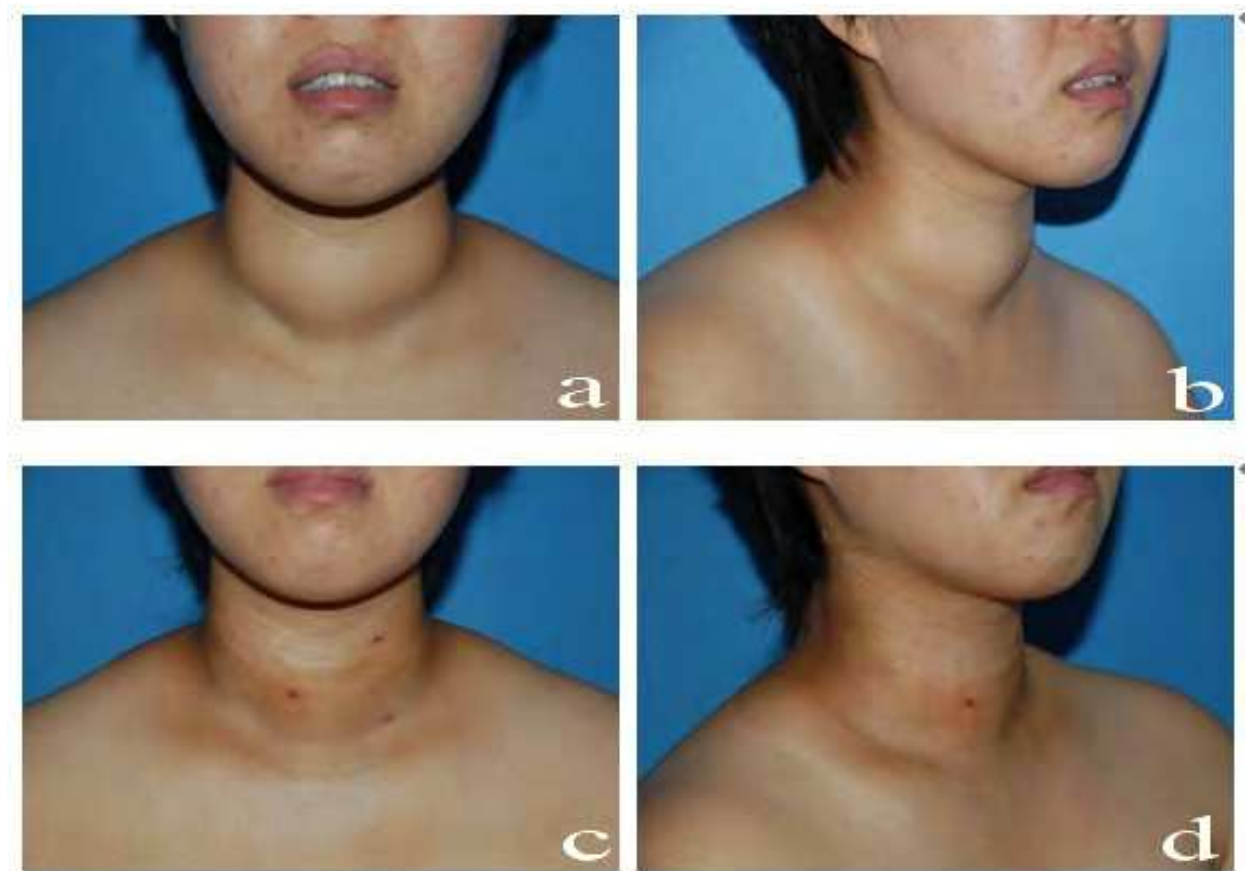

Fig. 9. a.b. A female patient with adipose tissues deposit in her front neck. c.d. One day after laser lipolysis.

Case 6. Adipose deposit in the arms

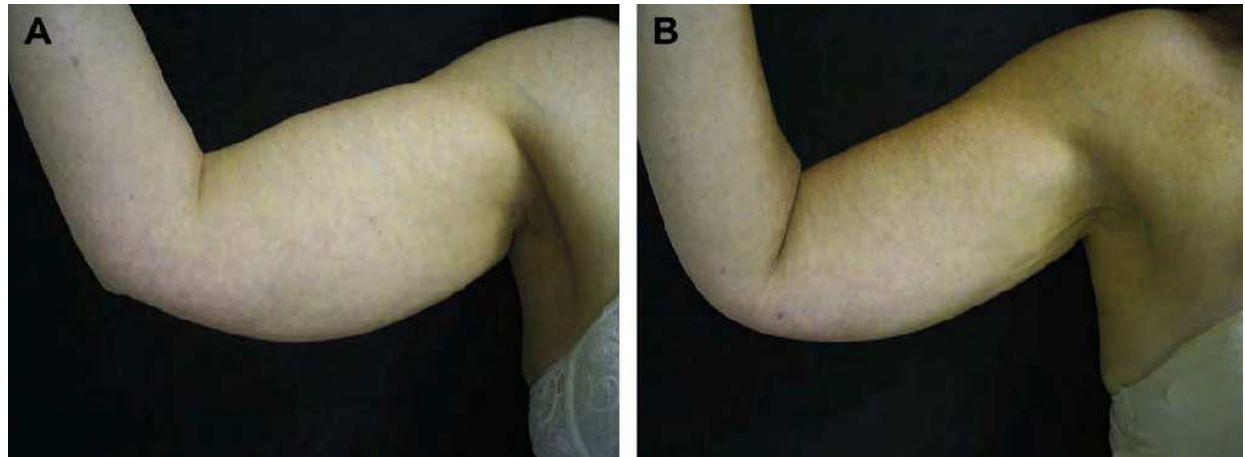


Fig. 10. 54-year-old woman is shown before (A) and 8 months after (B) laser-assisted liposuction of the arms.

Case 7. Adipose deposit in the abdomen and flanks.

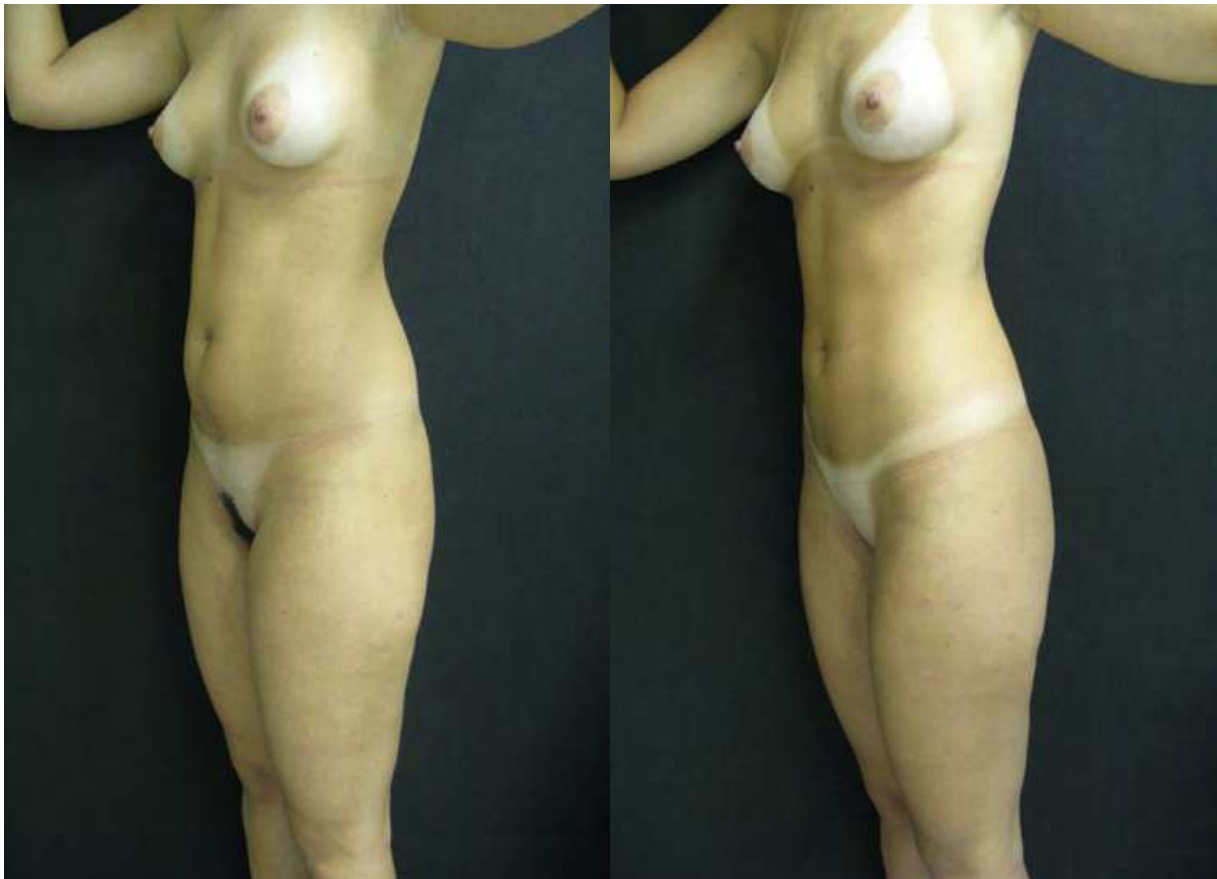

Fig. 11. 29-year-old woman is shown before (A, C) and 6 months after (B, D) laser-assisted liposuction of the abdomen and flanks.

Case 8. Adipose deposit in the abdomen, hips, and flanks.

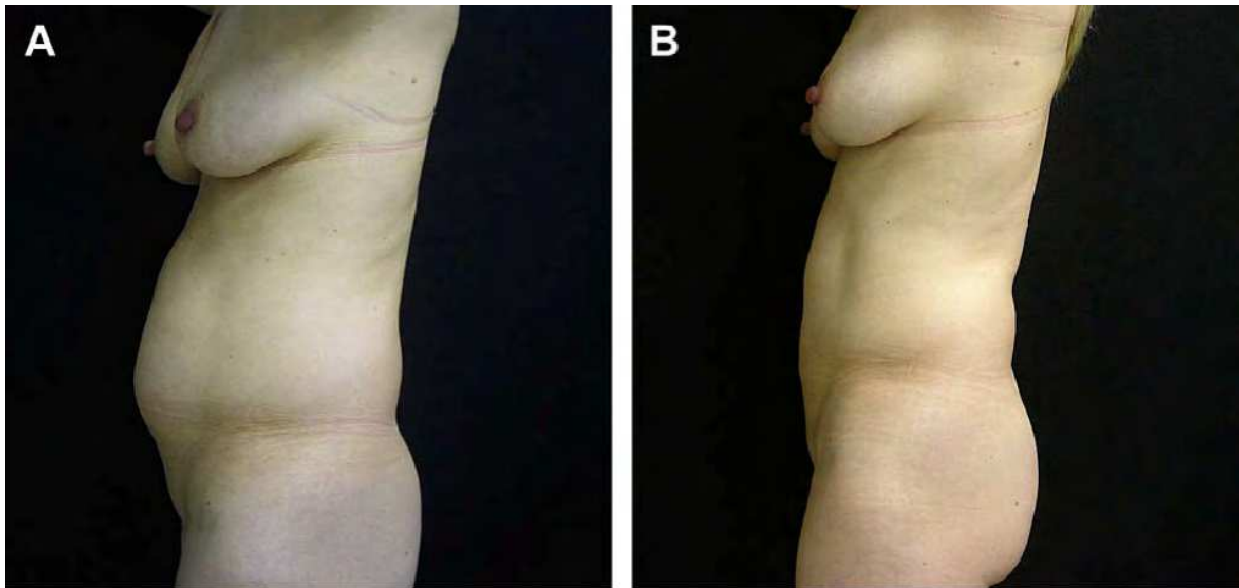


Fig. 12. 38-year-old woman is shown before (A, C) and 6 months after (B, D) laser-assisted liposuction of the abdomen, hips, and flanks.

Case 9. Adipose deposit in the hips.

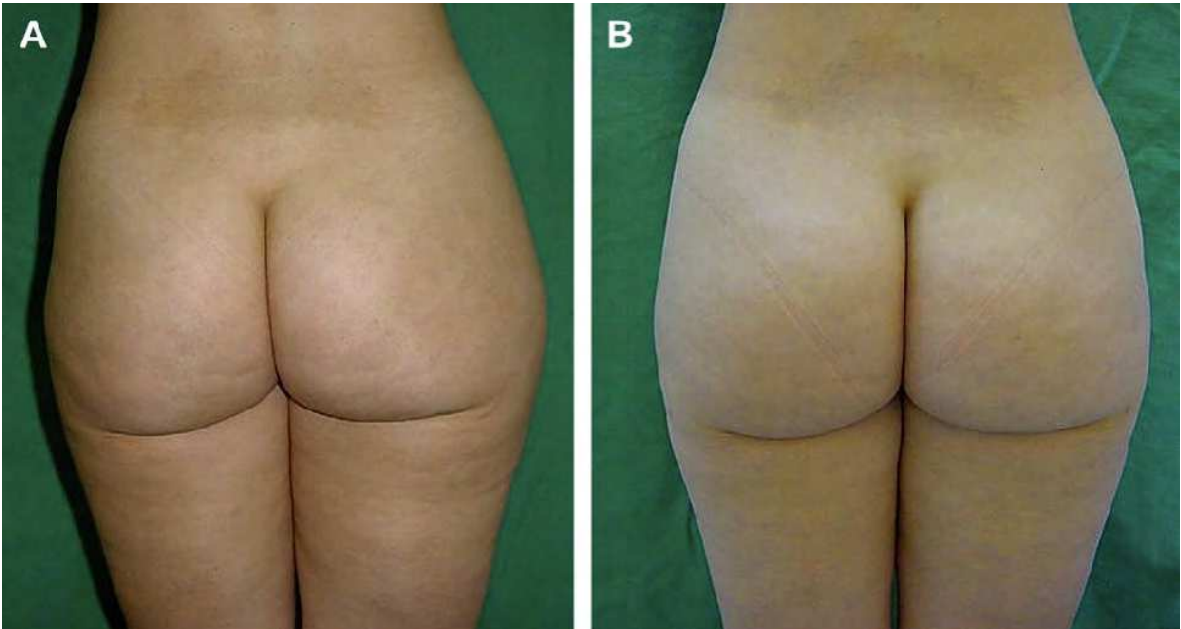


Fig. 13. 32-year-old woman is shown before (A) and 6 months after (B) laser-assisted liposuction of hips and thighs.

Case 10. Lipoma on the back.

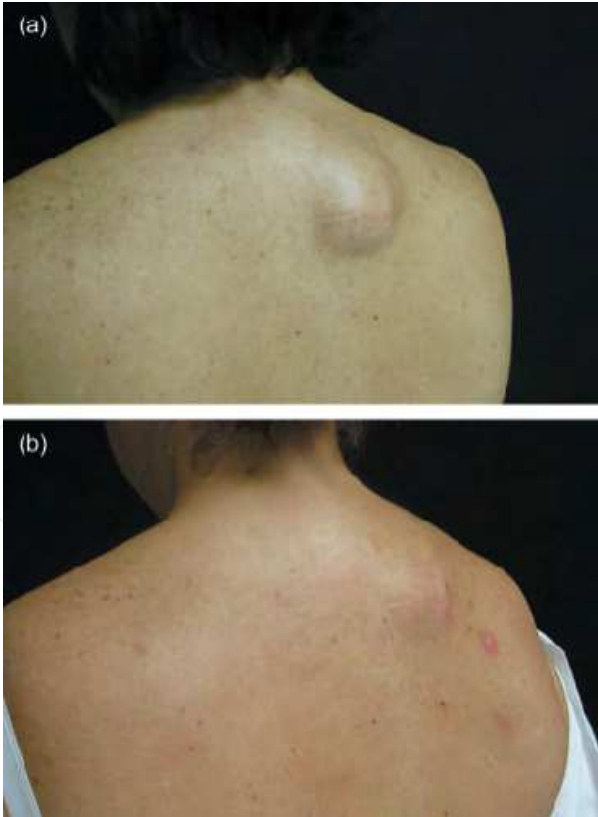

Fig. 14. (a) Lipoma on the back. Observe the scar produced by a previous surgical excision. (b) Five days after subdermal treatment with an Nd:YAGlaser. Edema and small scar.

Case 11. Axillary Hyperhidrosis.

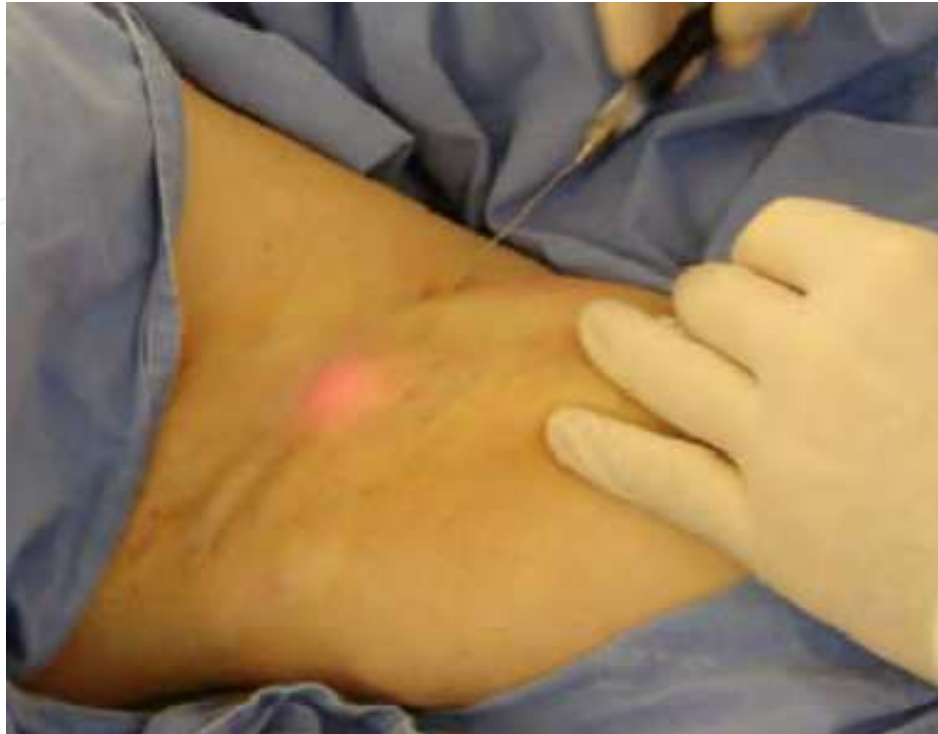

Fig. 15. Subdermal laser acting on the axillary region and the transillumination effect due to the red helium–neon laser. The incision was placed in a natural axillary fold.

8. Discussion

Lipolysis depends on the thermal effect of the laser. The laser can vaporize and melt tissues that it irradiates. Adipose tissues are located under the skin and above the deeper tissues, which include nerves and large vessels. It is very important to avoid excess tissue injury except for the target adipose tissue, especially in facial lipolysis. To achieve satisfactory therapeutic effects, the optimal energy of the laser should be set according to the regions of the treatment. The more fibrous and compact the tissues contained in the adiposis, the higher the laser energy density was needed. However, it was found that a long operation time was needed when laser lipolysis was applied in larger regions such as the abdominal wall. Therefore, laser lipolysis is more suitable for treating small regions and compact locations such as the face and cheeks, the mental region, the nuchal region, the upper arm, and the legs. Furthermore, it can also be used to improve local unevenness after conventional liposuction. Compared with the conventional liposuction technique, laser lipolysis has the following characteristics. The laser coagulates the small vessels and reduces the bleeding during the operation. Laser lipolysis has a well-distributed effect, and the skin surface is less uneven after the operation. Laser stimulates the formation of collagen in the region, which enhances the elasticity of the skin and facilitates the skin contraction in the operative regions. The laser breaks down the compact fibrous tissues of the localized adiposis, reduces the resistance of the suction cannula, and makes the operation easier. Finally, the trauma is mild, which brings a rapid recovery with fewer complications of edema, neural damage, and adipose embolism.

Laser lipolysis makes adipocytes rupture and shrink, with necrosis and carbonization. Reduction of the number of adipocytes improves the local shape, but the photothermal effect should also be controlled in a certain range. A variety of coagulation and other serious damage on lipocytes and collagen fibers must be taken into account. This method is suitable for small-scale, high-density area, and also unsatisfied areas after liposuction.

Although some negative or neutral views have been reported, most of the results have shown that laser lipolysis has the characteristics of less bleeding, pain, and edema; a quicker recovery; and better comfort. Most of the patients obtained satisfactory results, with significant reduction of localized fat. The clinical results have proved that laser lipolysis is an effective therapy for these patients. In subsequent histologic studies, the findings showed that the adipose cells had been damaged and "melted." Their cell membranes had shrunk, curled, or ruptured, leading to loss of integrity and shape of the cells, with consequent loss of cellular content.


9. Conclusion

Laser lipolysis is a new approach in the treatment of localized adiposis, which has satisfactory effects and potential clinical applications of other diseases. The approach is still in its initial stage, and the operation indications and criteria are not complete. Further studies and researches are needed to optimize the operation routes and methods.

10. References

- [1] Klein JA. Anesthesia for liposuction in dermatologic surgery. *J Dermatol Surg Oncol*. 1988 Oct; 14(10):1124-1132.
- [2] Klein JA. Tumescence technique for local anesthesia improves safety in large volume liposuction. *Plast Reconstr Surg*. 1993 Nov; 92(6):1085-1098.
- [3] Zocchi ML. Ultrasonic liposculpturing. *Aesthetic Plast Surg*. 1992; 16:287-298.
- [4] Maxwell GP, Gingrass MK. Ultrasound-assisted lipoplasty: A clinical study of 250 consecutive patients. *Plast Reconstr Surg*. 1998 Jan; 101(1):189-202.
- [5] Zocchi ML. Ultrasonic-assisted lipectomy. *Adv Plast Reconstr Surg*. 1995; 11:197.
- [6] Silberg BN. The technique of external ultrasound-assisted lipoplasty. *Plast Reconstr Surg*. 1998 Feb; 101(2):552.
- [7] Fodor PB, Vogt PA. Power-assisted lipoplasty (PAL): A clinical pilot study comparing PAL to traditional lipoplasty (TL). *Aesthetic Plast Surg*. 1999 Nov-Dec; 23(6):379-385.
- [8] Apfelberg DB. Laser-assisted liposuction may benefit surgeons, patients. *Clin Laser Mon*. 1992 Dec; 10(12):193-194.
- [9] Apfelberg DB, Rosenthal S, Hunsted JP, et al. Progress report on multicenter study of laser-assisted liposuction. *Aesthetic Plast Surg*. 1994 Summer; 18(3):259-264.
- [10] Apfelberg DB. Results of multicenter study of laser-assisted liposuction. *Clin Plast Surg*. 1996 Oct; 23(4):713-719.
- [11] Neira R, Solarte E, Reyes MA, et al. Low-level laser-assisted lipoplasty: A new technique. In: *Proceedings of the World Congress on Liposuction*. Dearborn, MI: 2000.
- [12] Neira R, Arroyave J, Ramirez H, et al. Fat Liquefaction: effect of low-level laser energy on adipose tissue. *Plast Reconstr Surg*. 2002 Sept; 110(3):912-922.

- [13] Neira R, Ortiz-Neira C. Low-level laser-assisted liposculpture: Clinical report of 700 cases. *Aesthetic Plast Surg.* 2002 Sept-Oct; 22(5):451-455.
- [14] Neira R, Toledo L, Arroyave J, et al. Low-level laser-assisted liposuction: the Neira 4L technique. *Clin Plast Surg.* 2006 Jan; 33(1):117-127.
- [15] Blugerman, G. Laser lipolysis for the treatment of localized adiposity and "cellulite." In: *Abstracts of the World Congress on Liposuction.* Dearborn, MI: 2000.
- [16] Schavelzon D, Blugerman G, Goldman A, et al. Laser lipolysis. In: *Abstracts of the 10th International Symposium of Cosmetic Laser Surgery.* Las Vegas, NV: 2001.
- [17] Goldman A, Schavelzon DE, Blugerman GS. Laser lipolysis: liposuction using Nd:YAG laser. *Rev Soc Bras Cir Plast.* 2002 Jan-Apr; 17(1):17-21.
- [18] Goldman, A. Lipoaspiração a laser - laserlipólise no contorno corporal. *Revista Brasileira de Cirurgia.* 92, 2002.
- [19] Goldman, A., Schavelzon, D., Blugerman, G. Laserlipólise - lipoaspiração com Nd:YAG laser. *Revista da Sociedade Brasileira de Laser em Medicina e Cirurgia.* 2(5), 2002.
- [20] Goldman A, Schavelzon D, Blugerman G. Liposuction using neodymium:yttrium-aluminum-garnet laser. *International Abs. Plast Reconstr Surg.* 2003 June; 111(7):2497.
- [21] Badin AZD, Moraes LM, Gondek LB, et al. Laser lipolysis: Flaccidity under control. *Aesthetic Plast Surg.* 2002 Sept-Oct; 26(5):335-339.
- [22] Goldman, A., Submentale Laserassistierte Liposuktion: Klinische Erfahrungen und Histologische Ergebnisse, *Kosmetische Medizin* 3:5 4-11, 2005
- [23] Badin AZD, Gondek LB, Garcia MJ, et al. Analysis of laser lipolysis effects on human tissue samples obtained from liposuction. *Aesthetic Plast Surg.* 2005 Jul-Aug; 29(4):281-286.
- [24] Goldman A. Submental Nd:YAG laser-assisted liposuction. *Lasers Surg Med.* 2006 Mar; 38(3):181-184.
- [25] Wollina U, Goldman A, Berger U, et al. Esthetic and cosmetic dermatology. *Dermatol Ther.* 2008; 21:118-130.
- [26] Goldman A, Wollina U. Subdermal Nd-YAG laser for axillary hyperhidrosis. *Dermatol Surg* 2008; 34:756-762.
- [27] Goldman A, Gotkin RH, Sarnoff DS, et al. Cellulite: A new treatment approach combining sub-dermal Nd:YAG laser lipolysis and autologous fat transplantation. *Aesthetic Surg J.* 2008 (in press).
- [28] Björntorp P. Adipose tissue distribution and function. *Int J Obes.* 1991 Sep;15 Suppl 2:67-81.
- [29] Anderson RR, Parrish JA. Selective photothermolysis: precise microsurgery by selective absorption of pulsed radiation. *Science.* 1983 April 29; 220:524-527.
- [30] Goldman A, Gotkin RH, Sarnoff DS, et al. Cellulite: A new treatment approach combining sub-dermal Nd:YAG laser lipolysis and autologous fat transplantation. *Aesthetic Surg J.* J 2008;28:656-662.
- [31] Sun Y, Wu SF, Yan S, et al. Laser lipolysis used to treat localized adiposis: a preliminary report on experience with Asian patients. *Aesthetic Plast Surg.* 2009;33:701-705.



Advanced Techniques in Liposuction and Fat Transfer

Edited by Prof. Nikolay Serdev

ISBN 978-953-307-668-3

Hard cover, 230 pages

Publisher InTech

Published online 12, September, 2011

Published in print edition September, 2011

Liposuction is the first cosmetic procedure to change beautification surgery from open extensive excision surgery into a more atraumatic closed one. It gave rise to the modern understanding of minimally scarring and minimally invasive surgery and changed the understanding and preferences of both patients and doctors. It also became the most common procedure in cosmetic surgery world-wide, practiced by an increased number of physicians from various specialties. The techniques of fat grafting, closely bound with liposuction, have found widespread application and fat stem cells seem to be changing the future of many areas in medicine. Turning the pages, the reader will find a lot of information about advances, tips and tricks, as well as important milestones in the development of the different methods available, such as classic, power, ultrasound, laser and radio-frequency assisted liposuction etc. Most useful anesthesia techniques are described and discussed, and guidelines have been established for medical indications. Special attention is paid to good patient selection, complications and risks.

How to reference

In order to correctly reference this scholarly work, feel free to copy and paste the following:

Alberto Goldman, Sufan Wu, Yi Sun, Diego Schavelzon and Guillermo Blugerman (2011). Gynoid Lipodystrophy Treatment and Other Advances on Laser-Assisted Liposuction, *Advanced Techniques in Liposuction and Fat Transfer*, Prof. Nikolay Serdev (Ed.), ISBN: 978-953-307-668-3, InTech, Available from: <http://www.intechopen.com/books/advanced-techniques-in-liposuction-and-fat-transfer/gynoid-lipodystrophy-treatment-and-other-advances-on-laser-assisted-liposuction>

INTech
open science | open minds

InTech Europe

University Campus STeP Ri
Slavka Krautzeka 83/A
51000 Rijeka, Croatia
Phone: +385 (51) 770 447
Fax: +385 (51) 686 166
www.intechopen.com

InTech China

Unit 405, Office Block, Hotel Equatorial Shanghai
No.65, Yan An Road (West), Shanghai, 200040, China
中国上海市延安西路65号上海国际贵都大饭店办公楼405单元
Phone: +86-21-62489820
Fax: +86-21-62489821

© 2011 The Author(s). Licensee IntechOpen. This chapter is distributed under the terms of the [Creative Commons Attribution-NonCommercial-ShareAlike-3.0 License](https://creativecommons.org/licenses/by-nc-sa/3.0/), which permits use, distribution and reproduction for non-commercial purposes, provided the original is properly cited and derivative works building on this content are distributed under the same license.

IntechOpen

IntechOpen