

We are IntechOpen, the world's leading publisher of Open Access books Built by scientists, for scientists

6,900

Open access books available

186,000

International authors and editors

200M

Downloads

Our authors are among the

154

Countries delivered to

TOP 1%

most cited scientists

12.2%

Contributors from top 500 universities



WEB OF SCIENCE™

Selection of our books indexed in the Book Citation Index
in Web of Science™ Core Collection (BKCI)

Interested in publishing with us?
Contact book.department@intechopen.com

Numbers displayed above are based on latest data collected.
For more information visit www.intechopen.com



The use of Confocal Scanning Laser Tomography in the Evaluation of Progression in Glaucoma

Liamet Fernández Argones, Ibraín Piloto Díaz, Marerneda Domínguez
Randulfe, Germán A. Álvarez Cisneros and Marcelino Río Torres
*Cuban Institute of Ophthalmology, Havana,
Cuba*

1. Introduction

Monitoring of glaucomatous damage is critical in a modern glaucoma practice. Confocal scanning laser tomograph or Heidelberg Retina Tomograph (HRT) is one of the imaging techniques that allow clinicians to examine more patients and to obtain objectives measurements compared to the gold standard of optic disc stereo- photography.

It employs a diode laser with a wavelength of 670nm. In a confocal optical system light can only reach the photo detector if it is reflected from a narrow area surrounding the set focal plane. Light reflected outside of the focal plane is highly suppressed (Heidelberg Engineering, 2005).

A two- dimensional sector of the retina is scanned sequentially. The amount of reflected light at each point is measured using a light sensitive detector. To obtain a topography image (three- dimensional image), the height of the retinal surface is computed at each point (Heidelberg Engineering, 2005).

Analysis of glaucomatous progression is performed with the HRT operating software by quantitatively describing temporal changes of the optic nerve head topography. It is particularly important as glaucoma progression occurs slowly and changes often are subtle and missed easily. The HRT has the advantage that the new technology enables backward compatibility. So progression can be analysed since the introduction of the first HRT (HRT Classic).

2. Progression analysis

2.1 Basis for a confident progression analysis

During the progression analysis the follow- up exam and the baseline are compared. To ensure that differences between the images are for glaucomatous progression and not for imaging conditions, the image quality, the alignment and normalization procedures should be addressed.

The control label of good or better must be present in all the images (defined as a scan standard deviation less than 30 μm). It means that the three 15° scans used to generate a mean topographic image are uniform. For each pixel in the topography image, the standard

deviation of the pixel height is calculated from the three scanned images and then averaged over the entire topography image (Heidelberg Engineering, 2005).

The image quality can be affected by age, incorrectly adjusted refraction, eye movement, dry eye, size of the pupil, media opacity or other physical characteristics of the eye. It is recommended to perform HRT scan before other diagnostic measures are taken. In dry eyes artificial tear fluid can be applied shortly before the examination while ointments, fluorescein, among others should be avoided. If the pupil diameter is smaller than 3 mm or if image quality is thought to be affected by media opacity, the pupil should be dilated with 0.5% tropicamide (Sihota et al., 2002; Heidelberg Engineering, 2005; Strouthidis & Garway-Heath, 2008; Fogagnolo et al., 2011). The good quality of images is determinant for the accuracy of the HRT progression analysis (figure 1).

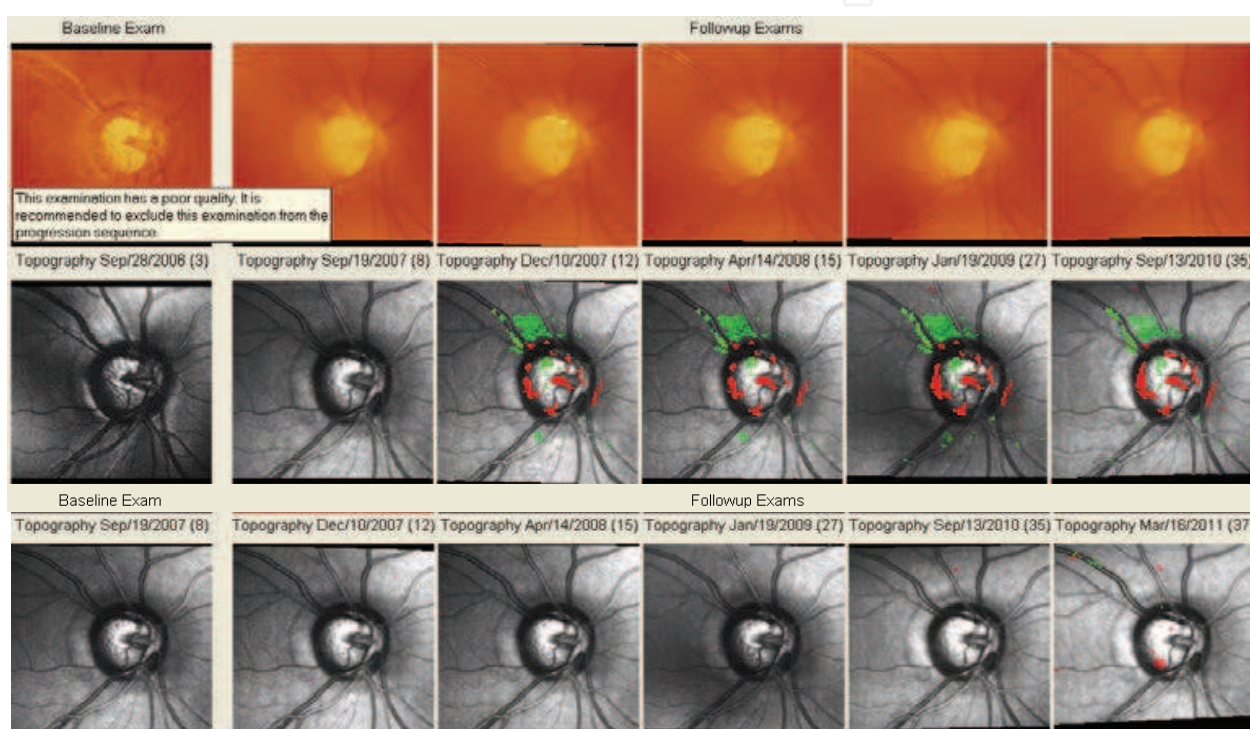


Fig. 1. This figure illustrates the importance of a good quality image in the progression analysis. The two superior rows show the difficulties in the evaluation of glaucomatous progression generated by a poor quality baseline. The inferior row shows the result when a poor quality image is excluded of the progression sequences.

The HRT has the ability to monitor quality control during follow-up image acquisition. There is a warning message which starts to blink if the current focus setting differs from the previous setting. There is also a blue frame which appears close to the line image margin, with a blue cross located in the center of the optic disc live image when the same retinal region as the baseline examination is adjusted (Heidelberg Engineering, 2005).

After the examination, a quickly view to the follow-up images may give information about the quality of the alignment. Black margins around the image appear when the optic nerve head is not centered (figure 2).

For the progression analysis based on stereometric parameters the demarcation of contour line is essential. It is manually located along the inner edge of the scleral (Elschnig's) ring by the operator. The margin of the optic disc is used as a reference. The contour line can be

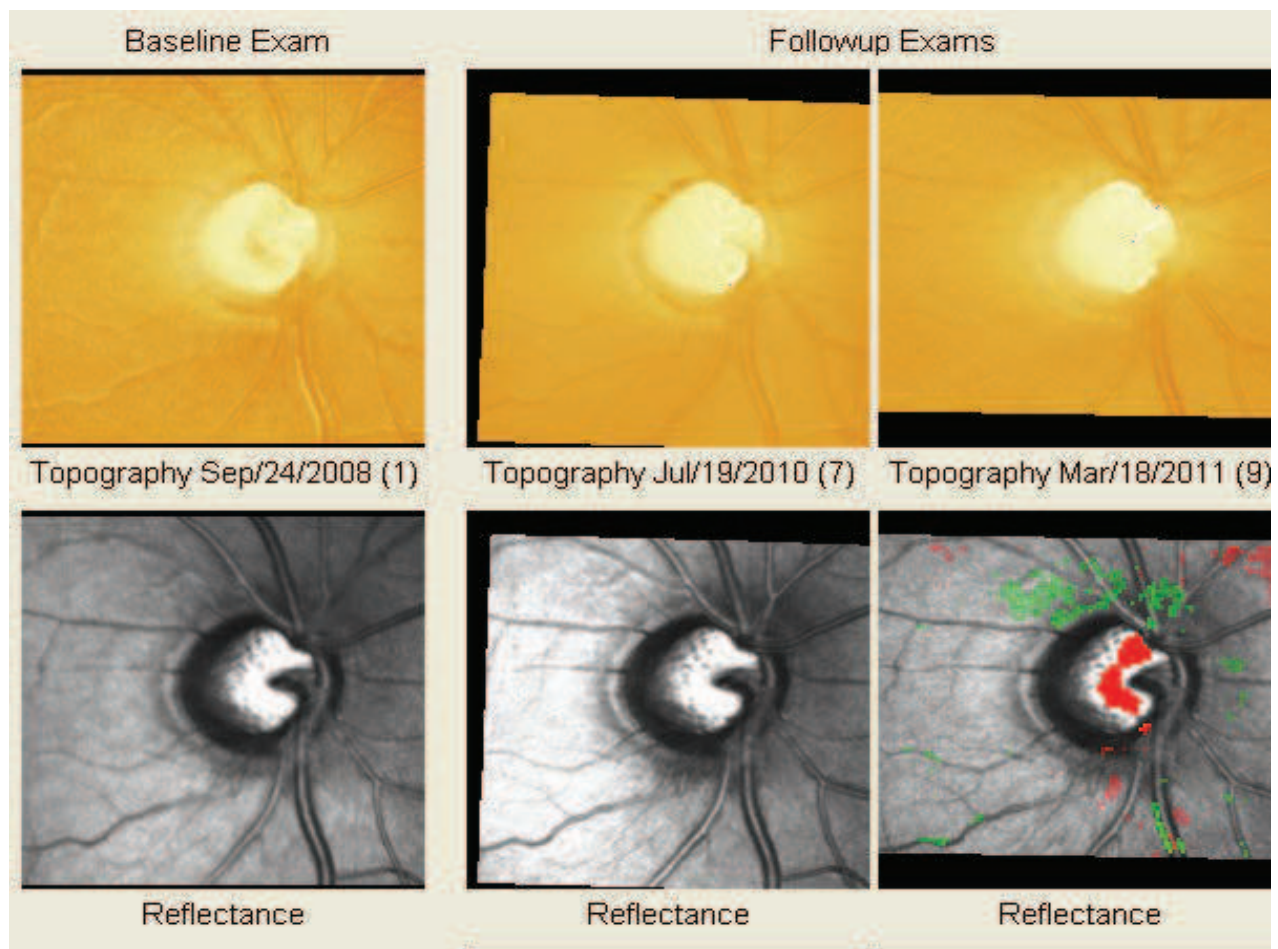


Fig. 2. Black margins around the images as a result of bad alignment during follow-up image acquisition. May be the image differences are due to different imaging conditions.

modified at any time later on. Every modification of the contour line in the baseline or follow-up examinations is transferred directly to all other examinations. Excluding a baseline examination results in the loss of the contour line. This will delete the stereometric parameter until a new contour line is drawn (Heidelberg Engineering, 2005).

The reference plane is parallel to the peripapillary retinal surface and located 50 μm below the retinal surface at the contour line and in the papillomacular bundle ($350^\circ - 356^\circ$). It is used to define structures above the plane as "rim" and below as "cup." In general, stereometric parameters are strongly influenced by the position of the reference plane. (Kamal et al., 2000; Tan et al., 2003a; Strouthidis et al., 2005a; Breusegem et al., 2008). It has been reported that the 320 μm plane, which is offset from the reference ring in the image periphery, is less likely to be affected by disease severity, resulting in more stable rim area measurements (Deleon et al., 2007).

Image acquisition-induced variability seemed larger than operator-induced variability (Miglior et al., 2002). Some factors such as image quality and the noise of HRT measurements, among others, influence the results (Owen et al., 2006; Bowd et al., 2009). It has been described that in some eyes, the optic nerve head is more elevated at the lower pressure (Harju et al., 2008; Vizzeri et al., 2011). On the other hand, it was found that intraocular pressure increases and decreases on the order of 5 mm Hg did not appear to have an effect on optic disc topography (Nicolela et al., 2006).

A follow-up examination is automatically normalized to its baseline examination. The six images are aligned and normalized to each other. It includes correction of displacement, rotation, tilt, magnification and prospective changes. It ensures that differences between the images that are due to different imaging conditions are eliminated and that baseline and follow-up examinations can be compared to detect glaucomatous progression. The Glaucoma Module 3.0 software uses an enhanced automatic alignment and normalization procedure, which is likely to improve progression analyses, both for assessment of surface height change by topographical change analysis, and serial analysis of stereometric parameters (Heidelberg Engineering, 2005; Strouthidis & Garway-Heath, 2008).

In rare cases, the automatic alignment procedure may not be able to precisely align the images. As a result, the contour line appears misplaced in the follow-up examination. To resolve this, a manual alignment procedure may be used (Heidelberg Engineering, 2005).

It is highly recommended to start a new progression analysis after any kind of invasive surgery, as this will modify the optic properties of the eye. The images before and after the surgery are not comparable to each other in most cases (Heidelberg Engineering, 2005).

When the baseline and the follow-up image are optimal to be compared, it is time to looking for glaucomatous progression by the Topographic Change Analysis and by the changes on Stereometric Parameters over time.

2.2 Topographic Change Analysis (TCA)

The most important method to detect glaucomatous progression is the TCA. It is a technique that compares the variability within a baseline examination to that between baseline and follow-up examinations. It is independent of the optic disc head contour line and it takes the chronologically oldest follow-up examinations as the baseline.

The software compares the “within variability” of all baseline and follow-up examination with the “pooled variability” of all baseline and follow-up examinations. If the pooled variability of all baseline and follow-up examinations is significantly increased, then there is a height change at the corresponding location. Super pixels with an error probability of less than 5% for rejecting the equal variances hypothesis indicate a significant change at the corresponding location (Heidelberg Engineering, 2005; Strouthidis & Garway-Heath, 2008) (figure 3).

A region of at least 20 super pixels with significant changes in surface height that are connected to each other is called a cluster. With the cluster analysis, it is possible to evaluate the temporal change of the size and the amount of change in a cluster of significant super pixels. For the computation of the cluster volume, all super pixels inside the cluster boundaries are considered, but only the significant super pixels inside the cluster boundaries contribute to the cluster area (Heidelberg Engineering, 2005; Strouthidis & Garway-Heath, 2008) (figure 3). The largest clustered super pixel area within the optic disc margin was the TCA parameter providing the best sensitivity/specificity tradeoff for the detection of glaucomatous progression. Authors suggested early progression detection using TCA (Bowd et al., 2009).

The TCA Cluster Change- Graph (figure 4) displays changes in cluster volume (red, right vertical axis) and cluster area (blue, left vertical axis) over time for all follow-up examinations compared to the baseline exam.

To successfully appreciate the follow-up information given by TCA it is necessary to know the following reproducibility rules: in the first follow-up exam no results is displayed, in the second follow-up exam only changes reproducible over both two follow-up exams are

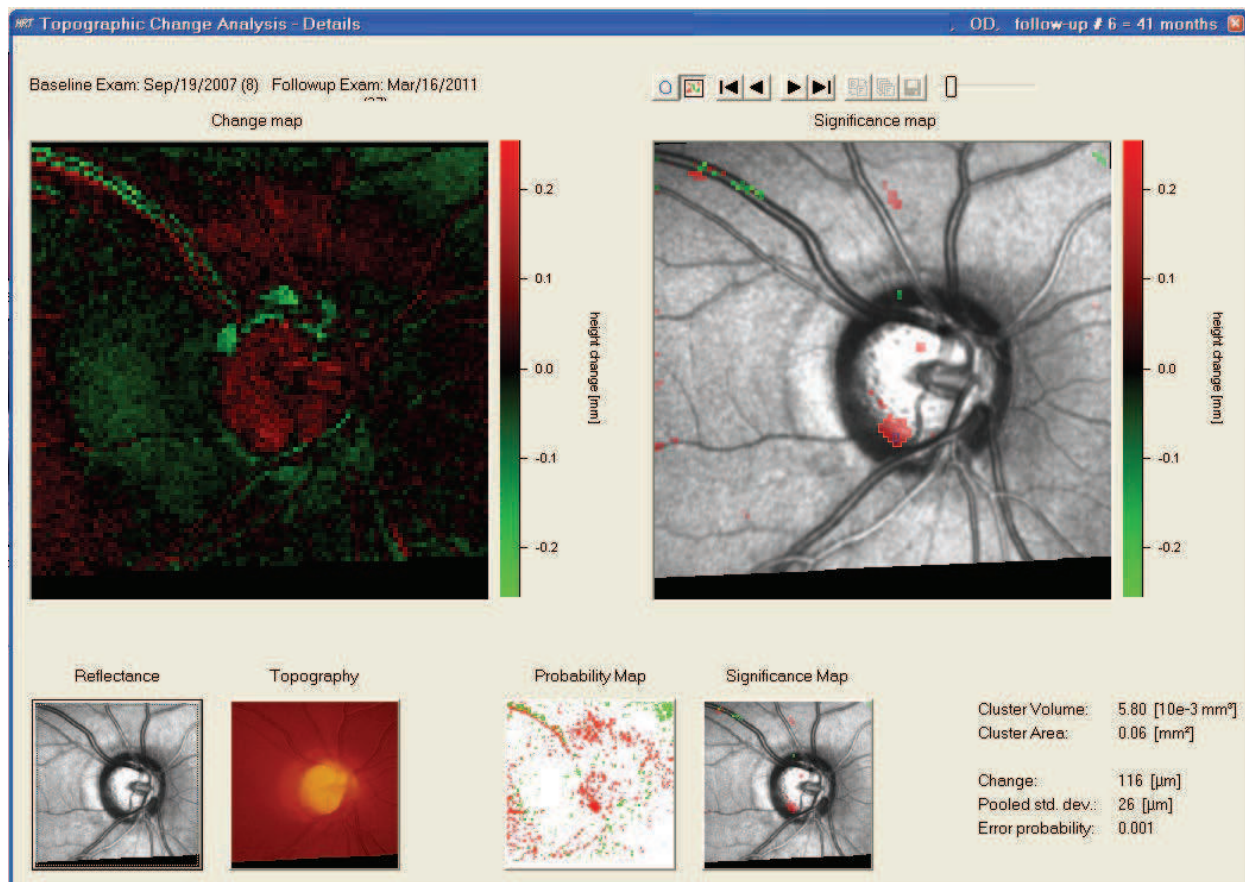


Fig. 3. Topographic Change Analysis- Details. It appears when double- click in an image of the progression sequence. It shows the cluster in the significance map (color red). The cluster volume and area are displayed on the right- inferior corner. The change of the local surface height in microns of the selected super pixel and the probability error of this change (corresponding to the current position of blue circle inside the cluster) are displayed below.

displayed, in the third follow- up exam only changes reproducible over all three follow- up exams are displayed, and in the further follow- up exam only changes reproducible in any three out of the last four follow- up exams are displayed (Heidelberg Engineering, 2005) (figure 4).

It has been suggested that significant TCA change may precede the visible progression by stereophotograph or by currently available visual field-based progression detection techniques (Chauhan et al., 2001; Budenz et al., 2006; Strouthidis & Garway-Heath, 2008; Bowd et al., 2009; Vizzeri et al., 2009; Asaoka et al., 2009). The TCA has demonstrated that it performs at least as well as either the individual or best combination of observer for detecting progressive glaucomatous disc changes of disc photographs (Chauhan et al., 2009). It has been considered that assessment of the HRT and stereophotography may be identifying different aspects of structural change. Some eyes progressing by TCA alone may have only areas of surface height change, which is less easily appreciated from photographs (Kourkoutas et al., 2007; Strouthidis & Garway-Heath, 2008). On the other hand, stereophotographic examination can assesses certain features of the optic disc, such as rim

pale, splinter haemorrhages, Alfa and Beta-Zone parapapillary atrophy, among others; that are important to evaluate the individual risk for progression (Budenz et al., 2006; Teng et al., 2010) (figure 5).

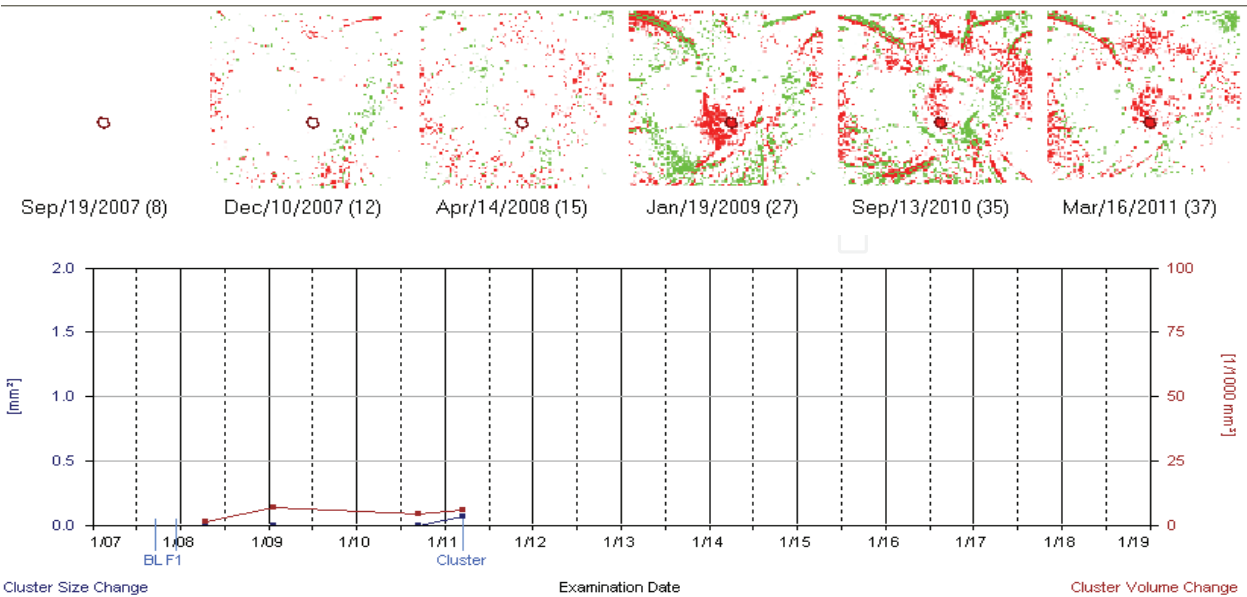


Fig. 4. Probability map and TCA Cluster Change- Graph. The TCA Cluster Change- Graph appears when double- click in a cluster area. Real progression of glaucomatous damage at the inferior- temporal cup is suspected in the right eye of the patient showed in figure 1. When there are more than four exams only significant changes reproducible in any three out of the last four follow-up are displayed (cluster delineated by a blue circle first appeared in the probability map in 2009 while it was first displayed in the significance map superimposed on the reflectance image in 2011).

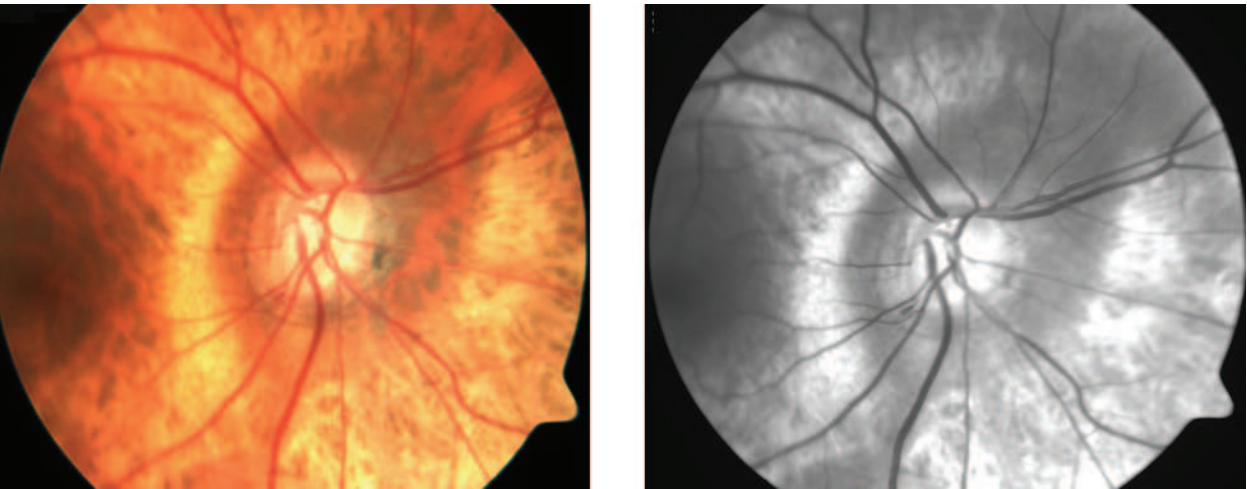


Fig. 5. Colour and red free photograph of the optic disc and retinal nerve fiber layer in a glaucomatous patient. A splinter haemorrhage is present at the inferior optic disc margin.

Results suggested that ideal parameters for separating glaucomatous and healthy groups are small clusters (between 1% and 2% of disc areas), with shallow depth changes (20–50 μm) (Bowd et al., 2009). Using the same cluster size in small and in large optic disc may cause that the required change has to be relatively bigger in small disc. TCA may fail to identify progressive structural damage in case of large disc with narrow neuro- retinal rim or in the presence of advanced optic nerve head damage with little anatomic reserve (Martinez de la Casa et al., 2006; Hudson et al., 2007).

At present, TCA progression alone should not indicate a treatment change. HRT change must be evaluated in conjunction with other clinical features of deterioration before altering therapy (Kourkoutas et al., 2007).

2.3 Glaucomatous progression in stereometric parameters

The progressions of stereometric parameters can be assessed by monitoring the change in a particular stereometric parameter over time, the event analysis, the trend analysis and different algorithms that have been described.

The event analyses identify progression when a measurement exceeds a predetermined criterion for change (or an event); it is assumed that any change below the criterion represents measurement variability and that changes above the criterion represent true disease change.

The trend analysis examines the change of stereometric parameters over time, with each value being normalized by using the ratio of the difference between a given value and baseline to the difference between the average value in a normal eye and an eye with advanced glaucoma. It does not give a statistical analysis of the rate of change (Strouthidis & Garway-Heath, 2008).

It is recommended a minimum of 7-8 images to increase the accuracy in the detection of progression, although a downward tendency in three consecutively images is suggestive of change. Using the downward tendency of more that 0.05 (normalized parameter value) in three consecutively image, as the criterion of progression, the specificity is increased to more that 90% (Martinez de la Casa et al., 2006).

Two progression algorithms assessing rim area change have been described: a trend analysis based on linear regression of sector rim area over time (Strouthidis et al., 2006) and an event analysis based on defining the criteria for change according to sector rim area coefficient of repeatability (Fayers et al., 2007). For both algorithms authors concluded that poor agreement exists between HRT rim area progression and visual field progression and suggested that on a practical level, both structural and functional measures need to be monitored to have the best chance of identifying glaucomatous progression.

The greatest challenge in detecting progression is the ability to discriminate true change (disease process) from measurement variability.

A difference of 10% or more in the standard reference height compared with the baseline is considered excess variability. It has been identified that excess standard reference height variability (average 24%) does occur in a considerable proportion of follow-up HRT 3 scans (46% of all HRT 3 scans) and that more than half the variability in retinal nerve fiber layer, rim area, and rim volume could be attributed to variability in the standard reference height (Breusegem et al., 2008). Increased test-retest variability is associated with the degree of

glaucomatous damage even after taking into account effects from age, visual acuity and lens media (Deleon et al., 2007).

The top five parameters considered by Heidelberg manufacturer are rim area, rim volume, cup shape measure, height variation contour and mean retinal nerve fiber layer (Heidelberg Engineering, 2005).

Rim area has been identified as a repeatable and reliable parameter in test-retest studies; it therefore represents a good marker for measuring disease progression (Kamal et al., 2000; Tan et al., 2003; Strouthidis et al., 2005a, 2005b; Artes et al., 2005; Jampel et al., 2006; Strouthidis & Garway-Heath, 2008). In a cohort study in ocular hypertensive and control subjects, the rim area event analysis had a higher detection rate of progression, at 95% specificity, than rim area trend analysis and the visual field progression criteria (Fayers et al., 2007). In a comparative study, the scanning laser polarimetry ability to discriminate eyes with progressing glaucoma by standard achromatic perimetry and/or stereophotographs from stable eyes was significantly greater for retinal nerve fiber layer thickness measured than for rim area measurements from HRT (Alencar et al., 2010).

Intertest differences in reference height and image quality had a strong relationship with intertest rim area differences and together they are responsible for 70% of the intertest variability of rim area measurements (Strouthidis et al., 2005a). The position of the reference plane with respect to the optic nerve head was considered the most frequent contributor to rim area variability (Tan et al., 2003b) and it has been demonstrated that the false positive progression can be reduced by increasing the quality follow-up image acquisition (Owen et al., 2006; Patterson et al., 2006; Bergin et al., 2008).

The detection of glaucomatous progression based on stereometric parameters, other than rim area, has been proposed. The best correlation with glaucomatous progression was found with the cup: disc area ratio (Saarela et al., 2010). In advanced glaucomatous damage the vertical cup: disc ratio may have a higher potential for detecting progression, where it maintains low test-retest variability (Deleon et al., 2007). In eyes with early glaucoma or suspected glaucoma, perimetry progression showed higher correlations with the cup area and the vertical cup: disc area. Those eyes with baseline Moorfields regression analysis changes were at a higher risk of having perimetry abnormalities and a faster progression (Garcia-Martin et al., 2010).

In a group of ocular hypertensive eyes converted to early glaucoma the parameters which changed most frequently were inferonasal cup volume (11% of discs), inferotemporal cup volume (8.5%), superotemporal cup area (7.3%) and global cup volume (6.7%) (Kamal et al., 2000). In a similar subject group, the optic disc parameters detect only a small amount of the converters, although the hit rate could be increased with the sectoral based analysis. The cup shape measure showed the highest rate (Philippin et al., 2006).

In a group of progressive optic neuropathy, a statistically significant change between baseline and follow-up examination was found for the following HRT parameters: cup shape measurement, classification index, the third moment in contour, cup/disc ratio, cup area, rim area, and area below reference while in the stable group no HRT parameters had changed significantly (Kalaboukhova et al., 2006).

The cup shape measure could be a preferred HRT3 parameter to determine glaucoma progression because it appeared to be independent of standard reference height, although

considerable variability exists by other factors (Breusegem et al., 2008). It was the only parameter which provides a significant correlation with progression of the retinal nerve fiber layer defect, whereas the best combination of two parameters included the maximum cup depth and the linear cup: disc area ratio; and the best combination of three parameters included the maximum cup depth, the linear cup: disc area ratio and the horizontal cup: disc area ratio (Saarela & Airaksinen, 2008).

It has been proposed that despite good image quality, the change in the stereometric parameters did not have a high sensitivity and specificity for progression detected with photographs. So evaluation of glaucomatous progression in the optic nerve head should not rely solely on the stereometric parameters of the HRT (Saarela et al., 2010). At present, it is a general opinion that further refinement is required to eliminate some of the inherent variability of the stereometric parameter change analysis (Kamal et al., 2000; Philipppin et al., 2006; Deleon et al., 2007; Breusegem et al., 2008; Alencar et al., 2010; Saarela et al., 2010).

It is important to highlight that age-dependent changes occur in optic nerve head topography detectable with the HRT. There were found significant changes indicating increased optic nerve head cupping in cup area, cup-to disc area ratio, rim area, mean cup depth and cup shape measure, after ten years of prospective follow- up in 36 healthy volunteers (Harju et al., 2010).

2.4 Progression analysis application (HRT 3)

The following patient is an African origin boy of 16 years old who was diagnosed of bilateral ocular hypertension in 2007. His grandfather received glaucoma filtration surgery in both eyes.

On clinical examination the average intraocular pressure measured by dynamic contour tonometer (Pascal tonometer) was 23.5mmHg (range 19.9-25.5) in the right eye and 23.7mmHg (range 20-27.7) in the left eye. The central corneal thickness was 642 and 630 for the respective eyes. The fundoscopic characteristics of both eyes are shown in figure 6. The visual field Octopus 101, 32 program, TOP strategy and Frequency- Doubling Technology (Humphrey Zeiss 710 FDT) were normal for both eyes.

The first step to analyze if glaucomatous progression occurred is the assessment of image quality in the baseline and the follow- up sequence. Those images with poor quality (more than 30 μ m) were excluded for the progression analysis in this patient.

The printed TCA and the trend analysis are displayed in figure 7 and 8 for the respective eyes. The TCA shows the significant height variation in different super- pixels within the disc margin (red colour) that do not form a cluster (both eyes).

The stereometric parameters were obtained after the contour line was delineated by an expert. The HRT computation revealed a disc area of 1.6mm² and 1.83mm² for respective eyes, so the disc size asymmetry may explain the slight asymmetry in cup appearance (figure 6).

The average reference height was 539.7 μ m and 516.5 μ m for the respective eyes. There was low variability between the baseline and the follow- up images in both eyes (average 1.6% and 2.1% respectively). The reference height can be obtained from the stereometric parameters window in each image analysis. The percentage of variability is then calculated. Thanks to good quality images, proper alignment, and low variability in the standard reference plane, the trend analysis become reliable and can help to identify if real progression has occurred.

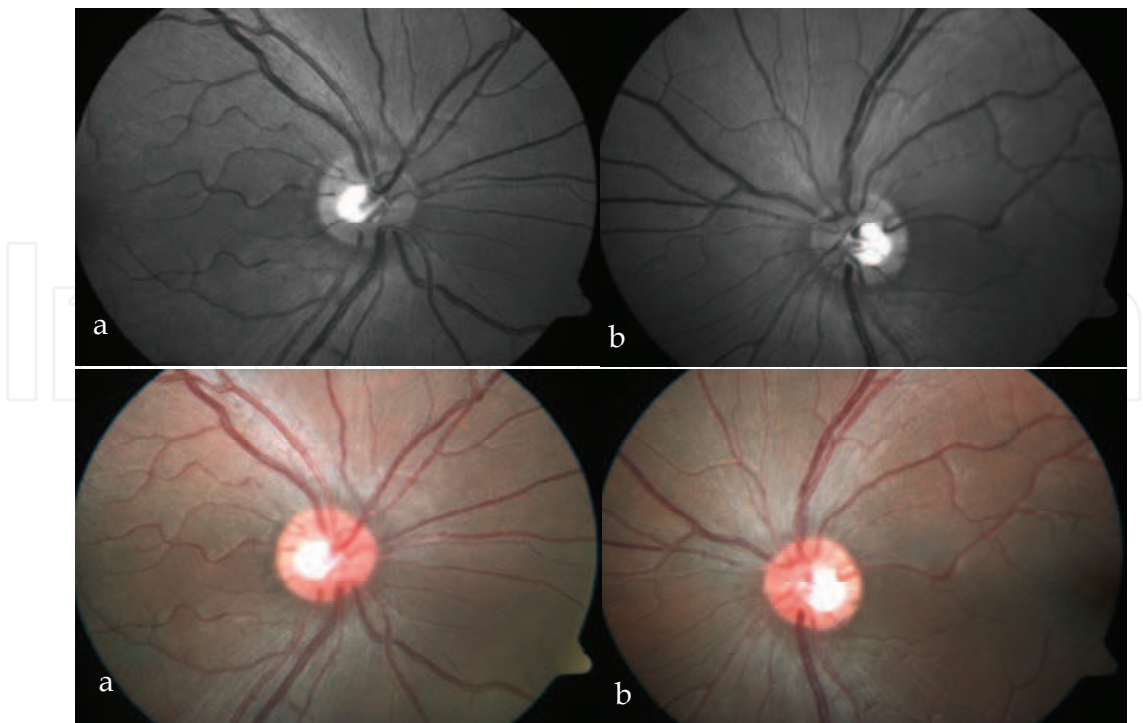


Fig. 6. Red- free and coloured photographs of the retinal nerve fiber layer and optic disc in the right eye (a) and in the left eye (b). As positive details the cup: disc area ratio and the vertical cup: disc diameter are both slightly increased in the left eye. The superior neuroretinal rim is larger than the inferior in both eyes.

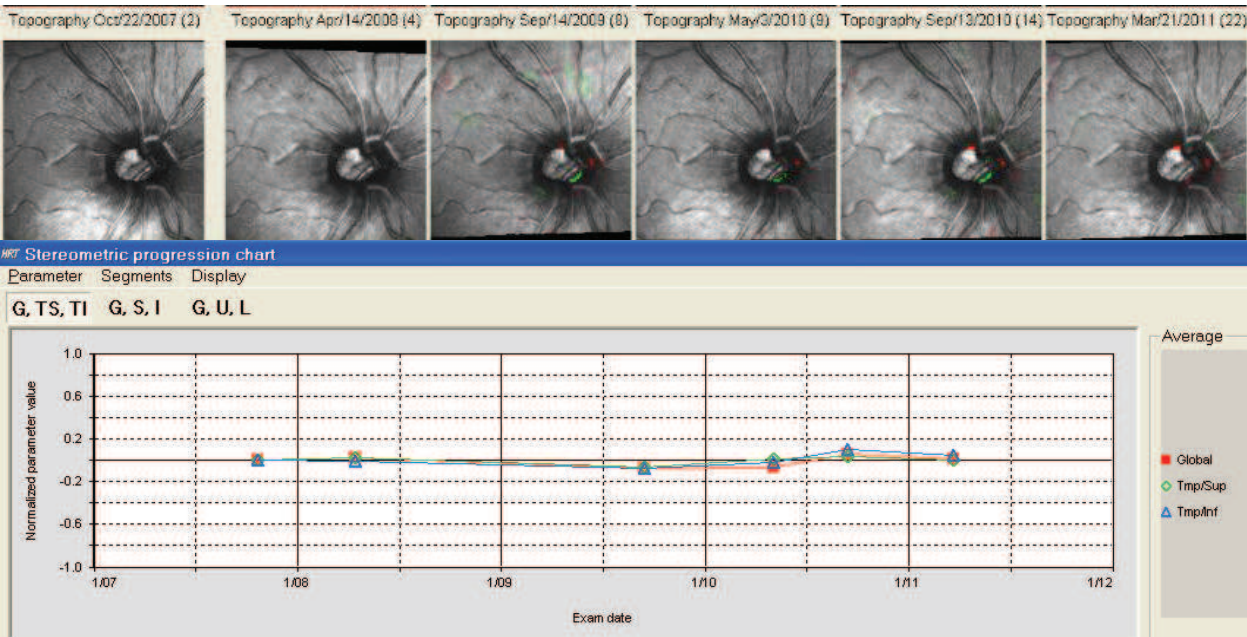


Fig. 7. Topographic Change Analysis and Trend Analysis of the right eye. The superior row shows the significance map superimposed on the reflectance image in the progression sequence. The inferior row shows the trend analysis. There were no significant changes on stereometric parameters over time.

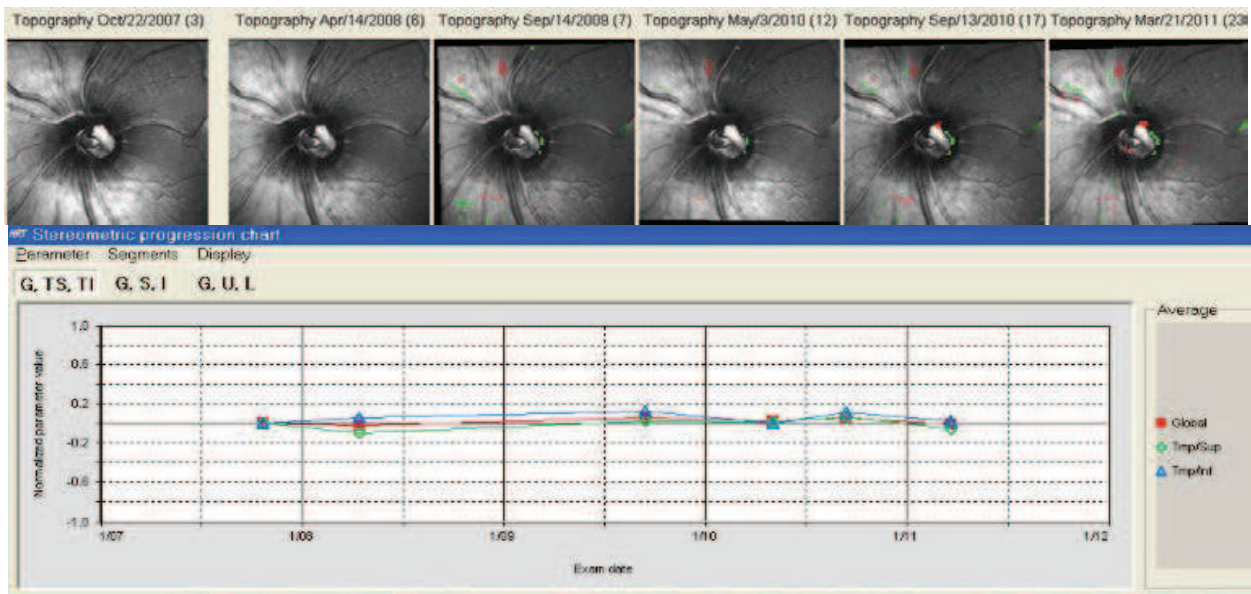


Fig. 8. Topographic Change Analysis and Trend Analysis of the left eye. The superior row illustrates a cluster in the superior retinal nerve fiber layer and significant height changes in super- pixels of the supero- temporal neuroretinal rim. There were no significant changes on stereometric parameters over time.

Progression analysis was also assessed following the changes on the main five stereometric parameters over time (figure 9). There was no variability in the four years follow- up.

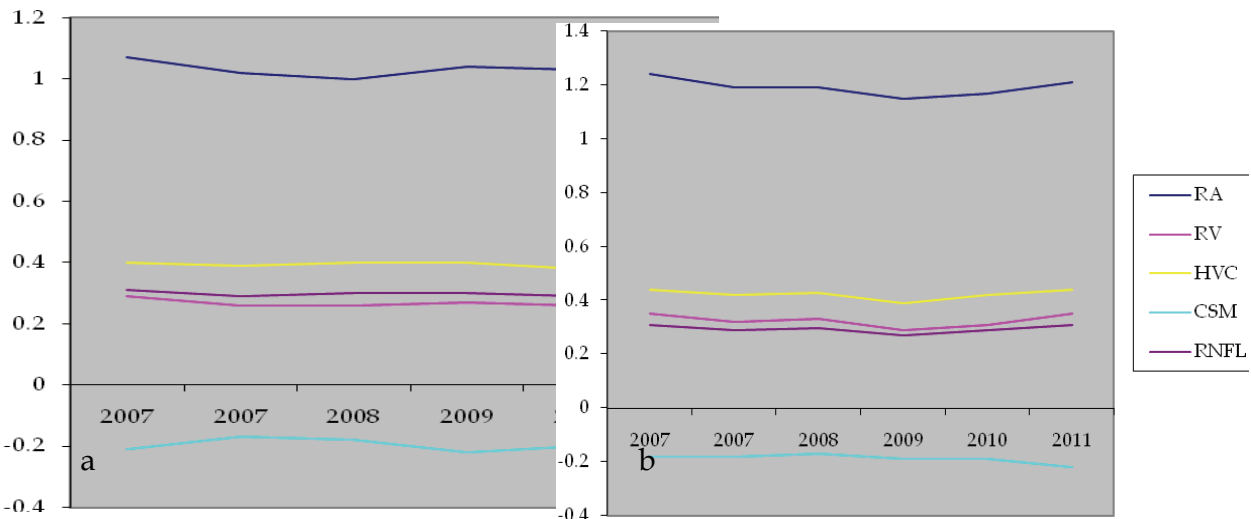


Fig. 9. Variability on the main five stereometric parameters over time in the right eye (a) and in the left eye (b). RA: rim area, RV: rim volume, HVC: height variation contour, CSM: cup shape measure, RNFL: retinal nerve fiber layer thickness.

In this patient longer follow-up is needed to identify if progression occurred by optic disc deterioration or visual fields abnormalities. Until now he receives early preventive treatment since he is considered at high risk of progression basis on his African origin, positive family history of glaucoma and long life expectance (Kass et al., 2010).

3. Conclusion

No consensus yet exists as to how best to integrate the new technology into clinical practice and what are the optimal operating criteria to enable their full potential to be realized.

Some authors prefer the TCA for progression analysis because it provides appropriate image alignment correction and considering guidelines for clinical versus statistical significant progress, whereas stereometric parameters measurements show big variability (Breusegem et al., 2008). Others consider that unlike rim area, the anatomical correlate of TCA is less easily understood. The HRT rim area may be observed both by clinical examination and by assessment of optic disc stereo-photographs (Asaoka et al., 2009). A recent study concluded that statistical methods for detecting structural changes in HRT images exhibit only moderate agreement with each other and have poor agreement with expert-assessed change in optic disc stereophotographs (O'Leary et al., 2010). For the most advantageous use of HRT it has been proposed the use of TCA as a tool for screening and the trend analysis as a confirmation of positive TCA cases. (Martinez de la Casa et al., 2006).

Different articles show evidence suggesting that there is poor agreement between structural and functional measurements of progression despite similar high levels of specificity and regardless of stage of disease. It has been suggested that it is the result of differences in measurement variability between the two methods in individual patients or different forms of presentation of the disease. It is not possible to be certain that there is an ordered structure-function relationship in glaucoma until the issue of test variability has been resolved fully (Fayers et al., 2007; Strouthidis & Garway-Heath, 2008).

The progression analysis by confocal scanning laser tomography is a powerful tool in the management of glaucoma patients. Although it is not possible to guarantee that glaucomatous damage is progressed only by HRT results, it is a strong complement to the clinical examination and the visual field function.

4. References

- Alencar, L.M.; Zangwill, L.M.; Weinreb, L.N.; Bowd, C.; Sample, P.A. & Girkin, C.A. (2010). A Comparison of Rates of Change in Neuroretinal Rim Area and Retinal Nerve Fiber Layer Thickness in Progressive Glaucoma. *Invest Ophthalmol. Vis Sci*, Vol.51, No.7, pp. 3531-3539, ISSN: 1552-5783.
- Artes, P.H. & Chauhan, B.C. (2005). Longitudinal changes in the visual field and optic disc in glaucoma. *Prog Retin Eye Res*, Vol.24, pp. 333-354, ISSN: 1350-9462.
- Asaoka, R.; Strouthidis, N.G.; Kappou, V.; Gardiner, S.K. & Garway-Heath, D.F. (2009). HRT-3 Moorfields reference plane: effect on rim area repeatability and

- identification of progression. *Br J Ophthalmol*, Vol.93, pp. 1510-1513, ISSN: 1468-2079
- Bergin, C.; Garway-Heath, D.F. & Crabb, D.P. (2008). Evaluating the effect of the new alignment algorithm for longitudinal series of Heidelberg retina tomography images. *Acta Ophthalmologica*. Vol.86, No.2, pp. 207-214, ISSN: 1755-3768.
- Bowd, C.; Balasubramanian, M.; Weinreb, R.N.; Vizzeri, G.; Alencar, L.M.; et al. (2009). Performance of Confocal Scanning Laser Tomograph Topographic Change Analysis (TCA) for Assessing Glaucomatous Progression. *Invest Ophthalmol Vis Sci*, Vol.50, No.2, pp. 691-701, ISSN:1552-5783.
- Breusegem, C.; Fieuws, S.; Stalmans, I. & Zeyen, T. (2008). Variability of the Standard Reference Height and Its Influence on the Stereometric Parameters of the Heidelberg Retina Tomograph 3. *Invest Ophthalmol Vis Sci*, Vol.49, No.11, pp. 4881-4885, ISSN: 1552-5783.
- Budenz, D.L.; Anderson, D.R.; Feuer, W.J.; et al. (2006). Detection and prognostic significance of optic disc haemorrhages during the ocular hypertension treatment study. *Ophthalmology*, Vol.113, pp. 2137-2143, ISSN: 0161-6420.
- Chauhan, B.C.; McCormick, B.A.; Nicolela, M.T. & Le Blanc, R.P. (2001). Optic Disc and Visual Field Changes in a Prospective Longitudinal Study of Patients with Glaucoma. *Arch Ophthalmol*, Vol.119, pp. 1492-1499, ISSN: 0003-9950.
- Chauhan, B.C.; Hutchison, D.M.; Artes, P.H.; Caprioli, J.; Jonas, J.B.; LeBlanc, R.P. & Nicolela, M.T. (2009). Optic disc progression in glaucoma: comparison of confocal scanning laser tomography to optic disc photographs in a prospective study. *Invest Ophthalmol Vis Sci*, Vol.50, No.4, pp. 1682-1691, ISSN: 1552-5783.
- Deleon, J.E.; Sakata, L.M.; Kakati, B.; McGwin, G. Jr.; Monheit, B.E.; Arthur, S.N. & Girkin, C.A. (2007). Effect of glaucomatous damage on repeatability of confocal scanning laser ophthalmoscope, scanning laser polarimetry, and optical coherence tomography. *Invest Ophthalmol Vis Sci*, Vol.48, No.3, pp. 1156-1163, ISSN: 1552-5783.
- Fayers, T.; Strouthidis, N.G. & Garway-Heath, D.F. (2007). Monitoring glaucomatous progression using a novel Heidelberg retina tomograph event analysis. *Ophthalmology*, Vol.114, pp. 1973-1980, ISSN: 0161-6420.
- Fogagnolo, P.; Romano, S.; Ranno, S.; Taibbi, G.; Pierrottet, C.; Ferreras, A.; Figus, M., Rossetti, L. & Orzalesi, N. (2011). Diagnostic assessment of normal and pale optic nerve heads by confocal scanning laser ophthalmoscope and stereophotography. *J Glaucoma*, Vol.20, No.1, pp. 10-4, ISSN: 1057-0829.
- García-Martín, E.; Pablo, L.; Ferreras, A.; Idoipe, M.; Pérez, S. & Pueyo, V. (2010). Ability of Heidelberg Retina Tomograph III to predict progression in patients with early glaucoma or suspected primary open-angle glaucoma. *Arch Soc Esp Oftalmol*, Vol.85, No.4, pp. 138-143, ISSN: 0365-6691.
- Harju, M.; Saari, J.; Kurvinen, L. & Vesti, E. (2008). Reversal of optic disc cupping in glaucoma. *Br J Ophthalmol*, Vol.92, No.7, pp. 901-905, ISSN: 1468-2079.
- Harju, M.; Kurvinen, L.; Saari, J. & Vesti, E. (2010). Change in optic nerve head topography in healthy volunteers: an 11-year follow-up. *Br J Ophthalmol* ISSN: 1468-2079. doi:10.1136/bjo.2010.186213.


- Heidelberg Retina Tomograph. (2005). Operating Instructions Software Version 3.0. Glaucoma Module, Heidelberg Engineering Gmgh, Alemania.
- Hudson, C.J.; Kim, L.S.; Hancock, S.A.; et al. (2007). Some dissociating factors in the analysis of structural and functional progressive damage in open-angle glaucoma. *Br J Ophthalmol*, Vol.91, pp. 624-628, ISSN: 1468-2079.
- Jampel, H.D.; Vitale, S.; Ding, Y.; Quigley, H.; Friedman, D.; Congdon, N. & Zeimer, R. (2006). Test-retest variability in structural and functional parameters of glaucoma damage in the glaucoma imaging longitudinal study. *J Glaucoma*, Vol.15, No.2, pp. 152-157, ISSN: 1057-0829 .
- Kalaboukhova, L.; Fridhammar, V. & Lindblom, B. (2006). Glaucoma follow-up by the Heidelberg retina tomograph--new graphical analysis of optic disc topography changes. *Graefes Arch Clin Exp Ophthalmol*, Vol.244, No.6, pp. 654-662, ISSN: 0721-832X(prin version) 1435-702X(electronic version).
- Kamal, D.S.; Garway-Heath, D.F.; Hitchings, R.A.; et al. (2000). Use of sequential Heidelberg retina tomograph images to identify changes at the optic disc in ocular hypertensive patients at risk of developing glaucoma. *Br J Ophthalmol*, Vol.84, pp. 993-998, ISSN: 1468-2079.
- Kass, M.A.; Gordon, M.O.; Gao, F.; Heuer,, D.K.; Higginbotham, E.J.; et al; for the Ocular Hypertension Treatment Study Group. (2010). Delaying Treatment of Ocular Hypertension. *Arch Ophthalmol*, Vol.128 No.3, pp. :276-287. doi:10.1001/archophthalmol.2010.20
- Kourkoutas, D.; Buys, Y.M.; Flanagan, J.G.; et al. (2007). Comparison of glaucoma progression evaluated with Heidelberg retina tomograph II versus optic nerve head stereophotographs. *Can J Ophthalmol*, Vol.42, pp. 82-88, ISSN: 1715-3360.
- Martínez de la Casa, J.M.; García-Feijoó, J.; Vizzeri, G. & Bowd, C. (2006). Rentabilidad diagnóstica de los sistemas de análisis de progresión del tomógrafo retiniano de Heidelberg. *Boletín de la Soc. Oftalmol. de Madrid - N.º 46*, ISSN: 1132-3701.
- Miglior, S.; Albé, E.; Guareschi, M.; Rossetti, L. & Orzalesi, N. (2002). Intraobserver and interobserver reproducibility in the evaluation of optic disc stereometric parameters by Heidelberg retina tomograph. *Ophthalmology*, Vol.109, No.6, pp. 1072-1077, ISSN: 0161-6420.
- Nicolela, M.T.; Soares, A.S.; Carrillo, M.M.; et al. (2006). Effect of moderate intraocular pressure changes on topographic measurements with confocal scanning laser tomography in patients with glaucoma. *Arch Ophthalmol*, Vol.124, pp. 633-640, ISSN: 0003-9950.
- O'Leary, N.; Crabb, D.P.; Mansberger, S.L.; Fortune, B.; Twa, M.D.; Lloyd, M.J.; Kotecha, A.; Garway-Heath, D.F.; Cioffi, G.A. & Johnson, C.A. (2010). Glaucomatous progression in series of stereoscopic photographs and Heidelberg retina tomograph images. *Arch Ophthalmol*. Vol.128, No.5, pp. 560-568, ISSN: 0003-9950.
- Owen, V.M.; Strouthidis, N.G.; Garway-Heath, D.F. & Crabb, D.P. (2006). Measurement variability in Heidelberg retina tomograph imaging of neuroretinal rim area. *Invest Ophthalmol Vis Sci*, Vol.47, pp. 5322-5330, ISSN: 1552-5783.
- Patterson, A.J.; Garway-Heath, D.F. & Crabb, D.P. (2006). Improving the repeatability of topographic height measurements in confocal scanning laser imaging using

- maximum-likelihood deconvolution. *Invest Ophthalmol Vis Sci*, Vol.47, pp. 4415-4421, ISSN: 1552-5783.
- Philippin, H.; Unsoeld, A.; Maier, P.; Walter, S.; Bach, M. & Funk, J. (2006). Ten-year results: detection of long-term progressive optic disc changes with confocal laser tomography *Graefes Arch Clin Exp Ophthalmol*, Vol.244, No.4, pp. 460-464, ISSN: :0721-832X(prin version) 1435-702X(electronic version).
- Saarela, V. & Airaksinen, P.J. (2008). Heidelberg retina tomograph parameters of the optic disc in eyes with progressive retinal nerve fibre layer defects. *Acta Ophthalmol*, Vol.86, No.6, pp. 603-608, ISSN: 1755-3768.
- Saarela, V.; Falck, A.; Airaksinen, P.J. & Tuulonen, A. (2010). The sensitivity and specificity of Heidelberg Retina Tomograph parameters to glaucomatous progression in disc photographs. *Br J Ophthalmol*, Vol.94, pp. 68-73, ISSN: 1468-2079.
- Sihota, R.; Gulati, V.; Agarwal, H.C.; Saxena, R.; Ajay, S. & Pandey, R.M. (2002). Variables Affecting Test-Retest Variability Of Heidelberg Retina Tomograph II Stereometric Parameters. *J Glaucoma*, Vol.11, No.4, pp. 321-328, ISSN: 1057-0829.
- Strouthidis, N.G.; White, E.T; Owen, V.M.; et al. (2005a). Factors affecting the test-retest variability of Heidelberg retina tomograph and Heidelberg retina tomograph II measurements. *Br J Ophthalmol*, Vol.89, pp. 1427-1432, ISSN:1468-2079 ____.
- Strouthidis, N.G.; White, E.T.; Owen, V.M.; et al. (2005b). Improving the repeatability of Heidelberg retina tomograph and Heidelberg retina tomograph II rim area measurements. *Br J Ophthalmol*, Vol.89, pp. 1433-1437, ISSN: 1468-2079 ____.
- Strouthidis, N.G.; Scott, A.; Peter, N.M. & Garway-Heath, D.F. (2006). Optic disc and visual field progression in ocular hypertensive subjects: detection rates, specificity, and agreement. *Invest Ophthalmol Vis Sci*. Vol.47, pp. 2904-2910, ISSN: 1552-5783 ____.
- Strouthidis, N.G. & Garway-Heath, D.F. (2008). New developments in Heidelberg retina tomograph for glaucoma. *Current Opinion in Ophthalmology*, Vol.19, No.2, pp. 141-148, ISSN: 1040-8738.
- Tan, J.C.; Garway-Heath, D.F.; Fitzke, F.W. & Hitchings, R.A. (2003a). Reasons for rim area variability in scanning laser tomography. *Invest Ophthalmol Vis Sci*, Vol.44, pp. 1126-1131, ISSN: 1552-5783 ____.
- Tan, J.C.; Garway-Heath, D.F. & Hitchings, R.A. (2003b). Variability across the optic nerve head in scanning laser tomography. *Br J Ophthalmol*, Vol.87, pp. 557-559, ISSN: 1468-2079 .
- Teng, C.C.; De Moraes, C.G.; Prata, T.S.; Tello, C.; Ritch, R.; Liebmann, M. (2010). Beta-Zone parapapillary atrophy and the velocity of glaucoma progression. *Ophthalmology*, Vol.117, No.5, pp. 909-915, ISSN: 0161-6420.
- Vizzeri, G.; Weinreb, R.N.; Martinez de la Casa, J.M.; Alencar, L.M.; Bowd, C.; et al. (2009). Clinicians Agreement in Establishing Glaucomatous Progression Using the Heidelberg Retina Tomograph. *Ophthalmology*, Vol.116, No.1, pp. 14-24, ISSN: 0161-6420.

Vizzeri, G.; Kjaergaard, S.M.; Rao, H.L. & Zangwill, L.M. (2011). Role of imaging in glaucoma diagnosis and follow-up. Indian J Ophthalmol, Vol.59, pp. 59-68, ISSN: 0301-4738.

IntechOpen

IntechOpen



The Mystery of Glaucoma

Edited by Dr. Tomas Kubena

ISBN 978-953-307-567-9

Hard cover, 352 pages

Publisher InTech

Published online 06, September, 2011

Published in print edition September, 2011

Since long ago scientists have been trying hard to show up the core of glaucoma. To its understanding we needed to penetrate gradually to its molecular level. The newest pieces of knowledge about the molecular biology of glaucoma are presented in the first section. The second section deals with the clinical problems of glaucoma. Ophthalmologists and other medical staff may find here more important understandings for doing their work. What would our investigation be for, if not owing to the people's benefit? The third section is full of new perspectives on glaucoma. After all, everybody believes and relies – more or less – on bits of hopes of a better future. Just let us engage in the mystery of glaucoma, to learn how to cure it even to prevent suffering from it. Each information in this book is an item of great importance as a precious stone behind which genuine, through and honest piece of work should be observed.

How to reference

In order to correctly reference this scholarly work, feel free to copy and paste the following:

Liamet Fernández Argones, Ibraín Piloto Díaz, Marerneda Domínguez Randulfe, Germán A. Álvarez Cisneros and Marcelino Río Torres (2011). The use of Confocal Scanning Laser Tomography in the Evaluation of Progression in Glaucoma, *The Mystery of Glaucoma*, Dr. Tomas Kubena (Ed.), ISBN: 978-953-307-567-9, InTech, Available from: <http://www.intechopen.com/books/the-mystery-of-glaucoma/the-use-of-confocal-scanning-laser-tomography-in-the-evaluation-of-progression-in-glaucoma>

INTECH
open science | open minds

InTech Europe

University Campus STeP Ri
Slavka Krautzeka 83/A
51000 Rijeka, Croatia
Phone: +385 (51) 770 447
Fax: +385 (51) 686 166
www.intechopen.com

InTech China

Unit 405, Office Block, Hotel Equatorial Shanghai
No.65, Yan An Road (West), Shanghai, 200040, China
中国上海市延安西路65号上海国际贵都大饭店办公楼405单元
Phone: +86-21-62489820
Fax: +86-21-62489821

© 2011 The Author(s). Licensee IntechOpen. This chapter is distributed under the terms of the [Creative Commons Attribution-NonCommercial-ShareAlike-3.0 License](https://creativecommons.org/licenses/by-nc-sa/3.0/), which permits use, distribution and reproduction for non-commercial purposes, provided the original is properly cited and derivative works building on this content are distributed under the same license.

IntechOpen

IntechOpen