

We are IntechOpen, the world's leading publisher of Open Access books Built by scientists, for scientists

6,900

Open access books available

186,000

International authors and editors

200M

Downloads

Our authors are among the

154

Countries delivered to

TOP 1%

most cited scientists

12.2%

Contributors from top 500 universities



WEB OF SCIENCE™

Selection of our books indexed in the Book Citation Index
in Web of Science™ Core Collection (BKCI)

Interested in publishing with us?
Contact book.department@intechopen.com

Numbers displayed above are based on latest data collected.
For more information visit www.intechopen.com



External Wire Frame Fixation for Skin Grafts

Rei Ogawa and Hiko Hyakusoku

*Department of Plastic, Reconstructive and Aesthetic
Surgery, Nippon Medical School, Tokyo
Japan*

1. Introduction

Skin grafting has been used widely for various reconstructions. The complete survival of the skin graft is necessary for functional and aesthetic restoration, as incomplete survival delays wound healing and results in severe primary and secondary contraction of the graft and scar contractures. To promote successful skin grafting, bleeding of the recipient wound bed must be arrested during surgery and the graft must be appropriately compressed and completely fixed to prevent shearing against the wound bed. After the operation, it is necessary to maintain the compression force and fixation of the graft for at least 5–7 days.

One of the difficulties associated with skin grafting is differences in recipient site conditions. Areas that are difficult to graft are mobile areas such as the joints and the neck, and areas that have a free border, such as the eyelids and the perioral area. The authors currently use the external wire-frame fixation method¹⁻⁵ for reliable skin grafting, in particular when these areas are involved. This technique is useful for securing the graft to the wound bed and it prevents the graft edges from lifting. In addition, it can sometimes be used to fix joints at the same time. This technique is introduced and discussed in this chapter.

2. Technique and methods

During surgery, the skin graft is fixed with sutures as usual (Fig. 1-1). At the same time, a wire frame of 0.7–1.0 mm-diameter Kirschner wire that has the shape of the graft is created. In the case of digital skin grafts, the wire frame can be slightly larger than the recipient site so that the digital joint(s) can be fixed at the same time and results in a three-dimensional wire frame. To ensure that the frame edges do not stick out, the ends of the Kirschner wire meet each other in a thin plastic tube, such as the outer sheath of an indwelling needle. The wire frame shape should be adjusted finely to ensure that it does not induce a pressure ulcer.

The wire frame is placed onto the graft and attached with the same sutures that were used to stitch the graft (Figs. 1-2 – 1-7). Finally, tie-over fixation is performed in the usual manner with appropriate pressure (Figs. 1-8 – 1-11).

The tie-over and the wire frame are removed about seven days later in the case of full-thickness skin grafts, and five days later in the case of split-thickness skin grafts, prior to removing the grafted skin sutures. The patient can then begin rehabilitating the affected sites.

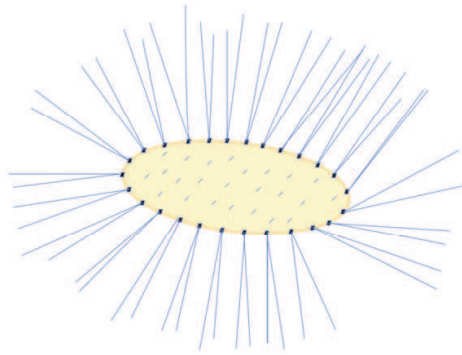


Fig. 1-1. The skin graft is sutured to the recipient site by 4-0 or 5-0 nylon or polypropylene sutures.

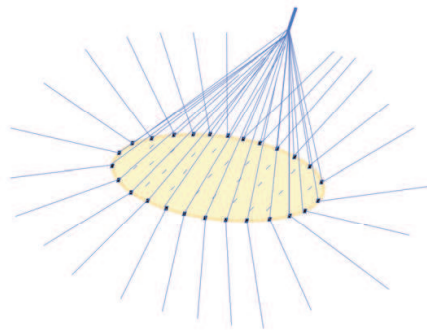


Fig. 1-2. One end of each suture is lifted and bound to the others, thus forming a hank.

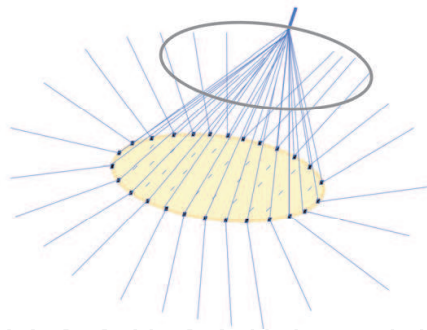


Fig. 1-3. The external wire frame is placed over the hank formed by the sutures.

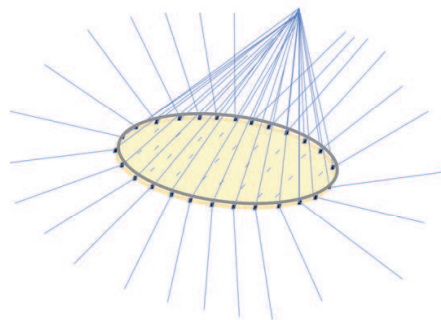


Fig. 1-4. The external wire frame is fitted onto the grafted skin.

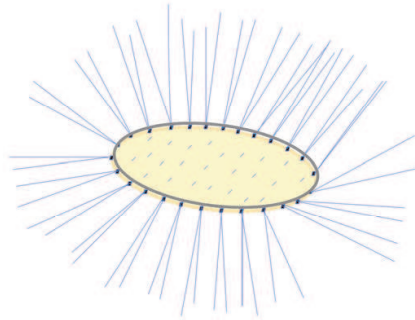


Fig. 1-5. The sutures are released from the hank.

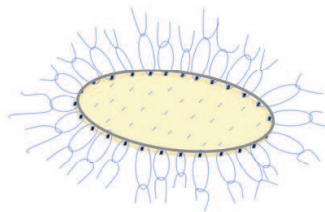


Fig. 1-6. To tie up and fix the external wire frame, the sutures are knotted.

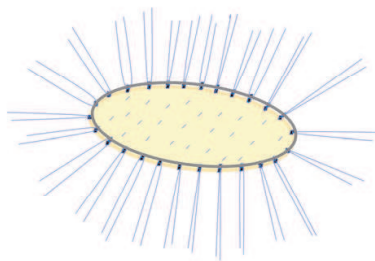


Fig. 1-7. The external wire frame is fixed tightly, with care taken to ensure that a pressure ulcer does not arise.

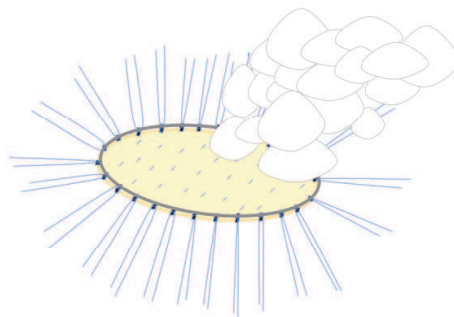


Fig. 1-8. Tie-over gauze is placed onto the grafted skin.

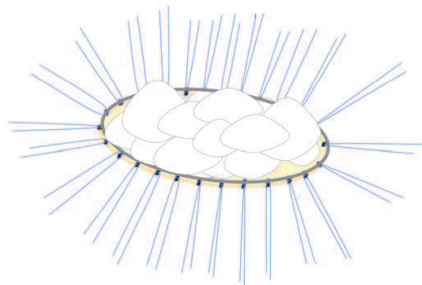


Fig. 1-9. The tie-over gauze is arranged so that its volume is distributed equally over the graft.

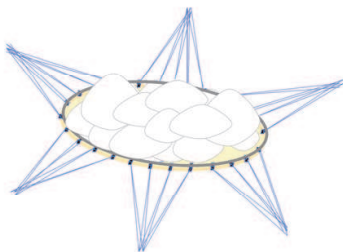


Fig. 1-10. The sutures are divided into 4-6 sets and bound into hanks.

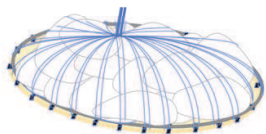


Fig. 1-11. The suture hanks that oppose each other diametrically are tied up, thus completing the tie-over fixation.

3. Discussion

With regard to eyelid skin grafts, the wire frame can eliminate the need for tarsorrhaphy, as an external wire frame allows the patient to open his or her eyes immediately after surgery without causing the skin grafts to move^{2,5}. With regard to the perioral area, an external wire

frame allows the patient to start eating immediately after surgery (Fig. 2-1 and 2-2). Moreover, the three-dimensional external wire frames³ used with digits are useful for fixing the digital joint(s) as well as the skin graft (Fig. 3-1 and 3-2). If external fixation method is used for digital skin grafting, the digital joints do not need to be fixed by pinning the digit with Kirschner wire. Thus, external wire frames are particularly useful for the grafting of the palmar surfaces of the fingers.

In summary, external wire frame fixation can secure skin grafts to the wound bed with homogeneous pressure and reduce shear force at the periphery, thereby promoting skin graft take. It provides reliable but not excessive fixation that permits the early movement and rehabilitation that promotes functional and aesthetic restoration. It is a simple, cheap and individualized technique that is associated with easy perioperative management and nursing.

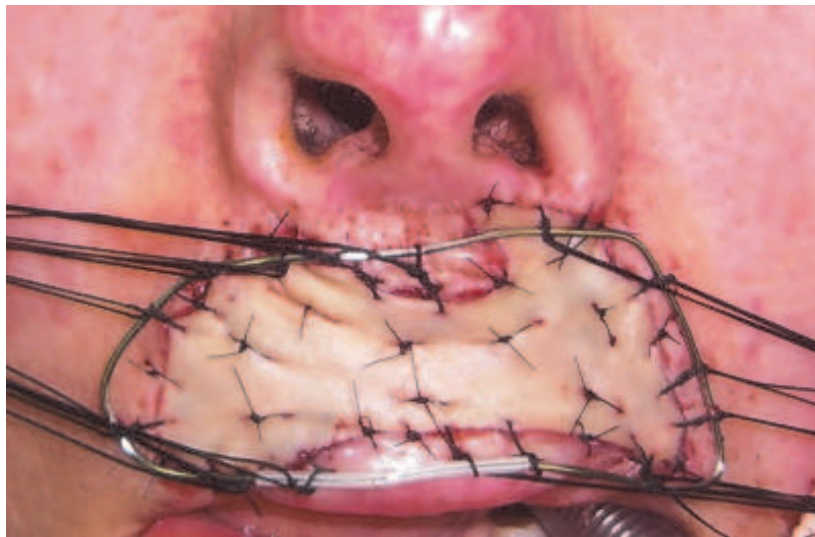

Fig. 2-1. Skin graft with external wire frame on the upper lip (intra-operative view)

Patient started to eat immediately after surgery.

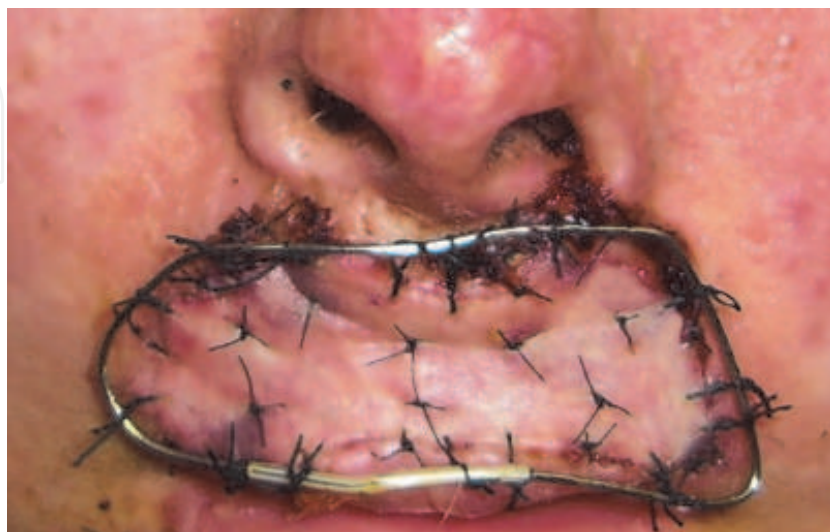

Fig. 2-2. Skin graft with external wire frame on the upper lip (7 days post-operative view)

Grafted skin survived completely.

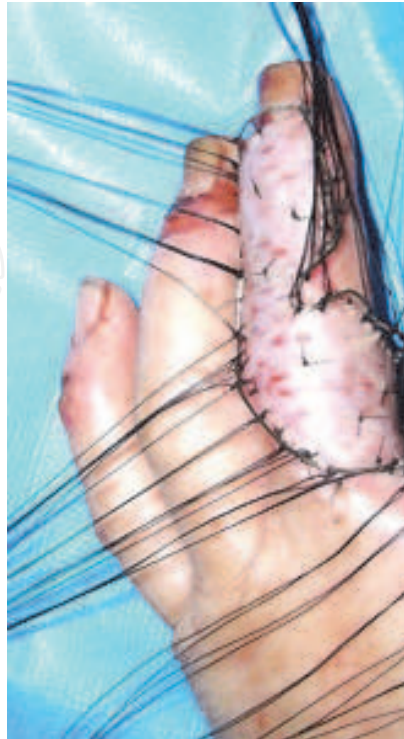


Fig. 3-1. Three-dimensional external wire frames used with digits (intra-operative view)

The digital joints did not need to be fixed by pinning using Kirschner wire.

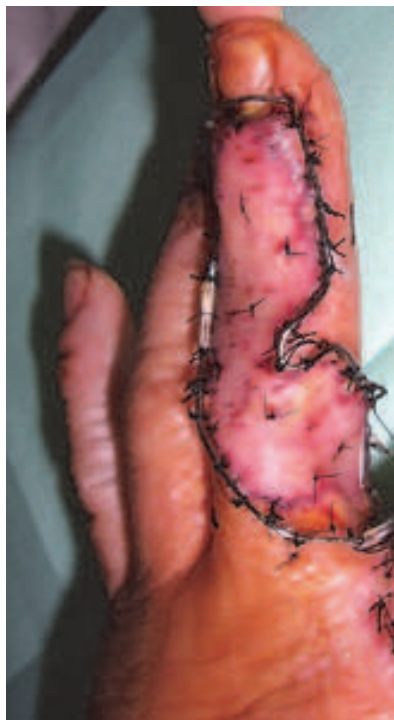

Fig. 3-2. Three-dimensional external wire frames used with digits (7 days post-operative view)

The grafted skin survived completely.

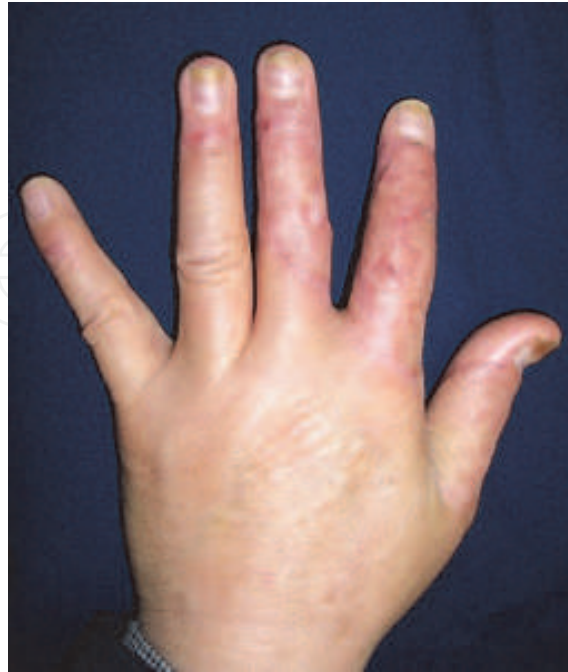

Fig. 3-3. Three-dimensional external wire frames used with digits (6 months post-operative view)

There were no functional limitation.

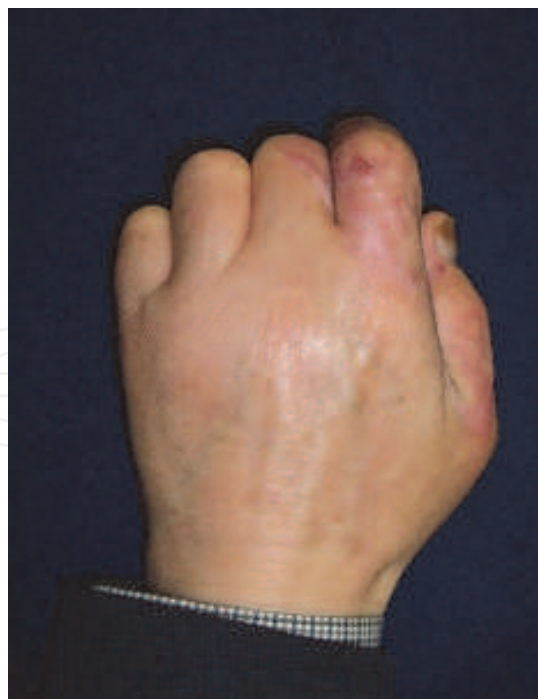

Fig. 3-4. Three-dimensional external wire frames used with digits (6 months post-operative view)

There were no functional limitation.

4. References

- [1] Hirai T, Hyakusoku H, Fumiiri M. The use of a wire frame to fix grafts externally. *Br J Plast Surg* 1991; 44: 69-70.
- [2] Murakami M, Hyakusoku H, Ishimaru S. External wire frame fixation of eyelid graft. *Br J Plast Surg* 2003; 56: 312-13.
- [3] Ogawa R, Aoki S, Aoki M, Oki K, Hyakusoku H. Three-dimensional external skin graft fixation of digital skin graft. *Plast Reconstr Surg*. 2007 Jan;119(1):440-2.
- [4] Ogawa R, Hyakusoku H, Ono S. Useful tips for successful skin grafting. *J Nippon Med Sch* 2007; 74: 386-92.
- [5] Murakami M, Ogawa R, Hyakusoku H. Efficacy of 'rugby-ball shape' skin grafting using external wire frame fixation without tarsorrhaphy for lower eyelid reconstruction. *J Plast Reconstr Aesthet Surg* 2010; 63: e220-1.

IntechOpen



Skin Grafts - Indications, Applications and Current Research

Edited by Dr. Marcia Spear

ISBN 978-953-307-509-9

Hard cover, 368 pages

Publisher InTech

Published online 29, August, 2011

Published in print edition August, 2011

The procedure of skin grafting has been performed since 3000BC and with the aid of modern technology has evolved through the years. While the development of new techniques and devices has significantly improved the functional as well as the aesthetic results from skin grafting, the fundamentals of skin grafting have remained the same, a healthy vascular granulating wound bed free of infection. Adherence to the recipient bed is the most important factor in skin graft survival and research continues introducing new techniques that promote this process. Biological and synthetic skin substitutes have also provided better treatment options as well as HLA tissue typing and the use of growth factors. Even today, skin grafts remain the most common and least invasive procedure for the closure of soft tissue defects but the quest for perfection continues.

How to reference

In order to correctly reference this scholarly work, feel free to copy and paste the following:

Rei Ogawa and Hiko Hyakusoku (2011). External Wire Frame Fixation for Skin Grafts, Skin Grafts - Indications, Applications and Current Research, Dr. Marcia Spear (Ed.), ISBN: 978-953-307-509-9, InTech, Available from: <http://www.intechopen.com/books/skin-grafts-indications-applications-and-current-research/external-wire-frame-fixation-for-skin-grafts>

INTECH
open science | open minds

InTech Europe

University Campus STeP Ri
Slavka Krautzeka 83/A
51000 Rijeka, Croatia
Phone: +385 (51) 770 447
Fax: +385 (51) 686 166
www.intechopen.com

InTech China

Unit 405, Office Block, Hotel Equatorial Shanghai
No.65, Yan An Road (West), Shanghai, 200040, China
中国上海市延安西路65号上海国际贵都大饭店办公楼405单元
Phone: +86-21-62489820
Fax: +86-21-62489821

© 2011 The Author(s). Licensee IntechOpen. This chapter is distributed under the terms of the [Creative Commons Attribution-NonCommercial-ShareAlike-3.0 License](https://creativecommons.org/licenses/by-nc-sa/3.0/), which permits use, distribution and reproduction for non-commercial purposes, provided the original is properly cited and derivative works building on this content are distributed under the same license.

IntechOpen

IntechOpen