

We are IntechOpen, the world's leading publisher of Open Access books Built by scientists, for scientists

6,900

Open access books available

186,000

International authors and editors

200M

Downloads

Our authors are among the

154

Countries delivered to

TOP 1%

most cited scientists

12.2%

Contributors from top 500 universities



WEB OF SCIENCE™

Selection of our books indexed in the Book Citation Index
in Web of Science™ Core Collection (BKCI)

Interested in publishing with us?
Contact book.department@intechopen.com

Numbers displayed above are based on latest data collected.
For more information visit www.intechopen.com



Application of the Nanocrystalline Silver in Treatment of Burn Wounds in Children

Maya Argirova and Ognian Hadjiiski
*N.I. Pirogov, Centre of Burns and Plastic Surgery, Sofia
 Bulgaria*

1. Introduction

Infection is one of the most frequent and major complications in patients with burn injuries and is the main cause for prolonged in-hospital stay and death in cases of wide-spread burns despite marked progress in the development of treatments methods for these patients. Burn infections get complicated by the development of multi-resistant organisms. The colonization and infection of these wounds are a dual clinical problem. On one hand, a slowing of the healing process is possible based on a damaged immune system and inadequate perfusion to the wound. On the other hand, the infected wound may be a potential source of spreading of antibiotic-resistant microorganisms. The infected wound is a cause for pain and discomfort for patients, as well as life-threatening septic conditions. Thus, the treatment cost and the medical care increase, respectively.

The topical treatment of the wound is an integral part of the general treatment of the burns. The topical treatment agents should possess some important characteristics such as a broad spectrum of antibacterial activity, low resistance level, decreased vapour loss, dehydration prevention, limited adverse effects, pain control, ease of use and limited toxic risk. Due to the wide variety of suitable agents, the choice of the agent depends on the assessment of the wound. The most important considerations for the choice of a burn wound dressing are the level of its antiseptic effect, the influence of its bioactive abilities on the epithelization and its abilities for management of the wound infection. The perfect dressing for children should provide optimal protection, reparation and minimization of pain and burn sequelae. Over the last 30 years, the knowledge of the mechanism of wound healing has made incredible progress as a result of intensive technological and clinical research. The new technologies have focused on the development of antiseptic products releasing the antiseptic agent slowly and steadily, which allows a lower and more efficient concentration. The wide-spread antiseptic agents containing silver have a long history of usage and a wide spectrum of activity (Klasen, 2000; Landsdown, 2006; Fong & Wood, 2006). Silver dressings are the most commonly and frequently used in burn wound treatment.

The perfect silver dressing should contain such silver concentration which creates a free (or limited) side antibacterial effect. The silver nitrate solution is not applied any more due to its toxic effect, change of ionic balance and low penetration in depth. The silver sulphadiazine SSD (Flammazine, Dermazin, Silvadene, Silverdin®, etc.) is the most frequently used agent for topical treatment of children with burns. SSD has a powerful antibacterial effect against a broad spectrum of Gram-positive and Gram-negative bacteria, and especially MRSA and

Candida spp. The antibacterial effect can be achieved two hours after application and its maximum activity lasts approximately six hours. The majority of the comparative clinical studies, utilizing biological and non-biological dressings, involves silver sulphadiazine, which shows that it is used as a standard agent for treatment in most burn centres (Huang et al., 2007; Cuttle et al., 2007).

Creams and solutions containing silver have been used as main agents in burn wound treatment for a long time. Attempts to utilize the excellent antiseptic properties of silver and keep the principles of maintaining the moisture environment in the wound on the one hand, and avoid the disadvantages of SSD and silver nitrate on the other, have led to the development of a new generation of silver dressings. New technologies allowing impregnating substances with “antimicrobial” effect in materials or medical equipment have been exploited. Silver dressings have preventive and healing effect on the wound surface (Burrell, 2003; Orvington, 2001).

The new silver-impregnated dressings, developed over the last 20 years, have overcome to a great extent the disadvantages and limitations of the older silver dressings and especially the fast silver inactivation. In these new dressings, when silver is consumed by interaction with target cells or inactivated by protein and anion complexes in wound exudate, additional silver is released in the wound. Thus, a sustained and steady supply of active silver is achieved on the wound surface (Leaper, 2006). The innovation in these dressings is not the properties of silver, which are well-known, but the amount of silver incorporated in the dressings themselves. Since the properties of silver are beyond doubt, the choice of dressing is determined by the characteristics of the silver-carrying material and by the way of silver delivery to the wound. The dressing components vary as well including mesh, nylon, hydrocolloid or methylcellulose. In order to be biologically active, the structure of silver should have dissolution properties, e.g., Ag^+ or Ag^0 . Ag^+ is a known ionic form present in silver nitrate, silver sulfadiazine and other ionic silver compounds. Ag^0 is the metallic or uncharged form of silver occurring in crystalline and nanocrystalline silver structures (Demling & De Santi, 2001; Orvington, 2001).

In the treatment practice, various silver-impregnated dressings are used. Dressings of this type differ mostly in their silver “reservoirs”. Some examples are Acticoat (Smith & Nephew), Actisorb Silver 220 (Johnson & Johnson), Aquacel - Ag (Convatec), Arglaes (Medline, Mundelein), Contreet - H (Coloplast, Marietta), SilvaSorb (Medline) and Silverlon® (Argentum LLC). The comparison of the silver dressings is usually based on the bacteriology (Cavanagh et al., 2010). Thus, differences are noticed in the field of inhibition, with Minimum Inhibitory Concentration (MIC) and Minimum Bactericidal Concentration (MBC) as a result of the antimicrobial activity of the agent. The results of the in-vitro studies of these products with respect to their antimicrobial effect are comparatively identical, and most of them demonstrate that Acticoat has a more powerful and broader-spectrum antibacterial effect (Yin, 2003; Yin, Langford & Burrell, 1999). For example, MIC is reached in concentration of Ag at the range of 5-50 ppm for the most bacteria of clinical interest and 60.5 ppm for MRSA. Ag concentration for Acticoat is 70 ppm. Acticoat and Aquacel-Ag are shown to be most efficient among the silver-impregnated dressings. It has to be pointed out that only few prospective clinical studies on the use of these products in patients with burns have been published. The nanocrystalline silver dressing was produced using nanotechnology and was introduced by R.E. Burrell in 1998 (Wright et al., 1998; Burrell et al., 1999).

Acticoat has biological, clinical and practical advantages. The biological advantages are: i) excellent antimicrobial activity; ii) decrease in the inflammatory reaction of the wound by diminishing exudation and control of wound contamination; and iii) creation of optimal environment for the healing process of the wound by maintaining moisture, stimulating epithelization and controlling wound contamination (Gravante et al., 2009).

The antimicrobial activity of silver ions has been studied in detail. It has been found that this activity is due to: i) interruption of the cell respiratory chain; ii) intervention in the electronic and ionic transport of the bacterial cell; iii) attaching to bacterial DNA and influence on cell replication; and iv) interaction with the cell membrane and damaging of its structure and receptor function.

The aim of our study was to assess the quality and efficacy of the nanocrystalline silver dressing in treatment of burn wounds and to determine the potential advantages over the older silver dressings.

2. Materials and methods

2.1 Prospective clinical study involving children treated with Acticoat

A prospective clinical study involving a clinical contingent of 112 children treated with Acticoat has been carried out. The protocol was approved by the local ethics committee and written informed consent was provided by the children's parents prior the commencement of the study. The approval of reporting the results of the study has been obtained. The nanocrystalline silver dressing has been applied on children of both genders, stationary treated for a period of one and a half year in 2009 and 2010. **Acticoat™** and **Acticoat Flex** with 3- and 7-day-wear time have been used. **Acticoat™** consists of three layers – two outer and one inner. The inner layer is an absorbent core of rayon and polyester, which controls the silver release. The two outer layers are a silver-coated, high-density polyethylene mesh. The silver dressing coating has a specific physical structure consisting of silver nanocrystalline, organised in a coarse columnar structure. The thickness of the silver layer is approximately one micrometer and contains 0.24 ± 0.4 mg silver per mg polyethylene mesh. Acticoat-7 dressing consists of three layers of polyethylene mesh coated with nanocrystalline silver and two layers of rayon polyester.

Acticoat Flex is a new, modern formula of the unique silver nanotechnology. Acticoat Flex has an open-weave structure. The open weave structure allows good contact with the wound and easy exudate migration, thus reducing the risk of maceration and does not require constant moistening. The dressing can be perfectly combined with vacuum negative pressure therapy in cases of soft tissue defects.

The monitored children were in the group age of 9 months to 18 years (mean age – 5.26 years) and had burn area of 0.5% to 95% (mean – 7.89%). The burn wounds had various depth and localization. Among them predominated the second-degree superficial burns (IIAB). The studied contingent was grouped into five groups:

- The first and largest group comprised 78 children with second-degree superficial burns (IIAB) having mean burn area of 6.82%;
- The second group involved 19 children with deep burn wounds – mean area of the deep burn wounds of 15.76%.
- The third group comprised 5 children on whom the Acticoat dressing was applied on excised wounds with mean area of 6.75%.
- The fourth group comprised 5 children with application of the dressing on autografts.

- The fifth group comprised 5 children with application of the dressing on fresh donor sites.

The assessment methods used included clinical, microbiological, statistical and photo documentation.

2.2 Comparative analysis

A comparative clinical and cost analysis between **Acticoat™** and **SSD (Dermazin)** has been carried out, since the latter agent has proven antiseptic properties and is widely used for the treatment of burns in children in comparison with the other epithelotonic and less antiseptic agents such as iodine and chlorine-hexidine (Tonkin & Wood, 2005). The clinical contingent for this comparative analysis is different from the previous one and involved 111 children. The patients were randomized into two groups. The comparative assessment has been performed for 68 children with **Acticoat™** and 43 children with **Dermazin** and the following parameters have been monitored:

- Clinical – wound type (initial and post dressing change), wound clearing time, epithelization time and hospital stay;
- Microbiological – dynamically monitoring the microbial flora, prior and post each dressing change;
- Pharmacological and cost parameters.

2.3 Method of use

The way of application depends on the type of **Acticoat**. The application is easy and identical regardless of the age, area, localization and the depth of the burn, excised area, area covered with autograft or donor site. The wound areas are mechanically cleaned by hydro-procedure using Hibiscrub. Prior to use, **Acticoat™** is moistened with sterile water and applied on the burn wound, excised area, autograft or donor site. The dressing is trimmed according to the shape of the treated area. **Acticoat™** is covered with a four-layer moistened gauze followed by four layers of dry gauze whose purpose is to drain the surplus amount of fluid. The dressing is held in place with a bandage or mesh. The moisture maintenance is an important condition for the dressing efficacy and can be done by means of the following two ways:

- Moistening the dressing by irrigation or watering once or twice daily. The outer gauze layer is changed.
- Covering the dressing with polyethylene foil which helps maintain moisture.

An alternative but a more expensive way to maintain the moisture is to use **Intrasite gel** or **Allevyn foam**.

In case of heavy exudate wounds, additional moistening of the wounds is not necessary. The dressing is changed 3 or 7 days after application, but this period may differ depending on the estimation. **Acticoat Flex** is used after an identical preparatory wound treatment and is moistened with sterile water prior to application. It is cut to the desired shape and size, and exploiting its elasticity applied to the wound area. The dressing is covered with a four-layer moistened gauze followed by four layers of dry gauze. It is not additionally moistened until the next dressing. In wide spread burns, the dressing change is performed by using a general anaesthesia (Tancheva, 2008). In cases of limited and small burn areas, a general anaesthesia is not necessary due to the painless dressing change.

Microbiological quantitative (tissue biopsy samples) and qualitative (wound surface swab) analysis of the flora in the treated areas were carried out before initial application and at

every dressing change. The studied contingent was monitored for presence of pain or discomfort after the dressing as well as for side effects – general and local.

The treatment of 62 children from the first group started within 24 hours after the burn and for the remaining 16 children – 24 hours after the burn. The treatment of 7 children from the second group began within 24 hours after the burn and for the remaining 12 children – within 42 hours.

In all burn centres **SSD** is changed every 12 hours. In this study the **Dermazin** dressings were changed every 24 hours. The microbiological analysis was performed at the beginning of the treatment and at every dressing change. The closed method of application was used. After a hydro-procedure with Hibiscrub and cleansing using disinfection solution, the agent of 2-3 mm layer was applied directly on the wound and covered with dry, sterile and dense bandage-gauze dressing (Atiyeh, 2009).

3. Clinical observations

3.1 Clinical observation of the wounds treated with Acticoat

The treatment with Acticoat of the first group of children (78) with superficial burns was conducted according to the described method. Decreasing of the exudation and demarcation of devitalized tissue was observed as early as in the first dressing. In wounds and areas of second degree (IIA), the dermis was deeply red with beginning epithelization. In cases of abundant exudation and of deep dermal burns, a bright and jelly-like coating was observed on the wound surface and the Acticoat bed, which was caused by protein coagulation. Attempting to remove this coating led to heavy wound bleeding. The wound resembled the “infected” one, but bacterial growth was absent. There was no inflammation area around the wound. A dark brown or grey pigmentation of the wound and intact skin was observed, which was transient and disappeared within 2 to 14 days. The intact skin was changed by the hydration but not macerated. The hydrated skin appeared white or lighter than the surrounding skin with a wrinkled or prune-like look, while the macerated skin was soft and tissue became bright red, progressing to blistering and breakdown. When Acticoat Flex was applied on this type of burns, a good fixation of the agent on the wound and hardly any exudation was observed. In most cases, the dressing could be removed only after a prolonged moistening. The dressing structure allows good control of the wound and a new dressing was not applied, regardless of the Acticoat Flex wear time (3 or 7 days), providing the dressing was properly fixed. When the dressing was applied on a heavily exudating wound, the exudation decreased after one or two dressings (6 children). The exudation level was subjectively assessed by the type and size of the coating on the wound surface and on the dressing. In burns above 10%, where wound infection was not present, smell appeared after the removal of the dressing. The patients did not feel pain immediately after the dressing application and between the dressing changes.

A discomfort after the dressing application was observed in 8 children, which disappeared within 3-4 hours. In the deep dermal burn wounds, a very rapid demarcation and removal of the necrotic tissue was observed (in the 2nd or 3rd dressing). The mean wound clearing time is 8.92 days and the mean epithelization time is 12.98 days, shorter in comparison with the agents used thus far. The second (IIA) degree burn wounds epithelialized within 5-6 days. In the case of cleared wound and beginning epithelization, the dressing could be replaced by another type of epithelotonic dressing such as Bactigras. (Bactigras is a sterile gauze dressing made of cotton impregnated with soft paraffin containing 0.5%

chlorhexidine acetate). When the Acticoat dressing was applied on infected wounds, the clinical type of the wound remained the same, but the coating on the dressing bottom was more mucous and thick, and a 4-5-day delay in the wound clearing was observed. Wound sites in which a pathogenic flora was isolated during the treatment did not clinically change the wound type. In these rare cases the only clinical sign was the delay of the wound clearing and epithelization, respectively.

The application of Acticoat™ and Acticoat Flex for treatment of superficial burns is demonstrated (Figures 1-15).

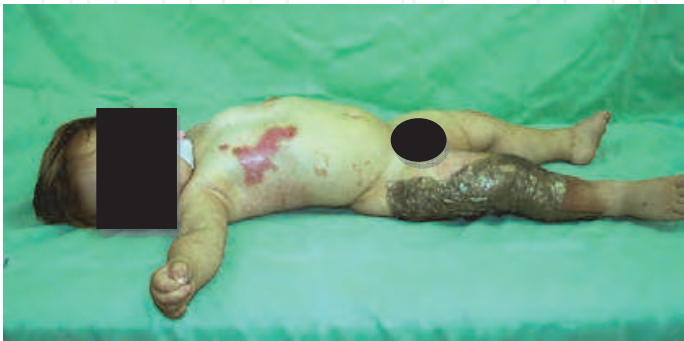

Fig. 1. The beginning of treatment

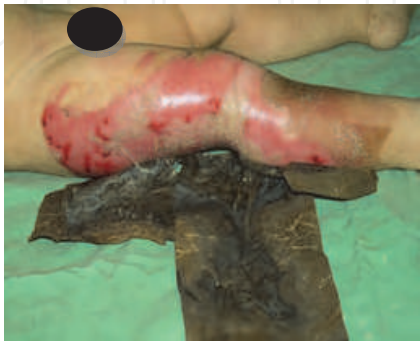

Fig. 2. Result after the 1st dressing

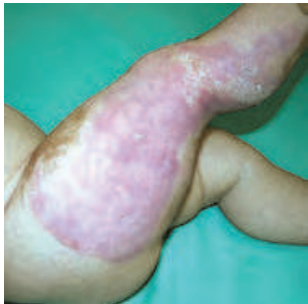


Fig. 3. Result after the 2st dressing – complete epithelization

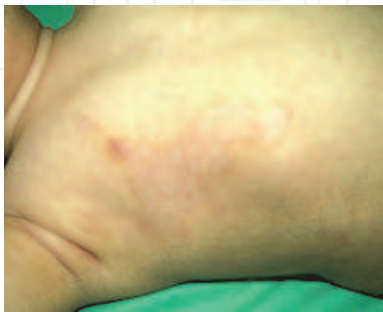
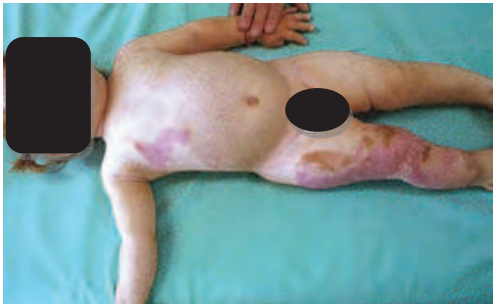
Fig. 4. Final result – 30th day after the burn

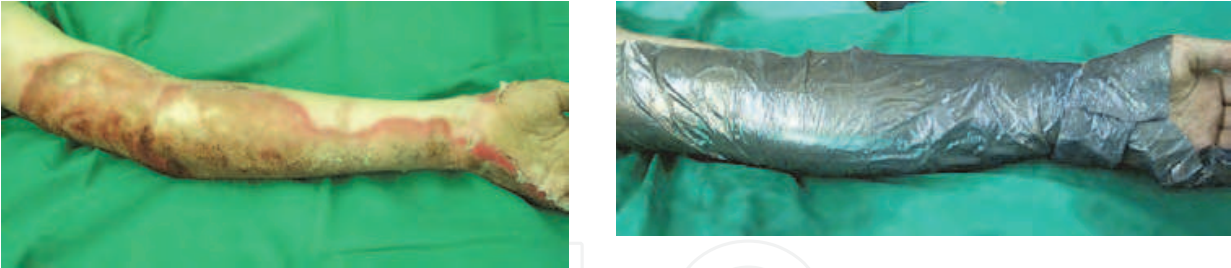


Fig. 5. The beginning of the treatment with Acticoat™ of a left arm with deep dermal flame burn –

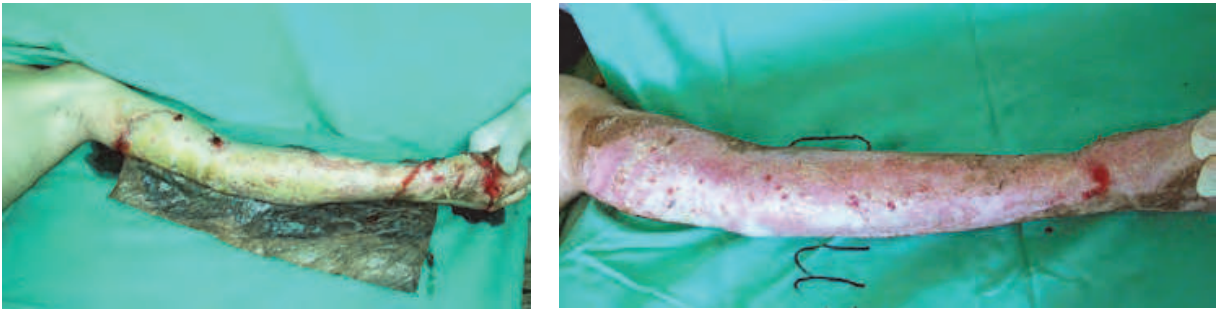


Fig. 6. Wound condition after the 1st dressing

Fig. 7. Wound condition after the 2nd dressing

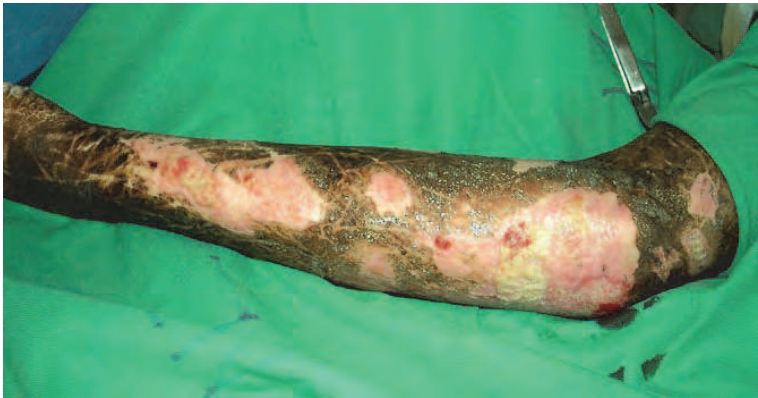

Fig. 8. Wound condition after the 3rd dressing – epithelialized surface with scattered small wounds and distinguished hyperpigmentation resulted from the application of the silver dressing

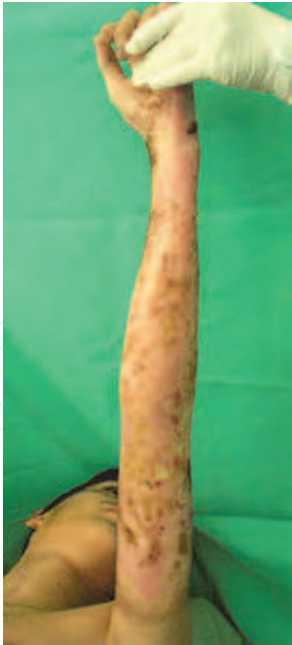

Fig. 9. The 16th day after burn. Full epithelization with disappearing hyperpigmentation

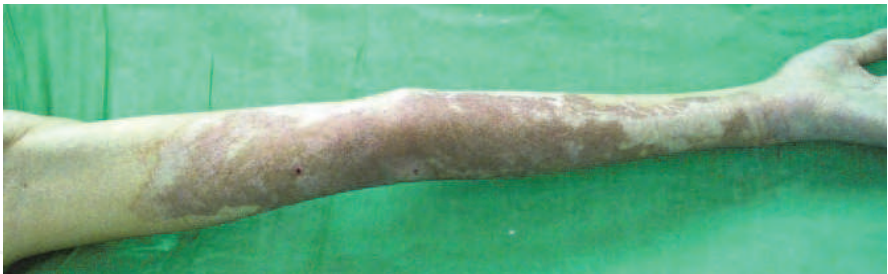

Fig. 10. Final outcome

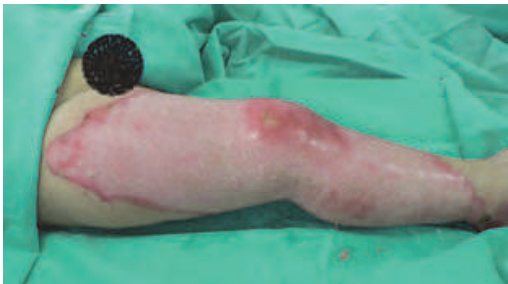

Fig. 11. Scalding of the right leg

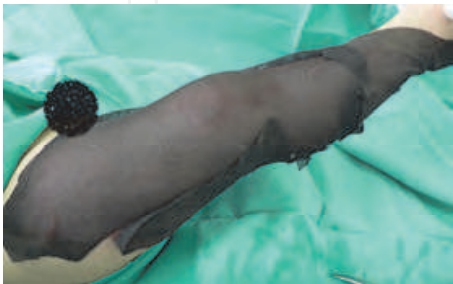

Fig. 12. Covering the wound with Acticoat Flex 7

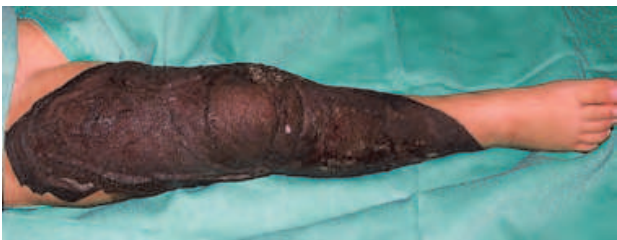

Fig. 13. The result after the 1st dressing on the 7th day of the treatment

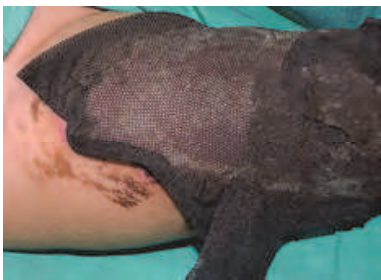

Fig. 14. Epithelializing wound covered with Acticoat Flex

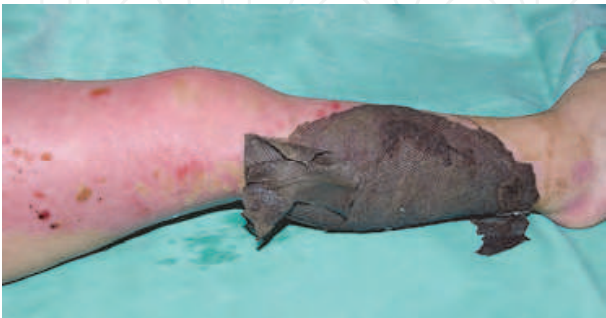

Fig. 15. The 12th day of the treatment - fully epithelialized wound of the thigh and progressing wound epithelization of the lower leg

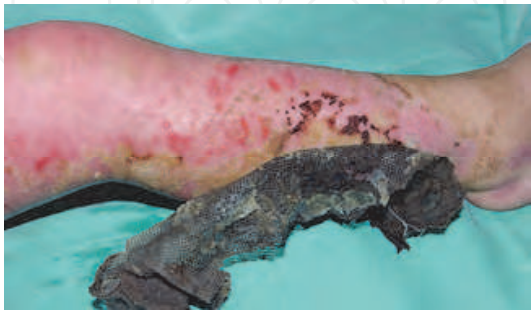

Fig. 16. Early result (15th day) - removing of the dressing after moistening. The wound is almost fully epithelialized

The dressing was applied on 19 children from the second group with deep burns with various area (from 0.5% to 95%, mean - 15.76%) and various localization. All children underwent operation. An early surgical excision at one, two or three stages was performed on 16 children between the 2nd and the 6th day after the burn. Three children were operated on after the 10th day of the burn. The dressing changes for this group conformed to the times of surgical treatment. On those patients operated on after the 10th day, the dressing was applied according to the described standard method. The demarcation and separation of the devitalized tissue in these patients occurred after the second or third dressing. The burns were clear and without exudation. The formed necroses were greenish and not dry for Acticoat™, while those for Acticoat Flex were greenish-brown and drier. Dressing removal was easy and without bleeding, and a clear wound with a short and fresh granulation was formed, ready for autografting.

In 5 children from the third group, Acticoat was applied on fresh excised sites of burn wounds (mean area of 6.75%), where multistage excision was carried out. After the dressing removal, the excised site was covered with bright yellow coating without smell and exudation. This coating could be easily removed and the wound area was fresh and ready for autografting without any additional surgical treatment. Hyperpigmentation of the wound was not observed.

The dressing was applied on autografts in 5 of the clinically monitored children, who had above 15% burn and deep burn area ranging from 6% to 72%. Using the standard method, Acticoat was applied directly on the autografts, which had various areas (300 cm² to 800 cm²) and was meshed at 1:2 ratio using mesh-graft dermatome (1:4 ratio for one patient only). The dressing was removed on the 4th day after the operation (in two children on the 5th day) and well-healed autografts with hyperpigmentation, scant smell and without exudation was observed. The epithelization of the mesh splits was 95%.

In 5 children, the dressing was applied on fresh donor sites situated on the thighs. The autografts with thickness of 0.2 - 0.5 mm were harvested from these areas with electric dermatome. The standard way of dressing application was used. After the removal of the dressing on the 4th day, the donor site had pink colour and was covered with silver scattered particles. This site did not have any smell, exudate or coating. Epithelization of 95% occurred in one child on the 4th day. The complete epithelization occurred in the remaining patients within 8 days after the dressing application. Hyperpigmentation of the intact skin was observed in all patients. The donor sites were monitored up to six months after the epithelization and there were no signs of hypertrophic scarring according to the Vancouver Scar Scale (VSS).

The following figures demonstrate a clinical case with Acticoat™ application (Figures 17-28): i) treatment of deep burns localized on the legs; ii) application on excised area; iii) application on auto- and allograft; iv) application on donor sites.

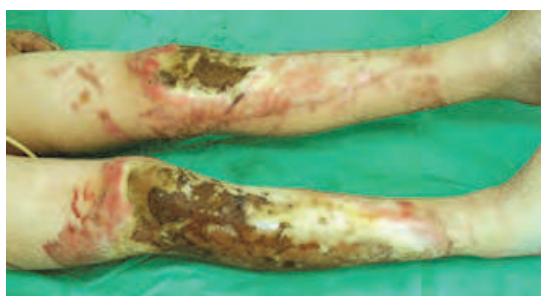

Fig. 17. Deep burn



Fig. 18. Application of Acticoat™ as a pre-operative preparation

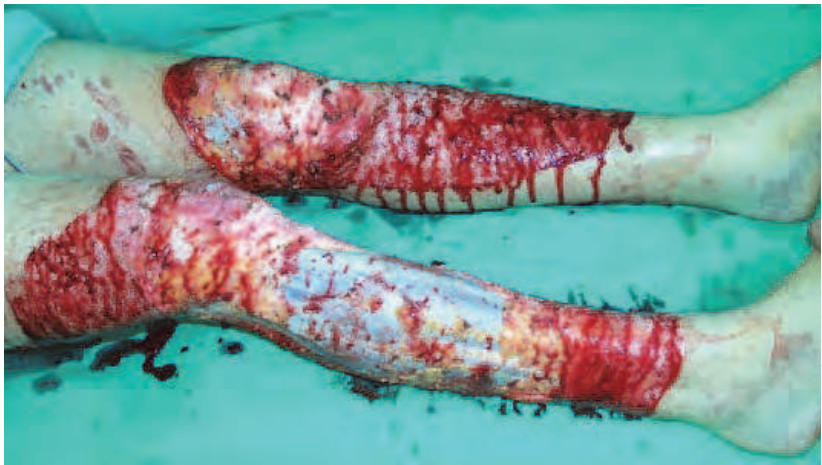

Fig. 19. Total surgical excision

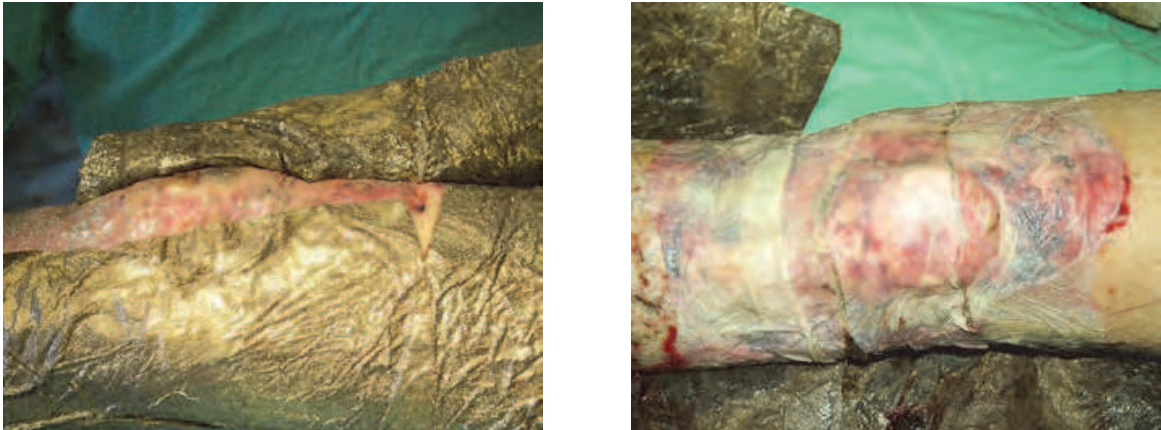


Fig. 20. Application of Acticoat™ on fresh autograft

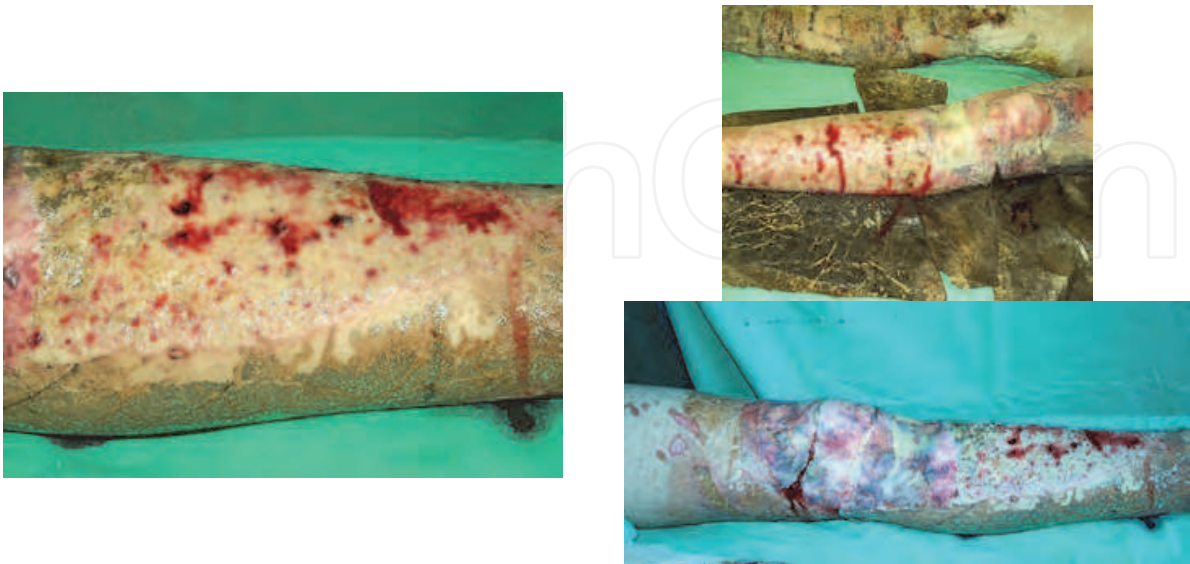

Fig. 21. A stable whole autograft on knee and condition of the excised site on the lower leg after Acticoat™ removal

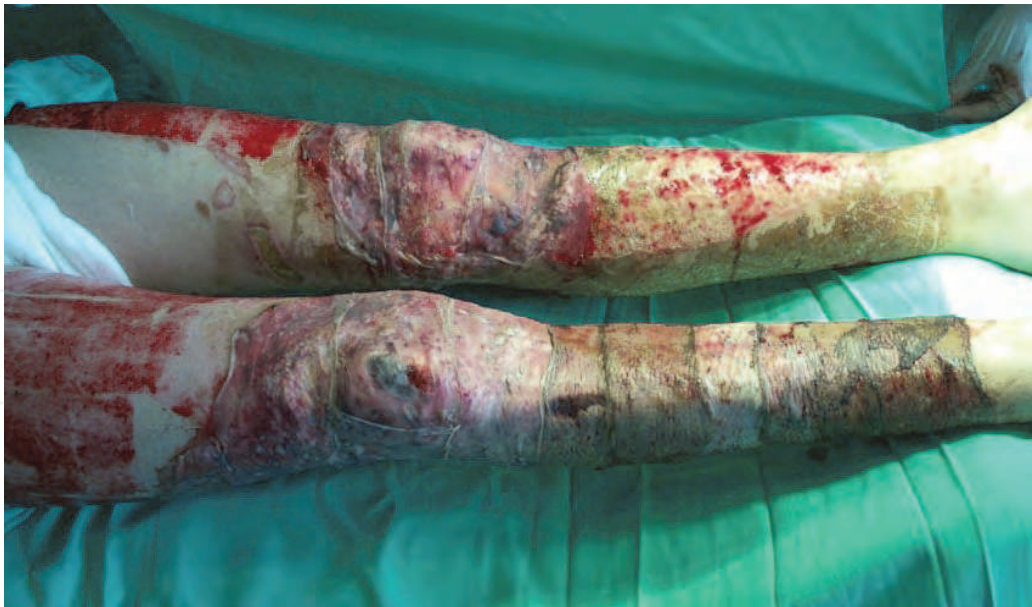

Fig. 22. A stage of the treatment – healed autografts in the knee area, healed autografts in the right lower leg; and clinical condition of the excised site on the left lower leg after Acticoat™ application

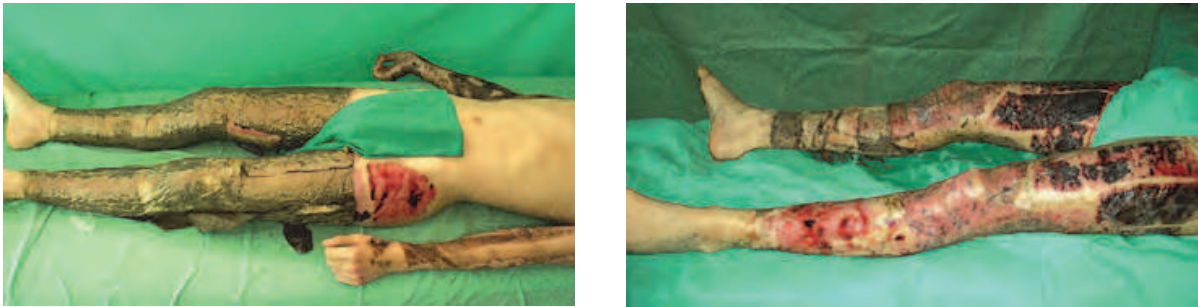


Fig. 23. Autografts covered with Acticoat and donor sites on both legs

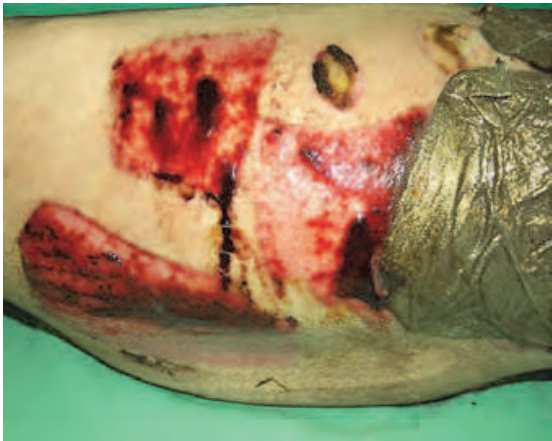

Fig. 24. Donor sites after the 1st Acticoat™ dressing

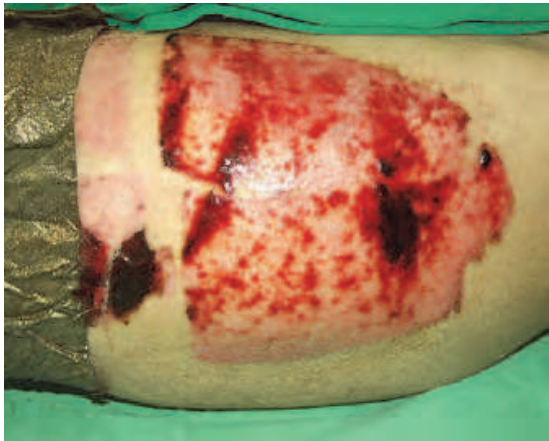

Fig. 25. Epithelialized donor site at the 2nd dressing and neighbouring donor site after the 1st dressing

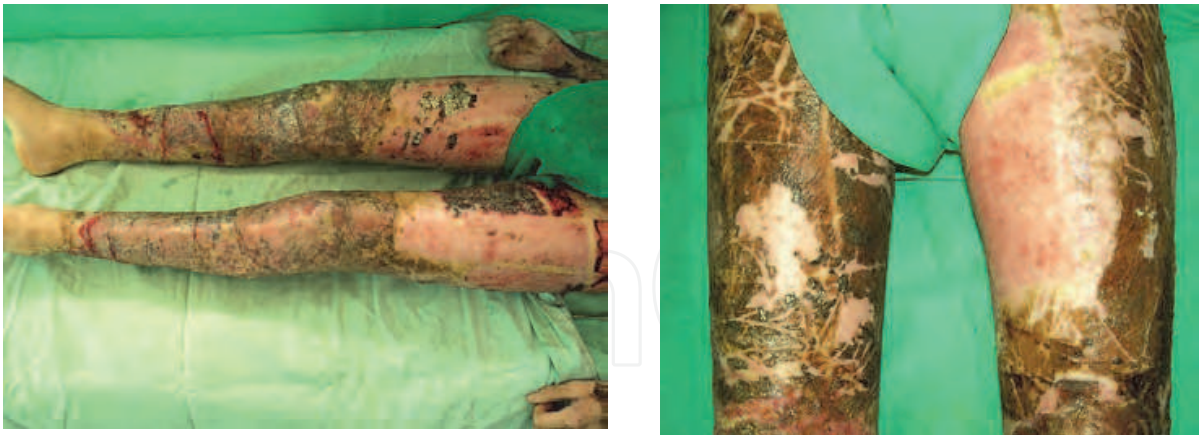

Fig. 26. Wounds covered with stable autografts and fully epithelialized donor sites. Persistent hyperpigmentation on operated and donor sites due the Acticoat™ use

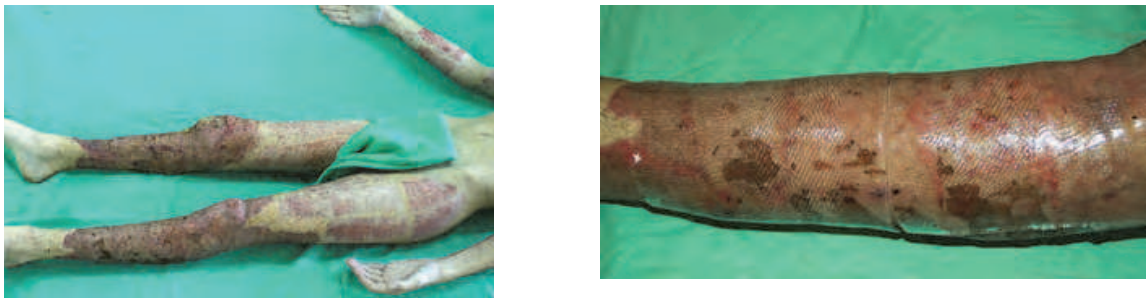

Fig. 27. Outcome at the end of the treatment and beginning of the prophylaxis of the scars with silicone sheets

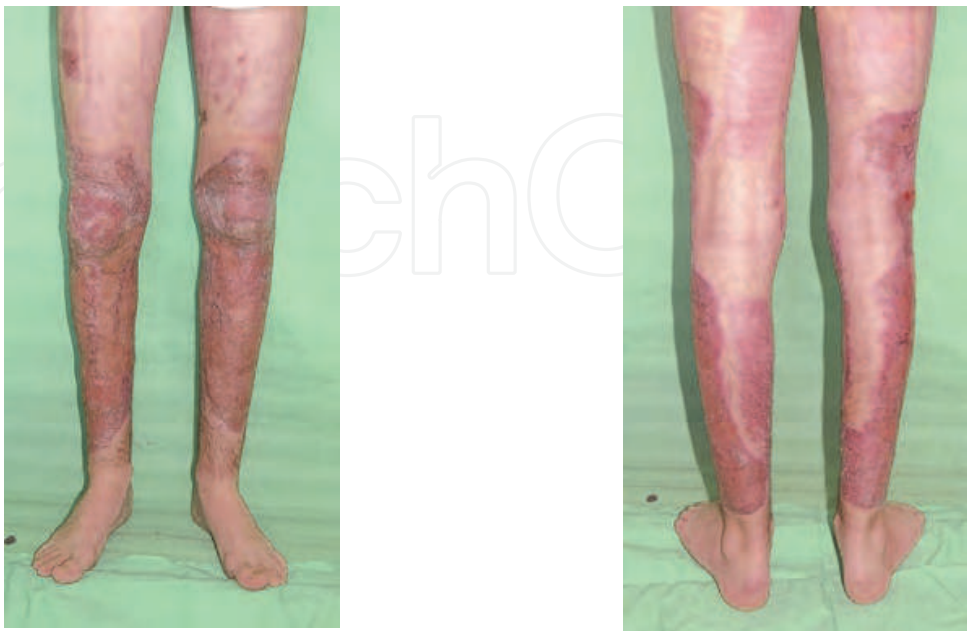


Fig. 28. The patients after the end of the treatment

3.2 Clinical observation of the wounds treated with Dermazin

The application time of the agent was registered until the beginning of stable epithelization of the wound in the patients with superficial burns. In the deep burns, this period included the time until the wound clears or the surgical treatment begins. The local treatment continued further with other agents for both groups of patients, depending on the wound type. In 32 patients with superficial burns, on which Dermazin was applied, the wounds were covered with “an abundant amount of fester-like exudate”, which created an impression of worsened local status (Figure 29). The bacteriological analysis showed that in most of the cases this exudate was sterile and was caused by the mixing of the wound exudate and the agent. Forming of “pseudonecrosis”, which was difficult and painful to remove, was observed (Figure 30). For this reason, the dressing change required general anaesthesia even in burns with small area. Moist and soft necroses with grey metallic colour, which were irremovable, were observed in deep-dermal and deep burn wounds (Tonkin & Wood, 2005). In patients who did not undergo operations, these necroses were slowly and tangentially detached in due course. In case of local infection, the dressings were wet at the time of dressing change due to the abundant amount of exudates, while swelling, reddening, firm wound edges and smell were observed.

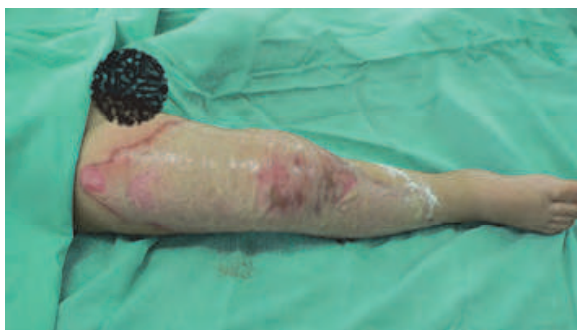

Fig. 29. Clinical state of a wound treated with Dermazin

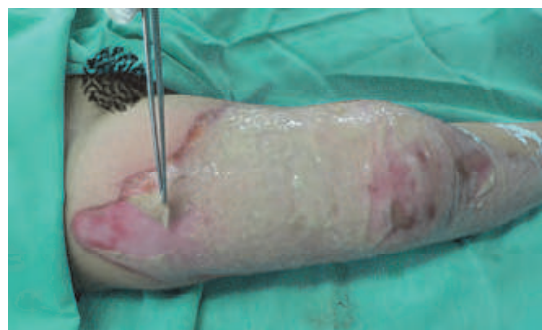

Fig. 30. Formed “pseudonecrosis” after the treatment with Dermazin

3.3 Bacteriological analysis

Acticoat is a dressing with a silver coating and unique physical structure of silver nanocrystalline, which in a moist environment provides a long-lasting and steady release of free silver ions and radicals on the surface of a burn wound. Although **Acticoat** releases 30 times less silver than 0.5 per cent solution of silver nitrate (AgNO_3) and SSD, it has a much quicker and more powerful antibacterial effect. It is an effective agent against Gram-positive and Gram-negative microorganisms, including aerobic and facultative anaerobic organisms and fungi. It is effective against all pathogenic microorganisms isolated from burn wounds, especially *Pseudomonas aeruginosa*, *Staphylococcus aureus* – MRSA and VRE (Tredget et al., 1998). Its antiseptic effect is revealed within 30 minutes of the application and lasts up to 3 days (Wright et al., 1999). The Minimum Inhibitory Concentration (MIC) and the Minimum Bactericidal Concentration (MBC) of the three silver dressings (**Acticoat**, AgNO_3 and SSD) have been spectrophotometrically studied, determined and compared using five bacterial strains, which are of clinical interest (Demling & DeSanti, 2002). **Acticoat** has the lowest MIC and MBC in comparison with the other two silver dressings. Due to these laboratory proven results, a preliminary in vitro analysis has not been carried out. The

investigation of the results from the bacteriological analysis after the **Acticoat** application indicates that (Figures 31-35):

- The wounds of 96 children (86%) were without bacterial growth at the beginning of the treatment with **Acticoat** and remained unchanged in 95 children until the end of the treatment.
- A Gram-positive and Gram-negative flora was isolated in 16 children at the beginning of the treatment (5 with *Staph.aureus-MRSA*, 2 with *Str.β haemoliticus* and 6 with *Staph.epidermidis*).
- In one child with uncontaminated wound at the beginning of the treatment, the wound became colonized by *Ps. aeruginosa* (microbial number was below the critical value of 10^3 , 10^2) during the treatment course.
- Bacterial growth was not observed in 109 children (97%) at the end of the treatment. Contaminated wounds of two children at the beginning of the treatment remained unchanged even after the third dressing, but the microbial number was below the critical values (1 child with *Ps. aeruginosa* 10^3 and 1 child with *Staph.aureus-MRSA* 10^2).

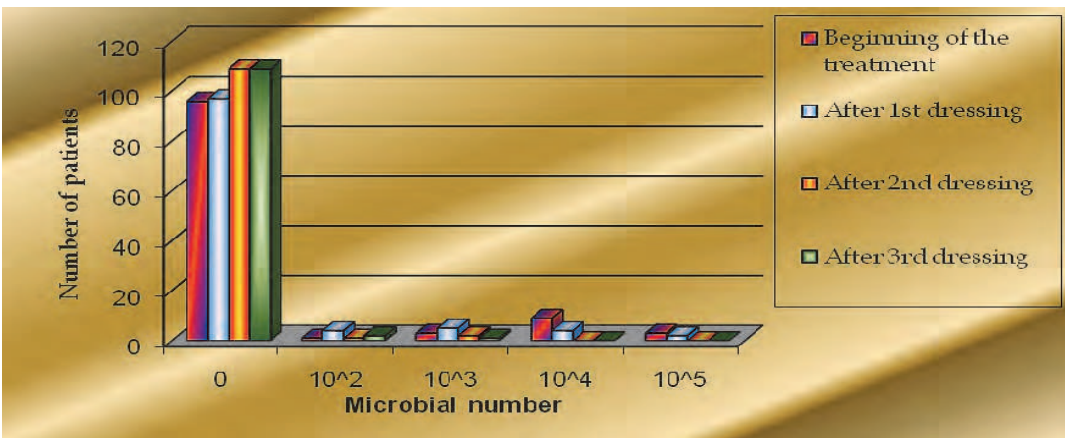


Fig. 31. Bacterial growth distribution during the treatment with Acticoat

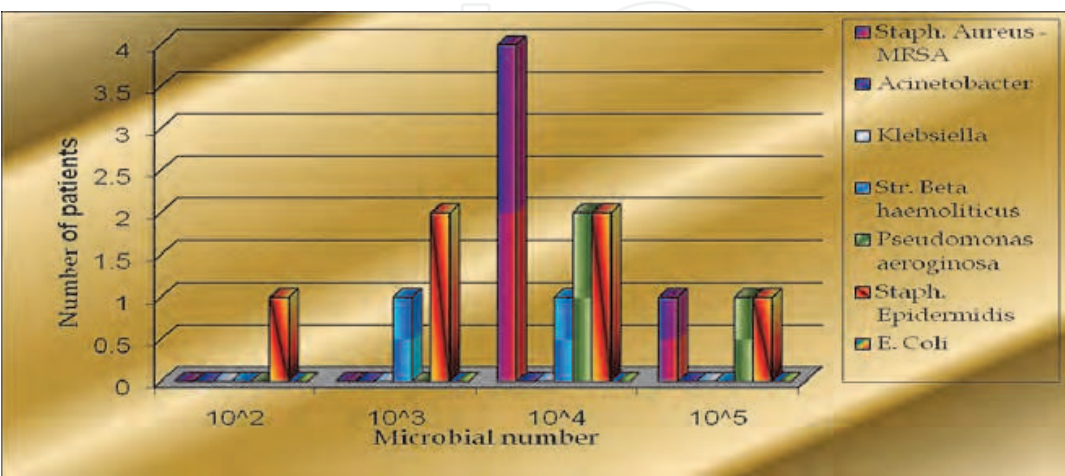


Fig. 32. Distribution of the bacteria and bacterial growth at the beginning of the treatment with Acticoat

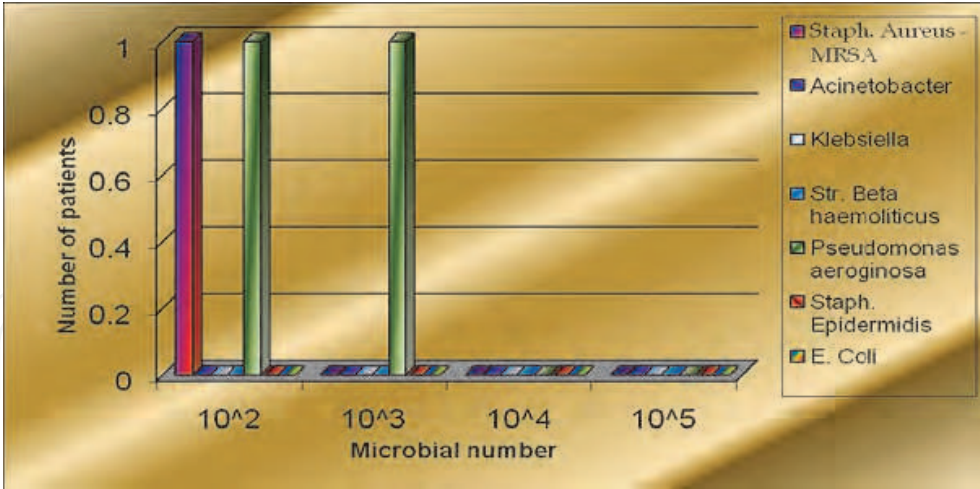


Fig. 33. Distribution of the bacteria and bacterial growth at the end of the treatment with Acticoat

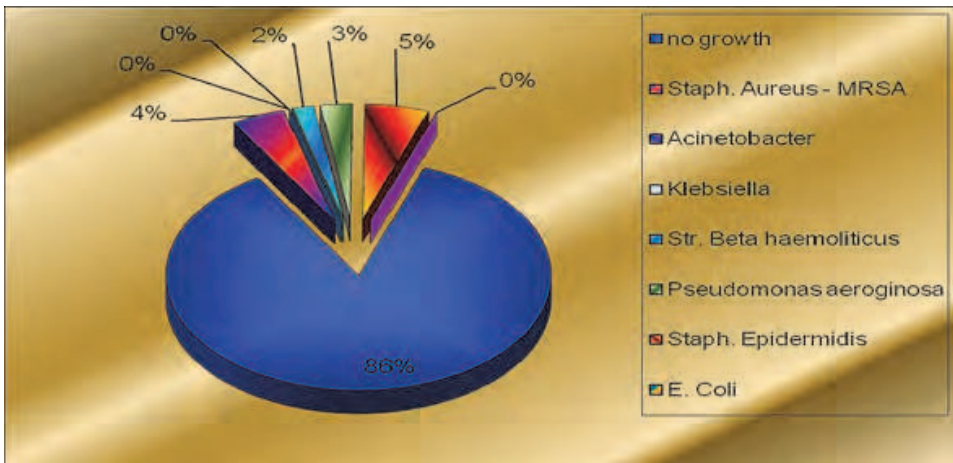


Fig. 34. Distribution of the bacteria at the beginning of the treatment with Acticoat

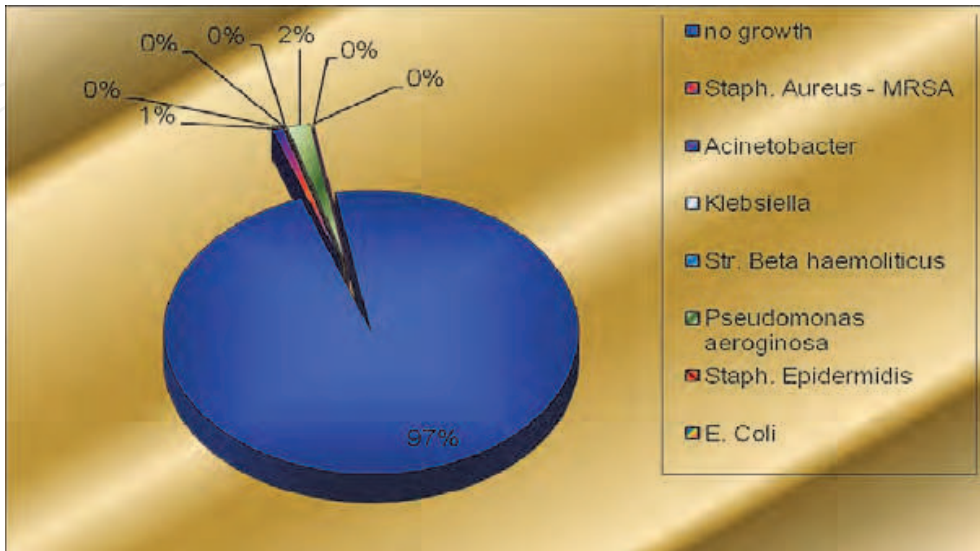


Fig. 35. Distribution of the bacteria at the end of the treatment with Acticoat

4. Comparative analysis between Acticoat™ and SSD (Dermazin)

4.1 Comparative bacteriological analysis between Acticoat™ and SSD (Dermazin)

A comparative bacteriological analysis between Acticoat™ and SSD (Dermazin) has been carried out. The following parameters have been monitored:

- The type of the bacterial flora (wound surface swab) before the Acticoat™ application;
- The type of the bacterial flora (wound surface swab) after each removal of the dressing. The dressings were changed every 3 days according to the already described way;
- The quantity of the bacterial flora (tissue biopsy samples) in gram wound tissue (microbial number), before and after the application of the agent. The critical value for development of a local and general infection of the wound is 10⁵ bacteria per gram tissue (b/gr).

The performed prospective clinical study comprised 111 patients – 68 (61.26%) of them were treated with Acticoat™ and 43 (38.74%) with Dermazin. The gender distribution is: 67 males (60.36%) and 44 females (39.64%). The average age of these children was 4.78±4.38 years in the age range of 9 months – 18 years. The total number of the burns was 265: 151 (56.98%) of which were treated with Acticoat™ and 114 (43.02%) with Dermazin.

4.1.1 Results

It could be seen from Tables 1 and 2 that the patients included in the sample do not statistically differ with respect to age, burn area and burn depth. The further analysis shows that there is no significant difference of gender distribution. The initial similarity of the main confounding factors gives a good basis for the comparison of the outcome obtained from the treatments with the two agents.

Parameter	Treated with Acticoat™			Treated with Dermazin			p
	N	\bar{X}	SD	N	\bar{X}	SD	
Age	66	4.65	4.11	43	4.97	4.80	n.s.
Burn area	68	7.65	5.95	43	9.95	7.84	n.s.

Table 1. Comparative analysis of the age and burn area of the patients treated with the studied agents (\bar{X} - mean value, SD- standard deviation, N- number, n.s. – not significant)

4.1.2 Initial status of the patients treated with the two agents with respect to bacterial flora

It is clear from Table 3 that bacterial flora is registered in 17.65% of the patients treated with Acticoat™ and in 13.95% of those treated with Dermazin. The Fisher’s exact test classifies the difference with respect to this parameter as non-significant. The ratio of the bacterial findings deep in the wound was identical to those on the surface at the beginning of the treatment.

4.1.3 The status of the bacterial flora on 4th day after the first dressing

The technology of treatment with the two agents allows comparison of impact only on the 4th day after the first dressing. The bacterial flora decreased from 17.65% at the beginning of

Degree	Statistics	Agent		Total
		Acticoat™	Dermazin	
II A	Number	54	38	92
	% w.r. degree	58.70	41.30	100.00
	% w.r. agent	40.91	43.18	41.82
II B	Number	62	40	102
	% w.r. degree	60.78	39.22	100.00
	% w.r. agent	46.97	45.45	46.36
III	Number	16	10	26
	% w.r. degree	61.54	38.46	100.00
	% w.r. agent	12.12	11.36	11.82
Total	Number	132	88	220
	% w.r. degree	60.00	40.00	100.00
	% w.r. agent	100.00	100.00	100.00

Table 2. The sample participants distribution with respect to the burn degree and agent (w.r. - with respect to)

Bacterial flora on the surface	Statistics	Agent		Total
		Acticoat™	Dermazin	
Absence	Number	56	37	93
	% w.r. flora	60.22	39.78	100.00
	% w.r. agent	82.35	86.05	83.78
Presence	Number	12	6	18
	% w.r. flora	66.67	33.33	100.00
	% w.r. agent	17.65	13.95	16.22
Total	Number	68	43	111
	% w.r. flora	61.26	38.74	100.00
	% w.r. agent	100.00	100.00	100.00

Table 3. The sample participants distribution with respect to the agent and existence of bacterial flora (w.r. - with respect to)

the treatment up to 16.18% on the 4th day for **Acticoat™**, while an increase from 13.95 up to 25.58% was observed in the patients treated with **Dermazin**. The change is significant, but it is in favour of the treatment with **Acticoat™**. On the 4th day of the treatment the ratio of the bacterial findings deep in the wound was completely identical to that on the surface. The dynamics of the change of the bacterial findings for the two agents on the 1st and 4th (Figure 36).

The dynamics of the change of the bacterial flora on the surface, treated with the two agents, showed that from 4 bacterial findings of Staph.aureus - MRSA at the beginning of the treatment with Acticoat™ only one was isolated on the 12th day, whereas from 3 bacterial findings of Pseudomonas aeruginosa two were present, while the other initial bacterial findings were killed.

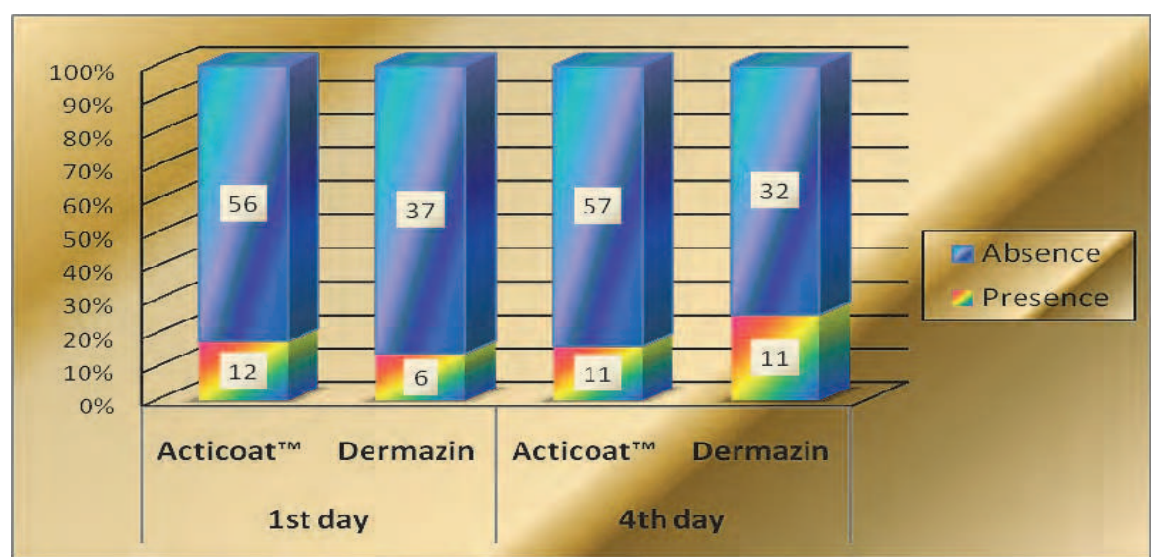


Fig. 36. The dynamics of the bacteria change for the two agents on the 1st and 4th day

In the treatment with Dermazin, an increase in the present bacterial findings or appearance of new ones in the course of treatment up to the 4th day were observed. This is most pronounced for *Acinetobacter* and *Pseudomonas aeruginosa* with respect to quantity. There was a decrease in *Staph.aureus* - MRSA from 5 to 3 findings and complete clearing of *Str.beta haemoliticus* (from 1 to 0), but the sterility as a whole aggravated for this agent on the 4th day (Figures 37-39).

The results of the deep analysis of the bacterial flora also showed the advantages of the treatment with Acticoat™ (Figures 40-42). The patients treated with Acticoat™ have worse bacteriological status in the beginning and significantly better dynamics on the 4th day of the treatment, while a worsening of the sterility in the deepness is observed for the patients treated with Dermazin. In one patient treated with Acticoat™, bacterial flora was observed only on the surface, but not in the deepness on the 8th and 12th day.

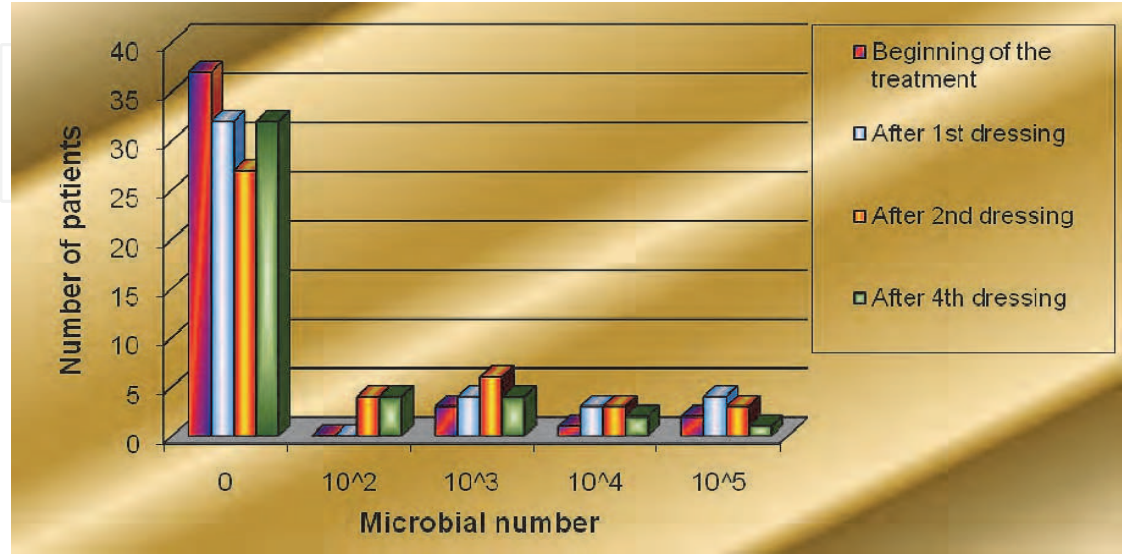


Fig. 37. Bacterial growth distribution during the treatment with Dermazin

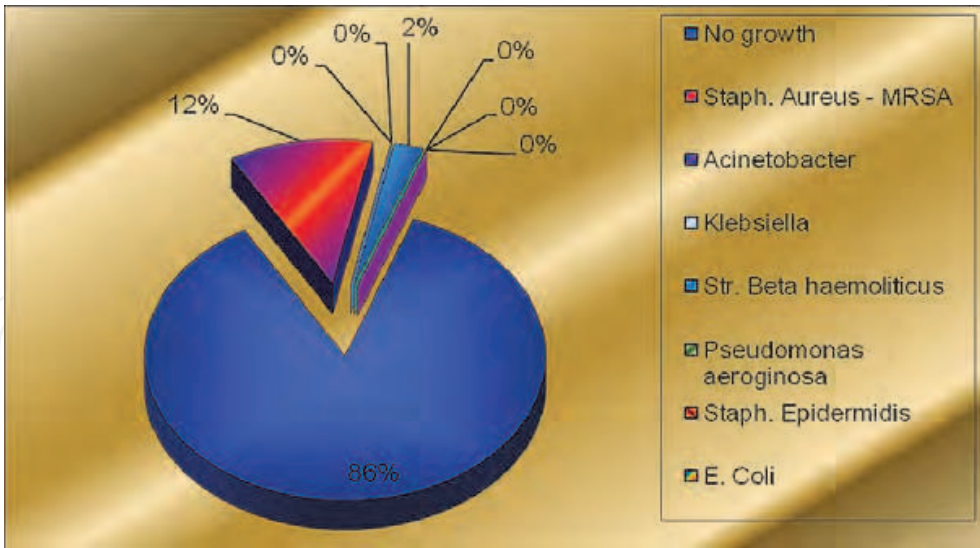


Fig. 38. Distribution of the bacteria at the beginning of the treatment with Dermazin

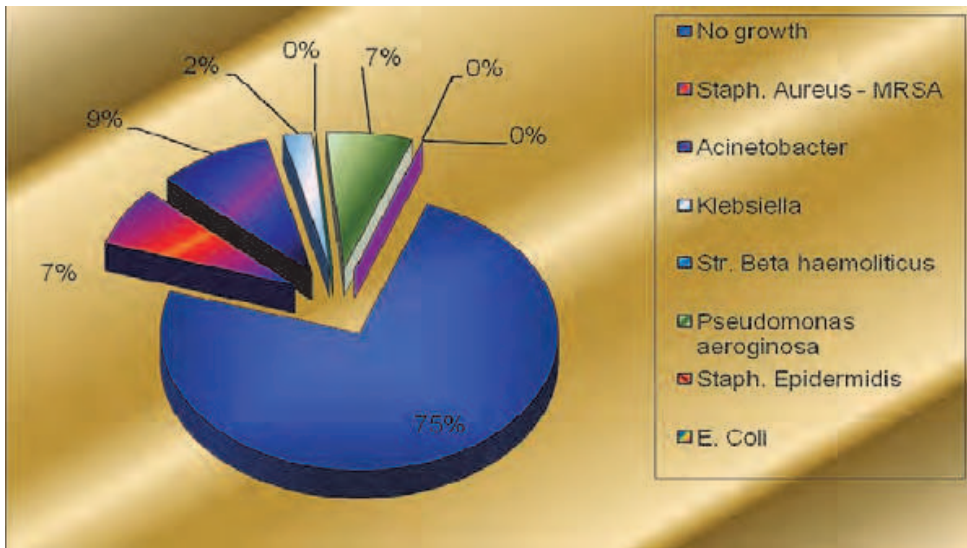


Fig. 39. Distribution of the bacteria at the end of the treatment with Dermazin

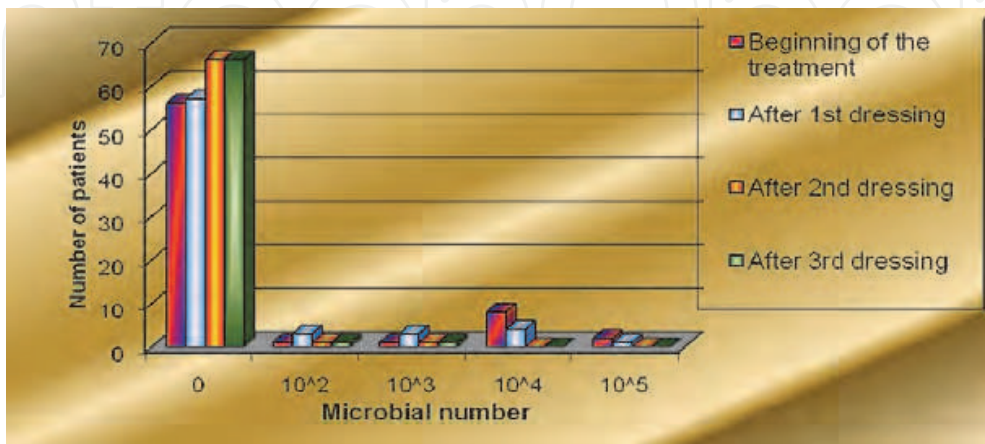


Fig. 40. Bacterial growth distribution during the treatment with Acticoat

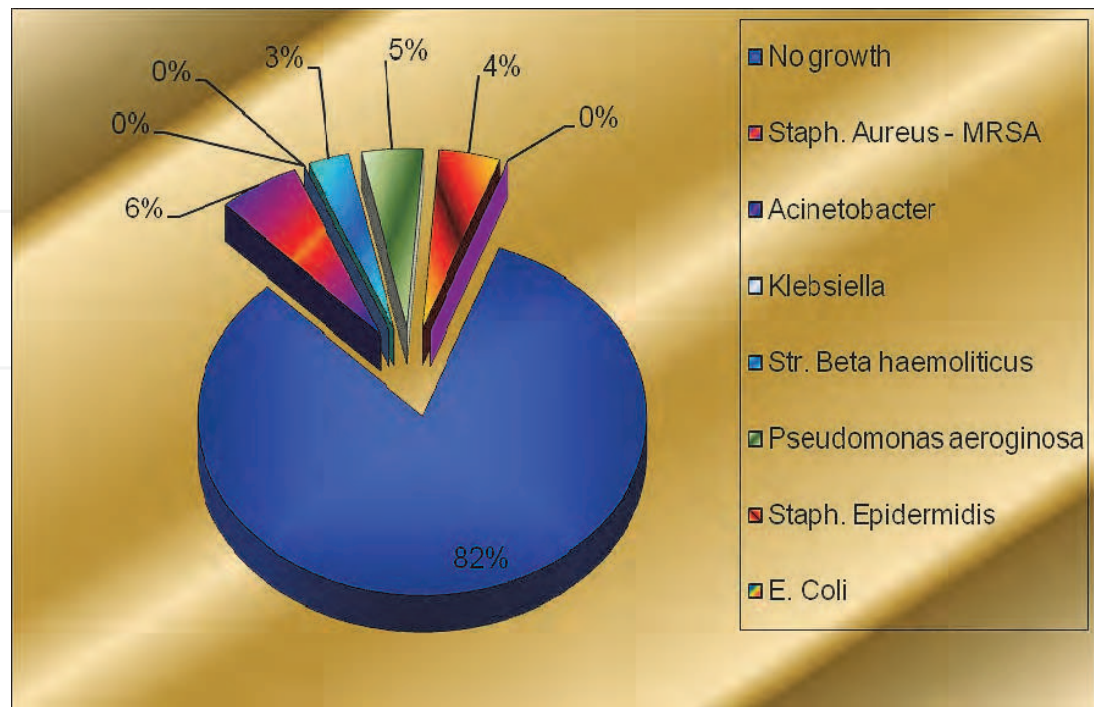


Fig. 41. Distribution of the bacteria at the beginning of the treatment with Acticoat

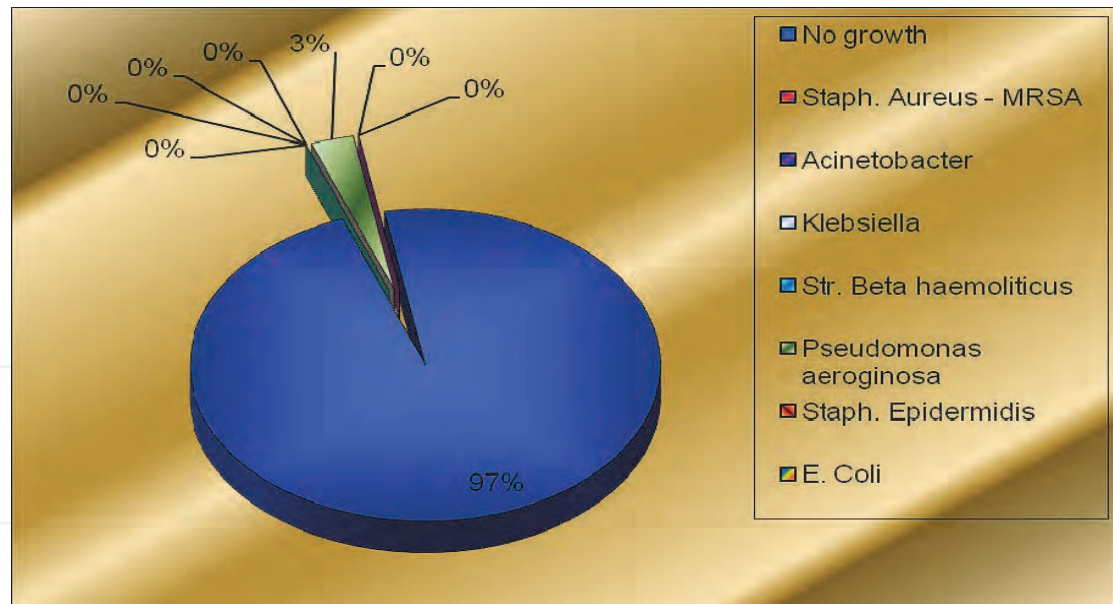


Fig. 42. Distribution of the bacteria at the end of the treatment with Acticoat

4.2 Comparative analysis of the patients treated with the two agents with respect to clearing time, epithelization and hospital stay

The results unambiguously illustrated that Acticoat™ possesses significantly better therapeutic effect in comparison with Dermazin (Figures 43-56; Table 4). It was clear that the burns treated with Acticoat™ had significantly shorter clearing/ epithelization time and hospital stay (Table 4).

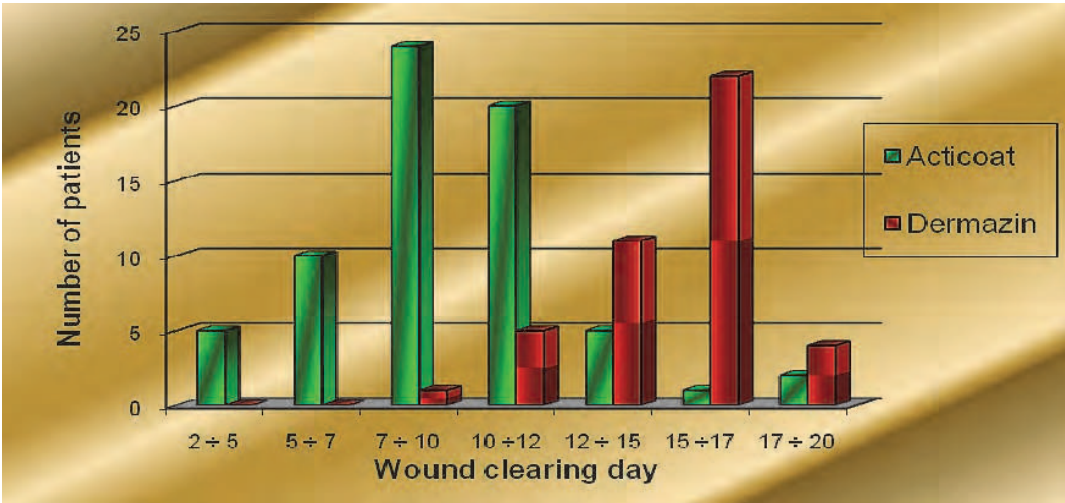


Fig. 43. Distribution of the wound clearing time

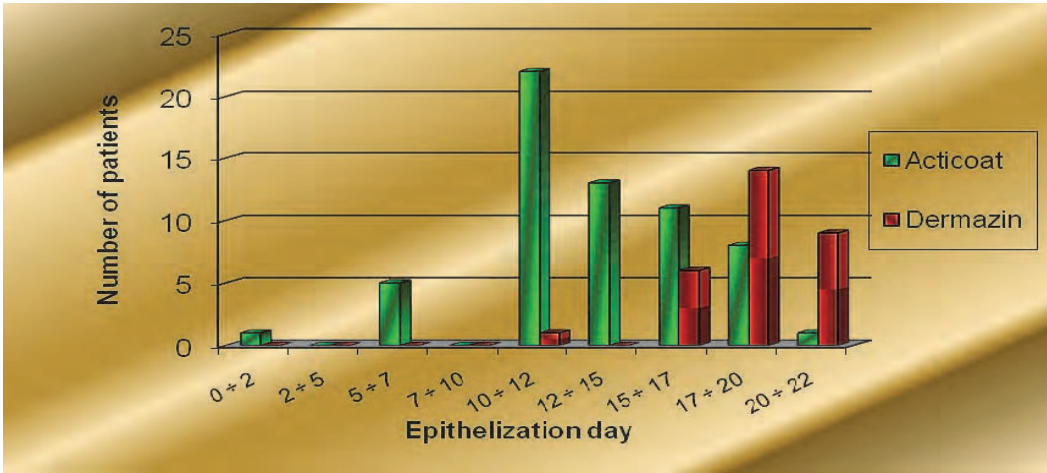


Fig. 44. Distribution of the wound epithelization time

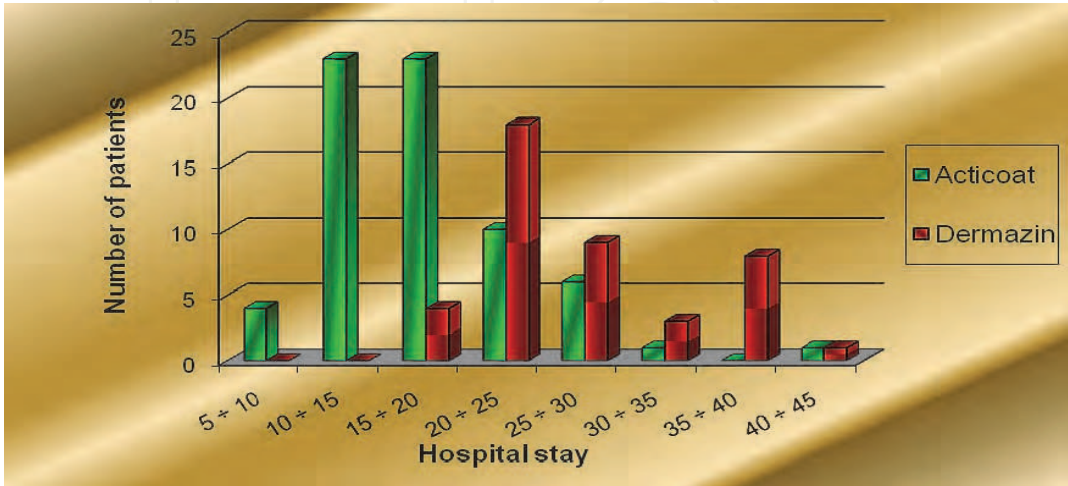


Fig. 45. Distribution of the hospital stay

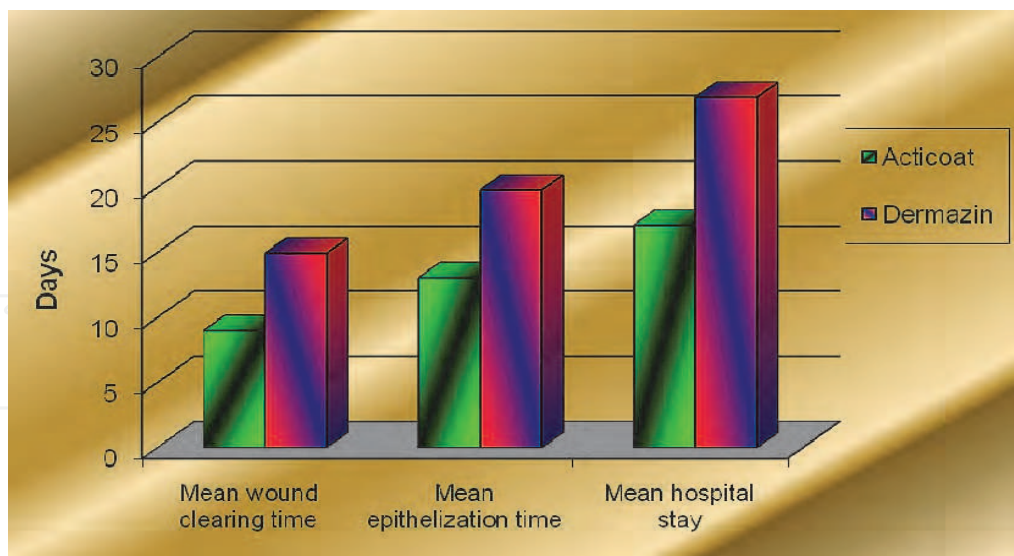


Fig. 46. Mean wound clearing time, mean epithelization time and mean hospital stay

Parameter	Treated with Acticoat™			Treated with Dermazin			p
	N	\bar{X}	SD	N	\bar{X}	SD	
Clearing day	66	8.92	3.16	43	14.93	2.20	<0.001
Epithelization time (days)	60	12.98	4.02	39	19.79	3.02	<0.001
Hospital stay (days)	66	16.95	6.19	42	26.90	6.91	<0.001

Table 4. Comparative analysis of the patients treated with the studied agents with respect to clearing time, epithelization time and hospital stay

The performed comparative statistical analysis (t-test) reveals that the differences of application of **Acticoat™** and **Dermazin** were statistically significant. The obtained p-value for the three tests (comparison of the clearing time, epithelization time and hospital stay for the two agents) was $p<0.01$. The Mann-Whitney test was applied for the statistical analysis of the bacterial growth (microbial number) and the obtained value ($p=<0.01$) implied that the difference of application of **Acticoat™** and **Dermazin** for the treatment of the monitored patients was statistically significant. This analysis showed statistically significant differences between the application of **Acticoat™** and **Dermazin** with respect to the clearing time, epithelization time, hospital stay and microbial growth.

The comparative clinical and microbiological analysis between the two silver agents revealed that treatment with **Acticoat™** achieves better efficacy in killing superficial and deep bacterial flora and yielded faster wound clearing, epithelization and shorter hospital stay.

4.3 Side effects

Three children of the observed contingent treated with **Acticoat™** developed rash, which was transient and faded quickly. The most probable reason for the rash was due to the

occlusive effect of the dressing caused by the polyurethane foil. Toxic effects were not observed. The hyperpigmentation of the intact skin was transient and disappeared within 14 days after the end of the treatment or dressing change. In the children of the control group with **Dermazin** no toxic and allergic reactions were observed. Cases of argyria were not observed.

4.4 Comparative cost analysis between Acticoat™ and SSD (Dermazin)

The comparative cost analysis was based on the treatment of a burn wound of second degree (IIAB) with 2000 cm² area. One surgeon, one anaesthesiologist, one surgical nurse, one anaesthetic nurse and one hospital attendant were involved for application of both agents. Table 5 shows the cost comparison of both agents.

	Acticoat™	Dermazin
Labour cost per dressing (L)	€ 13.36	€ 13.36
Materials per dressing (M)	€ 311.65	€ 93.60
Total Cost per dressing (L+M)	€ 325.01	€ 106.96
Dressing numbers (n)	4	20
Total (Euros) - (L+M)*n	€ 1300.04	€ 2139.20

Table 5. Comparative cost (in Euros) analysis of the treatment of a burn (2000 sm²) of second (IIAB) degree for both agents

The cost comparative analysis demonstrated that the treatment of a second degree (IIAB) burn wound (2000 cm² area) with Dermazin was more expensive by approximately € 839 (65% more expensive) than the treatment with Acticoat.

5. Discussion

General concepts and techniques for treatment of all wounds are applied regardless of the mechanism causing the wound. The key to high quality and proper local treatment is the correct and complete assessment of the burn wound. This includes etiology, localization, area (cm²), depth, exudation (quantity, type, colour), smell, appearance of the wound surface, appearance of the intact skin, presence of pain, and prior treatment method. The treatment goals are determined on the basis of proper assessment preceding the treatment. The burn wound changes dynamically depending on inner (release inflammatory mediators, bacterial proliferation) and outer (dehydration, hypotension and cooling) factors. Thus, the applied local agent is subjected to permanent control (both objective and subjective). The perfect dressing for children should provide optimal protection, reparation and minimization of the pain (Khundkar et al. 2010).

Silver-impregnated Acticoat™ dressing has been used in the Clinic of Burns at the “Pirogov” Emergency Hospital since 2004 and has gradually prevailed as the standard dressing in the treatment of burn wounds and post-traumatic defects. The clinical studies, conducted in the Clinic of Burns in Children in the second half of 2009 and 2010, demonstrate the advantages of topical treatment with nanocrystalline silver and was concluded that the agent was efficient in all cases and was easily tolerated. The less frequent and atraumatic dressing changes make this agent a preferable one for children. The clinical

observations of the use of Acticoat™ and the comparative analysis with Dermazin show that the time of dressing changes is reduced by 50%, since the dressing change is every 3rd day, in contrast to the Dermazin dressing, which has to be changed every 12 hours. This yields a reduced use of sedative and narcotic agents applied in dressings as well as less stress in dressing change, respectively (Probert & Burston, 2005).

Prior to the development of this type of dressing, it was considered that moist environment contributes to increased risk of infection. The clinical observations of many authors (Ang et al., 2003; Fong & Wood, 2006; Wright, et al. 2002) as well as our own studies reject such concern. Dermazin and other types of SSD extract water from the wound surface as a result of the cream hyperosmolarity, which requires frequent change. All the advantages, which the moist environment has for the healing process, pose the question of maintaining the moisture (Fong, 2005). The moistening of Acticoat has double effect – to maintain the moist environment in the wound and to release the antimicrobial power of nanocrystalline silver. The results (clinical and bacteriological) of polyethylene foil application, as an instrument for moisture maintaining, are very good. Everyday moistening by irrigation or change of the upper gauze layers is impractical and more difficult to control. Use of Intrasite gel and Allevyn is expensive and economically disadvantageous, therefore, semi-occlusive dressings are utilized. Each modern dressing should possess the property of moisture transmission and control. The complete occlusion may create an environment for the development of facultative pathogenic microorganisms, causing infection. For this reason, the Moisture Vapour Transmission Rate (MVTR) is an important parameter for each modern dressing. A value of MVTR = 600-3000 for the polyethylene foil is determined, and a complete occlusion occurs at value <500. Excellent moisture maintaining until the next dressing change was observed in the monitored clinical contingent and maceration was not observed. The typical imbibition was temporal and disappeared immediately after the change of the dressing type or after the treatment was discontinued. In cases of infected wounds with abundant exudation, an additional moistening is not necessary because the dressing has absorption property when it comes in contact with the wound exudates.

The clinical observations on the contingent studied confirm these properties of Acticoat. The comparative study carried out in the clinic shows that the mean time for the wound clearing is 8.92 days for Acticoat, whereas for Dermazin it is longer – 14.93 days. Correspondingly, the epithelization time is shorter for Acticoat (mean =12.98 days), while for Dermazin the mean epithelization time is 19.79 days. This parameter is particularly essential in the treatment of second-degree (IIA and IIB) burns, which epidemically have the highest incidence rate, and in the treatment of the so-called “mixed burns”, in which the epidermis is completely damaged while the dermis is damaged at various levels of thickness. Contrary to deep burns, mixed burns have the capacity of spontaneous healing in case of proper treatment. The incidence rate of these burns (having in mind a total damaged body area) is high, although it has not specially been reported in the literature. While the treatment method for the first- and third-degree burns is clearly determined, the algorithm for this type of superficial burns is a dilemma (Storm-Versloot et al., 2010). In this case, the active surgical behaviour has some disadvantages, since there are not exact demarcations of the areas, which will epithelize in time and those which will not close non-operatively. Good and fast epithelization of these border burns is very important in widespread burns with vast areas of deep burn, where the shortened epithelization time contributes to the quicker decrease in the total burn area and to the increase in the area of possible donor sites (Wright et al., 2002). The shortened wound epithelization time diminishes the risk of development of

bacteraemia and septic condition, which are a major cause of death in burns. Thus, the necessity of antibiotic therapy is reduced (Tonkin & Wood, 2005). Earlier wound clearing and closing diminishes the risk of development of hypertrophic scars and joint contractures on the one hand, and contributes to the child's faster recovery, on the other. An optimum microenvironment and absence of cytotoxic factors are essential for the phase of epithelization of the wound healing process. In-vitro studies show that Acticoat is toxic to both keratinocytes and fibroblasts, suppressing proliferation at the same time (Andrew et al., 2005; Burd et al., 2007; Paddle-Ledinek et al., 2006). The monitored patients' clinical results do not demonstrate such an in-vitro effect. This is confirmed by other in vivo studies. Apart from burn wounds, the anti-inflammatory, antibacterial and epithelotonic effect of the dressing is utilized in wounds covered with fresh autografts and donor sites (Demling & DeSanti, 2002; Olson et al., 2000; Silver, 2007). A faster stabilization and re-epithelization in comparison with other types of antiseptic and epithelotonic dressings was observed. Well-healed autografts and epithelization of the mesh splits (95%), in case of Acticoat application on 5 children with fresh autografts, was observed after the removing of the first dressing. In application on donor sites (5 children) almost full epithelization (96%) was detected in one child, and in the remaining 4 children full epithelization was observed on the 8th day. The donor sites were monitored up to six months and no signs of hypertrophic scarring appeared. The bacteriological observations demonstrate the powerful antibacterial effect of Acticoat. The rate and degree of killing of microbes is higher than those of the other silver agents used so far, which is due to the specific physical-chemical structure (Dunn & Edwards-Jones, 2004). After 30 minutes, nanocrystalline silver reduces the number of viable bacteria to very low levels, while the other dressings achieve this effect after 2 hours (Wright et al., 1999; Yin, 2003; Burrell, 2003; Heggers et al., 2005; Lansdown, 2006). Pure silver ions and radicals have been shown to provide protection against a broad spectrum of bacteria (more than 150 types), viruses and fungi and especially antibiotic-resistant bacteria. This effect is prolonged and lasts up to 3 days after the dressing application. Acticoat has preventive antibacterial function, too. Applied on wounds, which have no bacterial growth, it prevents contamination. The dressing reduces the risk of wound contamination, being a highly efficient agent for the prevention of general bacterial infection, especially in widespread burns (Singh et al., 2007; Nadworny et al., 2010). This is confirmed by the microbiological studies carried out (Hadijski & Argirova, 2008). Wounds without bacterial growth at the beginning of the treatment remained uncontaminated until the end of the treatment, and only in one child local infection (below the critical values) was observed during the treatment course. From the initially contaminated wounds (in 16 children), bacterial flora with non-significant quantitative values was isolated only in 3 children at the end of the treatment. Wherever a local infection was isolated, regardless of its type, the microbial numbers remained below the critical values and signs of general infection were not observed (Figures 31-35). The antimicrobial preventive activity described is essential for the successful surgical treatment of widespread and deep burns. The bacterial monitoring of the children to whom Acticoat was applied on excised sites, autografts and donor sites (total - 15) showed a negative bacterial growth. The results of the microbiological analysis are assessed as very good in 97%, good in 2% and unsatisfactory in 1% of the cases. The use of Acticoat does not lead to the development of resistant bacterial strains. The distinct agent action -superficial and in depth - against *Ps.aeruginosa* and *St.aureus* MRSA, which is demonstrated by the obtained results, make the dressing preferable for burn wounds (Chae et al., 2010). Thus, the need of antibiotic therapy is reduced, leading to a decreased risk of

the development of multi-resistant strains. A fungal infection was not isolated in the studied children. The Acticoat™ low adherent property allows a less painful dressing change, which makes it a preferable dressing for children (Tancheva, 2008). The long-lasting activity of the dressing reduces the total number of dressing changes. This yields better comfort, mobility and ability of the patients to participate in rehabilitation programmes. In the analysis of silver serum concentrations, haematological and biochemical parameters of the patients of the studied clinical contingent, treated with nanocrystalline silver, no indication for toxicity was observed (Moiemen et al., 2011; White, 2010). Due to lack of toxic effect, it is suitable for application even on very young children, unlike Dermazin (Rustogi et al., 2005). Side effects were not observed in the youngest patient, who was 9 months old. Silver is deposited mostly in the skin, oral mucosa, gums, kidneys, liver and cornea. Excretion is done mostly by biliary way. Monitoring of the plasma levels is recommended in burns over 10% and burns of second (IIB) and third (III) degree, and especially in patients with abnormal liver and kidney function (Landsdown, 2006).

6. Conclusion

The obtained clinical results, microbiologically and statistically verified, as well as the conducted comparative study between Acticoat and Dermazin, provide reasons to consider the Acticoat silver dressing as highly efficient for application in superficial burns of second (IIA and IIB) degree, pre-surgical treatment of patients, prophylaxis and treatment of infection in burns, treatment of donor sites, excised sites and autografts.

The presented properties of Acticoat allow us to define it as one of the leading agents for local treatment of burns. During the short time of its use in our clinic, it has been recognized as a preferable agent for wound treatment. The ease of use, powerful antibacterial effect, lower frequency of dressing change, variety of sizes, good moulding, shortened time of wound clearing and epithelization, and painless dressing change are the advantages of Acticoat™ over the other silver agents used so far. Acticoat™ is significantly more cost effective than the other frequently used agent Dermazin.

7. References

- Andrew, P. et al. (2005). Evaluation of Cytotoxicity and Antimicrobial Activity of Acticoat® Burn Dressing for Management of Microbial Contamination in Cultured Skin Substitutes Grafted to Athymic Mice, *J Burn Care Rehabil*, 26, pp.238-246
- Ang, E. et al. (2003). Pain Control in a Randomized, Controlled, Clinical Trial Comparing Moist Exposed Burn Ointment and Conventional Methods in Patients with Partial-Thickness Burns, *J Burn Care Rehabil*, 2003, Sep-Oct; 24(5), pp.289-96
- Atiyeh, B.S.; Dibo, S.A. & Hayek, S.N. (2009). Wound Cleansing, Topical Antiseptics and Wound Healing, *International Wound Journal*, 6(6), pp.420-430
- Burd, A. et al. (2007). A comparative Study of the Cytotoxicity of Silver-based Dressings in Monolayer Cell, Tissue Explant, and Animal Models, *Wound Repair Regen.*; 15(1), pp. 94-104
- Burrell, R.E. (2003). A Scientific Perspective on the Use of Topical Silver Preparations. *Ostomy Wound Manage*, 49 (Suppl.): 19
- Burrell, R.E.; Wright, J.B.; Heggers, J.P. & Davis, G.J. (1999). Efficacy of silver coated dressings as barriers in a rodent burn sepsis model. *Wounds*, 11(4), pp.64-71

- Cavanagh, M.H.; Burrell, R.E. & Nadworny, P.L. (2010). Evaluating Antimicrobial Efficacy of New Commercially Available Silver Dressings. *International Wound Journal*, Oct., 7(5), pp.394-405
- Chae, J. et al. (2010). Comparison of the Efficacies of Silver-containing Dressing Materials for Treating a Full-thickness Rodent Wound Infected by Methicillin-resistant Staphylococcus Aureus: P1563, *Clinical Microbiology & Infection*, 16 Sup 2:S454, April 2010
- Cuttle, L. et al. (2007). A Retrospective Cohort Study of Acticoat™ versus Silvazine™ in a Paediatric Population, *Burns*, Sep. 2007, 33 (6), pp.701-7
- Demling, R.H. & De Santi, L.(2001). Effects of Silver on Wound Management, *Wounds*, 13 (Supp A), pp.5-15
- Demling, R.H. & De Santi, L.(2002). The Rate of Re-epithelialization Across Meshed Skin Grafts is Increased With Exposure to Silver, *Burns*, 28(3), pp.264-6
- Dunn, K. & Edwards-Jones, V. (2004). The Role of Acticoat™ with Nanocrystalline Silver in the Management of Burns, *Burns*, 30, Suppl. 1, SILS9, pp. S1-S9
- Fong, J.; Wood, F. & Fowler, B. (2005). A Silver Coated Dressing Reduces the Incidence of Early Burn Wound Cellulites and Associated Costs of Inpatient Treatment: Comparative Patient Care Audits, *Burns*, 31, pp.562-567
- Fong, J. & Wood, F. (2006). Nanocrystalline Silver Dressing in Wound Management: A Review, *International Journal of Nanomedicine*, 1(4), pp.441-449
- Fong, J. (2005). The Use of Silver Products in the Management of Burn Wounds: Change in Practice for the Burn unit at Royal Perth Hospital, *Primary Intention*, 13(4), pp. S16-S22
- Gravante, G. et al. (2009). Nanocrystalline Silver: A Systematic Review of Randomized Trials Conducted on Burned Patients and an Evidence-Based Assessment of Potential Advantages Over Older Silver Formulations, *Annals of Plastic Surgery*, 63(2), pp.201-205, August 2009
- Hadjiiski, O. & Argirova, M. (2008). Antiseptic agents containing silver components, *Handbook on Surgery with Atlas*, Vol. VII - Burns and Frostbite (Hadjiiski O. Editor), pp. 86-97 (in Bulgarian)
- Heggers, J. et al. (2005). Therapeutic Efficacy of Three Silver Dressings in an Infected Animal Model, *J Burn Care Rehabil*, 26, pp. 53-56
- Huang, Y. et al. (2007). A Randomized Comparative Trial between Acticoat and SD-Ag in the Treatment of Residual Burn Wounds, Including Safety Analysis, *Burns*, Vol. 33 (2), pp.161-166
- Khundkar, R.; Malic, C. & Burge, T. (2010). Use of Acticoat Dressings in Burns: What Is the Evidence? *Burns*, 36(6), pp.751-8
- Klasen, H. (2000). A Historical Review of the Use of Silver in the Treatment of Burns. II. Renewed Interest for Silver, *Burns*, 26, pp.131-138
- Landsdown, A.B. (2006). Silver In Health Care: Antimicrobial Effects and Safety in Use, *Curr. Probl. Dermatol*, 33, pp.17-34
- Leaper, D.J. (2006). Silver Dressings: Their Role in Wound Management, *Int Wound J*, 2006, 3, pp.282-294
- Moiemen, N.S. et al. (2011). Acticoat Dressings and Major Burns: Systemic Silver Absorption, *Burns*, 37 (1), pp.27-35

- Nadworny, P.L. et al. (2010). Does Nanocrystalline Silver Have a Transferable Effect?, *Wound Repair Regen.*, 18(2), pp.254-65
- Olson, M.E. et al. (2000). Healing of Porcine Donor Sites Covered With Silver-coated Dressings, *Eur. J. Surg*, 166(6), pp. 486-9
- Orvington, L. (2001). Nanocrystalline Silver: Where the Old And Familiar Meets a New Frontier, *Wounds*, 13(Suppl B), pp.5-10
- Orvington, L. (2001). The Role of Silver Technology in Wound Healing: Part 2 Why Is Nanocrystalline Silver Superior?, *Wounds, A Compendium Clinical Research and Practice*, 13(2)(Suppl.B), pp.5-10
- Paddle-Ledinek, J.E.; Nasa, Z. & Cleland, H.J. (2006). Effect of Different Wound Dressings on Cell Viability and Proliferation, *Plast Reconstr Surg*, 117(7 Suppl), pp.110S-118S, discussion 119S-120S.
- Probert, R. & Burston, S. (2005). Wounds with a Silver Lining, *Primary Intention*, 13(4), pp. 10-S14
- Rustogi, R. et al. (2005). The Use of Acticoat™ in Neonatal Burns, *Burns*, 31(7), pp.878-882
- Singh, V. et al. (2007). The Pathogenesis of Burn Wound Conversion, *Annals of Plastic Surgery*, 59(1), pp.109-115
- Silver, G.M. et al. (2007). A Silver-Coated Antimicrobial Barrier Dressing Used Postoperatively on Meshed Autografts: A Dressing Comparison Study, *J Burn Care Res*, 28, pp.715-719.
- Storm-Versloot, M.N. et al. (2010). Topical Silver for Preventing Wound Infection, *Cochrane Database Syst Rev*, 17;(3), CD006478.
- Tancheva, D. (2008). Burns and Frostbite, In: *Handbook on Surgery with Atlas*, Vol. VII - Burns and Frostbite (Hadjijski O. Editor), pp.222-231, "Prof. M. Drinov" Academic Publishing House (in Bulgarian)
- Tonkin, C. & Wood, F. (2005). Nanocrystalline Silver Reduces the Need for Antibiotic Therapy in Burn Wounds, *Primary Intention*, 13(4), pp.163-168
- Tredget, E. et al. (1998). A Matched-Pair, Randomised Study Evaluating the Efficacy and Safety of Acticoat Silvercoated Dressing for the Treatment of Burn Wounds, *J Burn Care Rehabil*, 19(6), pp.531-537
- White, R. (2010). Silver-containing Dressings: Availability Concerns, *Ostomy Wound Manage*, 56(8), pp.6-8
- Wright, J.B. et al. (2002). Early Healing Events in a Porcine Model of Contaminated Wounds: Effects of Nanocrystalline Silver on Matrix Metalloproteinases, Cell Apoptosis, and Healing, *Wound Repair Regen*, 10, pp.141-51
- Wright, J.B. et al. (1999). Efficacy of Topical Silver Against Fungal Burn Wound Pathogens, *Am J Inf Cont*, 27, pp.344-50.
- Wright, J.B.; Hansen, C.E. & Burrell, R.E. (1998). The Comparative Efficacy of Two Antimicrobial Barrier Dressings: In-vitro Examination of Two Controlled Release of Silver Dressings, *Wounds*, 10, pp.179-188
- Yin, H.G. (2003). Antimicrobial Effects of Acticoat Nanocrystalline Silver-Coated Dressing, *John A. Boswick - Burn and Wound Care Symposium*, Maul, Hawaii, February 2003.
- Yin, H.Q.; Langford, R. & Burrell, R.E. (1999). Comparative Evaluation of the Antimicrobial Activity of Acticoat Antimicrobial Barrier Dressing, *J. Burn Care & Rehabil*, 20, pp.195-200



Skin Grafts - Indications, Applications and Current Research

Edited by Dr. Marcia Spear

ISBN 978-953-307-509-9

Hard cover, 368 pages

Publisher InTech

Published online 29, August, 2011

Published in print edition August, 2011

The procedure of skin grafting has been performed since 3000BC and with the aid of modern technology has evolved through the years. While the development of new techniques and devices has significantly improved the functional as well as the aesthetic results from skin grafting, the fundamentals of skin grafting have remained the same, a healthy vascular granulating wound bed free of infection. Adherence to the recipient bed is the most important factor in skin graft survival and research continues introducing new techniques that promote this process. Biological and synthetic skin substitutes have also provided better treatment options as well as HLA tissue typing and the use of growth factors. Even today, skin grafts remain the most common and least invasive procedure for the closure of soft tissue defects but the quest for perfection continues.

How to reference

In order to correctly reference this scholarly work, feel free to copy and paste the following:

Maya Argirova and Ognian Hadjiiski (2011). Application of the Nanocrystalline Silver in Treatment of Burn Wounds in Children, Skin Grafts - Indications, Applications and Current Research, Dr. Marcia Spear (Ed.), ISBN: 978-953-307-509-9, InTech, Available from: <http://www.intechopen.com/books/skin-grafts-indications-applications-and-current-research/application-of-the-nanocrystalline-silver-in-treatment-of-burn-wounds-in-children>

INTECH
open science | open minds

InTech Europe

University Campus STeP Ri
Slavka Krautzeka 83/A
51000 Rijeka, Croatia
Phone: +385 (51) 770 447
Fax: +385 (51) 686 166
www.intechopen.com

InTech China

Unit 405, Office Block, Hotel Equatorial Shanghai
No.65, Yan An Road (West), Shanghai, 200040, China
中国上海市延安西路65号上海国际贵都大饭店办公楼405单元
Phone: +86-21-62489820
Fax: +86-21-62489821

© 2011 The Author(s). Licensee IntechOpen. This chapter is distributed under the terms of the [Creative Commons Attribution-NonCommercial-ShareAlike-3.0 License](https://creativecommons.org/licenses/by-nc-sa/3.0/), which permits use, distribution and reproduction for non-commercial purposes, provided the original is properly cited and derivative works building on this content are distributed under the same license.

IntechOpen

IntechOpen