

We are IntechOpen, the world's leading publisher of Open Access books Built by scientists, for scientists

6,900

Open access books available

185,000

International authors and editors

200M

Downloads

Our authors are among the

154

Countries delivered to

TOP 1%

most cited scientists

12.2%

Contributors from top 500 universities



WEB OF SCIENCE™

Selection of our books indexed in the Book Citation Index
in Web of Science™ Core Collection (BKCI)

Interested in publishing with us?
Contact book.department@intechopen.com

Numbers displayed above are based on latest data collected.
For more information visit www.intechopen.com



Indications of Skin Graft

Abdou Darwish
Minia University
Egypt

1. Introduction

The skin is the largest organ of the human body and it known as the integument or integumentary system because it covers the entire outside of the body. The skin consists of two main layers: the outer layer, or epidermis, which lies on and is nourished by the thicker inner layer, or dermis.. These two layers are approximately 0.04–0.08 in (1–2 mm) thick. The epidermis consists of an outer layer of dead cells called keratinocytes, which provide a tough protective coating, and several layers of rapidly dividing cells just beneath the keratinocytes. The dermis contains the blood vessels, nerves, sweat glands, hair follicles, and oil glands. The dermis consists mainly of connective tissue, which is largely made up of a protein called collagen. Collagen gives the skin its flexibility and provides structural support. The fibroblasts are the main cell type in the dermis and make collagen. Skin varies in thickness in different parts of the body; it is thickest on the palms and soles of the feet, and thinnest on the eyelids. In general, men have thicker skin than women, and adults have thicker skin than children. After age 50, the skin begins to grow thinner again as it loses its elastic fibers and some of its fluid content. A skin graft is used permanently replace damaged missing skin or provide a temporary wound covering. Skin is necessary because it protects the body against

Fluid loss, bacteria or virus invasion, and aids in temperature regulation. Skin that is damaged extensively by burns or non-healing wound can compromise an individual's health and well-being. Skin grafting is the next step on the reconstructive ladder for the closure of a wound that cannot be closed primarily. Skin grafts are classified as either split-thickness or full-thickness, depending on the amount of dermis included in the graft.

A partial or split-thickness skin graft (STSG) contains a variable thickness of dermis, while a full-thickness skin graft (FTSG) contains the entire dermis. Split-thickness skin grafts are further categorized as thin (0.005–0.012 in), intermediate (0.012–0.018 in), or thick (0.018–0.030 in) based on the thickness of the graft harvested. Skin grafting serves two purposes: reduce the course of treatment and improves function and appearance of the recipient area.

2. Types of skin grafts

The term "graft" by itself commonly refers to either an allograft or an auto graft. An autograft is a type of graft that uses skin from another area of the body but there has to be enough undamaged skin available and the patient has to be healthy

enough to undergo surgery. An allograft uses skin obtained from another human being. Donor skin from cadavers is frozen, stored, and available for use as an allograft. Skin taken from an animal (usually a pig) is called a xenograft because it comes from a nonhuman species. Allograft and xenograft provide only a temporary covering because of rejection by the patient's immune system within seven days. The allograft or xenograft must then be replaced with an auto graft.

2.1 Split thickness grafts

The most important part of any skin graft procedure is proper preparation of the wound. Skin grafts will not survive on tissue with a limited blood supply (cartilage, bone or tendons) or tissue that has been damaged by radiation treatment. The wound must be free of any dead tissue, foreign matter, or bacterial contamination. After the patient has been anesthetized, the surgeon prepares the wound by rinsing it with saline solution or a diluted antiseptic (Betadine) and debrides any dead tissue. In addition, the surgeon stops the flow of blood into the wound by applying gentle pressure, tying off blood vessels, or administering a medication (epinephrine) that causes the blood vessels to constrict.

Following preparation of the wound, the surgeon then harvests the tissue for grafting. A split-thickness skin graft involves the epidermis and a little of the underlying dermis; (the donor site usually heals within several days). The surgeon first marks the outline of the wound on the skin of the donor site, enlarging it by 3–5% to allow for tissue shrinkage. The surgeon uses a dermatome (a special instrument for cutting thin slices of tissue) to remove a split-thickness graft from the donor site. The wound must not be too deep if a split-thickness graft is going to be successful, since the blood vessels that will nourish the grafted tissue must come from the dermis of the wound itself. The graft is usually taken from an area that is ordinarily hidden by clothes such as the buttock or inner thigh and applied on the wound. Gentle pressure from a well-padded dressing is then applied, or a few small sutures used to hold the graft in place. A sterile non adherent dressing is then applied to the raw donor area for approximately three to five days to protect it from infection.

2.2 Full thickness grafts.

Full-thickness skin grafts may be necessary for more severe burn injuries, trauma and excision of malignancy. These grafts involve both layers of the skin. Full-thickness auto grafts are more complicated than partial-thickness grafts, but provide better contour, natural color, and contract less at the grafted site. The back and the abdomen are common donor sites for full-thickness grafts. A full-thickness graft is removed from the donor site with a scalpel rather than a dermatome. After the surgeon cuts around the edges of the pattern used to determine the size of the graft, the skin is lifted with a special hood and the fatty tissue is trimmed. The graft is then placed on the wound and secured in place with absorbable sutures.

2.3 Composite skin graft

A composite skin graft is sometimes used. A composite skin graft consists of combinations of skin and fat, skin and cartilage, or dermis and fat. Composite grafts are used in patients whose injuries require three-dimensional reconstruction. For example, a wedge of ear containing skin and cartilage can be used to repair the nose.

3. Indications of skin graft

3.1 Deep fullthickness burns

Deep full thickness burns destroy the skin and damage underlying tissues and are the most common indication For split thickness skin grafts (fig. 1) where, the skin is destroyed to its full depth, in addition to damage done to underlying tissues, and Deep full thickness burns must be covered as soon as possible to prevent infection and fluid loss. Wounds that are left to heal on their own (secondary intention) can contract and result in serious and painful scarring and actually prevent normal limb movement.

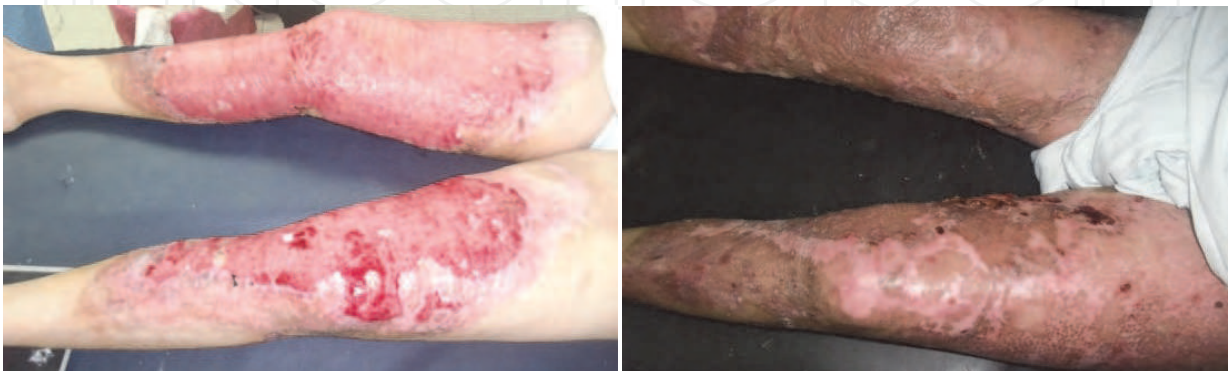

Fig. 1. Deep full thickness burns of both lower limbs and after reconstruction with STSG.

3.2 Post traumatic skin loss

Friction burns ((fig. 2) and degloving injuries (fig. 3,4) due to car accident and other traumas which leads to full thickness skin loss are indication for split thickness graft. In cases of friction burns the area of skin loss should be washed thoroughly with sterile saline to make sure that the recipient site is clean and ready for grafting. If the wound still remains contaminated, it should be dressed until complete cleanliness of the wound is obtained.

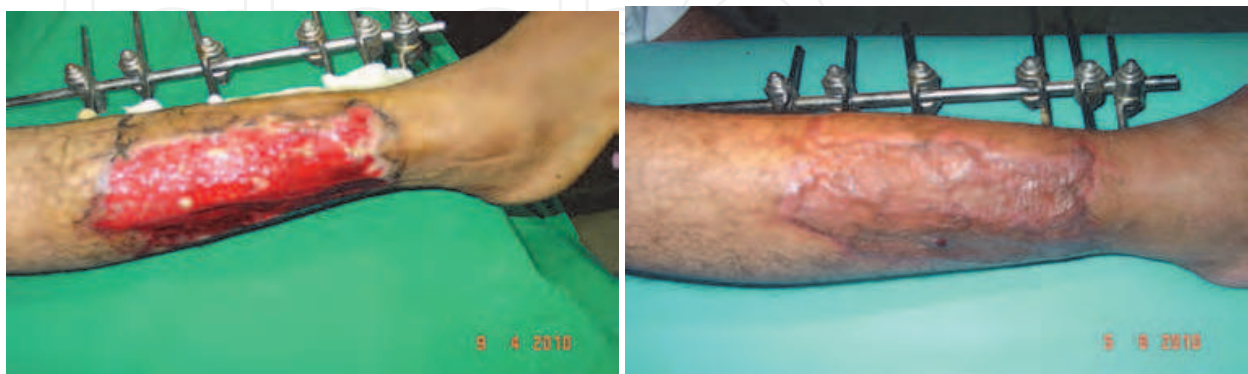

Fig. 2. Friction burns of the lateral aspect of the lower leg with full thickness skin loss and after reconstruction with STSG.

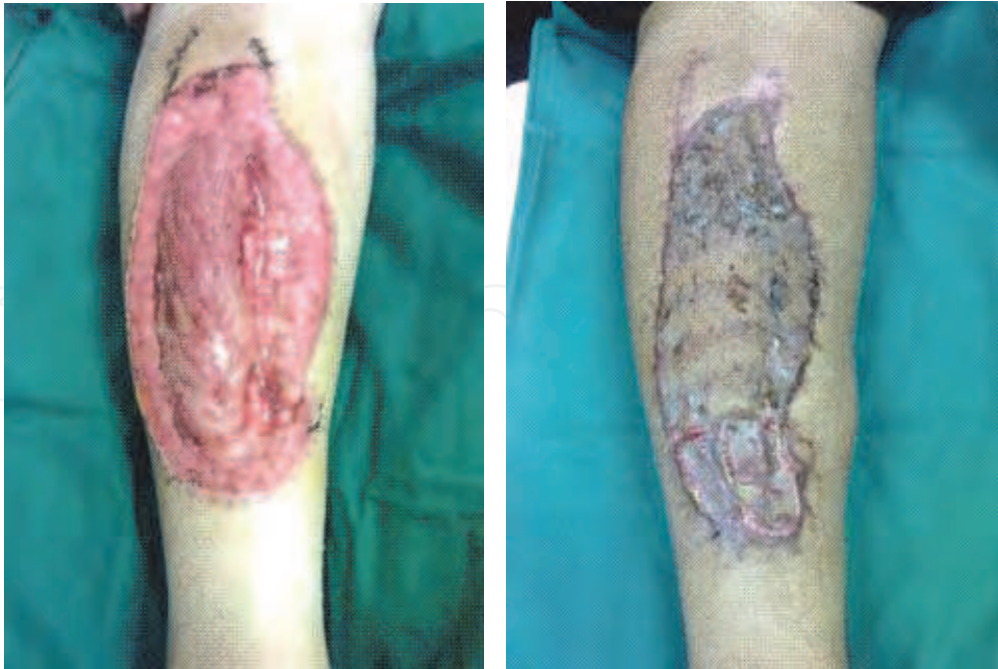

Fig. 3. Degloving injury of the right leg after debridement and after reconstruction by STSG

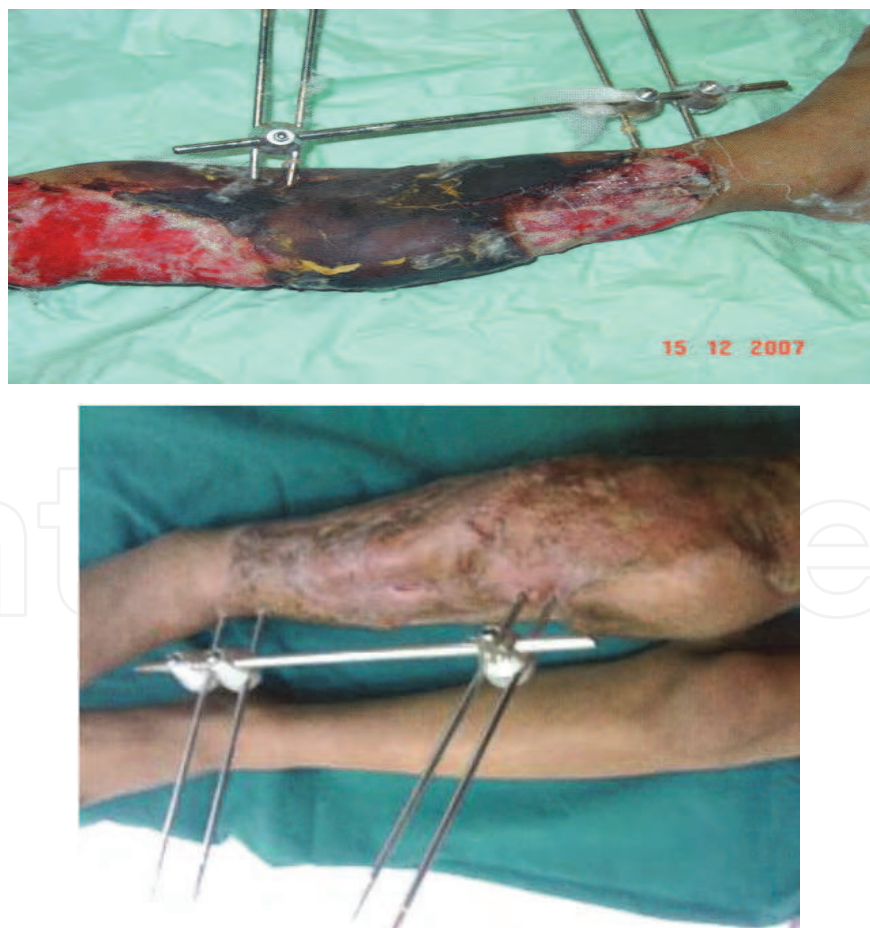

Fig. 4. Degloving injury of the right leg before and after debridement and reconstruction by STSG

3.3 During surgery

After release of post burn contractures and after reconstruction by local flaps such as a transposition or bipedicle flap requires grafting to close the donor site (fig. 5-8). Also excision of large tumor usually need skin graft to reconstruct the resultant defect.

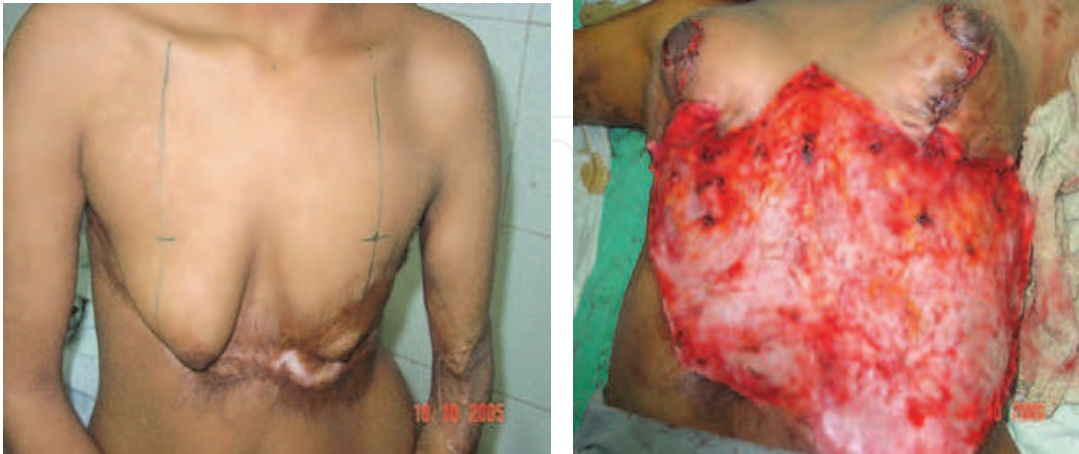

Fig. 5. A) Post burn breast contraction of both breasts and after release of breast contraction

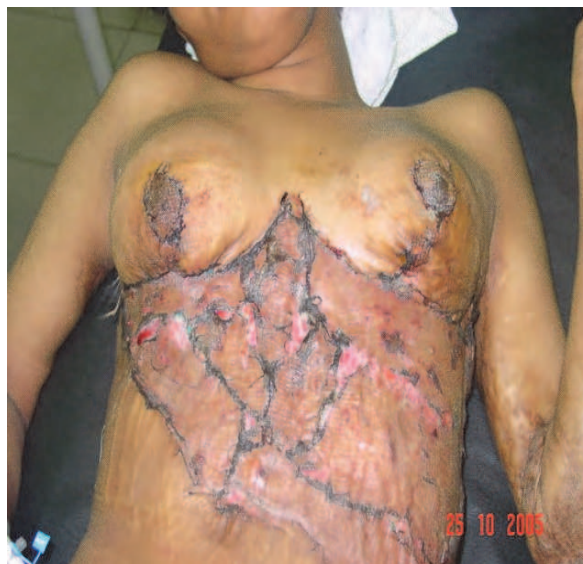

Fig. 5. B) After application of STSG to the row area of lower chest and upper abdominal wall

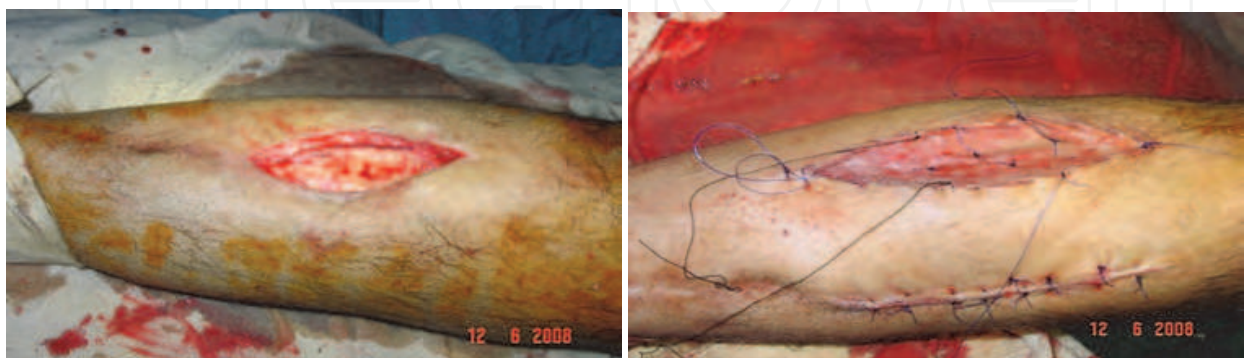

Fig. 6. Exposed tibia and after reconstruction by bipedicle flap and STSG applied to the donor site of flap

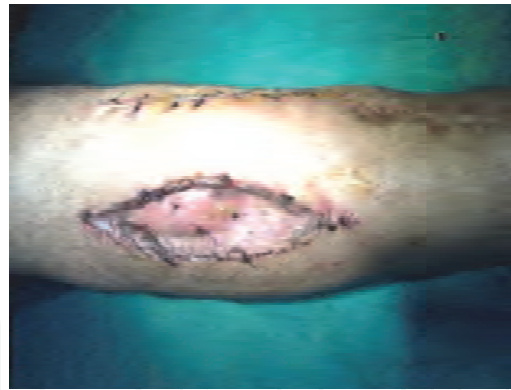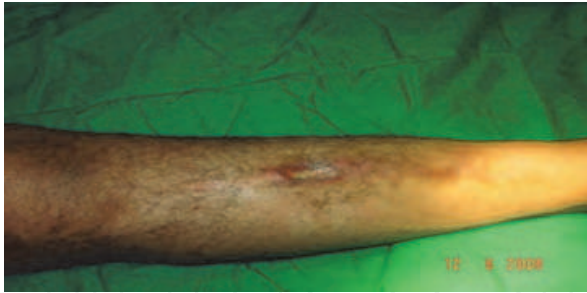


Fig. 7. Exposed tibia and after reconstruction by bipedicled flap and STSG applied to the donor site of the flap.

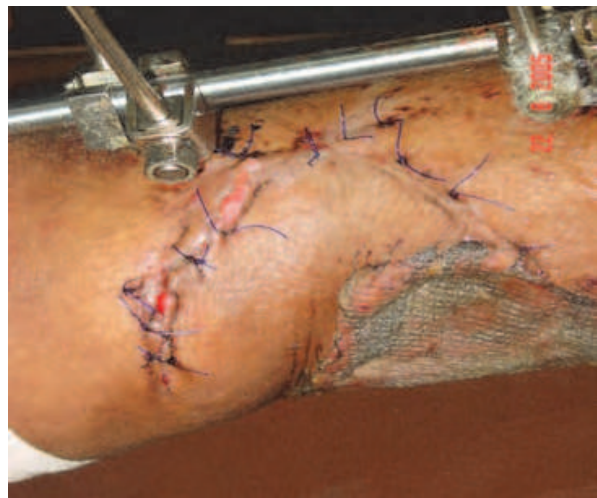
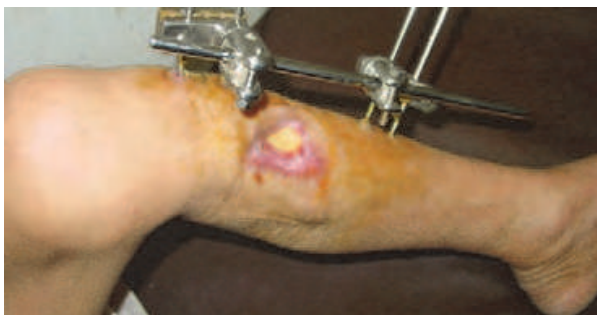

Fig. 8. A) Exposed tibia and after reconstruction by transposition flap and STSG is applied to the donor site of the flap.

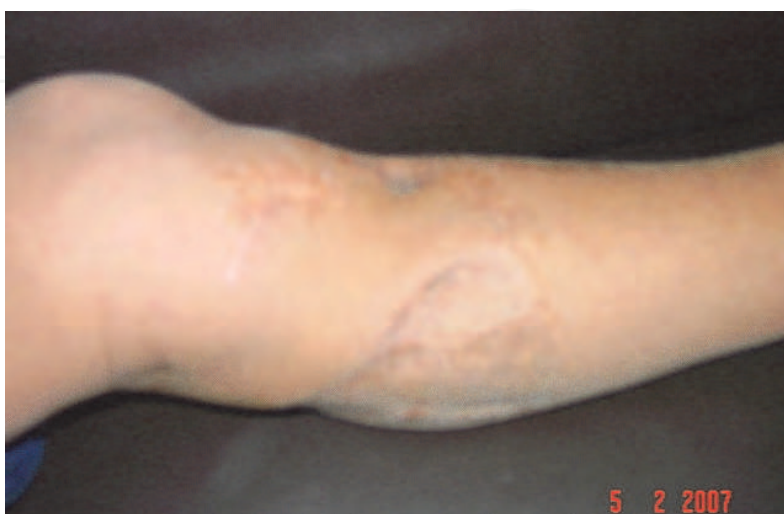

Fig. 8. B) the appearance of the graft after one year.

3.4 Post operative

Compartment syndrome of an extremity needs urgent release of the fascia (fasciotomy) to re-establish limb vasculature. The resultant fasciotomy wound usually requires reconstruction with a skin graft for closure after establishment of limb vasculature (fig. 9).

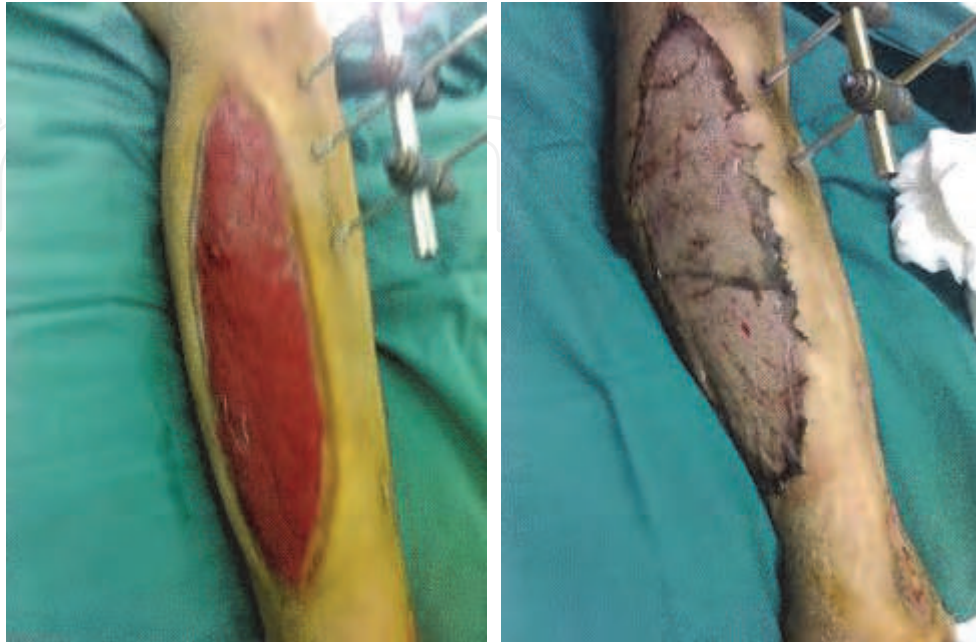

Fig. 9. Fasciotomy of the lateral aspect of the leg and after application of a STSG

3.5 Post infection skin loss

Necrotizing fasciitis is considered one of the most common indications of skin graft after a thorough debridement of the dead tissue and clearance of the infection. Diabetic infections usually need extensive debridement and the wound closed with a skin graft (fig.10).

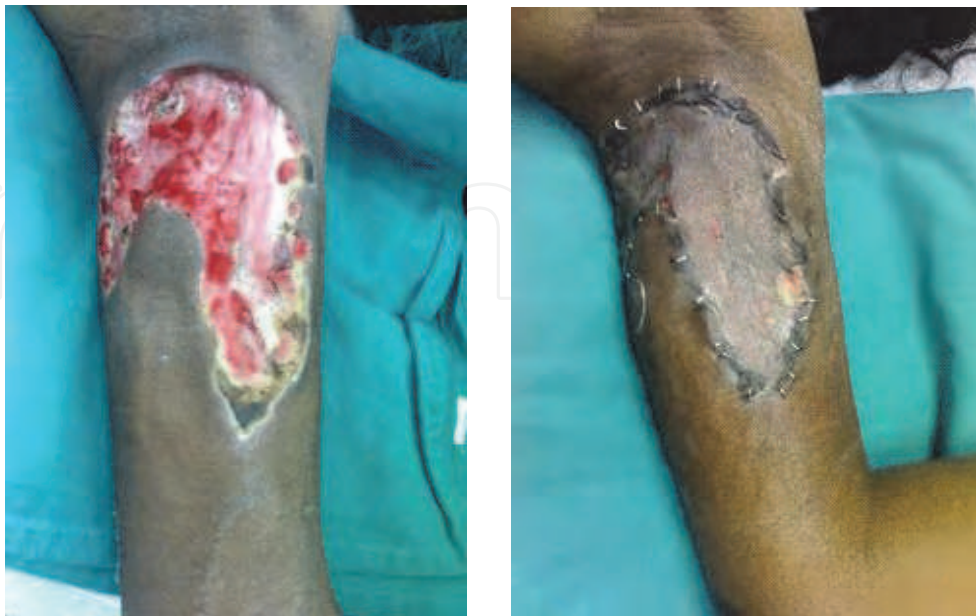

Fig. 10. Post necrotising fasciitis row area of the medial aspect of the arm and after debridement and application of STSG

4. Indications of allografts and xenografts

With extensive full thickness skin loss exceeding 30% of the body surface, auto grafts are often not available in sufficient quantities. Temporary coverage can be obtained by skin allograft from volunteers, diseased free cadavers, or the patient's relatives and friends and is often a life-saving measure. It is used as a biologic dressing and can serve several functions: (1) provide clean granulating area prior to auto-grafting, (2) protect open wound from protein and water loss until auto-grafting is available, (3) decrease surface bacterial count and pain at the site of an open wound, (4) covers the vital organs and (5) facilitate early movement of affected part. In order to avoid rejection response to allo-graft, the allograft skin should be changed every three days. It can be obtained fresh from the relatives and either used immediately or stored in the live state at a temperature near or above freezing.

Skin allograft has also been recommended for coverage of second degree burns. In addition to providing pain relief and inhibition of evaporate and exudative water loss, skin allograft promote healing with an improved cosmetic results.

5. Xenografts

The functions of skin xenografts as temporary biologic dressing are similar to those outlined in the above section on allograft. Xenografts have been most extensively used in covering large burn wounds before auto-grafting. The use of xenografts have also been used for the temporary coverage of exposed vessels, tendons, large ulcers, flap donor sites and skin graft donor sites.

6. References

- Bromberg, BE, Snog, IC and Mohen, MP: The use of Pig skin as a temporary biological dressing. *Plast. Reconstructive Surg.* 36:80, 1965.
- Bromberg, BE and Snog, IC.: Skin substitutes Homo and Hetero grafts. *Am. J. Surg.* 112:28, 1966.
- Elliot, R A and Hoehn, J G :Use of commercial Porcine skin for wound dressing. *Plast. Reconstructive Surg.* 52:401, 1973.
- Darwish A M :Bipedicled flap in reconstruction of exposed tibia. *J Plast Reconstr Aesthet Surg.* 63, 160-163, 2010.
- Eto, M., H. Hackstein, K. Kaneko, et al. "Promotion of Skin Graft Tolerance Across MHC Barriers by Mobilization of Dendritic Cells in Donor Hemopoietic Cell Infusions." *Journal of Immunology* 69 (September 1): 2390-2396, 2002.
- Latenser, B. A. and Vern A. Kowal. "Paediatric Burn Rehabilitation." *Pediatric Rehabilitation* 5 (January-March).
- Losada, F., M.D., Pedro P. Garcia-Luna, M.D., T. Gomez-Cia, M.D., et al. "Effects of Human Recombinant Growth Hormone on Donor-Site Healing in Burned Adults." *World Journal of Surgery* 26 (January): 2-8, 2002.
- Revis, Don R., Jr., and Michael B. Seagal, . "Skin Grafts, Full-Thickness." *eMedicine*, May 17, 2002 [cited June 25, 2003].
- Snyder, R. J., H. Doyle, and T. Delbridge. "Applying Split-Thickness Skin Grafts : A Step-by-Step Clinical Guide and Nursing Implications." *Ostomy Wound Management* 47 (November): 990-996, 2002.
- Woudruff M F A: The Transplantation of tissue and organs. Springfield, IL, Charles C. Thomas, 1960.



Skin Grafts - Indications, Applications and Current Research

Edited by Dr. Marcia Spear

ISBN 978-953-307-509-9

Hard cover, 368 pages

Publisher InTech

Published online 29, August, 2011

Published in print edition August, 2011

The procedure of skin grafting has been performed since 3000BC and with the aid of modern technology has evolved through the years. While the development of new techniques and devices has significantly improved the functional as well as the aesthetic results from skin grafting, the fundamentals of skin grafting have remained the same, a healthy vascular granulating wound bed free of infection. Adherence to the recipient bed is the most important factor in skin graft survival and research continues introducing new techniques that promote this process. Biological and synthetic skin substitutes have also provided better treatment options as well as HLA tissue typing and the use of growth factors. Even today, skin grafts remain the most common and least invasive procedure for the closure of soft tissue defects but the quest for perfection continues.

How to reference

In order to correctly reference this scholarly work, feel free to copy and paste the following:

Abdou Darwish (2011). Indications of Skin Graft, Skin Grafts - Indications, Applications and Current Research, Dr. Marcia Spear (Ed.), ISBN: 978-953-307-509-9, InTech, Available from:
<http://www.intechopen.com/books/skin-grafts-indications-applications-and-current-research/indications-of-skin-graft>

INTECH
open science | open minds

InTech Europe

University Campus STeP Ri
Slavka Krautzeka 83/A
51000 Rijeka, Croatia
Phone: +385 (51) 770 447
Fax: +385 (51) 686 166
www.intechopen.com

InTech China

Unit 405, Office Block, Hotel Equatorial Shanghai
No.65, Yan An Road (West), Shanghai, 200040, China
中国上海市延安西路65号上海国际贵都大饭店办公楼405单元
Phone: +86-21-62489820
Fax: +86-21-62489821

© 2011 The Author(s). Licensee IntechOpen. This chapter is distributed under the terms of the [Creative Commons Attribution-NonCommercial-ShareAlike-3.0 License](https://creativecommons.org/licenses/by-nc-sa/3.0/), which permits use, distribution and reproduction for non-commercial purposes, provided the original is properly cited and derivative works building on this content are distributed under the same license.

IntechOpen

IntechOpen