

We are IntechOpen, the world's leading publisher of Open Access books Built by scientists, for scientists

6,900

Open access books available

186,000

International authors and editors

200M

Downloads

Our authors are among the

154

Countries delivered to

TOP 1%

most cited scientists

12.2%

Contributors from top 500 universities



WEB OF SCIENCE™

Selection of our books indexed in the Book Citation Index
in Web of Science™ Core Collection (BKCI)

Interested in publishing with us?
Contact book.department@intechopen.com

Numbers displayed above are based on latest data collected.
For more information visit www.intechopen.com



The Role of Liver Biopsy in the Non-Invasive Methods Era and Liver Stiffness Measurement Using Transient Elastography

C. Rinaldi A. Lesmana and Laurentius A. Lesmana

*Division of Hepatology, Department of Internal Medicine,
Cipto Mangunkusumo Hospital, University of Indonesia
Digestive Disease Centre, Medistra Hospital, Jakarta
Indonesia*

1. Introduction

Liver biopsy is still the most accurate tool to assess liver histopathology in chronic liver disease (CLD), especially in patients with chronic active hepatitis who need a treatment decision. Nowadays, there are many non-invasive methods are being used to assess liver fibrosis and might replace liver biopsy. One of the new methods is transient elastography (TE/Fibroscan) which has been widely used to predict liver fibrosis in chronic active hepatitis B and C. However, whether TE is ready to replace the liver biopsy is still controversial.

In cases like chronic hepatitis B infection (CHB), autoimmune hepatitis (AIH), non-alcoholic steatohepatitis (NASH), drug induced liver injury (DILI), and cholestatic liver diseases, the role of liver biopsy is very important to make the whole information of liver histopathology (not only about liver fibrosis). On the other hand, to make a diagnosis of liver cirrhosis, we have some parameters that can be used, such as clinical stigmata of advanced chronic liver disease (jaundice, hyper pigmentation, spider nevi, palmar erythema, ascites, edema, and others), low level of platelet count, and low level of albumin, prolonged protombin time, and picture of liver cirrhosis based on ultrasound examination.

In chronic active hepatitis B infection, the treatment decision is usually based on the increase level of alanine aminotransferase (ALT), high HBV-DNA serum level, and the presence of HBeAg status. In patients with normal ALT level or less than 2x ULN, the liver biopsy is needed to decide whether the antiviral therapy should be started or not. In this group, not only liver fibrosis assessment is important, but also the degree of necroinflammation will influence the decision of antiviral therapy. From the point of view of liver fibrosis itself when using TE, it is not always accurate to differentiate between fibrosis 1 or 2, since this differentiation is also important to start antiviral therapy.

Despite the etiology of liver injury, TE itself has problem with overweight and obese patients, and patients with narrowed intercostals space. TE also cannot be performed in ascitic patient because the interposed fluid blocks the shear wave. The increase of liver stiffness cut off is also can be influenced by metabolic syndrome, age, BMI, and the increase of ALT level.

The liver biopsy still has the most important role in assessing liver histopathology but we might reduce the need of liver biopsy examination in some patients. At this moment, TE can

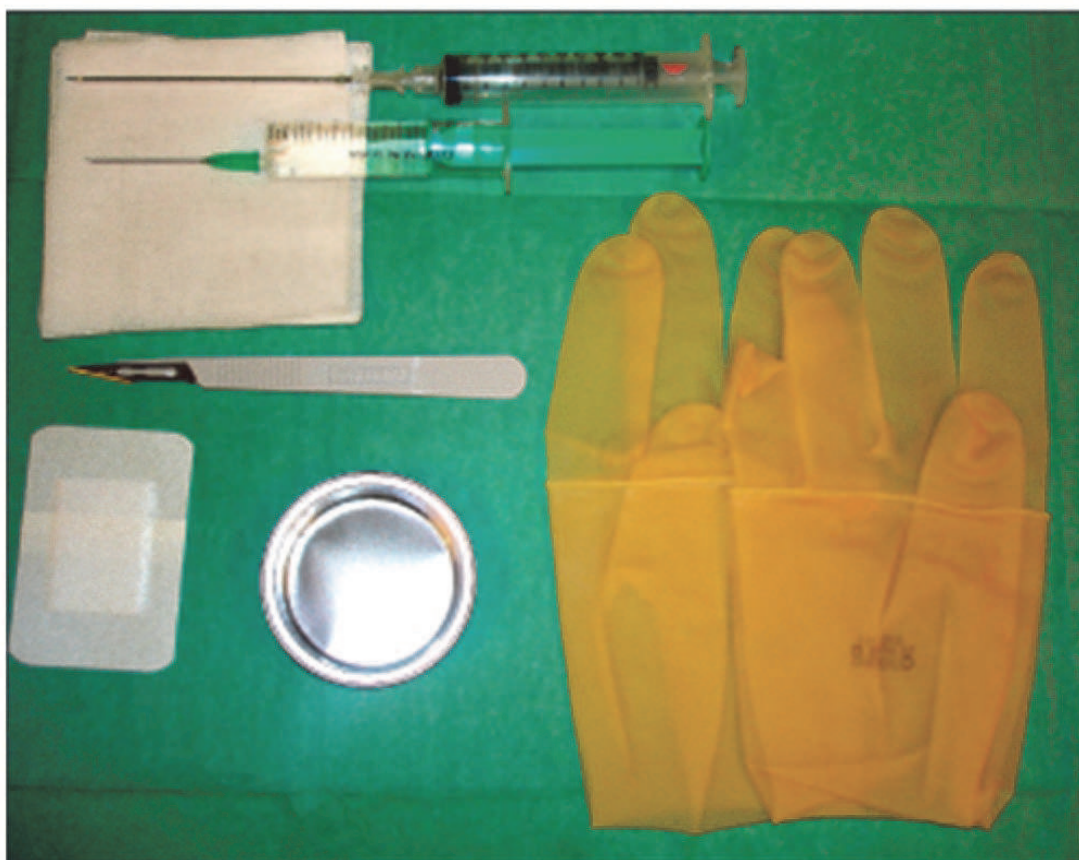be used as a predictor tool in assessing liver fibrosis in chronic active hepatitis with regard to clinical and laboratory parameters.

A lot of study is still needed to validate the usefulness of TE in assessing liver fibrosis in chronic active hepatitis.

2. Liver biopsy

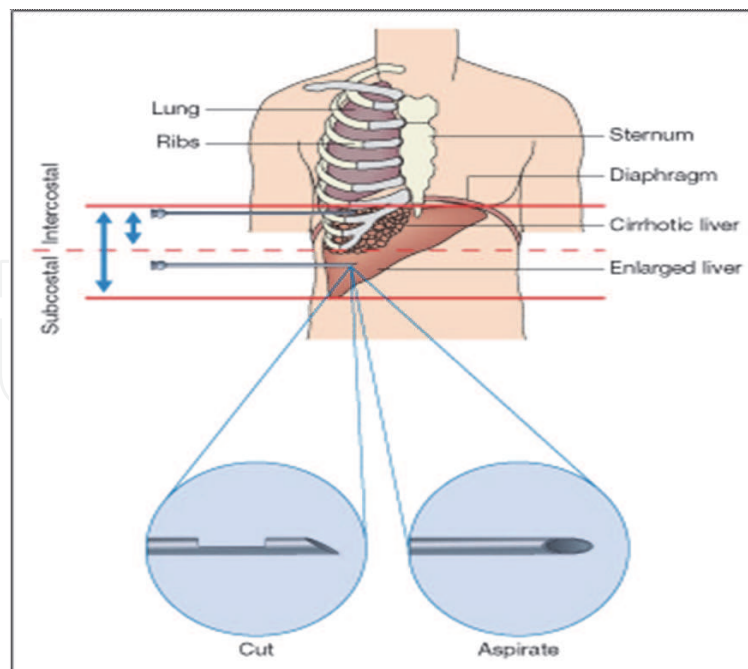
2.1 History and definition

In 1883, the first liver biopsy was performed by Ehrlich to assess hepatic glycogen content in a diabetic patient, followed by Lucatello who performed liver biopsy to analyze a tropical abscess of the liver 12 years later. In 1907, Schuper is the one who published a series number of liver biopsy which are performed in humans and rats. The liver biopsy technique has been evolved for many years, and in 1958 Menghini technique of liver biopsy has been introduced and widely used in the clinical practice. This technique can be easily performed by experienced and well-trained clinicians and especially hepatologists. Liver biopsy is a technique to obtain, view, and assess the liver histology, either by cutting or aspiration. This technique can be done via transcutaneous route, or transjugular. (1)



Copyright 2006 by Elsevier Inc.

Fig. 1. Typical set-up of materials required for an aspiration transcutaneous liver biopsy. The syringe is already connected to an aspiration needle (Menghini) biopsy set. The other syringe is used for local anesthesia. Adapted from Zakim and Boyer's Hepatology 2006.



Copyright 2006 by Elsevier Inc.

Fig. 2. The approach to transcutaneous liver biopsy. A transcutaneous biopsy of the liver is performed in complete expiration to limit accidental pulmonary injury. As the liver is frequently cirrhotic and therefore small, an intercostal approach is necessary. However, in large livers a subcostal route is preferred as a safer route. The schematic illustrates the two principal types of needle used: cutting needles and aspiration needles, for which several models are commercially available and which should be chosen according to the patient's risk profile and the clinical indication for the biopsy. Adapted from Zakim and Boyer's Hepatology 2006.

2.2 The clinical importance of liver biopsy: Its use, risk and assessment

Liver biopsy is an important examination in assessing the progression of liver disease, establish the diagnosis when there is no clear etiology, and to make a decision of therapy. We know that the risks of liver disease progression are liver cirrhosis (LC) and liver cancer/hepatocellular carcinoma (HCC). These could be due to chronic active hepatitis virus infection (such as hepatitis B (HBV) and C (HCV) virus), drug induced liver injury (DILI), alcoholic liver disease (ALD), non-alcoholic steatohepatitis (NASH), autoimmune hepatitis (AIH), etc. In chronic active hepatitis virus infection, of course we need to do liver biopsy in special circumstances (based on the guidelines). However, the disease such as AIH, DILI, and NASH, liver biopsy examination could be a mandatory since we need to see clearly the histology picture to establish the diagnosis. Even sometimes, patient with unknown etiology of hepatomegaly with abnormality liver biochemistry test, we do need a liver biopsy. Liver biopsy in Non-Alcoholic Fatty Liver Disease (NAFLD) can become a dilemma since we know that not all patients with fatty liver will develop NASH. There were some contrarily about doing liver biopsy since there are side effects that could happen, such as bleeding/hemorrhage and pain. The frequency of complications was 3.2% in physicians with a history of less than 20 biopsies, compared to 1.1% when over 100 had been performed. Recently, the use of ultrasound as a guide to liver biopsy has been used widely among the hepatologists. Many recommendations has also been made regarding to liver

biopsy preparation but there is still lack of evidence. The only thing is that really matters are anticoagulant use and hemostase examination. Sampling error is that something that could happened because we only use small needle and probably we could only assess small area of the liver tissue even though we have the preconditions for liver tissue sampling so it can be assessed very well by the pathologist. However, until now liver biopsy is still a gold standard to obtain information about what happened in the progression of liver diseases and of course to see the improvement of liver histology after the patients received treatment. In Advanced liver disease, we have clinical (chronic liver disease stigmata such as icteric, spider nevi, hyper pigmentation, palmar erythema, splenomegaly, ascites, caput Medusa, and leg edema), biochemical parameters (low platelet count, albumin globulin ratio, hyperbilirubinemia, abnormal hemostase, etc), and imaging studies (ultrasound, CT-scan, MRI) to confirm the diagnosis so we don't have to perform any liver biopsy. (2,3,4,5)

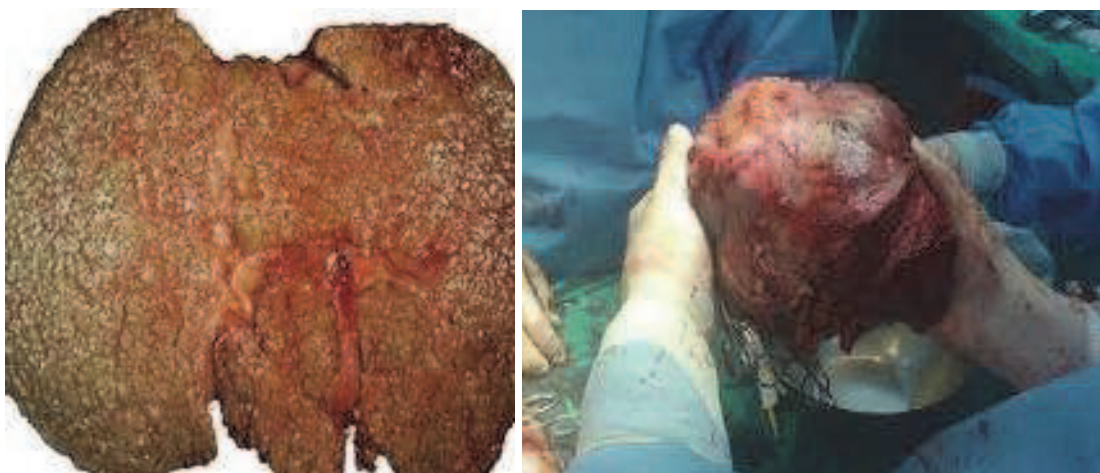

Fig. 3. Liver Cirrhosis and Hepatocellular Carcinoma Illustrations.

2.3 Non invasive methods in assessing liver fibrosis

The ideal non invasive methods in assessing liver fibrosis should be highly sensitive and specific, technically easy to measure, inexpensive, minimal or no side effect, and can be used easily to monitor the progression or regression of liver disease during the treatment. There are several direct and indirect serum markers that have been studied for long time to assess liver fibrosis. The direct markers such as collagens (procollagen I C peptide/PICP, procollagen III N peptide/PIIINP, type IV collagen and its fragments (NC1 and PIVNP), glycoproteins and polysaccharides (hyaluronic acid/HA, laminin, tenascin, YKL-40/chondrex), collagenase and their inhibitors (metalloproteinases/MMPs, tissue inhibitors of metalloproteinases/TIMPs), and cytokines (TGF- β 1 and PDGF) are related to matrix deposition since we know that the activation process of stellate cell which is the key event of liver fibrosis is related to the increase production of MMP-1, MMP-2, and TIMPs, and leading to replacement by interstitial collagen. However, most of the studies showed the significant difference between no or mild fibrosis group (F0-F1) and moderate-severe liver fibrosis group (F2-F4) or between F0-F2 vs. F3-F4 group. (6,7,8,9,10) When it comes to differentiate between F1 and F2, most of the studies showed unsatisfied result. Mostly have not very high sensitivity when it is used to differentiate between F1 and F2. In a large cohort study, nine different markers have been evaluated in HCV, ALD, and NAFLD patients, and it is found that HA, TIMP-1, and PIIINP were selected as

having the best accuracy in diagnosing F2-F4 with the AUROC were 0.77, 0.94, and 0.87. Another large study in 696 HCV patients has shown that HA, TIMP-1 and α -2-macroglobulin were having 75% accuracy in diagnosing F2-F4 with AUROC 0.82-0.83. Zhang BB et al also showed very good results of the direct serum markers such as PDGF-BB, TIMP-1, TIMP-1/MMP-1, and TIMP-1mRNA when diagnosing hepatic inflammation and fibrosis in CHB patients compared to normal control. It showed good correlations ($r=0.239-0.565$; $p=0.000-0.0033$), but in this study didn't show any differences between fibrosis stages. Study by Oberti et al, showed that the best diagnostic accuracy was found for HA, laminin, PIIINP, and TGF- β 1, but it didn't show any diagnostic advantage when those markers were taken together. All of these markers are not liver specific as it might be influenced by some other conditions, such as inflammation at any other organs. The value of these markers in diagnosing the liver condition also can be questionable whether due to the progression of matrix deposition or recovery process after inflammation process. (6,11,12) The cost-effectiveness of the non-invasive markers is still debatable since in most countries in Asia, the price of non-invasive markers can become a problem when it comes to the market.

The indirect markers such as serum ALT levels, AST/ALT ratio, platelet count (PT), prothrombin index, and multi-combination indirect fibrosis test (Forns index, Fibro Test, APRI, PGA, PGAA, FIB-4, Hepascore and Acti Test) also have been studied for many years whether it could be used to replace liver biopsy or not. The simple indirect marker test such as ALT level seemed that is not really a good marker in hepatic fibrosis prediction since there have been many studies showed that even though patients with normal ALT could possibly have advanced liver fibrosis. (8,13,14,15,16) The AST/ALT ratio showed a good predictive value in advanced liver disease, especially when combined with platelet count which has been reported mostly in CHC patients. A retrospective study by Yilmaz et al showed statistically significance for the correlation between APRI score and hepatic fibrosis in CHC ($r=0.2634$, $p=0.0059$) and NAFLD ($r=0.2273$, $p=0.0069$) patients but not in CHB ($r=0.1005$, $p=0.1495$) patients even though the r values showed not very strong correlation. This study also found that APRI has sensitivity 55.0% and specificity 75.4% for CHC, 60.0% and 73.3% for NAFLD, and 55% and 75.4% for CHB. (17) Another retrospective study comparing 6 non-invasive liver fibrosis markers (APRI, Fibrometer, FIB-4, Hepascore, Forns index, and Shanghai Liver Fibrosis Group/SLFG's index) showed that better correlation were found in Fibrometer ($r=0.69$), Hepascore ($r=0.62$), and SLFG ($r=0.68$) with METAVIR score ($p<0.001$) of liver histopathology compared with others. Fibrometer, Hepascore, and SLFG are more representing direct markers while APRI, FIB-4, and Forns index are indirect markers. However, in this study only showed the AUROCs were better when these markers are used to differentiate between F0-F2 and F3-4 compared to F0-1 and F2-4 group. (18)

2.4 Imaging studies in assessing liver fibrosis

There are some imaging studies that can be used to assess the liver morphology such as ultrasound, CT-scan, and Magnetic Resonance Imaging (MRI). However, none of these modalities can be used when the differentiation between mild and early significant liver fibrosis is needed. In chronic active hepatitis, the only finding that can be found with these imaging modalities is the cirrhotic liver. (7,19) On the other side the imaging studies like CT-scan and MRI will cost a lot of money. A retrospective cross sectional study looking at comparative MR imaging studies with superparamagnetic iron oxide (SPIO)-enhanced and

double-enhanced spoiled gradient echo (SPGR) sequences in 101 patients (HCV, HBV, AIH, NASH, PBC, PSC, alcoholic hepatitis, and cryptogenic) showed that qualitative and quantitative image scores were significantly higher for patients with METAVIR fibrosis scores of 3 or higher than for those with scores of 2 or lower ($p < .001$). Diagnostic performance for detection of grade 3 or more severe fibrosis was better with the doubled-enhanced sequence than with the SPIO-enhanced sequences. This study showed a good performance only when it comes to assess advanced liver fibrosis. The limitations of this study were retrospective study and only have a small number patient with mild fibrosis.(20) During the development of imaging studies, a modified phase contrast magnetic resonance (MR) imaging sequence to assess liver tissue shear waves, which is called MR elastography, also has been studied. In twelve patients with chronic liver disease (HCV, AIH, NASH, liver cirrhosis due to sarcoidosis) who underwent MR elastography, there were 11 patients with liver fibrosis (stage 1 in four patients, stage 2 in three patients, stage 3 in three patients, and stage 4 in one patient) based on histopathology results and from the imaging result showed that the mean liver stiffness was significantly higher than was found in healthy control group ($p < .001$). This preliminary study has shown that MR elastography can be used to differentiate between normal and fibrotic liver but still it needs a lot of sample to confirm these findings especially when it will be used to differentiate between mild and advance liver fibrosis. (21)

2.5 Transient elastography (Fibroscan) in assessing liver fibrosis

Transient Elastography (TE/Fibroscan, Echosens, Paris, France) has been introduced recently as a new tool for liver fibrosis assessment. It is an easy and user friendly technique for clinicians and very comfortable examination for the patients. The non-fasting patients lying flat on their back, with the right arm tucked behind the head to facilitate access to the right upper quadrant. The ultrasound transducer probe is mounted on the axis of a vibrator and the elastic shear wave induced by the vibrations will propagates through the liver tissue. The examination will takes only less than 5 minutes in experienced and well trained clinicians or nurses (after 100 examinations). Liver stiffness values range from 2.5 to 7.5 kPa. The validity of this examination depends on the interquartile range (IQR), which reflects the variability of the validated measures, and should not exceed 30% of the median value. The success rate should be at least 60%. The limitations of this examination are when dealing with obese patients, patients with ascites, and high ALT level. Failure rates to perform this examination in high BMI patients have been showed in several studies and the range was showed between 2.4% and 9.4%. (22,23) The level of ALT has become a major issue since many studies have shown that higher ALT will make the higher liver stiffness value. (24,25,26) Most of the TE studies in Western countries were done in CHC patients since we know that CHC is more prevalent. On the other side, most Asian countries tried to look this new tool for liver fibrosis assessment in CHB patients. There are several major issues when we look two sides of the world's perspective about this examination. First, the different etiology of the liver disease could make the difference of liver stiffness value even though there were some studies in CHB patients done in Western countries and showed the similar proposed cut off with CHC for F2. In Asian countries, many factors have been known can influence the progression of liver disease such as metabolic factors, medicines, genetic polymorphism, and viral genotype. These factors could contribute differently when compare to Western countries. Second, the liver stiffness value impact between CHC and CHB is still debatable in liver fibrosis measurement. When diagnosing the liver fibrosis progression to consider for antiviral therapy, in CHC patients

probably is simpler than in CHB patients because in CHB not only the fibrosis is important but also the necroinflammation of the liver. Third, the AUROCs for F2 prediction in CHB which were reported in Asian studies found lower value than it found in Western studies. Beyond this point, study by Chan et al has showed there was a grey area in CHB patients with normal ALT between LSM 6.0-9.0 kPa, where a LSM 5.0-6.0 kPa would indicate insignificant fibrosis, a LSM >9.0 kPa had a high chance of bridging fibrosis, and that >12.0 kPa had a high chance of cirrhosis. It means in this grey zone the liver biopsy might be needed. (24,27,28) The use of TE in liver cirrhosis (LC) patients is still controversies since we have a lot of non-invasive parameters that can be used to diagnose LC. In some special conditions such as hemophilia, aplastic anemia, thrombocytopenia not related to liver disease, etc, TE might be a good consideration when those patients suffered from chronic active hepatitis virus infection (B & C).

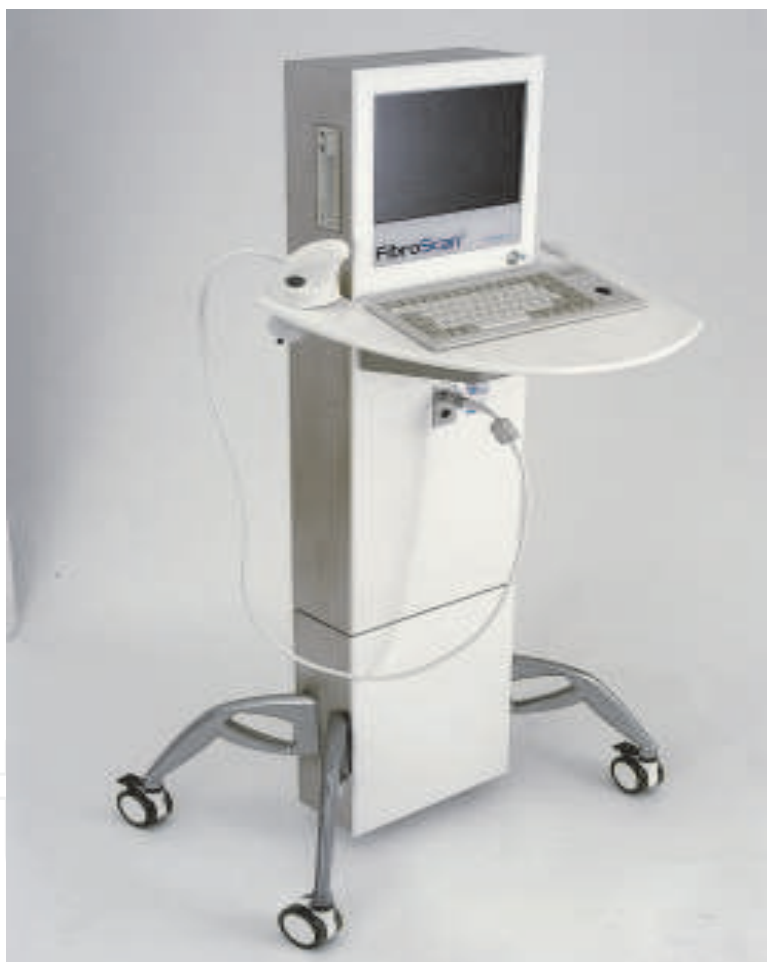

Fig. 4. Fibroscan.

2.6 Liver biopsy or non invasive method in clinical practice

In clinical practice, it is not about which one is better to another method in liver fibrosis assessment but it is more important to see patient to patient's problem based. The final purpose of all these is to make a better clinical decision for the patient but not for the doctor because most patients would like to know whether they have advanced fibrosis or not. Overall, we need to give more concern in patient's safety, cost-effectiveness, and of

course what advantage that the patient will have from each examination for disease management.

3. Conclusions

Liver biopsy still has an important role in the non-invasive methods era even though the need of liver biopsy could be reduced with many kinds of non-invasive methods in liver fibrosis prediction. Further development of non-invasive methods is still needed since we haven't found the perfect non-invasive method that can entirely replace liver biopsy examination.

4. References

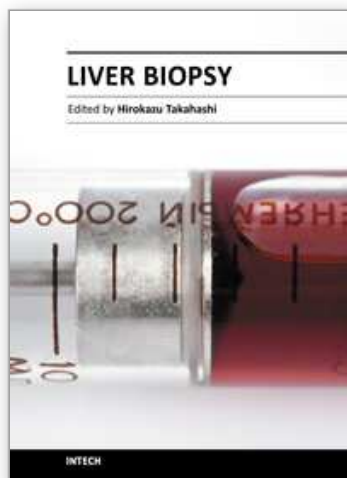
- [1] Strassburg CP, Manns MP. Liver biopsy techniques in: Boyer TD, Wright TL, Manns MP, editors. *Zakim and Boyer's Hepatology. A textbook of liver disease*. Saunders Elsevier, Canada 2006; 5th ed; vol.1: p 195-203.
- [2] Rockey DC, Caldwell SH, Goodman ZD, Nelson RC, Smith AD. Liver biopsy. *Hepatology* 2009; 49(3): p 1017-44.
- [3] Liao YF, Leung N, Kao JH, Piratvisuth T, Gane E, Han KH, et al. Asian pacific consensus statement on the management of chronic hepatitis B: a 2008 update. *Hepatology* 2008; 2: 263-83.
- [4] Lok ASF, McMahon BJ. AASLD practice guidelines. Chronic hepatitis B: update 2009. *Hepatology* 2009; 50(3): 1-36.
- [5] Rockey DC, Friedman SL. Hepatic fibrosis and cirrhosis in: Boyer TD, Wright TL, Manns MP, editors. *Zakim and Boyer's Hepatology. A textbook of liver disease*. Saunders Elsevier, Canada 2006; 5th ed; vol.1: p 87-109.
- [6] Grigorescu M. Noninvasive biochemical markers of liver fibrosis. *J Gastrointest Liver Dis* 2006; 15(2): 149-59.
- [7] Carey E, Carey WD. Noninvasive tests for liver disease, fibrosis, and cirrhosis: is liver biopsy obsolete? *CCJM* 2010; 77(8): 519-27.
- [8] Castera L, Pinzani M. Biopsy and non-invasive methods for the diagnosis of liver fibrosis: does it take two to tango? *Gut* 2010; 59: 861-88.
- [9] Lesmana CRA, Hasan I, Budihusodo U, Gani RA, Krisnuhoni E, Akbar N, Lesmana LA. Diagnostic value of a group of biochemical markers of liver fibrosis in patients with non-alcoholic steatohepatitis. *J Dig Dis* 2009; 10: 201-6.
- [10] Geramizadeh B, Janfeshan K, Saberfiroozi M. Serum hyaluronic acid as a noninvasive marker of hepatic fibrosis in chronic hepatitis B. *Saudi J Gastro* 2008; 14(4): 174-7.
- [11] Rosenberg WMC, Voelker M, Thiel R, et al. Serum markers detect the presence of liver fibrosis: a cohort study. *Gastroenterology* 2004; 127: 1704-13.
- [12] Patel K, Gordon SC, Jacobson I, et al. Evaluation of a panel of non-invasive serum markers to differentiate mild from moderate-to-advanced liver fibrosis in chronic hepatitis C patients. *J Hepatology* 2004; 41: 935-42.
- [13] Lai CL, Yuen MF. The natural history and treatment of chronic hepatitis B: A critical and evaluation of standard treatment criteria and end points. *Ann Intern Med* 2007; 147: 58-61.

- [14] Lai M, Hyatt BJ, Nasser I, Curry M, Afdhal NH. The clinical significance of persistently normal ALT in chronic hepatitis B infection. *J Hepatol* 2007; 47: 760-7.
- [15] Nguyen MH, Garcia RT, Trinh HM, Lam KD, Weiss G, Nguyen HA, et al. Histological disease in Asian-Americans with chronic hepatitis B, high hepatitis virus DNA, and normal alanine aminotransferase levels. *Am J Gastroenterol* 2009; doi: 10.1038/ajg.2009.48.
- [16] Lesmana CRA, Gani RA, Simadibrata M, Lesmana LA, Pakasi LS, Hasan I, et al. Histopathological findings in chronic hepatitis B patients with ALT less than 2x ULN and its correlation with various clinical variables. *J Gastroenterol Hepatol* 2010; 25(suppl.2): A140.
- [17] Yilmaz Y, Yonal O, Kurt R, Bayrak M, Aktas B, Ozdogan O. Noninvasive assessment of liver fibrosis with the aspartate transaminase to platelet ratio index (APRI): usefulness in patients with chronic liver disease. *Hepat Mon* 2011; 11(2): 103-7.
- [18] Wu SD, Wang JY, Li L. Staging of liver fibrosis in chronic hepatitis B patients with a composite predictive model: a comparative study. *World J Gastroenterol* 2010; 16(4): 501-7.
- [19] Martinez SM, Crespo G, Navasa M, Forns X. Noninvasive assessment of liver fibrosis. *Hepatol* 2011; 53: 325-35.
- [20] Aguirre DA, Behling CA, Alpert E, Hassanein TI, Sirlin CB. Liver fibrosis: noninvasive diagnosis with double contrast material-enhanced MR imaging. *Radiology* 2006; 239(2): 425-37.
- [21] Rouviere O, Yin M, Dresner MA, Rossman PJ, Burgart LJ, Fidler JL, Ehman RL. MR elastography of the liver: preliminary results. *Radiology* 2006; 240(2): 440-8.
- [22] Castera L, Forns X, Alberti A. Non-invasive evaluation of liver fibrosis using transient elastography. *J Hepatol* 2008; 48: 835-47.
- [23] Sirli R, Sporea I, Deleanu A, Tudora A, Bota S, Popescu A, Danila M. Factors associated with failure of liver stiffness measurement using transient elastography. *TMJ* 2009; 59(1): 34-8.
- [24] Chan HLY, Wong GLH, Choi PCL, Chan AWH, Chim AML, Yiu KKL, et al. Alanine aminotransferase-based algorithms of liver stiffness measurement by transient elastography (Fibroscan) for liver fibrosis in chronic hepatitis B. *JVH* 2009; 16: 36-44.
- [25] Fung J, Lai CL, Cheng C, Wu R, Wo DKH, Yuen MF. Mild-to-moderate elevation of alanine aminotransferase increases liver stiffness measurement by transient elastography in patients with chronic hepatitis B patients. *Am J Gastroenterol* 2011; 106: 492-6.
- [26] Myers RP, Crotty P, Layrargues, Ma M, Urbanski SJ, Elkashab M. Prevalence, risk factors and causes of discordance in fibrosis staging by transient elastography and liver biopsy. *Liver Int* 2010; DOI: 10.1111/j.1478-3231.2010.02331.x.
- [27] Cobbold JFL, Morin S, Taylor-Robinson SD. Transient elastography for the assessment of chronic liver disease: ready for the clinic? *World J Gastroenterol* 2007; 13(36): 4791-7.

- [28] Poggio PD, Colombo S. Is transient elastography a usefull tool for screening liver disease? World J Gastroenterol 2009; 15(12): 1409-14.

IntechOpen

IntechOpen



Liver Biopsy

Edited by Dr Hirokazu Takahashi

ISBN 978-953-307-644-7

Hard cover, 404 pages

Publisher InTech

Published online 06, September, 2011

Published in print edition September, 2011

Liver biopsy is recommended as the gold standard method to determine diagnosis, fibrosis staging, prognosis and therapeutic indications in patients with chronic liver disease. However, liver biopsy is an invasive procedure with a risk of complications which can be serious. This book provides the management of the complications in liver biopsy. Additionally, this book provides also the references for the new technology of liver biopsy including the non-invasive elastography, imaging methods and blood panels which could be the alternatives to liver biopsy. The non-invasive methods, especially the elastography, which is the new procedure in hot topics, which were frequently reported in these years. In this book, the professionals of elastography show the mechanism, availability and how to use this technology in a clinical field of elastography. The comprehension of elastography could be a great help for better dealing and for understanding of liver biopsy.

How to reference

In order to correctly reference this scholarly work, feel free to copy and paste the following:

C. Rinaldi A. Lesmana and Laurentius A. Lesmana (2011). The Role of Liver Biopsy in the Non-Invasive Methods Era and Liver Stiffness Measurement Using Transient Elastography, Liver Biopsy, Dr Hirokazu Takahashi (Ed.), ISBN: 978-953-307-644-7, InTech, Available from: <http://www.intechopen.com/books/liver-biopsy/the-role-of-liver-biopsy-in-the-non-invasive-methods-era-and-liver-stiffness-measurement-using-trans>

INTECH
open science | open minds

InTech Europe

University Campus STeP Ri
Slavka Krautzeka 83/A
51000 Rijeka, Croatia
Phone: +385 (51) 770 447
Fax: +385 (51) 686 166
www.intechopen.com

InTech China

Unit 405, Office Block, Hotel Equatorial Shanghai
No.65, Yan An Road (West), Shanghai, 200040, China
中国上海市延安西路65号上海国际贵都大饭店办公楼405单元
Phone: +86-21-62489820
Fax: +86-21-62489821

© 2011 The Author(s). Licensee IntechOpen. This chapter is distributed under the terms of the [Creative Commons Attribution-NonCommercial-ShareAlike-3.0 License](https://creativecommons.org/licenses/by-nc-sa/3.0/), which permits use, distribution and reproduction for non-commercial purposes, provided the original is properly cited and derivative works building on this content are distributed under the same license.

IntechOpen

IntechOpen