

We are IntechOpen, the world's leading publisher of Open Access books Built by scientists, for scientists

6,900

Open access books available

186,000

International authors and editors

200M

Downloads

Our authors are among the

154

Countries delivered to

TOP 1%

most cited scientists

12.2%

Contributors from top 500 universities



WEB OF SCIENCE™

Selection of our books indexed in the Book Citation Index
in Web of Science™ Core Collection (BKCI)

Interested in publishing with us?
Contact book.department@intechopen.com

Numbers displayed above are based on latest data collected.
For more information visit www.intechopen.com



Intestinal Dynamic Color Doppler Sonographic Tissue Perfusion Measurement

Thomas Scholbach¹, Jörg Hofmann¹ and Jakob Scholbach²

¹*Hospital for Children and Adolescents, Chemnitz Clinics, 09116 Chemnitz*

²*University of Münster, Mathematical Institute, 48149 Münster
Germany*

1. Introduction

The evaluation of intestinal diseases encompasses morphological as well as functional aspects. The proper function of any organ depends on a sufficient blood supply to meet its actual metabolic needs. Blood flow though is a measure of physiological and pathophysiological tasks which are accomplished by the respective organ. Thus, many of these tasks can be described by measuring the amount of blood passing through tissues. Inflammation is an excellent example of such a response to a stimulus which increases tissue perfusion. The measurement of perfusion intensity would be helpful to monitor inflammatory processes. In contrast to the obvious advantages of such an approach only very limited methods exist to quantify perfusion of the bowel today. Contrast media in MRI, CT and angiography can give a vague impression of the quality of bowel perfusion but are not usable to quantify perfusion. Doppler ultrasound is used to record changes of blood flow velocity in the main intestinal arteries to calculate the so called Resistance Index (RI) and the related Pulsatility Index (PI). Both cannot describe the amount of intestinal blood since they lack the information of the width of the intestinal vascular network. Besides the actual flow velocity inside each vessel the vessel width is the other necessary constituent to calculate flow intensity or volume inside a tissue. We developed a novel method to overcome these limitations - the Dynamic Color Doppler Sonographic Tissue Perfusion Measurement (DTPM). The following chapter describes the principle of DTPM and its use in gastroenterology.

DTPM was developed to meet so far unsatisfied daily needs in clinical practice, to quantify tissue perfusion in order to answer pressing clinical questions: is the tissue viable, is it damaged and to which extent, is there an inflammatory hyperperfusion, is the blood supply to an organ sufficient to fulfill its tasks properly.

2. Dynamic Color Doppler Sonographic Tissue Perfusion Measurement (DTPM)

2.1 Idea

The idea behind DTPM is that we all are used to estimate by the naked eye the intensity of blood flow in a tissue by watching the strong or less strong coloration of a tissue during a routine color Doppler ultrasound examination – but unfortunately this feeling that the blood

flow is strong or weak cannot be used for a sound decision on treatment. All we see remains a vague impression. To discuss our findings with others or to refer to our own previous observations we need a reliable basis for comparison – we need a measurement of what we see. This is not easily accomplished since the pumping heart causes an ever changing picture of sparkling color dots inside the tissue under investigation. We need to measure these changes from beginning to the end of the heart beat to calculate a mean perfusion value referring to a complete heart beat. Moreover we know that perfusion is blood volume per time running through the vascular bed of a tissue. Volume per time per tissue unit is but perfused area multiplied by perfusion velocity (the area is virtually lifted at a certain height per time thus creating a volume made up of tiny cylinders which stand more or less dispersed between nonperfused (extravascular) parts (the non-colored background of the color Doppler image). The product of perfused area and perfusion velocity needs to be referred to the total area of the tissue section which is actually examined.

2.2 Principle

DTPM is a software assisted method to extract and use color Doppler data from standardized color Doppler videos in order to measure the perfusion of a tissue (Scholbach et al., 2004; Scholbach et al., 2005a, 2006; Scholbach et al., 2005b). The perfusion intensity (Q) is calculated as product of perfusion velocity and perfused area (A) inside a region of interest (A_{ROI})

$$Q = v \cdot A / A_{ROI} \text{ with the unit } [\text{cm/s}] = [\text{cm/s} \cdot \text{cm}^2 / \text{cm}^2].$$

All colored pixels code a certain number of red blood cells moving with a certain velocity towards the transducer. The color represents the flow direction (red symbolizes flow towards the transducer and blue the opposite direction or vice versa). The shade of both colors from dark to light nuances represents a certain velocity value. Each pixel has a certain area and is the elementary unit of image resolution. Perfused parts of a tissue are depicted in color whereas nonperfused parts remain non-colored (black, gray or white). DTPM comprises the complete information, which is necessary to describe the perfusion intensity i.e. perfused area and velocity values of all pixels, which is extracted and referred to the tissue area under investigation. This way a description of perfusion is achieved which goes far beyond existing techniques of conventional Doppler sonographic perfusion evaluation as RI and PI (Resistance and Pulsatility Index) (Scholbach et al., 2005b). Thus DTPM is applicable for all tissues which can be depicted by means of ultrasound (Rouviere et al., 2004; Scholbach & Scholbach, 2009; Wieczorek et al., 2009).

2.3 Technical requirements

The equipment to perform DTPM is a conventional color Doppler ultrasound machine with transducers that are suitable for a detailed and fast color Doppler imaging. For the investigation of the intestinal tract a linear transducer is mandatory with a B-mode frequency above 5 MHz and a color Doppler frequency of at least 3 MHz. The machine must display the color bar inside the image and must show the maximum values of the depicted flow velocities at the end of the color bar. Moreover the recording of short videos must be possible (at least 2 sec duration) and these files should be recorded and transferred to an external PC via network, USB-stick or other data storage media for the subsequent DTPM with the PixelFlux-software. DICOM file format is preferred over avi-file format since

information about image and recording details as well as patient data are included in the header of the DICOM-file but lack in the avi-file. Despite this avi files are suitable too but need more manual processing than DICOM files thus requiring more time and manpower to be processed.

2.4 Standardization

The standardization of image acquisition is crucial for DTPM. A preset of all machine settings must be defined in the beginning of a DTPM study to define in detail the best imaging conditions for the tissue in question. The following parameters must be kept constant in all times to ensure a comparability of the DTPM (others may be also fixed – depending on the parameters offered by the equipment in use): gain, frequency, persistence, color bar, time and spatial resolution, transducer type, ultrasound machine type, wall filter, depth compensation.

If the actual patient requires an other imaging preset then the primary one, it must be confirmed by statistical comparisons, that the measurement results of both presets are not significantly different. If significant differences are found in a preliminary investigation with the same probands or calibrating devices a special reference range must be established to compare those data with the normal range established with the new preset.

In general daily practice this strict confinement to the own standard preset does not interfere with a smooth work-up of the imaging requests. It is a general practice to define presets for special purposes and all manufacturers offer a variety of them as default settings for different organs and transducers. In most cases these presets can be used or need to be adapted only slightly. Such a preset should be named and can be reinstituted then by preselection before starting the imaging.

2.5 Phantom perfusion measurements

DTPM is basically a pixelwise evaluation of perfusion using the color Doppler image data as delivered by the ultrasound machine. To prove if the concept yields reliable results we made interobserver correlation studies as well as phantom flow comparisons of the actually pumped volumes and the perfusion intensities measured by DTPM. In a phantom study with a perfused tube in a water basin we found a highly significant correlation to the actual perfusion as pumped by a precision laboratory pump (Pearson's $r = 0,987$; $p < 0,001$) (Scholbach et al., 2011). Moreover in a clinical setting the ultrasound of the thyroid revealed a good correlation between two independent researchers measuring the same video sequences (Spearman's $r = 0,870$, $p < 0,001$) (Scholbach et al., 2011).

2.6 Output

With DTPM the following parameters are calculated from a video sequence recording at least one full heart cycle.

- Perfusion intensity throughout the entire ROI: Perfusion intensity [cm/s] = mean perfused area [cm²] * mean flow velocity [cm/s] / area of the ROI [cm²]
- Mean flow velocity throughout the entire region of interest (ROI)
- Mean perfused area in relation to the ROI
- Area of the ROI
- Tissue Pulsatility Index (TPI) of velocity / of area / of perfusion intensity

- $TPI = (\text{maximal systolic value} - \text{minimal diastolic value}) / \text{mean value}$ - "value" may be velocity, area or intensity
- Tissue Resistance Index (TRI) of velocity / of area / of perfusion intensity
- $TRI = (\text{maximal systolic value} - \text{minimal diastolic value}) / \text{maximal systolic value}$ - "value" may be velocity, area or intensity
- Spatial distribution of flow across the tissue
- an overlay of false colors upon the ROI shows local distribution of flow intensity
- Quantitative distribution of perfusion intensity throughout the tissue section
- the whole range of flow intensity (resp. perfused area) over a full video sequence is divided into percentiles. Each interval's fraction of the ROI describes the distribution of perfusion intensity in numerical values.
- Time lines of above explained perfusion parameters of individual patients can be displayed and statistically evaluated

An example of a DTPM is given below (fig 1a-d).

2.7 Performing a DTPM

The first step to perform a DTPM is to record a standardized color Doppler video of the respective tissue. In the case of intestinal diseases the bowel or gastric wall is focused on. Liver, pancreas and lymph nodes are equally useful targets of a DTPM investigation. In the following a typical procedure for examining the bowel in chronic inflammatory bowel diseases (IBD) is outlined.

With a linear Doppler probe the respective bowel segment is imaged. Colon segments are in most cases easily distinguished from small bowel segments by their haustra. Inflamed bowel segments expose themselves by their typical inflammatory changes: they are much thicker, darker and less mobile than normal ones (fig 2).

The bowel segment is then imaged with color Doppler ultrasound. The patient is asked to stop breathing for 3 seconds to prevent movements of the bowel segment. Most inflamed bowel segments are rather immobile so breathing sometimes can be continued. In all cases flushing movement color artifacts, which may veil larger parts of the image behind a curtain of a single color shade (which unmasks them as artifacts easily) have to be avoided. A video of 2 to 3 seconds duration is recorded then and transferred to the PC with the PixelFlux-software. The video file is then opened and calibrated according to the distances and the color hues. This is done by the software in DICOM-files and must be supported in avi-files by the investigator. The calibration is necessary to calculate areas and flow velocities. Flow velocities are calculated by direct comparison of each color pixel with the color bar. Since the software deciphers the velocity values from the color bar, it can assign to each pixel inside the bowel wall an individual velocity value. All pixels are measured and the sum of all colored pixels' area and the mean of all color pixels' velocity values is calculated. This is repeated automatically from the beginning to the end of a heart cycle. The software recognizes automatically complete heart cycles. The mean values of all colored areas (A) from one or more complete heart cycles and of all velocities (v) are calculated and referred to the area of the entire region of interest (A_{ROI}) to calculate the perfusion intensity Q (see above). Besides this most important parameter of perfusion more than 50 others are displayed and may add to the perfusion measurement (for details see www.chameleon-software.de) (Chameleon-Software, 2009). The perfusion intensity is used as the parameter to describe blood flow inside the bowel wall and can be used to grade hyperperfusion in inflammatory disorders. The grade of hyperperfusion is a measure of actual inflammatory processes at the investigation site.

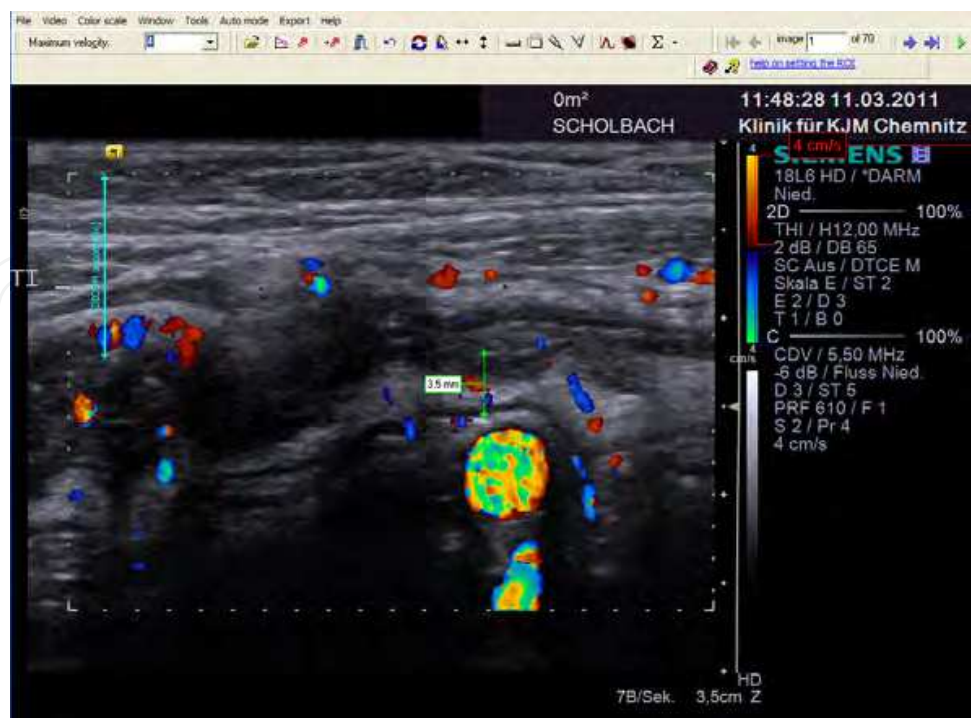

Fig. 1a. Color Doppler sonogram of the terminal ileum in a patient with Crohn disease

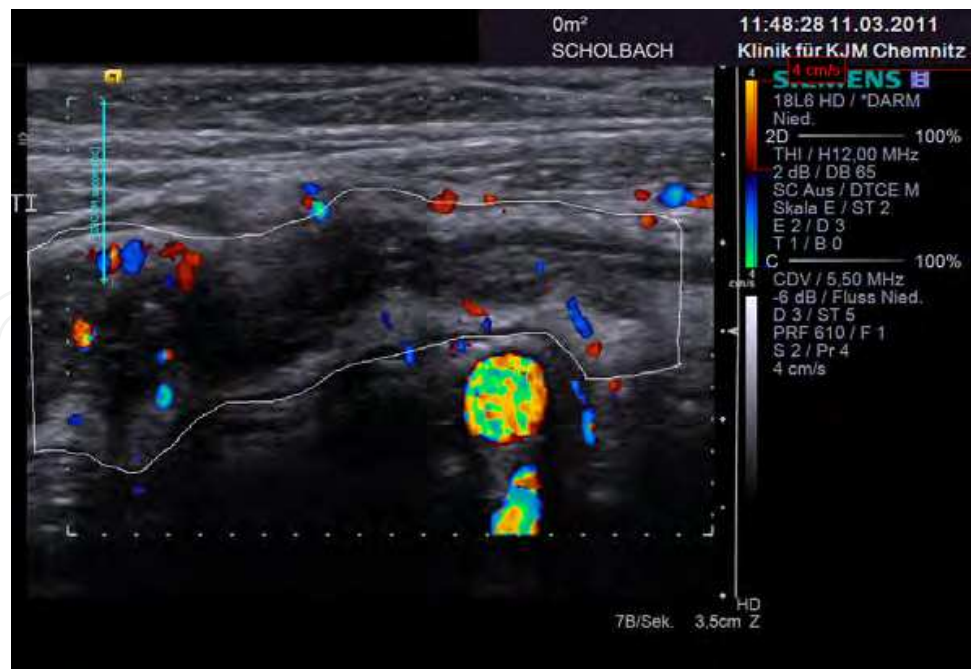

Fig. 1b. Freehand encirclement of the ROI. Posterior and anterior wall are included

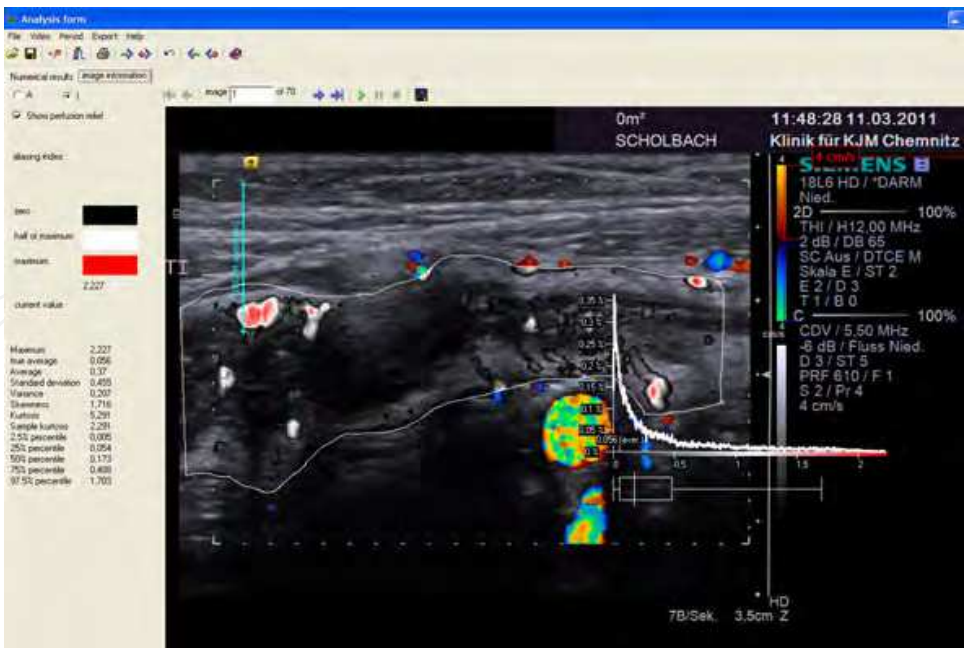


Fig. 1c. False color map of the terminal ileum in a patient with Crohn disease and diagram of the distribution of perfusion intensities with quartile boxplot (inset)

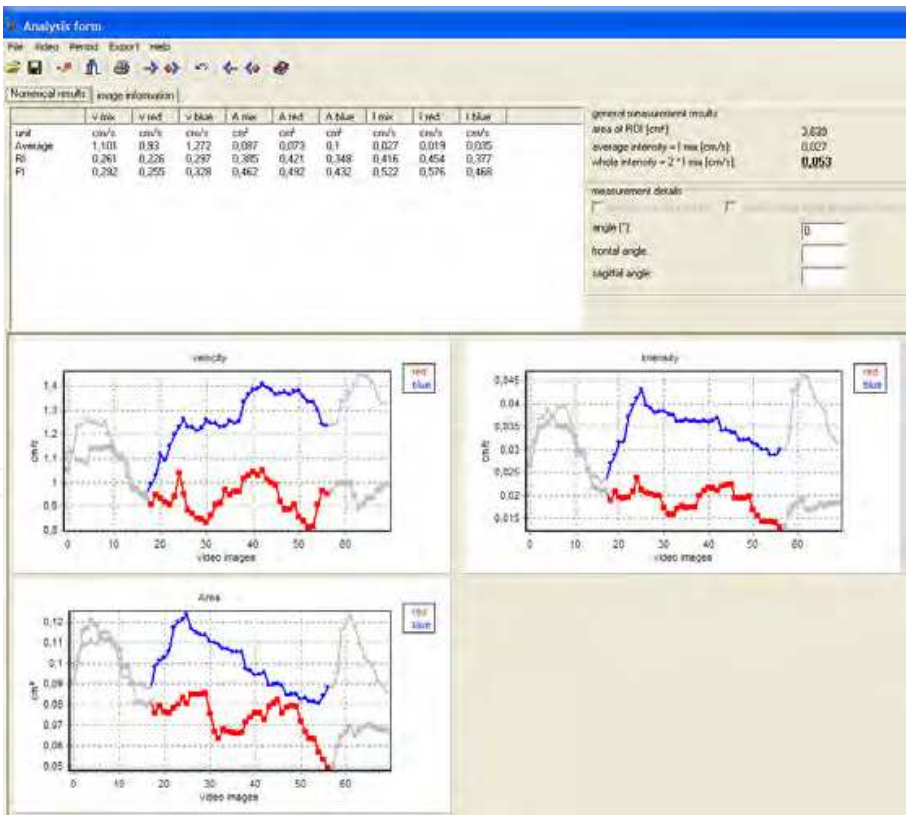
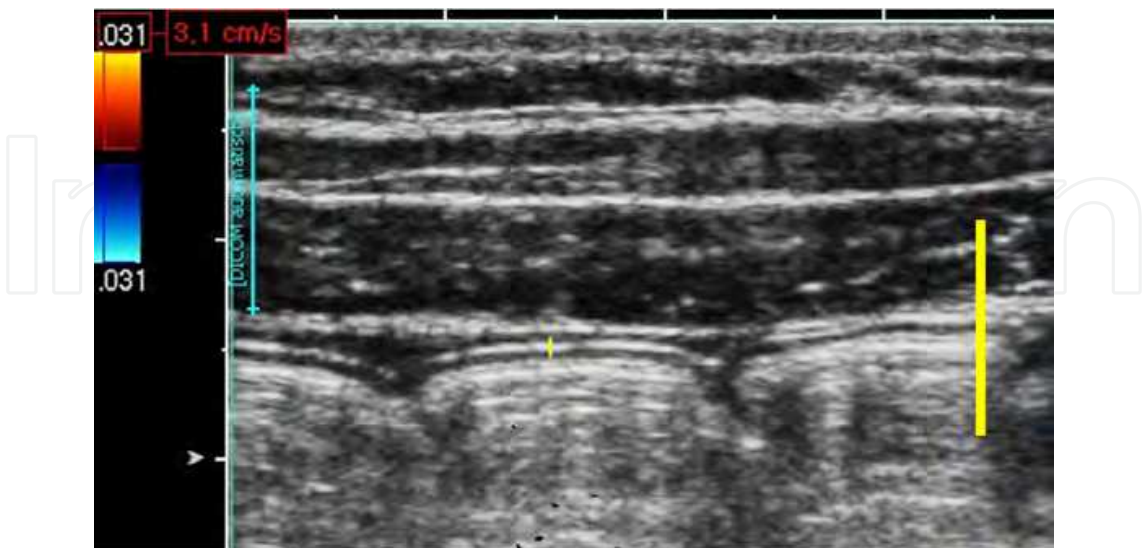
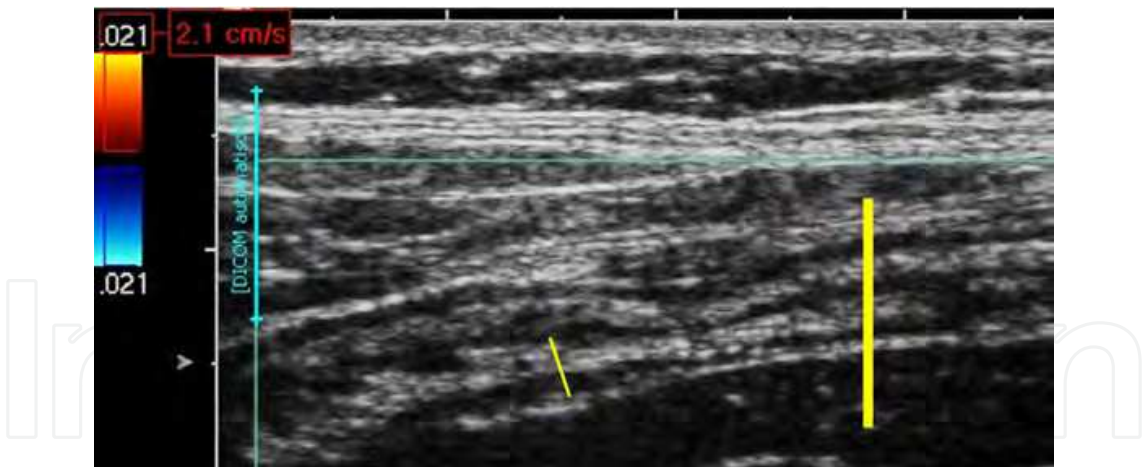


Fig. 1d. PixelFlux-output (abridged) indicating clue parameters as table and diagrams. The diagrams show the time course of flow velocities and perfused areas as well as the calculated perfusion intensities from the first to the last image of the respective video. Colored parts of the curves highlight the automatically recognized heart cycles.



Normal colon wall. (thick bar: 1 cm; thin bar anterior wall with three clearly discernable layers)

Fig. 2a. Color Doppler image of the wall of the ascending colon in a healthy proband



Normal wall of the terminal leum (thick bar: 1 cm; thin bar thickness of the posterior wall with three clearly discernable layers)

Fig. 2b. Color Doppler image of the wall of the erminal ileum in a healthy proband

2.7 Interpretation and normal values

Bowel wall perfusion intensity is low in healthy probands (tab.1, fig. 2a and 2b). Significant differences exist only between perfusion of the terminal ileum and some parts of the large bowel (tab. 2).

Bowel segment	N	Median of perfusion intensity [cm/s]	25. percentile [cm/s]	75. percentile [cm/s]	90. percentile [cm/s]	95. percentile [cm/s]
TI	13	0,008	0,002	0,015		
CA	18	0,007	0,001	0,009		
CT	11	0,004	0,001	0,007		
CD	15	0,003	0,001	0,007		
SI	18	0,003	0,002	0,006		
all	75	0,004	0,002	0,009	0,013	0,034

Table 1. Perfusion intensity in healthy probands

Bowel segment	TI	CA	CT	CD
CA	p=0,230			
CT	p=0,082	p=0,514		
CD	p=0,072	p=0,395	p=0,815	
SI	p=0,036	p=0,319	p=0,770	p=1,000

TI: terminal ileum
CA: ascending colon
CT: transverse colon
CD: descending colon

Table 2. Differences of perfusion intensities of different bowel segments in healthy probands (Mann-Whitney-U-test)

There are no overt differences of the bowel wall perfusion in fasting probands and probands examined without regard to the time interval to the last meal (fig 3).
The thickness of large and small bowel segments (terminal ileum) is significantly different in healthy probands (tab. 3 and 4) (Hormann, 2011):

Bowel segment	N	Median of bowel wall thickness [mm]	Maximum of bowel wall thickness [mm]
TI	13	1,9	2,1
CA	18	1,5	2,0
CT	11	1,5	1,8
CD	15	1,5	2,2
SI	18	1,4	2,1

Table 3. Bowel wall thickness of different segments in healthy adult probands

Bowel segment	TI	CA	CT	CD
CA	p=0,001			
CT	p < 0,001	p=0,412		
CD	p=0,008	p=0,817	p=0,357	
SI	p=0,003	p=0,650	p=0,877	p=0,556

Table 4. p-values of the two-tailed Mann-Whitney-U-test for differences of the bowel wall thickness of different segment in healthy adult probands

There is a weak inverse correlation (Spearman $p=0,018$, $r=-0,535$, $n=19$) of bowel wall perfusion intensity and the body mass index (BMI) (fig. 3)(Hormann, 2011). In contrast to this no correlation was found between BMI and the bowel wall thickness (fig. 4). In children similar results as in adults could be found (table 5 and 6) (Hormann, 2011).

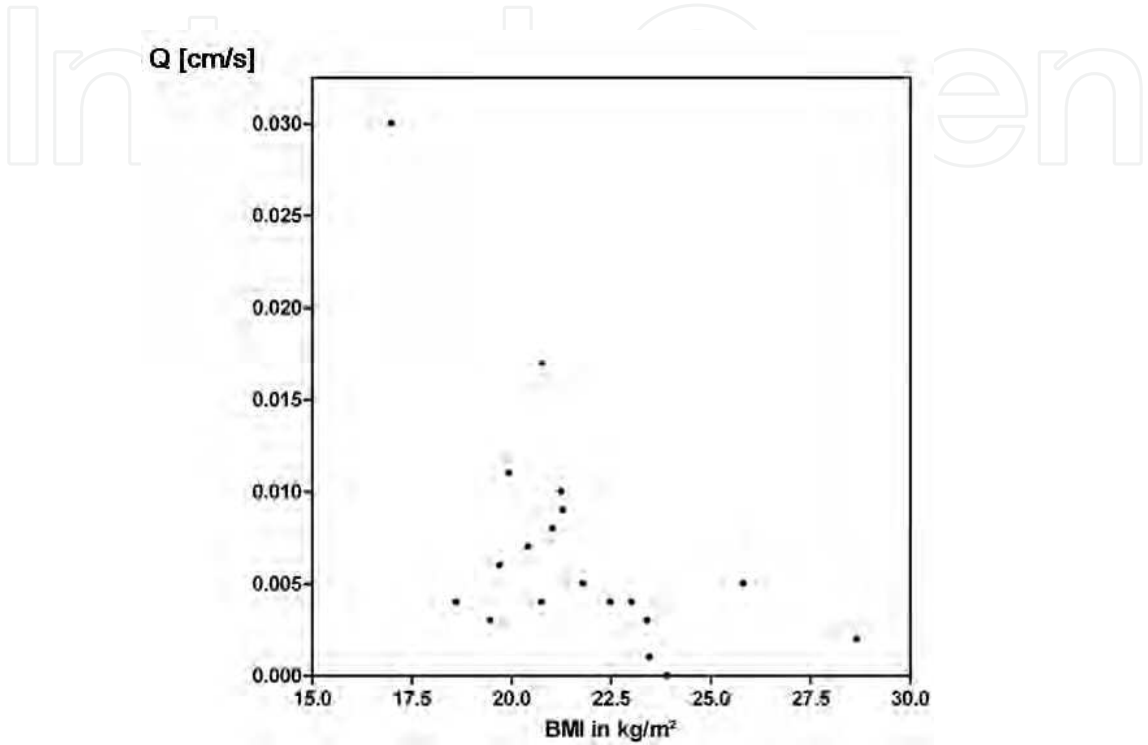


Fig. 3. Correlation between bowel wall perfusion and BMI

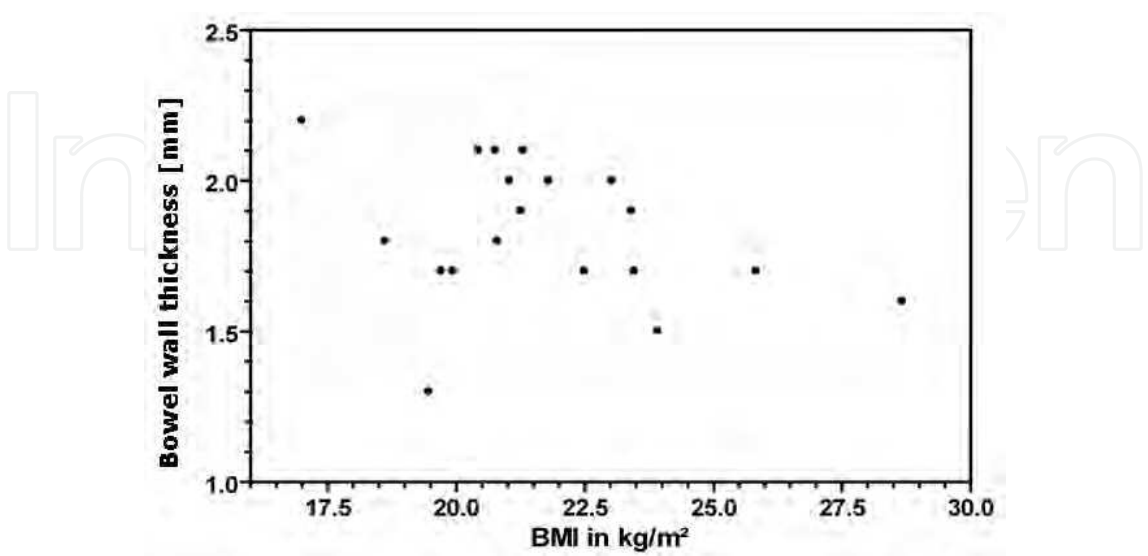


Fig. 4. Correlation of bowel wall thickness and BMI, $n=19$

Bowel segment	N	Median of perfusion intensity [cm/s]	25. percentile [cm/s]	75. percentile [cm/s]	90. percentile [cm/s]	95. percentile [cm/s]
TI	8	0,008	0,002	0,016		
CA	8	0,002	0	0,005		
CT	5	0,007	0	0,015		
CD	7	0,007	0,001	0,014		
SI	6	0,007	0,001	0,059		
all	34	0,007	0,001	0,014	0,028	0,071

Table 5. Median values and percentiles of bowel wall perfusion in healthy children in different bowel segments

Bowel segment	TI	CA	CT	CD
CA	p=0,130			
CT	p=0,524	p=0,621		
CD	p=0,694	p=0,281	p=0,755	
SI	p=0,852	p=0,181	p=0,537	p=0,731

Table 6. p-values of the two-tailed Mann-Whitney-U-test for differences of the bowel wall thickness of different segment in healthy children

Bowel segment	N	Median of bowel wall thickness [mm]	Maximum of bowel wall thickness [mm]
TI	8	1,9	2,6
CA	8	1,5	2,6
CT	5	1,5	2,5
CD	7	1,5	2,6
SI	6	1,4	2,8

Table 7. Bowel wall thickness of different segments in healthy children

Bowel segment	TI	CA	CT	CD
CA	p=0,232			
CT	p=0,524	p=0,755		
CD	p=0,382	p=0,955	p=0,833	
SI	p=0,181	p=0,836	p=0,537	p=0,950

Table 8. Differences of perfusion intensities of different bowel segments in healthy children (Mann-Whitney-U-test)

Between healthy adults and children no significant differences of the bowel wall perfusion could be demonstrated in comparison of all bowel segments (TI, CA, CT, CD, SI) (figure 5) and also no significant differences could be demonstrated in perfusion intensity (fig. 6) (Hormann, 2011).

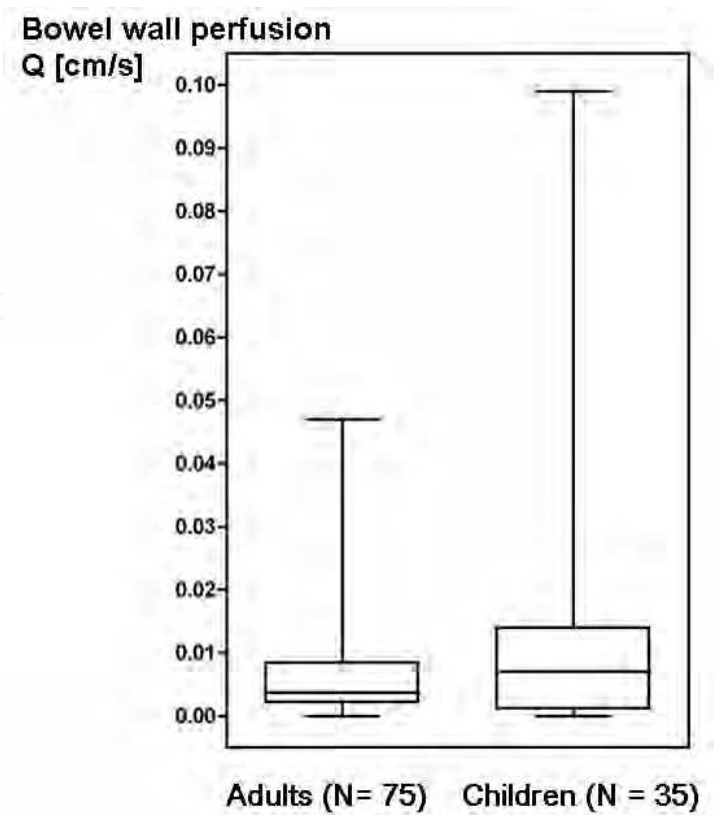


Fig. 5. Comparison of bowel wall perfusion between healthy adults and children - no significant differences (Mann-Whitney-U-test: $p=0,783$; N: number of bowel segments).

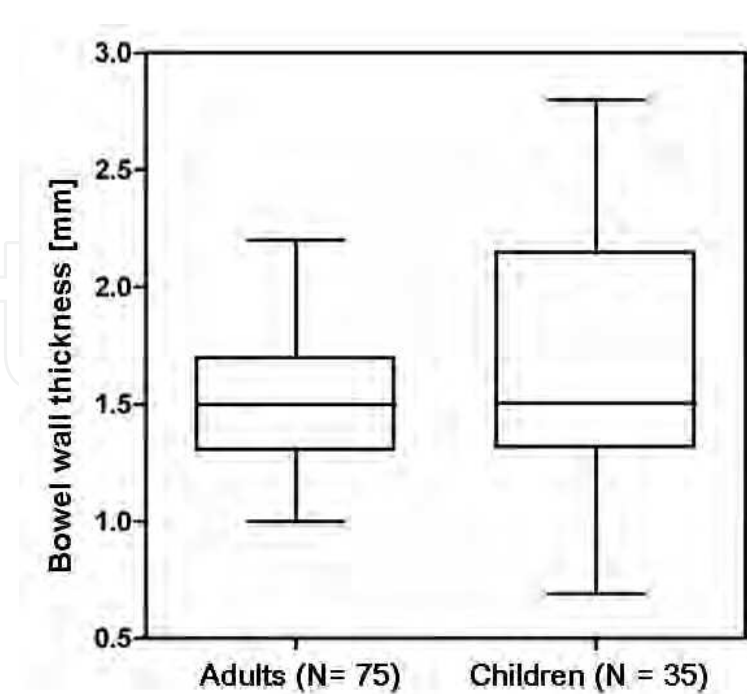


Fig. 6. Comparison of bowel wall thickness between healthy adults and children - no significant differences (Mann-Whitney-U-test: $p=0,680$; N: number of bowel segments).

3. DTPM in gastroenterology

3.1 Chronic inflammatory bowel diseases (IBD)

IBD constitute a diagnostic and therapeutic challenge as their symptoms start creepingly and are unspecific. Their course is unpredictable and complicated by spontaneous recovery as well as unexpected outbreaks. The diagnostic gold standard today is the histology and endoscopic description. The threshold for endoscopy is high due to its invasiveness, need for preparation, discomfort and pain for the patient, often requiring general anesthesia, and costs. Non-invasive methods are therefore urgently wanted to make the diagnosis and to describe the natural course of IBD, their intestinal extent and the effects of treatment. Ideally complications should be also evaluated with noninvasive techniques. Imaging modalities hold the promise of being non-invasive (aside from the need of contrast media injection for CT, MRI or angiography or the necessity to infuse or drink enemas). Ultrasound combines the advantages of being noninvasive too while offering a spatial resolution which other techniques cannot achieve. Moreover this is combined with hemodynamic information displayed as color Doppler signals that give functional information and direct insight into the local inflammatory reaction which is from ancient times described as a process characterized by rubor, tumor, calor, dolor and functio laesa. All of them are reflected in color Doppler sonography as increased perfusion causing redness resp. increased coloration, heat resp. increased temperature by activated metabolism fueled by hyperperfusion, pain which can be traced by one finger palpation during the ultrasound investigation directly, swelling to be detected in B-mode ultrasound images and disturbed function which is reflected, among others, by stiffness of the thickened bowel wall and dampened peristalsis. It is therefore a logical step to use color Doppler ultrasound to describe this inflammation. Unfortunately conventional approaches fall short compared to the inherent potential of the method. Perfusion estimates from changes of the Resistance index (Britton et al., 1998) in the superior mesenteric artery do not take into account the blood volumes passing through the intestines and do not elucidate the specific increase caused by a certain affected bowel segment. More precise insight is possible by direct evaluation of the affected intestinal segment. To quantify inflammatory hyperperfusion inside the bowel wall scores have been proposed which count vessels or perfused area inside a bowel wall segment in still images. DTPM expands these approaches. It does not only count vessels but measures each pixel's velocity value and area but refers these data to the area of the bowel wall and to full heart cycles. This way changes of these parameters which cause relevant spread of measurements in still images can be overcome and the error of measurement reduced which on the other hand is inevitable with the use of still images in describing a dynamic phenomenon as cyclic perfusion basically is.

The following section describe in detail the advantages of DTPM in Crohn disease and ulcerative colitis.

3.1.1 Crohn disease (CrD)

CrD is diagnosed in increasing frequency in the industrialized countries (Munkholm et al., 1993; Pozler et al., 2006; Shoda et al., 1996; Vind et al., 2006). Its main localization is the terminal ileum which is easily accessible with ultrasound. Other intestinal sites may be also affected. Even with small bowel affections others than the TI the diseased site can be retrieved by ultrasound since the inflammation causes prominent swelling and hyperperfusion which are readily found.

CrD is a transmural inflammation which typically causes a disruption of the clear borders between the intestinal layers which in healthy intestines can be clearly distinguished in all parts of the intestines (fig. 2a and 2b). This blurring of the inner wall structure may resolve and a thickened submucosal layer may point to chronic fibrotic changes. In acute stages prominent fat wrapping encapsulating the inflamed loops may be quite impressive. This mesenteric fat may host dilated vessels running in intervals to the inflamed segment to feed shorter pieces of the intestinal tube. Enlarged local lymph nodes accompany the inflammation but may be not differentiated in B-mode alone from resting but still enlarged ones. Here the use of color Doppler ultrasound is quite helpful or even necessary. As in the bowel wall in the surrounding structures perfusion intensity can be measured and thus compared to the bowel perfusion. Thus it is possible to discriminate different degrees of inflammation and to determine its focus. DTPM has proven to give valuable diagnostic and treatment-relevant information in patients with CrD (Scholbach et al., 2005b).

An example of CrD with transition from normal to inflamed bowel segments is given in figures 8a and 8b. B-Mode alone is suspicious for IBD but cannot tell resting from exacerbated disease. Color Doppler, in a standardized fashion of image acquisition, however, can show, that there is actually an inflammation going on. But to which degree this inflammation has already evolved cannot be deduced from such an image. To accomplish this, a semiquantitative method (Heyne et al., 2002; Rogoveanu et al., 2003; Ruess et al., 2000; Spalinger et al., 2000), contrast enhanced sonographic perfusion evaluation (Girlich et al., 2009; Ripolles et al., 2009) or even better, since not requiring invasive and costly procedures, DTPM is necessary. An example of its results is shown in fig. 8b. The red column refers to the perfusion intensity in the thin-walled segment, whereas the green one describes perfusion intensity on the neighboring segment. So it is very easy to compare different parts of the intestinal tract with respect to their actual involvement into an IBD. This holds true for the effects of treatment too. Figure 9 shows the differing impact of treatment onto various bowel segments highlighting where the disease is still active. This may aid the planning of future treatment modalities in selected cases. In this case the ascending colon responded much quicker and stronger than the descendent colon in a patient with CrD.

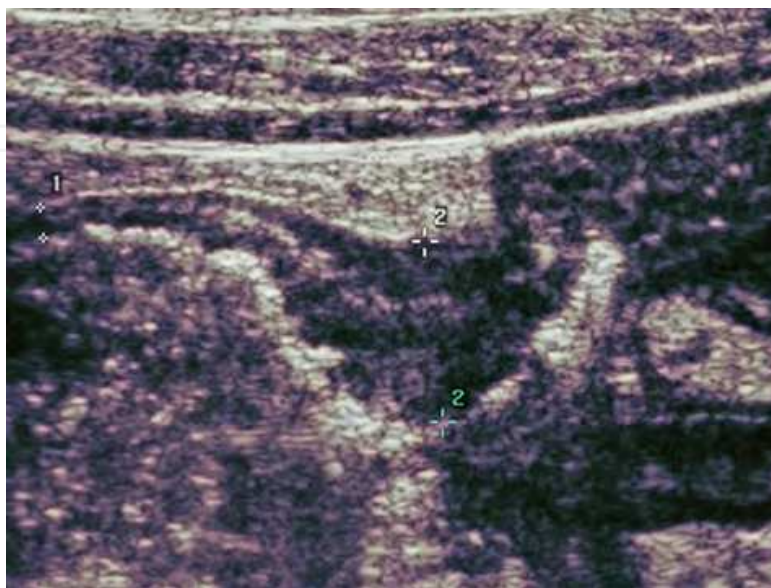


Fig. 8a. B-mode ultrasound image of the transition from normal to inflamed colon in CrD

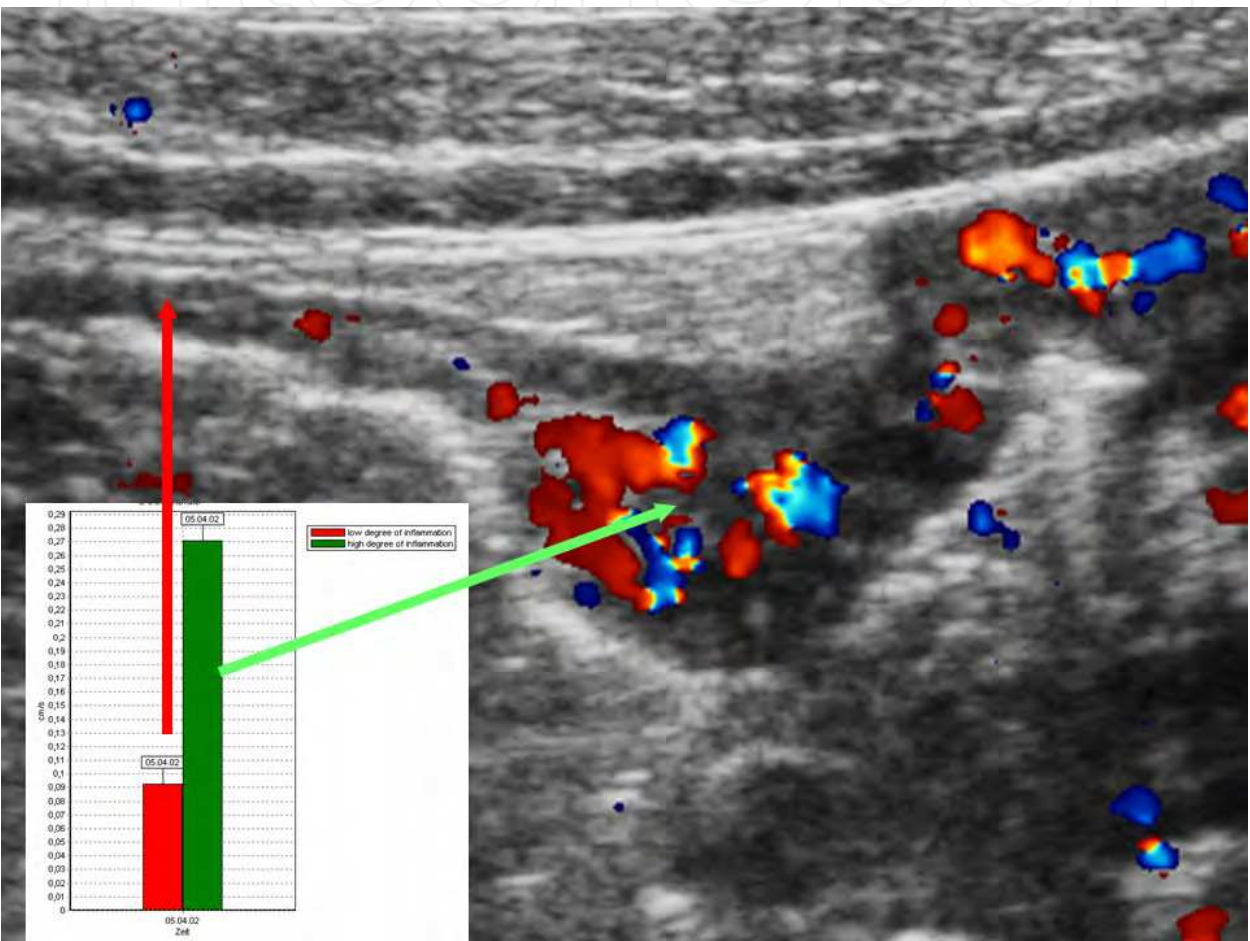


Fig. 8b. Same image as in fig. 8a in color Doppler mode. Inset showing the results of dynamic tissue perfusion measurement in both segments.

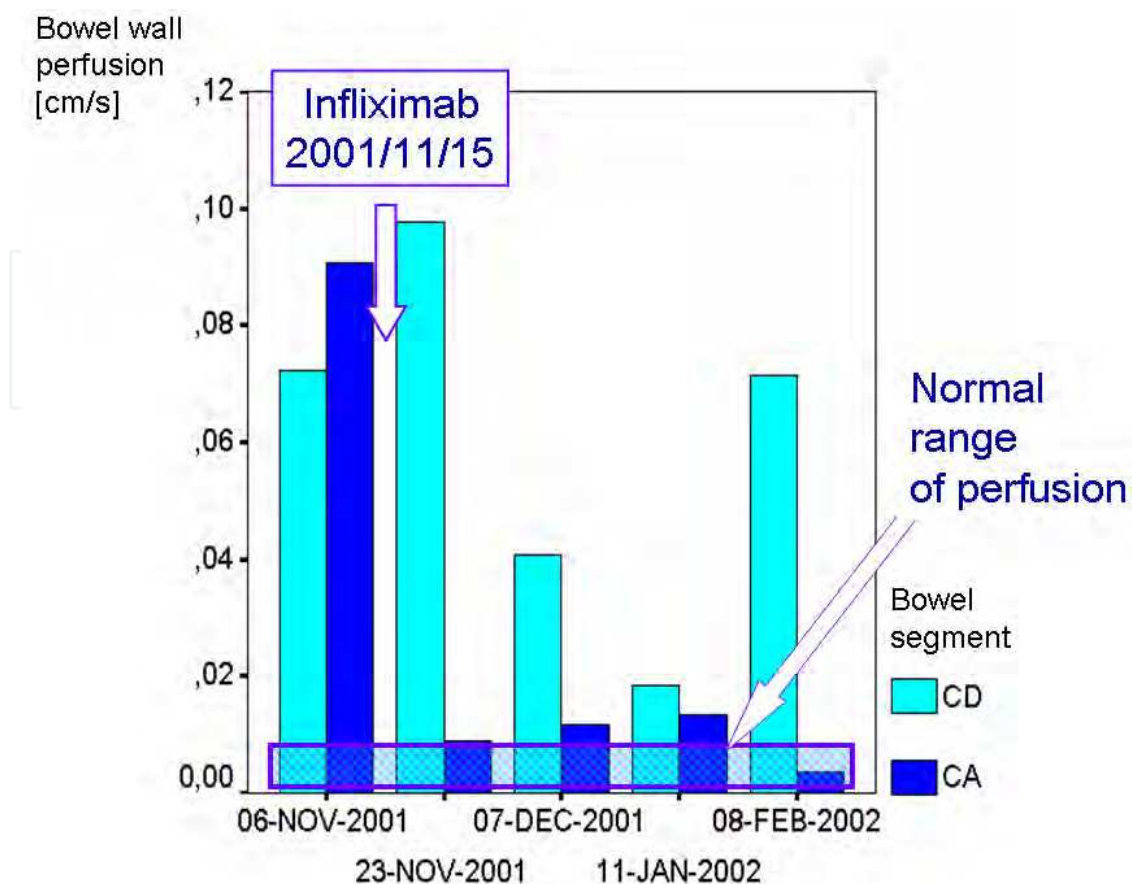


Fig. 9. Differing response of different bowel segments to Infiximab treatment. Descending colon (CD) responding later and less pronounced than ascending colon (CA). Normal range highlighted as semitransparent box.

Complications of CrD as fistulas can be described with great scrutiny. In figure 10a the cutaneous mouth of a fistula in CrD is shown and its closure is documented shortly after treatment with Infiximab. One might assume, that a profound suppression of the inflammation occurred. However, DTPM shows the details of fistula perfusion thus demonstrating, that there is a clear reduction of hyperperfusion but to a remaining value of 61% of the original one. The investigation of the intestinal opening of the fistula gives more information (fig. 10b). Here it becomes quite obvious, that further treatment is necessary to dampen the inflammation in order to prevent a new outbreak of the fistula. Repeated Infiximab infusions eventually led to a normalization of the initial hyperperfusion and resulted clinically in a permanent closure of the fistula. The terminal ileum, away from the fistula bearing colon, showed a different but substantial response too (fig. 10c).

Clinical assessment of disease activity might be difficult, especially in children. Often activity indices are sought to establish a basis to compare activity scores along with treatment and over time. These indices are a composition of clinical, anamnestic and laboratory data. They cannot describe the disease activity at its origin but are used when other tools cannot be applied (repeated endoscopies) or are lacking. DTPM can fill this gap. We found a weak but significant correlation of Children's Crohn Activity Index to bowel wall perfusion intensity measured with DTPM (fig. 11a). An individual example (fig. 11b) demonstrates that there may be a clear discrepancy between the locally measured disease activity and the pediatric CAI. Striking changes of local inflammatory hyperperfusion fail to

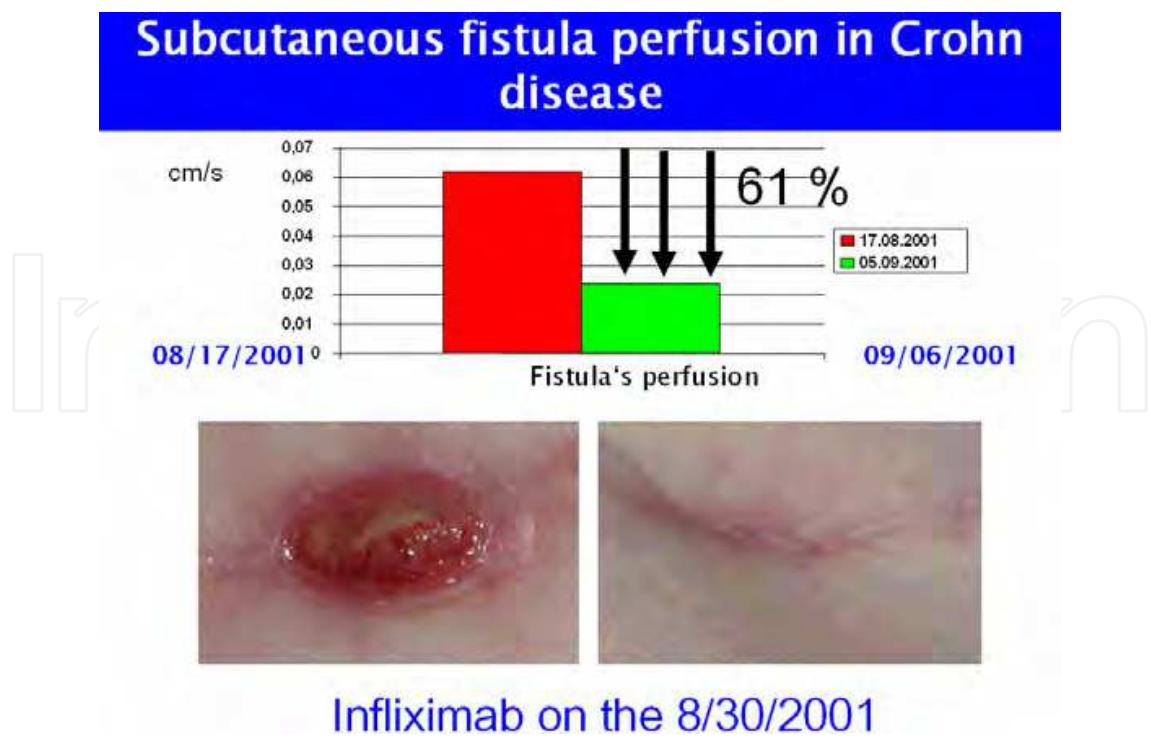


Fig. 10a. Enterocutaneous fistula in CrD evaluated clinically (below) and by means of DTPM (upper part). Infliximab treatment caused a closure of the cutaneous mouth and a reduction of fistula’s hyperperfusion to 61%.

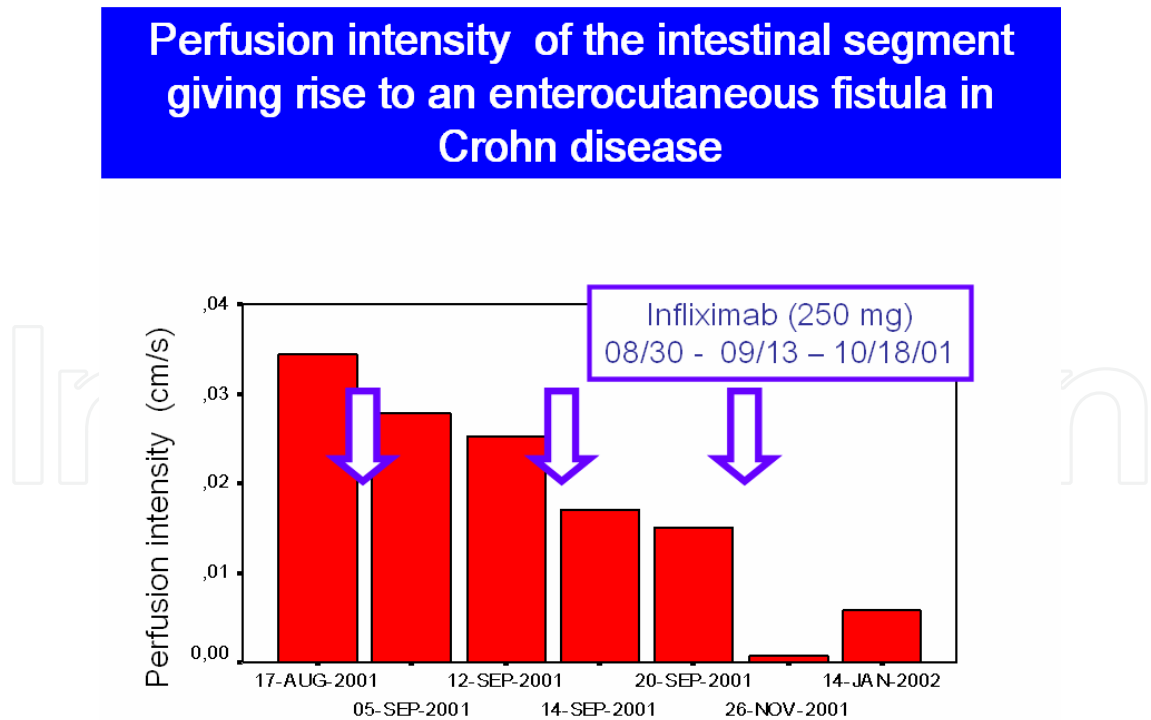


Fig. 10b. Same patient as in fig. 10a. Here DTPM of the colonic segment around the enteric opening of the fistula. In contrast to the proper fistula bowel perfusion drops less readily and signals the need of further treatments, which, after all, led to a normalization of perfusion.

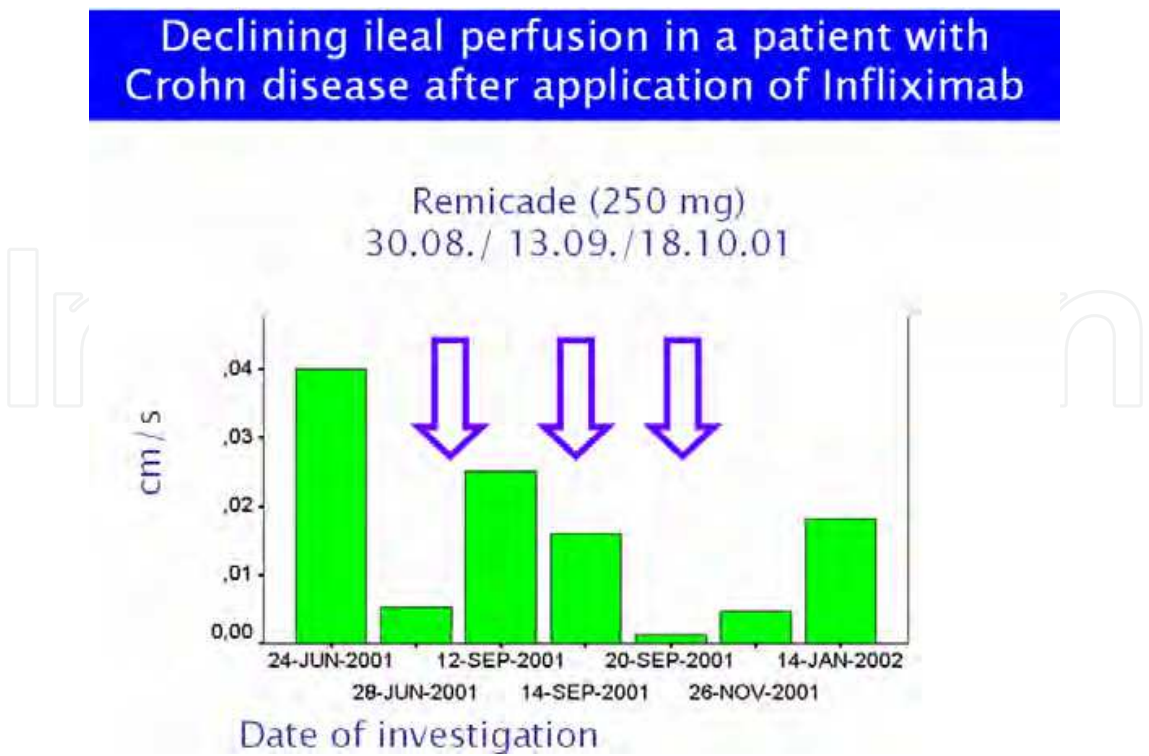


Fig. 10c. Same patient as in 10 a and 10b. The terminal ileum responds differently compared to fistula and colonic fistula origin.

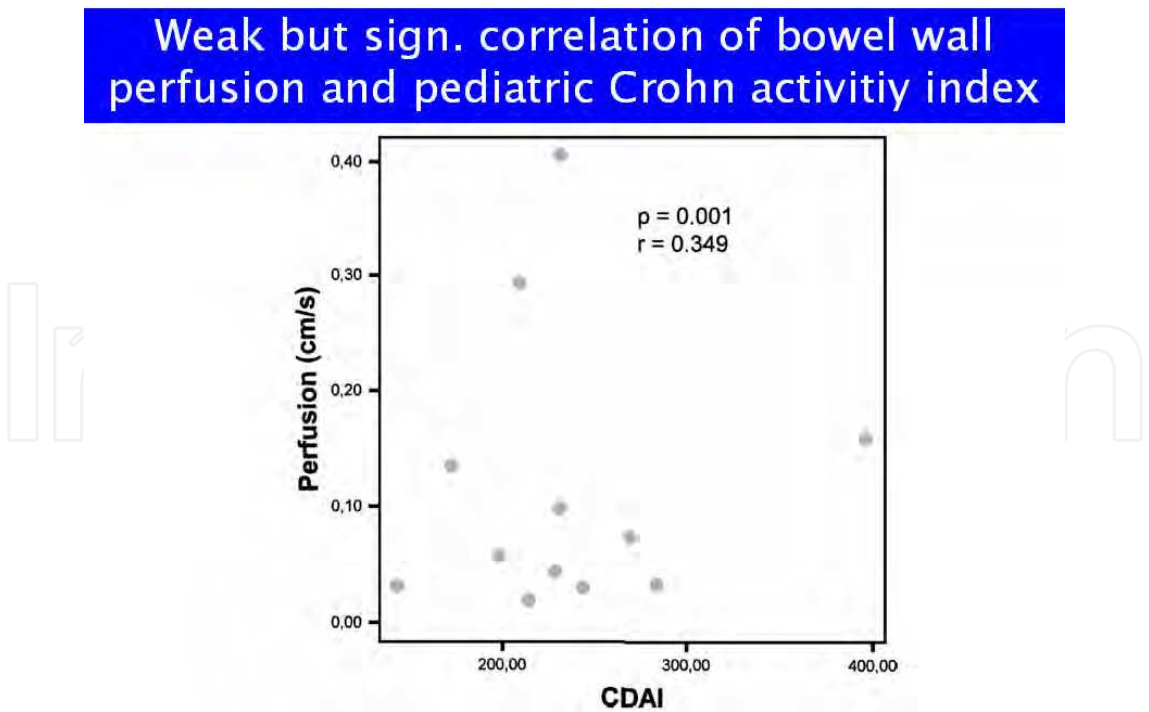


Fig. 11a. Weak but significant correlation of bowel wall perfusion intensity and pediatric Crohn activity index.

Divergent activity assessment with CAI and DTPM

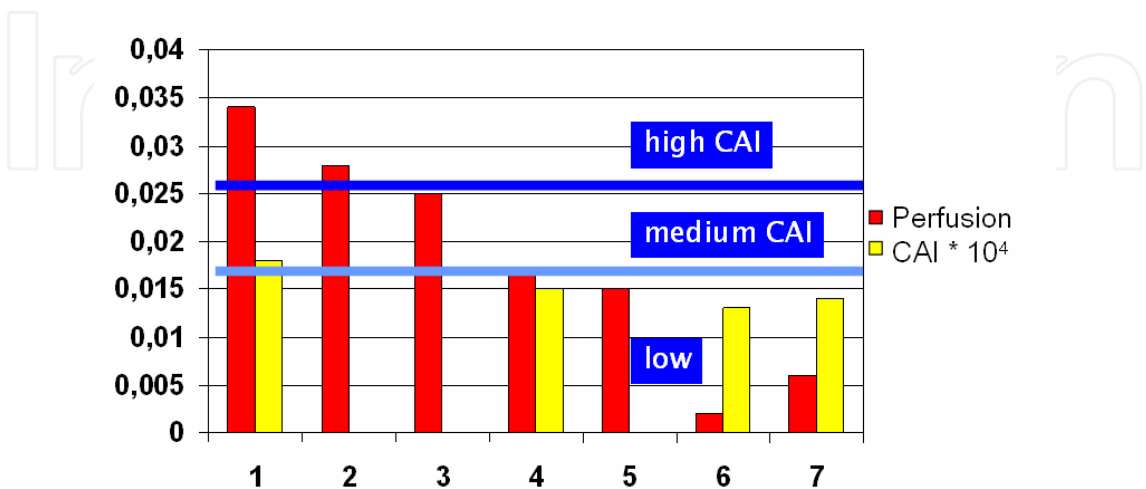


Fig. 11b. Obvious differences of inflammation evaluation in an individual with CrD by means of DTPM and pediatric Crohn activity index (CAI). Red columns: Perfusion intensity; yellow columns: CAI. Perfusion intensity follows the actual inflammation more closely than CAI leading to diverging assessment of disease activity.

be mirrored by an adequate fluctuation of the CAI. However, this is not surprising with regard to the different sources of information in both methods. DTPM measures local perfusion whereas the indices refer to indirect criteria only. Similar results were found by others comparing bowel wall thickening and biochemical indices of inflammation (Mayer et al., 2000)

3.1.2 Ulcerative colitis (UC)

As in CrD UC-incidence is increasing too (Jakobsen et al., 2008) but contradictory reports have been also published (Loftus et al., 2007; Molinie et al., 2004). In less industrialized regions similar incidences as in industrialized countries were found for both CD and UC (Sood et al., 2003). This stresses the need for a fast and reliable, cheap and non-invasive diagnostic tool for these conditions. DTPM, which meets these needs, can affirm the presence of colonic inflammation and describe its activity quite clearly.

We correlated several histological parameters (table 9) of UC with DTPM at the site of the biopsies in 19 patients with UC (Scholbach et al., 2010).

Patients with UC demonstrated a weak but significant correlation of their bowel wall perfusion intensity and wall thickness (fig. 7).

A synopsis of histological, endoscopic and color Doppler images underscores the advantage of a perfusion measurement (figure 12). It is helpful to describe the degree of inflammation numerically in order to substantiate the visual impression of imaging and the verbal description of findings. The columns demonstrate clearly how DTPM can tell severe from medium and low grade inflammation whereas the images themselves are important and impressive but cannot convey such precise information that would make them numerically

Score points	0	1	2	3
Changes of crypt architecture (Bentley et al., 2002)	none	minor	moderate	severe
Depletion of goblet cells(Guindi & Riddell, 2004; Hendrickson et al., 2002; Morson, 1971)	no	minor	moderate	severe
Paneth cells distal of the left colon flexure (Bentley et al., 2002)	none	few	some	many
Lymphocytes (Ajioka et al., 2005; Bentley et al., 2002; Eksteen et al., 2008)	normal concentration	minor increase	relevant increase	severe increase
Plasma cells (Bentley et al., 2002; Morson, 1971)	normal concentration	minor increase	relevant increase	severe increase
Eosinophils (Eksteen et al., 2008; Schmitz-Moormann & Himmelmann, 1988)	normal concentration	minor increase	relevant increase	severe increase
unspecific inflammatory infiltrates (Bentley et al., 2002)	none	minor	moderate	severe
PMNs in Lamina propria and Lamina epithelialis (Glickman et al., 2004; Reaves et al., 2005; Wang et al., 2004)	normal concentration	minor increase	relevant increase	severe increase
Crypt abscesses (Bentley et al., 2002; Glickman et al., 2004; Hendrickson et al., 2002; Morson, 1971)	none	few	some	many
Edema (Hendrickson et al., 2002)	none	minor	moderate	severe

Score points	0	1	2	3
Erosions or ulcerations (Bentley et al., 2002; Hendrickson et al., 2002)	none	erosion	large erosions	ulcera
regenerative epithelium (Lee, 1987; Morson, 1971)	none	scarce	relevant	
Fibrosis (Mitomi et al., 2005; Schmitz- Moormann & Himmelmann, 1988)	none	minor	moderate	severe
Increased cryptal distance to muscularis mucosae (Morson, 1971; Robert et al., 2004; Schmitz-Moormann & Himmelmann, 1988)	none	minor	moderate	severe

Table 9. Histological criteria compared with DTPM from the biopsy site

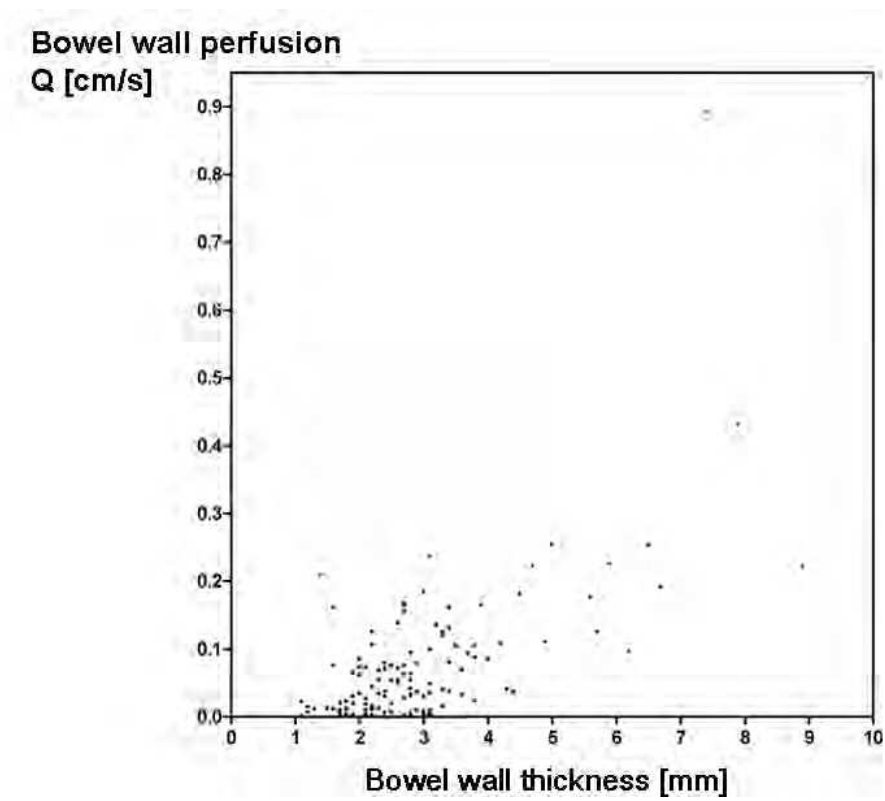


Fig. 7. Correlation of bowel wall perfusion and wall thickness in patients with ulcerative colitis (Spearman $p<0,001$, $r=0,563$)

comparable. With respect to the color Doppler images it must be stressed, that the information given by single images may be misleading since the image is taken from an undefined point of the heart cycle. The visual impression changes profoundly from systole to diastole. DTPM, in contrary evaluates all images of an entire heart cycle, thus ruling out this error.

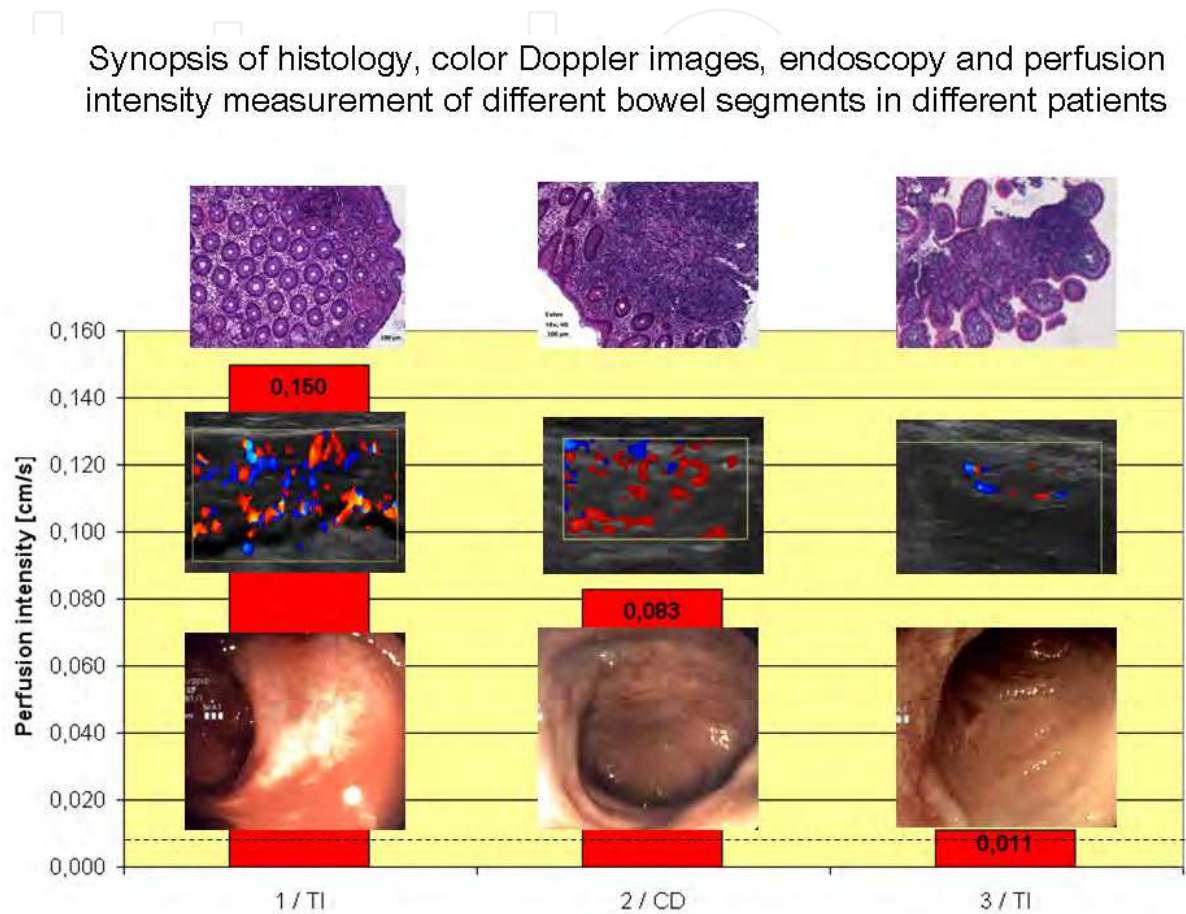


Fig. 12. Synopsis of histology (upper row), color Doppler images (central row), endoscopy (lower row), and perfusion intensity measurement (red columns) of different bowel segments (TI: terminal ileum, CD: descending colon) in different patients (1-3). Normal range limit indicated by dashed line.

4. Summary

In IBD, in CrD as well as in UC, a fast, convenient, inexpensive and reliable assessment of the intestinal inflammation is possible without preparation of the patient. DTPM allows a true comparison of measurement results in the course of the disease by the use of standardized imaging conditions, defined ultrasound presets and an objective software-based calculation of inflammatory hyperperfusion. Significant correlations could be demonstrated with established histological criteria. DTPM is thus an adjunct to colonoscopy quantifying inflammation with minimal effort. In some cases it may even replace a control endoscopy. In all cases it will add to the endoscopic findings what cannot be perceived from the luminal perspective: the reliable, since numerical description of the periintestinal


structures and their perfusion as well as a refined description of the changes inside the submucosal layers of the intestinal wall.

5. References

- Ajioka, Y., Nishikura K. & Watanabe G. 2005. [Pathomorphology of ulcerative colitis]. *Nippon Rinsho* 63:763-769.
- Bentley, E., Jenkins D., Campbell F. & Warren B. 2002. How could pathologists improve the initial diagnosis of colitis? Evidence from an international workshop. *J Clin Pathol* 55:955-960.
- Britton, I., Maguire C., Adams C., Russell R. I. & Leen E. 1998. Assessment of the role and reliability of sonographic post-prandial flow response in grading Crohn's disease activity. *Clin Radiol* 53:599-603.
- Chameleon-Software. 2009. PixelFlux. www.chameleon-software.de
- Eksteen, B., Liaskou E. & Adams D. H. 2008. Lymphocyte homing and its role in the pathogenesis of IBD. *Inflamm Bowel Dis* 14:1298-1312.
- Girlich, C., Jung E. M., Iesalnieks I., Schreyer A. G., Zorger N., Strauch U. & Schacherer D. 2009. Quantitative assessment of bowel wall vascularisation in Crohn's disease with contrast-enhanced ultrasound and perfusion analysis. *Clin Hemorheol Microcirc* 43:141-148.
- Glickman, J. N., Bousvaros A., Farraye F. A., Zholudev A., Friedman S., Wang H. H., Leichtner A. M. & Odze R. D. 2004. Pediatric patients with untreated ulcerative colitis may present initially with unusual morphologic findings. *Am J Surg Pathol* 28:190-197.
- Guindi, M. & Riddell R. H. 2004. Indeterminate colitis. *J Clin Pathol* 57:1233-1244.
- Hendrickson, B. A., Gokhale R. & Cho J. H. 2002. Clinical aspects and pathophysiology of inflammatory bowel disease. *Clin Microbiol Rev* 15:79-94.
- Heyne, R., Rickes S., Bock P., Schreiber S., Wermke W. & Lochs H. 2002. Non-invasive evaluation of activity in inflammatory bowel disease by power Doppler sonography. *Z Gastroenterol* 40:171-175.
- Hormann, J. 2011. Farbduplexsonografische Gewebep erfusionsmessung im Vergleich mit histologischen Untersuchungen der Darmwand bei pädiatrischen Patienten mit Colitis ulcerosa
- Jakobsen, C., Wewer V., Urne F., Andersen J., Faerk J., Kramer I., Stagegaard B., Pilgaard B., Weile B. & Paerregaard A. 2008. Incidence of ulcerative colitis and Crohn's disease in Danish children: Still rising or levelling out? *J Crohns Colitis* 2:152-157.
- Lee, R. G. 1987. Villous regeneration in ulcerative colitis. *Arch Pathol Lab Med* 111:276-278.
- Loftus, C. G., Loftus E. V., Jr., Harmsen W. S., Zinsmeister A. R., Tremaine W. J., Melton L. J., 3rd & Sandborn W. J. 2007. Update on the incidence and prevalence of Crohn's disease and ulcerative colitis in Olmsted County, Minnesota, 1940-2000. *Inflamm Bowel Dis* 13:254-261.
- Mayer, D., Reinshagen M., Mason R. A., Muche R., von Tirpitz C., Eckelt D., Adler G., Beckh K. & Kratzer W. 2000. Sonographic measurement of thickened bowel wall segments as a quantitative parameter for activity in inflammatory bowel disease. *Z Gastroenterol* 38:295-300.
- Mitomi, H., Okayasu I., Bronner M. P., Kanazawa H., Nishiyama Y., Otani Y., Sada M., Tanabe S., Igarashi M., Katsumata T. & Saigenji K. 2005. Comparative histologic

- assessment of proctocolectomy specimens from Japanese and American patients with ulcerative colitis with or without dysplasia. *Int J Surg Pathol* 13:259-265.
- Molinie, F., Gower-Rousseau C., Yzet T., Merle V., Grandbastien B., Marti R., Lerebours E., Dupas J. L., Colombel J. F., Salomez J. L. & Cortot A. 2004. Opposite evolution in incidence of Crohn's disease and ulcerative colitis in Northern France (1988-1999). *Gut* 53:843-848.
- Morson, B. C. 1971. Pathology of ulcerative colitis. *Proc R Soc Med* 64:976-977.
- Munkholm, P., Langholz E., Nielsen O. H., Kreiner S. & Binder V. 1993. [Increased incidence of Crohn disease in the county of Copenhagen]. *Ugeskr Laeger* 155:3199-3202.
- Pozler, O., Maly J., Bonova O., Dedek P., Fruhauf P., Havlickova A., Janatova T., Jimramovsky F., Klimova L., Klusacek D., Kocourkova D., Kolek A., Kotalova R., Marx D., Nevoral J., Petro R., Petru O., Plasilova I., Seidl Z., Sekyrova I., Semendak N., Schreierova I., Stanek J., Sykora J., Sulakova A., Toukalkova L., Travnickova R., Volf V., Zahradnicek L. & Zeniskova I. 2006. Incidence of Crohn disease in the Czech Republic in the years 1990 to 2001 and assessment of pediatric population with inflammatory bowel disease. *J Pediatr Gastroenterol Nutr* 42:186-189.
- Reaves, T. A., Chin A. C. & Parkos C. A. 2005. Neutrophil transepithelial migration: role of toll-like receptors in mucosal inflammation. *Mem Inst Oswaldo Cruz* 100 Suppl 1:191-198.
- Ripolles, T., Martinez M. J., Paredes J. M., Blanc E., Flors L. & Delgado F. 2009. Crohn disease: correlation of findings at contrast-enhanced US with severity at endoscopy. *Radiology* 253:241-248.
- Robert, M. E., Tang L., Hao L. M. & Reyes-Mugica M. 2004. Patterns of inflammation in mucosal biopsies of ulcerative colitis: perceived differences in pediatric populations are limited to children younger than 10 years. *Am J Surg Pathol* 28:183-189.
- Rogoveanu, I., Saftoiu A., Cazacu S. & Ciurea T. 2003. Color Doppler transabdominal ultrasonography for the assessment of the patients with inflammatory bowel disease during treatment. *Rom J Gastroenterol* 12:277-281.
- Rouviere, O., Curiel L., Chapelon J. Y., Bouvier R., Ecochard R., Gelet A. & Lyonnet D. 2004. Can color doppler predict the uniformity of HIFU-induced prostate tissue destruction? *Prostate* 60:289-297.
- Ruess, L., Blask A. R., Bulas D. I., Mohan P., Bader A., Latimer J. S. & Kerzner B. 2000. Inflammatory bowel disease in children and young adults: correlation of sonographic and clinical parameters during treatment. *AJR Am J Roentgenol* 175:79-84.
- Schmitz-Moormann, P. & Himmelmann G. W. 1988. Does quantitative histology of rectal biopsy improve the differential diagnosis of Crohn's disease and ulcerative colitis in adults? *Pathol Res Pract* 183:481-488.
- Scholbach T, Scholbach J. & Stöppler M. 2011. unpublished results.
- Scholbach, T., Dimos I. & Scholbach J. 2004. A new method of color Doppler perfusion measurement via dynamic sonographic signal quantification in renal parenchyma. *Nephron Physiol* 96:p99-104.
- Scholbach, T., Girelli E. & Scholbach J. 2005a. Dynamic tissue perfusion measurement: a novel tool in follow-up of renal transplants. *Transplantation* 79:1711-1716.
- Scholbach, T., Scholbach J., Krombach G. A., Gagel B., Maneschi P. & Di Martino E. 2005b. New method of dynamic color doppler signal quantification in metastatic lymph

- nodes compared to direct polarographic measurements of tissue oxygenation. *Int J Cancer* 114:957-962.
- Scholbach, T., Girelli E. & Scholbach J. 2006. Tissue pulsatility index: a new parameter to evaluate renal transplant perfusion. *Transplantation* 81:751-755.
- Scholbach, T., Hormann J. & J. S. 2010. Dynamic tissue perfusion measurement of the intestinal wall - correlation to histology in ulcerative colitis. *Journal of Medical Ultrasound* 18:62-70.
- Scholbach, T., Koblre A. & Bergner N. 2011. unpublished results.
- Scholbach, T. & Scholbach J. 2009. Can We Measure Renal Tissue Perfusion by Ultrasound? *Journal of Medical Ultrasound* 17:9-16.
- Shoda, R., Matsueda K., Yamato S. & Umeda N. 1996. Epidemiologic analysis of Crohn disease in Japan: increased dietary intake of n-6 polyunsaturated fatty acids and animal protein relates to the increased incidence of Crohn disease in Japan. *Am J Clin Nutr* 63:741-745.
- Sood, A., Midha V., Sood N., Bhatia A. S. & Avasthi G. 2003. Incidence and prevalence of ulcerative colitis in Punjab, North India. *Gut* 52:1587-1590.
- Spalinger, J., Patriquin H., Miron M. C., Marx G., Herzog D., Dubois J., Dubinsky M. & Seidman E. G. 2000. Doppler US in patients with crohn disease: vessel density in the diseased bowel reflects disease activity. *Radiology* 217:787-791.
- Vind, I., Riis L., Jess T., Knudsen E., Pedersen N., Elkjaer M., Bak Andersen I., Wewer V., Norregaard P., Moesgaard F., Bendtsen F. & Munkholm P. 2006. Increasing incidences of inflammatory bowel disease and decreasing surgery rates in Copenhagen City and County, 2003-2005: a population-based study from the Danish Crohn colitis database. *Am J Gastroenterol* 101:1274-1282.
- Wang, B., Saha P. K., Udupa J. K., Ferrante M. A., Baumgardner J., Roberts D. A. & Rizi R. R. 2004. 3D airway segmentation via hyperpolarized ³He gas MRI by using scale-based fuzzy connectedness. *Comput Med Imaging Graph* 28:77-86.
- Wieczorek, A. P., Wozniak M. M., Stankiewicz A., Bogusiewicz M., Santoro G. A., Rechberger T. & Scholbach J. 2009. The assessment of normal female urethral vascularity with Color Doppler endovaginal ultrasonography: preliminary report. *Pelviperrineology* 28:59-61



Colonoscopy

Edited by Prof. Paul Miskovitz

ISBN 978-953-307-568-6

Hard cover, 326 pages

Publisher InTech

Published online 29, August, 2011

Published in print edition August, 2011

To publish a book on colonoscopy suitable for an international medical audience, drawing upon the expertise and talents of many outstanding world-wide clinicians, is a daunting task. New developments in videocolonoscopy instruments, procedural technique, patient selection and preparation, and moderate sedation and monitoring are being made and reported daily in both the medical and the lay press. Just as over the last several decades colonoscopy has largely supplanted the use of barium enema x-ray study of the colon, new developments in gastrointestinal imaging such as computerized tomographic colonography and video transmitted capsule study of the colonic lumen and new discoveries in cellular and molecular biology that may facilitate the early detection of colon cancer, colon polyps and other gastrointestinal pathology threaten to relegate the role of screening colonoscopy to the side lines of medical practice. This book draws on the talents of renowned physicians who convey a sense of the history, the present state-of-the art and ongoing confronting issues, and the predicted future of this discipline.

How to reference

In order to correctly reference this scholarly work, feel free to copy and paste the following:

Thomas Scholbach, Jörg Hofmann and Jakob Scholbach (2011). Intestinal Dynamic Color Doppler Sonographic Tissue Perfusion Measurement, Colonoscopy, Prof. Paul Miskovitz (Ed.), ISBN: 978-953-307-568-6, InTech, Available from: <http://www.intechopen.com/books/colonoscopy/intestinal-dynamic-color-doppler-sonographic-tissue-perfusion-measurement>

INTech
open science | open minds

InTech Europe

University Campus STeP Ri
Slavka Krautzeka 83/A
51000 Rijeka, Croatia
Phone: +385 (51) 770 447
Fax: +385 (51) 686 166
www.intechopen.com

InTech China

Unit 405, Office Block, Hotel Equatorial Shanghai
No.65, Yan An Road (West), Shanghai, 200040, China
中国上海市延安西路65号上海国际贵都大饭店办公楼405单元
Phone: +86-21-62489820
Fax: +86-21-62489821

© 2011 The Author(s). Licensee IntechOpen. This chapter is distributed under the terms of the [Creative Commons Attribution-NonCommercial-ShareAlike-3.0 License](https://creativecommons.org/licenses/by-nc-sa/3.0/), which permits use, distribution and reproduction for non-commercial purposes, provided the original is properly cited and derivative works building on this content are distributed under the same license.

IntechOpen

IntechOpen