

We are IntechOpen, the world's leading publisher of Open Access books Built by scientists, for scientists

6,900

Open access books available

186,000

International authors and editors

200M

Downloads

Our authors are among the

154

Countries delivered to

TOP 1%

most cited scientists

12.2%

Contributors from top 500 universities



WEB OF SCIENCE™

Selection of our books indexed in the Book Citation Index
in Web of Science™ Core Collection (BKCI)

Interested in publishing with us?
Contact book.department@intechopen.com

Numbers displayed above are based on latest data collected.
For more information visit www.intechopen.com



Endoscopic Submucosal Dissection for Colorectal Lesions

Takashi Shida

Department of Surgery,

Funabashi Central Social

*Insurance Hospital, Funabashi, Chiba,
Japan*

1. Introduction

Recently in Japan, Endoscopic submucosal dissection (ESD) is beginning to become widely performed for the treatment of colorectal lesions. However, ESD is a very difficult technique which may lead to perforation of the colonic wall and also time consuming compared to Endoscopic mucosal resection (EMR). In this article, I would like to introduce the indications and the practical procedure of colorectal ESD.

Since Endoscopic mucosal resection (EMR) is widely and safely performed throughout the world, the indications for colorectal ESD are as follows: 1) lesions which are difficult to remove en block with a snare EMR due to size, such as those in the LST-NG category, lesions exhibiting V_I pit patterns, shallow submucosal invasive carcinoma, large depressed type tumors and large protruded type lesions suspected to be carcinoma. 2) lesions with fibrosis due to biopsy or peristalsis. 3) sporadic localized lesions in chronic inflammation, such as ulcerative colitis. 4) local residual carcinoma after EMR. This indication was proposed by Tanaka S et al and is widely applied in Japan.¹⁾ Since, most early colorectal lesions can be treated by EMR or Endoscopic piecemeal mucosal resection (EPMR), indications for ESD is relatively limited. The most beneficial point of ESD is the accuracy of en block resection of the lesion without regard to the specimen size.

Needle knife, IT (Insulated Tipped) knife, Hook knife, Flex knife and Dual knife are representative knives for ESD.¹⁾ For colorectal ESD, Flex knife, Dual knife and Hook knife are mainly used. Also transparent hood is essential for colorectal ESD. Glycerol or sodium hyaluronate solution is necessary for submucosal injection.²⁾ A good quality high-frequency power supplies like VIO300D, ICC200 (ERBE, Germany), or ESG-100 (Olympus, Japan) is also required. To decrease patient's discomfort, the Carbon dioxide insulation system (UCR system, Olympus, Japan) is useful. Carbon dioxide can be absorbed into the human tissue more than 100 times faster than room air. The use of this system can decrease the distention of the colon.³⁾

In order to perform colorectal ESD, the most important point is to place the lesion opposite toward the gravity. You have to change the patient's position to check this point before starting ESD. General anesthesia is not necessary because it becomes difficult to change the

patient's position during the ESD procedure. In Japan, colorectal ESD is mainly performed under conscious sedation.

After locating the lesion in the appropriate position, submucosal injection is performed. You have to inject enough amount of solution to elevate the lesion completely (Glycerol or sodium hyaluronate solution). ESD requires larger volume of submucosal injection compared to EMR. Usually, we dilute the sodium hyaluronate solution by glycerol 4 ~5 folds containing a small amount of indigo carmine and epinephrine hydrochloride. Indigo carmine is useful for a better visualization of the submucosal layer.

After submucosal injection, mucosal incision is performed. For mucosal incision, Flex knife or Dual knife is used. It is important to fix the knife gently to the colonic wall and not to press it strongly. Colonic wall is very thin, and there is no need to press the knife strongly towards the wall. When using the Flex knife, appropriate length of the knife may be about 2mm or less. If the lesion is larger than 40mm, it is important not to complete the circular mucosal incision before the submucosal dissection. This is because the submucosal solution leaks out from the mucosal incision space, and the observation of the submucosal space becomes poor. For submucosal dissection, the important point is to slide into the submucosal space by using the transparent hood as soon as possible. Flex knife or Dual knife is mainly used, but in difficult situation, Hook knife is useful. Hook knife is safe because it allows submucosal dissection by hooking and pulling the tissue towards the luminal side.⁴⁾ During this procedure, vessels are usually seen and sometimes it requires hemostasis. Since the colonic wall is extremely thin, a special hemostatic forceps with a small cup is used (50~60W, soft coagulation). To prevent delayed perforation, excess coagulation must be avoided. Post ESD bleeding is a rare event in colorectal ESD, so there is no need for excess coagulation.

Figure 1 shows a case treated by ESD. This is a granular-type laterally spreading tumor (LST-G) with a scar, 35mm in diameter in the sigmoid colon. As shown in **figure1**, you can see that the lesion is positive for non-lifting sign. It is impossible to perform en-block resection by conventional EMR method in a case like this. The lesion had severe fibrosis in the center but it was successfully removed by ESD. The procedure time was 70 minutes.

The most hazardous and dangerous complication in colorectal ESD is the perforation of the bowel wall. This must be managed with extreme caution because it will easily lead to peritonitis and may sometimes be life threatening. When the perforation is admitted during the ESD procedure, the perforation site must be closed by an endoscopic clip immediately.⁵⁾ To continue the ESD procedure or not depends on the condition of the patient. In my opinion, you should stop the ESD and manage the lesion later (ie; laparoscopic operation). Leading the patient to a life threatening situation should be avoided as much as possible. The most important point is that colorectal ESD is a very difficult technique and is still a clinical research procedure. Colorectal ESD should be performed only by a well experienced colonoscopist.

Colorectal ESD is now beginning to be performed in many hospitals in Japan, but is still at a clinical research level. More devices and safe procedures are warranted for the establishment of standard safe colorectal ESD. I hope that all colorectal lesions will be properly treated by a treatment method appropriately selected from among EMR, ESD and surgical resection (including laparoscopic operation) after precise preoperative diagnosis.

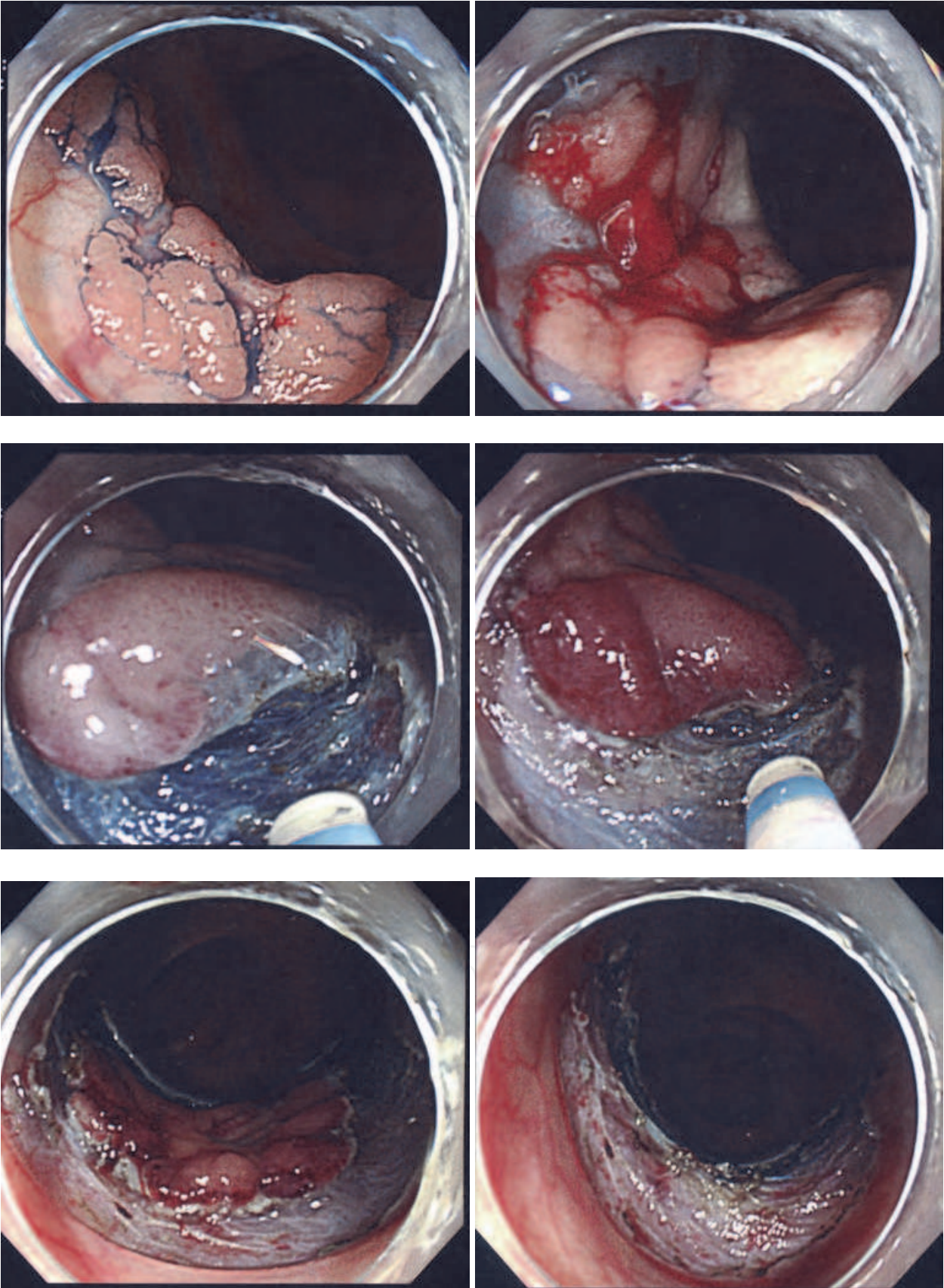



Fig. 1.

2. Reference

- [1] Tanaka S, Oka S, Chayama K: Colorectal endoscopic submucosal dissection: present status and future perspective, including its differentiation from endoscopic mucosal resection. *J Gastroenterol* 2008;43:641-651
- [2] Fujishiro M, Yahagi N, Nakamura M, et al. Successful outcomes of a novel endoscopic treatment for GI tumors: endoscopic submucosal dissection with a mixture of high-molecular-weight hyaluronic acid, glycerin, and sugar. *Gastrointest Endosc* 2006;63:243-249
- [3] Saito Y, Uraoka T, Matsuda T, et al. A pilot study to assess the safety and efficacy of carbon dioxide insufflation during colorectal endoscopic submucosal dissection with the patient under conscious sedation. *Gastrointest Endosc* 2007;65:537-542
- [4] Tamegai Y, Saito Y, Masaki N, et al. Endoscopic submucosal dissection: a safe technique for colorectal tumors. *Endoscopy* 2007;39:418-422
- [5] Tanaka S, Oka S, Kaneko I, et al. Endoscopic submucosal dissection for colorectal neoplasia: possibility of standardization. *Gastrointest Endosc* 2007;66:100-107

IntechOpen



Colonoscopy

Edited by Prof. Paul Miskovitz

ISBN 978-953-307-568-6

Hard cover, 326 pages

Publisher InTech

Published online 29, August, 2011

Published in print edition August, 2011

To publish a book on colonoscopy suitable for an international medical audience, drawing upon the expertise and talents of many outstanding world-wide clinicians, is a daunting task. New developments in videocolonoscopy instruments, procedural technique, patient selection and preparation, and moderate sedation and monitoring are being made and reported daily in both the medical and the lay press. Just as over the last several decades colonoscopy has largely supplanted the use of barium enema x-ray study of the colon, new developments in gastrointestinal imaging such as computerized tomographic colonography and video transmitted capsule study of the colonic lumen and new discoveries in cellular and molecular biology that may facilitate the early detection of colon cancer, colon polyps and other gastrointestinal pathology threaten to relegate the role of screening colonoscopy to the side lines of medical practice. This book draws on the talents of renowned physicians who convey a sense of the history, the present state-of-the art and ongoing confronting issues, and the predicted future of this discipline.

How to reference

In order to correctly reference this scholarly work, feel free to copy and paste the following:

Takashi Shida (2011). Endoscopic Submucosal Dissection for Colorectal Lesions, Colonoscopy, Prof. Paul Miskovitz (Ed.), ISBN: 978-953-307-568-6, InTech, Available from:

<http://www.intechopen.com/books/colonoscopy/endoscopic-submucosal-dissection-for-colorectal-lesions>

INTECH
open science | open minds

InTech Europe

University Campus STeP Ri
Slavka Krautzeka 83/A
51000 Rijeka, Croatia
Phone: +385 (51) 770 447
Fax: +385 (51) 686 166
www.intechopen.com

InTech China

Unit 405, Office Block, Hotel Equatorial Shanghai
No.65, Yan An Road (West), Shanghai, 200040, China
中国上海市延安西路65号上海国际贵都大饭店办公楼405单元
Phone: +86-21-62489820
Fax: +86-21-62489821

© 2011 The Author(s). Licensee IntechOpen. This chapter is distributed under the terms of the [Creative Commons Attribution-NonCommercial-ShareAlike-3.0 License](https://creativecommons.org/licenses/by-nc-sa/3.0/), which permits use, distribution and reproduction for non-commercial purposes, provided the original is properly cited and derivative works building on this content are distributed under the same license.

IntechOpen

IntechOpen