

# We are IntechOpen, the world's leading publisher of Open Access books Built by scientists, for scientists

6,900

Open access books available

186,000

International authors and editors

200M

Downloads

Our authors are among the

154

Countries delivered to

TOP 1%

most cited scientists

12.2%

Contributors from top 500 universities



WEB OF SCIENCE™

Selection of our books indexed in the Book Citation Index  
in Web of Science™ Core Collection (BKCI)

Interested in publishing with us?  
Contact [book.department@intechopen.com](mailto:book.department@intechopen.com)

Numbers displayed above are based on latest data collected.  
For more information visit [www.intechopen.com](http://www.intechopen.com)



# Endoscopic Manifestations and Mucosal Patterns Associated to Collagenous Colitis

Daniel Gustavo Cimmimo and José Manuel Mella

*Endoscopy Unit and Gastroenterology Unit, Hospital Alemán, Buenos Aires, Argentina*

## 1. Introduction

Microscopic colitis (MC) are clinical pathologic entities characterized by secretory-like aqueous chronic diarrhea, in its large majority without hematochezia. From the first descriptions of MC<sup>1</sup>, normal endoscopic and radiological findings have been a pathognomonic feature. It is thought that up to 20% of adults with chronic diarrhea who have an endoscopically normal colonoscopy may have MC.

Most common MC are collagenous colitis and lymphocytic colitis. They are two morphologically distinct entities of MC. They are similar in presentation but differ histologically. Endoscopic biopsy is required for the diagnosis of MC<sup>2</sup>. As there are usually no mucosal abnormalities, the biopsies taken must be random. However, several authors have described different mucosal abnormalities related to the MC, most of them related to collagenous colitis.

Our aims were to review the medical literature and to describe the mucosal patterns and mucosal abnormalities that have been associated with the microscopic colitis, especially those related to the collagenous colitis.

### 1.1 Search

A MEDLINE search (1966-December 2010), was done using the terms "Colitis, Microscopic"[Mesh] or "Colitis, Collagenous"[Mesh] or "Colitis, Lymphocytic"[Mesh] and "Endoscopy, Digestive System"[Mesh] or "Endoscopy, Gastrointestinal"[Mesh] or "Colonoscopy"[Mesh] to find relevant articles. The search was carried out without restrictions or limits. The selection process of the articles was done independently by both authors. Agreement was measured using kappa coefficient (k). First, relevant studies were selected by the title (k 0.80, CI95% 0.63-0.97) and differences were resolved by consensus. Then, the fulltexts of selected articles were read.

## 2. Role of endoscopy in microscopic colitis

Endoscopy is essential for the diagnosis of microscopic colitis<sup>2</sup>. The diagnosis of microscopic colitis is based on mucosal biopsies taken during colonoscopy at the appropriate sites. It is essential to take colonic biopsies when endoscopic examinations are carried out in the clinical context of chronic diarrhea, even if the functional nature of the diarrhea is suspected.

By definition, the colonic mucosa has an endoscopically normal appearance in microscopic colitis. However, some authors have reported endoscopic abnormalities and mucosal patterns in patients with MC (see below).

2.1 Colorectal biopsy samples: where and how much?

Histological abnormalities in MC are generally pancolonic as they can be distributed throughout the colon as well as limited to the right colon<sup>3</sup>. In collagenous colitis, thickening of the subepitelial collagen band is in some cases more marked in the proximal colon than in the distal colon. The two endoscopically normal sites in which biopsies should be taken for optimal diagnosis of MC are the ascending colon and the sigmoid colon. Three to four biopsies should be taken per site.

3. Mucosal patterns and mucosal lesions associated to microscopic colitis

In the colonoscopy, the colonic mucosa has usually a normal aspect or it can present minimum and unspecific abnormalities such as erythema patches, edema or alterations in the vascular pattern.

In our search, we found several case reports and case series of endoscopic findings that would suggest the presence of this type of colitis, most of the findings related to collagenous colitis. In Table 1 there is a summary of the different endoscopic manifestations of the collagenous colitis and the authors of these findings.

Author	Colorectal findings in collagenous colitis
Richieri <i>et al</i> <sup>4</sup> (1993)	mucosal tears
Katsinelos <i>et al</i> <sup>16</sup> (1997)	multiple red spots
Sato <i>et al</i> <sup>17</sup> (1998)	spindle network pattern
Cruz–Correa <i>et al</i> <sup>5</sup> (2002)	mucosal tears
Buchman <i>et al</i> <sup>18</sup> (2004)	pseudomembranous collagenous colitis
Koulaouzidis <i>et al</i> <sup>6</sup> (2006)	mucosal tears and scars
Tysk <i>et al</i> <sup>7</sup> (2006)	mucosal tears, longitudinal mucosal lacerations
Smith <i>et al</i> <sup>13</sup> (2007)	mucosal tears on insufflation, colonic perforation
Allende <i>et al</i> <sup>14</sup> (2008)	bleeding linear ulcers, colonic perforations
Hashimoto <i>et al</i> <sup>8</sup> (2008)	linear ulcers, scar-like areas; crowded vascularity of the colonic mucosa and dilated, circling or winding blood capillaries
Dunzendorfer <i>et al</i> <sup>21</sup> (2008)	mucosal tears
Umeno <i>et al</i> <sup>10</sup> (2008)	linear mucosal defects
Couto <i>et al</i> <sup>9</sup> (2009)	scars; mucosal tears, superficial lacerations or “cat scratches” enhanced with air insufflation during colonoscopy
Hashimoto <i>et al</i> <sup>19</sup> (2009)	mucosa similar to ischemic colitis
Cimmino <i>et al</i> <sup>20</sup> (2010)	colorectal mosaic pattern
Nomura <i>et al</i> <sup>11</sup> (2010)	linear mucosal defects

Table 1. Summary of the mucosal abnormalities associated with collagenous colitis.

### 3.1 Mucosal tears

Mucosal tears were the most frequent endoscopic findings in our search. The terms “linear mucosal defects” have been used by several authors to describe mucosal tears and sharp longitudinal ulcers (characteristic colonoscopic findings in patients with collagenous colitis). One of the first descriptions of mucosal tears that we found data were from 1993 (Richieri *et al.*<sup>4</sup>) and 2002 (Cruz-Correa *et al.*<sup>5</sup>).

In 2006, Koulaouzidis *et al.*<sup>6</sup> described discrete linear mucosal breaks in the caecum after gentle insufflation, suggesting that this mucosal tears in the colon could occur spontaneously in patients with collagenous colitis.

In the same year, Curl Tysk *et al.*<sup>7</sup> reviewed the medical literature and reported longitudinal mucosal lacerations in the colon of patients with collagenous colitis (Figure 1 and 2), emphasizing that these lesions may be a sign of underlying collagenous colitis, and that mucosal biopsies should be obtained to confirm the diagnosis. Based on the previous reports that they had found, they advised that these lesions might be associated with an increased risk of colonic perforation, and that the colonoscopist should be aware that the risk of perforation is likely to be increased.

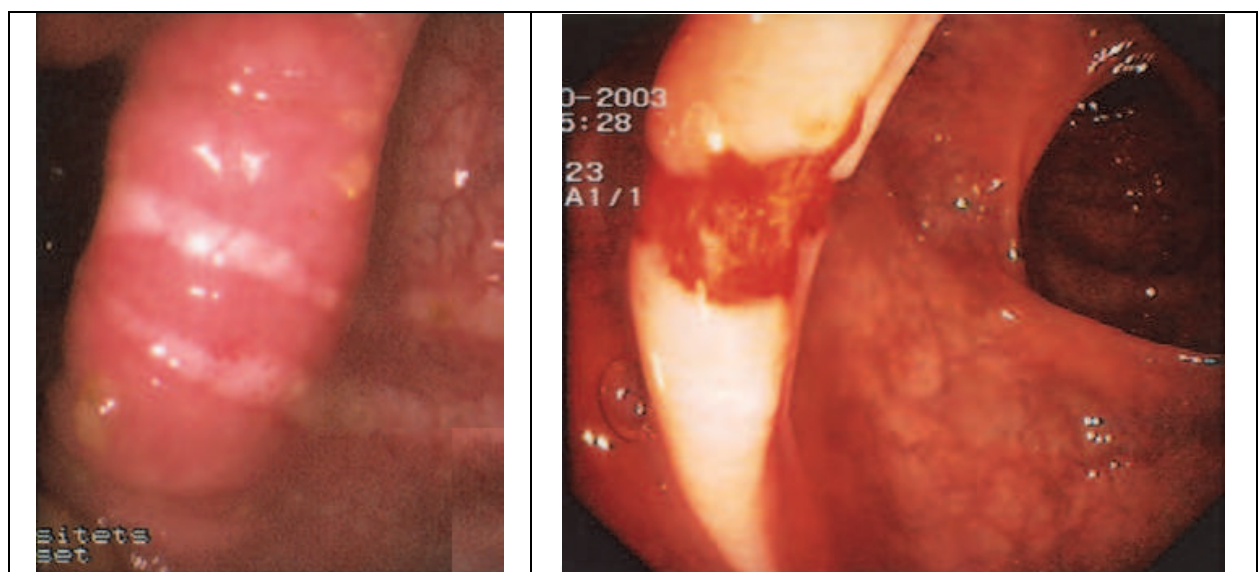


Fig. 1. Mucosal tears in patients with collagenous colitis (Courtesy of Dr Curt Tysk<sup>7</sup>)

In 2008, Hashimoto *et al.*<sup>8</sup> described a surprising finding in a patient with chronic diarrhea: a 20 cm long linear ulcer or scar like area of mucosal damage without bleeding in the descending colon. The biopsies taken revealed that it was a collagenous colitis.

In 2009, Couto *et al.*<sup>9</sup> suggested that the scars found in the colonic mucosa were signs of scarring of previous spontaneous mucosal tears, superficial lacerations or “cat scratches” enhanced with air insufflation during colonoscopy in patients with collagenous colitis.

#### 3.1.1 Drugs associated with mucosal tears

Umeno *et al.*<sup>10</sup> and Nomura *et al.*<sup>11</sup> have associated the presence of these linear mucosal defects to the drug lansoprazole, a proton pump inhibitor. They found that linear mucosal defects and friable mucosa may be characteristic colonoscopic findings in cases of lansoprazole-associated collagenous colitis (Figure 2).

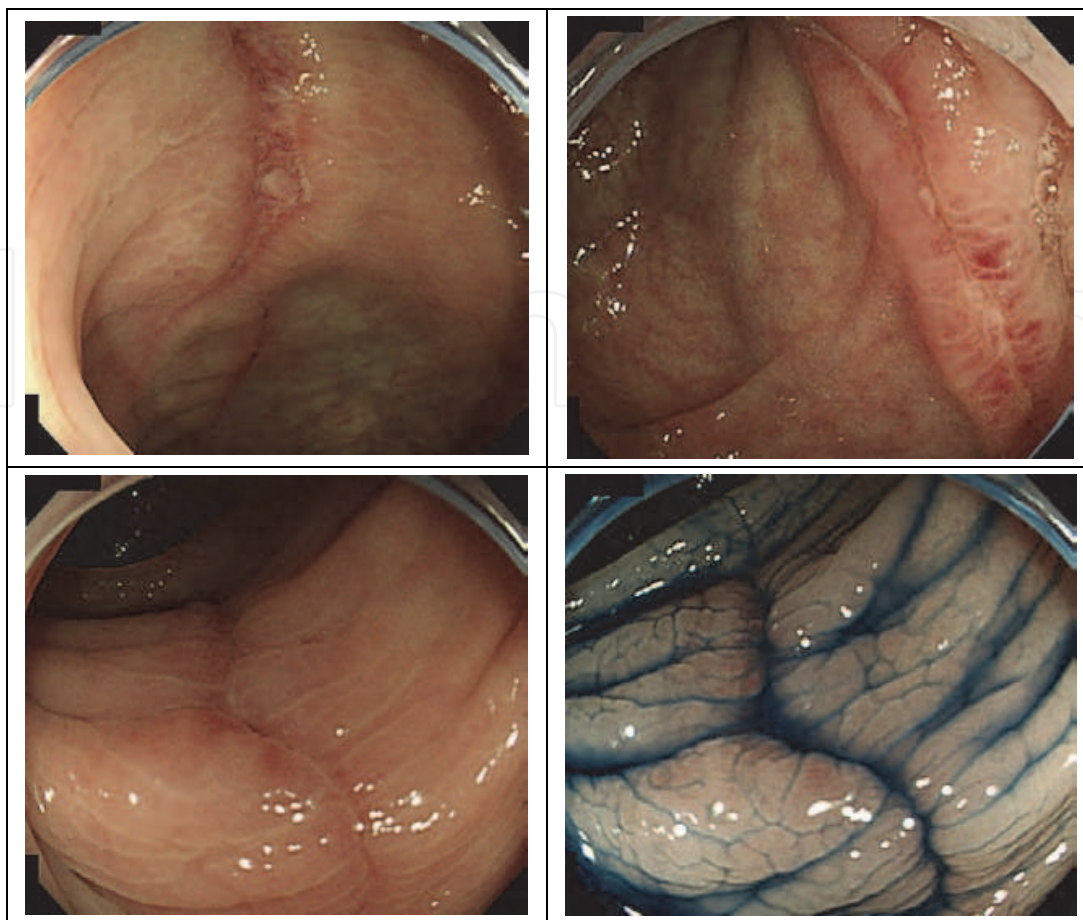


Fig. 2. Mucosal tears in patients with lansoprazole associated-collagenous colitis (Courtesy of Dr Eiki Nomura<sup>11</sup>)

### 3.1.2 Risk of colonic perforation in patients with collagenous colitis

Several authors have suggested that patients with collagenous colitis have an increased risk of colonic perforation during the colonoscopy procedure. Most of them agree that the mucosal tears might be the initial lesion of the perforations.

Sherman *et al*<sup>12</sup> and Smith *et al*<sup>13</sup> found mucosal tears (linear “fractures” of the colon) following diagnostic colonoscopies in patients with severe collagenous colitis. They theorized that the stiffness of the colon in areas of collagenous colitis with submucosal fibrosis could make it susceptible to linear “fractures” during colonoscopic air insufflation with subsequent transmural air dissection. They urged extreme caution if these lesions were recognized at colonoscopy and recommended aborting the examination and obtaining plain radiographs to detect free intraperitoneal air.

Allende *et al*<sup>14</sup> published the largest series up to date about 12 patients with collagenous colitis complicated with colonic perforations. In their series the most outstanding colonoscopic findings were bleeding linear ulcers. They observed that the colon in collagenous colitis perforates not only with colonoscopy, but also with barium enema. Colonoscopic perforations were more common than barium enema, probably due to its higher intraluminal pressures. They thought that marked collagenous colitis severity was implicated as a risk factor for perforation. They found that the right colon was the most



common perforation site, corresponding to its preferential involvement by collagenous colitis and predisposing physical properties of the right colonic wall.

In 2010, Hussain *et al*<sup>15</sup> published a systematic review about the colonic perforations in patients with collagenous colitis. They did an exhaustive and systematic search and found 21 case reports of colonic perforation, mainly following colonoscopy. The site of colonic perforations and mucosal tears were predominantly in the right colon.

### 3.2 Other mucosal abnormalities

In 1997, Katsinelos *et al*<sup>16</sup> reported the presence of multiple red spots in the lower part of the ascending colon in a patient with chronic diarrhea. The histological examinations of the biopsies taken from this pathological area showed it was a collagenous colitis.

In 1998, Sato *et al*<sup>17</sup> reported a spindle network pattern after indigo carmine dye-spraying, in association with collagenous colitis.

In 2004, Alan Lewis Buchman *et al*<sup>18</sup> described an interesting endoscopic manifestation of collagenous colitis in two patients with chronic diarrhea: pseudomembrane formations (Figure 3) in the absence of *Clostridium difficile* infection. They used the term of “pseudomembranous collagenous colitis”.

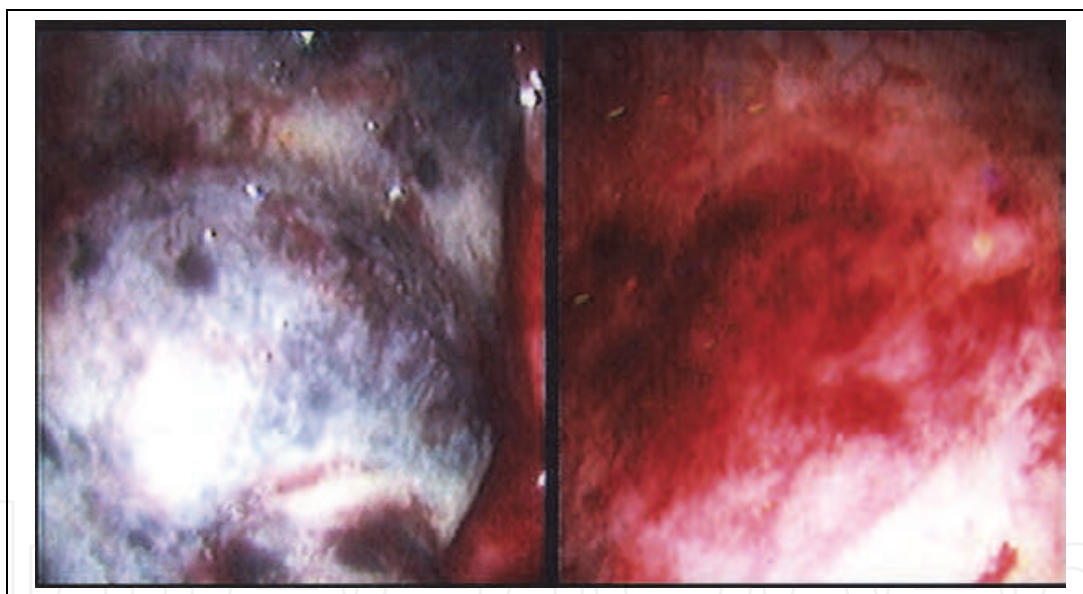


Fig. 3. Pseudomembranes in a patient with collagenous colitis (Courtesy of Dr Alan Buchman<sup>18</sup>)

In 2008, Hashimoto *et al*<sup>8</sup> reported numerous crowded, small, dilated, circling or winding blood vessels on the mucosal surface of the entire colon, especially the transverse colon (appearing like a spider web) in association with this type of colitis.

In 2009, Hashimoto *et al*<sup>19</sup> found an actively hemorrhagic linear ulcer and a linear ulcer scar in a woman with abrupt onset of lower abdominal pain and heavy blood in her stool. Histopathological examination of biopsy samples taken showed subepithelial collagen bands and the diagnosis of collagenous colitis was made. They thought it was a case of lansoprazole-associated collagenous colitis with a unique presentation similar to an ischemic colitis.

In 2010, Cimmino *et al*<sup>20</sup> described a mosaic pattern as an endoscopic finding in the collagenous colitis (Figure 4). They compared the presence of this mosaic pattern in patients with chronic diarrhea, and they found that the presence of this colorectal mosaic pattern would have a high specificity (99%) and a high positive likelihood ratio (LR+ 17) for the diagnosis of collagenous colitis in patients with chronic diarrhea who undergo a colonoscopy.

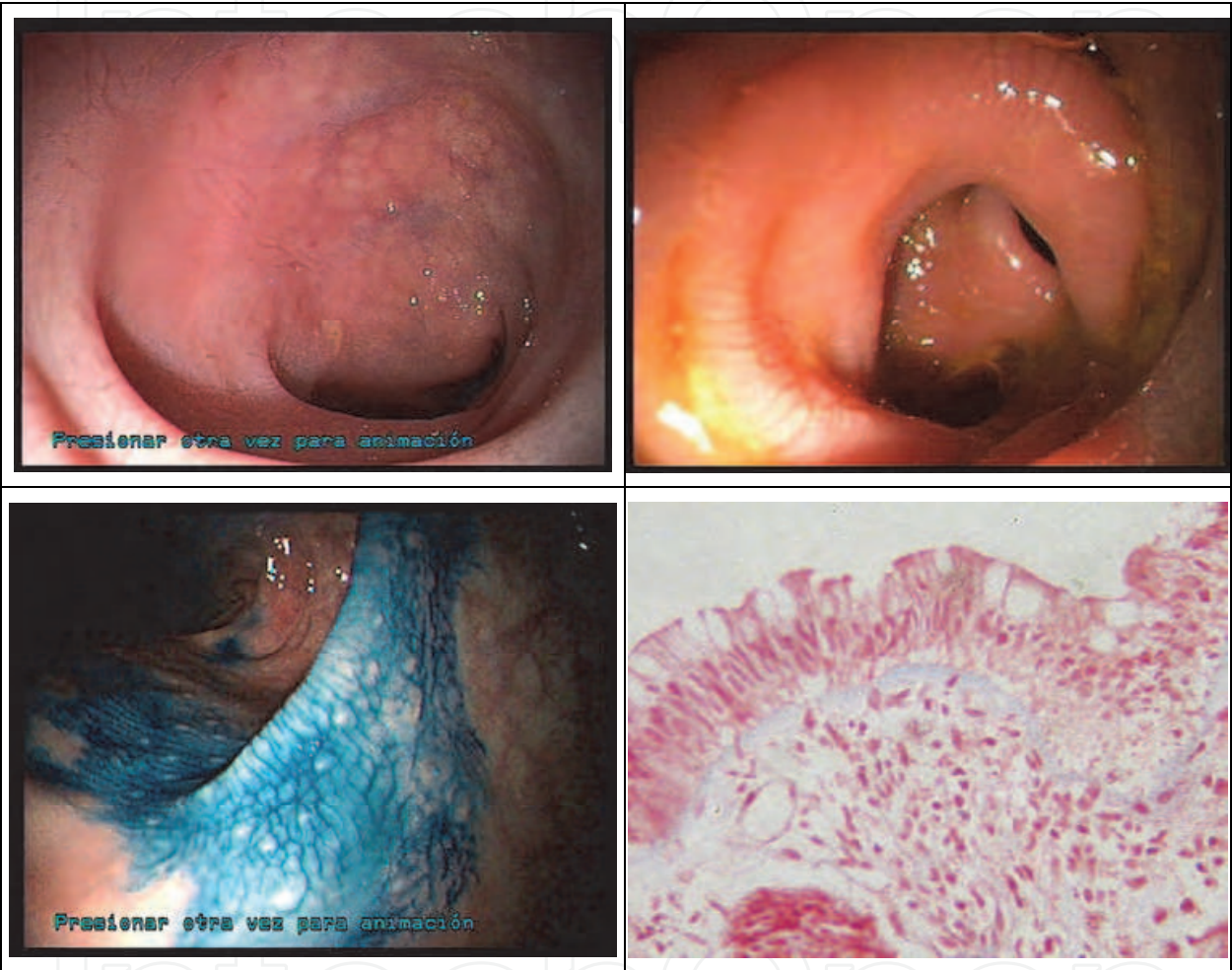


Fig. 4. Colorectal mosaic pattern in patients with collagenous colitis (Courtesy of Dr Cimmino<sup>20</sup>)

4. The future of endoscopy in microscopic colitis

Endomicroscopy is a newly developed endoscopic modality, which allows in vivo microscopy of the mucosal layer in about 1000-times magnification with subcellular resolution during ongoing gastrointestinal endoscopy. This technique enables subsurface imaging of living tissue during ongoing endoscopy and allows confocal microscopy in addition to standard video endoscopy. Kiesslich *et al*<sup>22</sup> showed that endomicroscopy allows localization and measurement of the amount of collagenous bands in the mucosal layer, offering the possibility of targeted biopsies, which would be a new approach in collagenous colitis.

## 5. Summary

The term microscopic colitis includes the collagenous colitis and the lymphocytic colitis, both entities are characterized by chronic diarrhea and normal colonoscopy, and the diagnosis is confirmed by biopsies taken at random. In recent years, abnormalities in the mucosa, mainly related with collagenous colitis, have been described. In Table 1 we summarize the mucosal patterns and the endoscopic manifestations which have been associated with collagenous colitis. Most of the reports mentioned the mucosal tears as the most frequent abnormality. Scars following mucosal lacerations were also a frequent finding. The risk of colonic perforations seems to be slightly higher in patients with collagenous colitis during colonoscopy. The main reason appears to be the lacerations done during air insufflations in the procedure. Other endoscopic findings were blood vessels alterations, pseudomembranes and mosaic pattern.

## 6. Conclusion

Several mucosal patterns and mucosal abnormalities have been reported in association with collagenous colitis. Knowledge of these endoscopic manifestations of the collagenous colitis could help to a better understanding of this disease and to target the colonic biopsies.

## 7. Acknowledgment


We want to thank Dr. Curl Tysk, Dr. Eiki Nomura and Dr. Alan Lewis Buchman for providing us the pictures and photos of their endoscopic findings. They have been very kind.

## 8. References

- [1] Lindstrom CG. "Collagenous colitis" with watery diarrhoea – a new entity? *Pathol Eur* 1976;11:87.
- [2] Beaugier L, Napoleon B, Ponchon T, Boyer J, Canard JM, Dalbies P, Escourrou J, Greff M, Lapuelle J, Letard JC, Marchetti B, Palazzo L, Rey JF, Sautereau D; Société Française d'Endoscopie Digestive. Guidelines of the French Society for Digestive Endoscopy (SFED). Role of endoscopy in microscopic colitis. *Endoscopy*. 2005 Jan;37(1):97-8.
- [3] Thijs WJ, van Baarlen J, Kleibeuker JH, Kolkman JJ. Microscopic colitis: prevalence and distribution throughout the colon in patients with chronic diarrhoea. *Neth J Med*. 2005 Apr;63(4):137-40.
- [4] Richieri JP, Bonneau HP, Cano N, Di Costanzo J, Martin J. Collagenous colitis: an unusual endoscopic appearance. *Gastrointest Endosc* 1993; 39:192-4.
- [5] Cruz-Correa M, Milligan F, Giardiello FM. Collagenous colitis with mucosal tear on endoscopic insufflation: a unique presentation. *Gut* 2002;51:600-600
- [6] Koulaouzidis A, Henry JA, Saeed AA. Mucosal tears can occur spontaneously in collagenous colitis. *Endoscopy* 2006; 38:549.
- [7] Wickbom A, Lindqvist M, Bohr J, Ung KA, Bergman J, Eriksson S, Tysk C. Colonic mucosal tears in collagenous colitis. *Scand J Gastroenterol* 2006; Jun;41(6): 726-9.



- [8] Hashimoto Y, Endo Y, Kuroki Y, Yoshikumi H, Yoshiba M. Collagenous colitis with unique colonoscopic findings. *Endoscopy*. 2008 Sep;40 Suppl 2:E162.
- [9] Couto G, Bispo M, Barreiro P, Monteiro L, Matos L. Unique endoscopy findings in collagenous colitis. *Gastrointest Endosc*. 2009 May;69(6):1186-8.
- [10] Umeno J, Matsumoto T, Nakamura S, Jo Y, Yada S, Hirakawa K, Yoshimura R, Yamagata H, Kudo T, Hirano A, Gushima M, Yao T, Nakashima Y, Iida M. Linear mucosal defect may be characteristic of lansoprazole-associated collagenous colitis. *Gastrointest Endosc*. 2008 Jun;67(7):1185-91.
- [11] Nomura E, Kagaya H, Uchimi K, Noguchi T, Suzuki S, Suzuki M, Onodera H, Tateno H. Linear mucosal defects: a characteristic endoscopic finding of lansoprazole-associated collagenous colitis. *Endoscopy*. 2010;42 Suppl 2:E9-10.
- [12] Sherman A, Ackert JJ, Rajapaksa R, et al. Fractured colon: an endoscopically distinctive lesion associated with colonic perforation following colonoscopy in patients with collagenous colitis. *J Clin Gastroenterol* 2004; 38:341-345.
- [13] Smith RR, Ragput A. Mucosal tears on endoscopic insufflation resulting in perforation: an interesting presentation of collagenous colitis. *J Am Coll Surg*. 2007 Nov;205(5):725.
- [14] Allende DS, Taylor SL, Bronner MP. Colonic perforation as a complication of collagenous colitis in a series of 12 patients. *Am J Gastroenterol*. 2008 Oct;103(10):2598-604.
- [15] Hussain Z, Kelly S, Clarke A, Adams S, Miller G. Colonic perforation in collagenous colitis: a systematic review of a rare complication and guidance on management. *Surg Endosc*. 2010 Dec;24(12):2930-4.
- [16] Katsinelos P, Katsos I, Patsiaoura K, Xiarchos P, Goulis I, Eugenidis N. A new endoscopic appearance of collagenous colitis. *Endoscopy* 1997;Feb;29(2):135.
- [17] Sato S, Benoni C, Tóth E, Veress B, Fork FT. Chromoendoscopic appearance of collagenous colitis--a case report using indigo carmine. *Endoscopy* 1998;Sep;30(7):S80-1.
- [18] Buchman AL, Rao S. Pseudomembranous collagenous colitis. *Dig Dis Sci*. 2004 Nov-Dec;49(11-12):1763-7.
- [19] Yusuke H, Jun T, Naotaka M, Yuichi T, Yutaka E, Kazuaki I. Lansoprazole-associated collagenous colitis: unique presentation, similar to ischemic colitis. *Endoscopy*. 2009;41 Suppl 2:E281-2.
- [20] Daniel G. Cimmino, José M. Mella, Lisandro Pereyra, Pablo A.E. Luna, Gabriel Casas, Ignacio Caldo, Federico Popoff, Silvia Pedreira, Luis A. Boerr. "A colorectal mosaic pattern might be an endoscopic feature of collagenous colitis". *Journal of Crohn's and Colitis* 2010, 4:139-143
- [21] Dunzendorfer T, Wilkins S, Johnson R. Mucosal tear in collagenous colitis. *Clin Gastroenterol Hepatol*. 2009 Sep; 7(9):e57.
- [22] Kiesslich R, Hoffman A, Goetz M, Biesterfeld S, Vieth M, Galle PR, Neurath MF. In vivo diagnosis of collagenous colitis by confocal endomicroscopy. *Gut*. 2006 Apr;55(4): 591-2.



## **Colonoscopy**

Edited by Prof. Paul Miskovitz

ISBN 978-953-307-568-6

Hard cover, 326 pages

**Publisher** InTech

**Published online** 29, August, 2011

**Published in print edition** August, 2011

To publish a book on colonoscopy suitable for an international medical audience, drawing upon the expertise and talents of many outstanding world-wide clinicians, is a daunting task. New developments in videocolonoscopy instruments, procedural technique, patient selection and preparation, and moderate sedation and monitoring are being made and reported daily in both the medical and the lay press. Just as over the last several decades colonoscopy has largely supplanted the use of barium enema x-ray study of the colon, new developments in gastrointestinal imaging such as computerized tomographic colonography and video transmitted capsule study of the colonic lumen and new discoveries in cellular and molecular biology that may facilitate the early detection of colon cancer, colon polyps and other gastrointestinal pathology threaten to relegate the role of screening colonoscopy to the side lines of medical practice. This book draws on the talents of renowned physicians who convey a sense of the history, the present state-of-the art and ongoing confronting issues, and the predicted future of this discipline.

### **How to reference**

In order to correctly reference this scholarly work, feel free to copy and paste the following:

Daniel Gustavo Cimmino and José Manuel Mella (2011). Endoscopic Manifestations and Mucosal Patterns Associated to Collagenous Colitis, Colonoscopy, Prof. Paul Miskovitz (Ed.), ISBN: 978-953-307-568-6, InTech, Available from: <http://www.intechopen.com/books/colonoscopy/endoscopic-manifestations-and-mucosal-patterns-associated-to-collagenous-colitis>

**INTECH**  
open science | open minds

### **InTech Europe**

University Campus STeP Ri  
Slavka Krautzeka 83/A  
51000 Rijeka, Croatia  
Phone: +385 (51) 770 447  
Fax: +385 (51) 686 166  
[www.intechopen.com](http://www.intechopen.com)

### **InTech China**

Unit 405, Office Block, Hotel Equatorial Shanghai  
No.65, Yan An Road (West), Shanghai, 200040, China  
中国上海市延安西路65号上海国际贵都大饭店办公楼405单元  
Phone: +86-21-62489820  
Fax: +86-21-62489821

© 2011 The Author(s). Licensee IntechOpen. This chapter is distributed under the terms of the [Creative Commons Attribution-NonCommercial-ShareAlike-3.0 License](https://creativecommons.org/licenses/by-nc-sa/3.0/), which permits use, distribution and reproduction for non-commercial purposes, provided the original is properly cited and derivative works building on this content are distributed under the same license.

IntechOpen

IntechOpen