

We are IntechOpen, the world's leading publisher of Open Access books Built by scientists, for scientists

6,900

Open access books available

185,000

International authors and editors

200M

Downloads

Our authors are among the

154

Countries delivered to

TOP 1%

most cited scientists

12.2%

Contributors from top 500 universities



WEB OF SCIENCE™

Selection of our books indexed in the Book Citation Index
in Web of Science™ Core Collection (BKCI)

Interested in publishing with us?
Contact book.department@intechopen.com

Numbers displayed above are based on latest data collected.
For more information visit www.intechopen.com



Transvaginal Natural Orifice Transluminal Endoscopic Surgery (Notes): Surgical Technique and Results

William Kondo et al.*

¹Hospital da Cruz Vermelha, Curitiba, Paraná,

²Centro Médico-Hospitalar Sugisawa, Curitiba, Paraná,

³University Hospital Teresopolis HCTCO-FESO, Rio de Janeiro,

⁴CHU Estaing, Clermont-Ferrand,

^{1,2,3}Brazil

⁴France

1. Introduction

In recent decades, surgical specialties have experienced numerous changes and developments, and minimally invasive surgical techniques have been adopted to reduce patient morbidity (Branco et al., 2008a). Laparoscopy has a well-established role in the modern era of surgery. Despite the difficulties in terms of learning curve early in the clinical implementation of this method, almost all surgical specialties have adopted the minimally invasive surgical approach as the gold standard. This results in less postoperative pain, shorter hospital stay, faster recovery and better aesthetic results (Jin et al., 2009; Keus et al., 2010; Kondo et al., 2006).

Recently, a new minimally invasive surgical approach has been increasingly described in the literature as NOTES (Natural Orifice Transluminal Endoscopic Surgery). This is an access to the abdominal cavity without any incisions in the abdominal wall (scarless surgery), and the natural orifices serve as the gateway to the peritoneal cavity. Thus, an endoscope is inserted into the abdominal cavity through the stomach, vagina, bladder or colon (de la Fuente et al., 2007). The first report of this surgical technique was described by Gettman et al. (2002), at The University of Texas in 2002, which demonstrated that transvaginal nephrectomy in an experimental animal model was feasible. Two years later, Kalloo et al. (2004) performed transgastric liver biopsies at the Johns Hopkins University. After these initial reports, several researchers have demonstrated the safety of the transgastric access to perform tubal ligation (Jagannath et al., 2005), cholecystectomy (Park et al., 2005), gastrojejunostomy (Kantsevov et al., 2005), subtotal hysterectomy with oophorectomy (Wagh et al, 2005; Wagh et al, 2006), splenectomy (Kantsevov et al., 2006), gastric bypass (Kantsevov et al., 2007), nephrectomy (Lima et al., 2007) and pancreatectomy (Matthes et al., 2007), all based on experimental studies in the porcine model.

Since 2007, reports of cholecystectomy (Branco Filho et al., 2007; Marescaux et al., 2007; Zorrón et al., 2007), nephrectomy (Branco et al., 2008b) and tubal ligation (Kondo et al., 2009)

*Anibal Wood Branco, Alcides José Branco Filho, Rafael William Noda, Monica Tessmann Zomer, Lorne Charles, Nicolas Bourdel and Ricardo Zorrón.

using transvaginal NOTES in humans appeared in the literature. In this chapter we will discuss Natural Orifice Transluminal Endoscopic Surgery with the vagina as the point of entry into the abdominal cavity.

2. Overview of the previous studies

2.1 Transvaginal endoscopic access in animal models

The transvaginal endoscopic approach has been tested in animal models in General Surgery, Urology and Gynecology.

2.1.1 General surgery

Several procedures in the field of General Surgery have been performed in animal models by transvaginal endoscopic approach. Cholecystectomy is the simplest procedure for training and it can be performed by the hybrid technique (transvaginal access associated with transabdominal laparoscopic punctures) (Bessler et al., 2008; Horváth et al., 2009) or by the purely vaginal approach (Sánchez-Margallo et al., 2009). The use of the hybrid technique facilitates the procedure and is recommended at the beginning of training in NOTES.

The repair of abdominal wall hernias using the endoscopic transvaginal approach has also been studied by some authors (Lomanto et al., 2009b; Powell et al., 2010). Lomanto et al. (2009b) performed 5 abdominal wall hernia repairs using a transvaginal approach. The procedures were performed using a double-channel endoscope under general endotracheal anesthesia. A mesh was placed and fixed to the abdominal wall using laparoscopic and endoscopic standard equipment. The animals survived for 2 weeks and were subsequently euthanized. At the autopsy all meshes were in place and mild adhesions were recorded in one animal with a small subcutaneous abscess. In a study by Powell et al. (2010), transvaginal placement of a large synthetic mesh to repair the hernia was feasible in seven porcine animal models with a mean operative time of 133 minutes. No gross contamination was seen at autopsy. However, five animals had positive mesh cultures; 7 had positive cultures from the rectouterine space in enrichment broth or by direct culture. They concluded that future studies need to be conducted to develop better techniques and determine the significance of mesh contamination.

Even more complex surgical procedures such as partial gastrectomy (Nakajima et al., 2008) and distal pancreatectomy (Allemann et al., 2009) have been successfully performed using the endoscopic transvaginal access in animal model.

Lomanto et al (2009a) assessed the safety of transluminal surgery by investigating the intraperitoneal bacterial load and contamination during transgastric and transvaginal surgeries. Twelve female pigs underwent transgastric ($n = 7$; tubal ligation and oophorectomy) and transvaginal procedures ($n = 5$; cholecystectomy), and all animals were sacrificed after 2 weeks. In the transgastric group, six animals completed the surgical procedures and survived. Three pigs demonstrated signs of postoperative adhesions and abscesses with peritonitis and *Escherichia coli* was isolated at autopsy. In the transvaginal group, cholecystectomy was performed without any technical problems in the animals. No signs of postoperative sepsis or bacterial growth were observed in the microbiologic samples. The authors concluded that the transvaginal approach seemed to be safer and produced less contamination and intra-abdominal sepsis, compared to the transgastric route.

2.1.2 Urology

The first report of transvaginal NOTES in Urology was in 2002 by Gettman et al. They performed six transvaginal laparoscopic nephrectomies in female pigs. In one renal unit, the laparoscopic nephrectomy was completed entirely by way of the vagina. In five renal units, a single, 5-mm transabdominal laparoscope was required to facilitate visualization. In one case an uncontrollable vascular injury occurred during placement of the Endo-GIA stapler, resulting in exsanguination. After this initial report, other authors published their experience on transvaginal NOTES nephrectomy with success (Aminsharifi et al., 2009; Clayman et al., 2007; Haber et al., 2009; Isariyawongse et al., 2008), using the hybrid or pure technique. Also, Raman et al. (2009) demonstrated that the use of magnetically anchored instrumentation can improve shortcomings of previously reported NOTES nephrectomies in that triangulation, instrument fidelity, and visualization are preserved while hilar ligation is performed using a conventional stapler without need for additional transabdominal trocars. The exploration of the retroperitoneum's via NOTES using transvaginal access in a porcine model was evaluated by Zacharopoulou et al (2009). An excellent view of the retroperitoneal space and structures, such as the vascular and lymphatic tissues, the kidney, the adrenal gland, and the ureter, was obtained.

2.1.3 Gynecology

Transvaginal endoscopic retroperitoneal lymphadenectomy in a pig model was first demonstrated by Nassif et al. (2009). They performed three pelvic lymphadenectomies and three retroperitoneal lymphadenectomies (inter-aortocaval, lateral-aortic and lateral caval) successfully. The group of Clermont-Ferrand (CHU Estaing) (Bourdel et al., 2009) also evaluated this access in the performance of retroperitoneal sentinel lymph node resection in 10 pigs. After injection of methylene blue in the paracervical region (Figures 1A and 1B), the endoscope was inserted through a colpotomy incision on the right side. The internal iliac vessels were visualized, followed by identification of the bilateral external iliac vessels, aorta and vena cava (Figures 1C to 1E). The blue stained sentinel nodes were dissected bluntly and removed (Figures 1F to 1I). The mean operative time was 56 minutes and the average number of lymph nodes removed per animal was 1.75. After transvaginal NOTES lymphadenectomy, a laparoscopic procedure was performed and the removal of 19 of 20 sentinel nodes was confirmed. No major complication occurred in 10 animals. Of the 19 sentinel nodes, 11 were located on the left side and 8 on the right side. Fifteen lymph nodes were obtained from the iliac vessels or the region of the promontory and four from the pre-aortic or lateral aortic regions.

2.2 Transvaginal endoscopic access in human cadavers

2.2.1 General surgery

Sugimoto et al. (2009) performed one case of transvaginal NOTES cholecystectomy in a human female cadaver. The surgical time was 87 minutes and there was no major complication. Some cases of transvaginal NOTES gastric bypass in human cadavers have been reported in the literature (Hagen et al., 2008; Madan et al., 2008). Nevertheless, several factors made this technique very challenging and time-consuming. A lack of proper instrumentation resulting in insufficient tissue traction, countertraction, and instrument manipulation complicated several steps during the procedure. A combination of flexible with rigid endoscopic techniques offers specific advantages for aspects of this type of surgery. Changes in instrument design are required to improve ergonomics in more complex endosurgical procedures (Hagen et al., 2008).

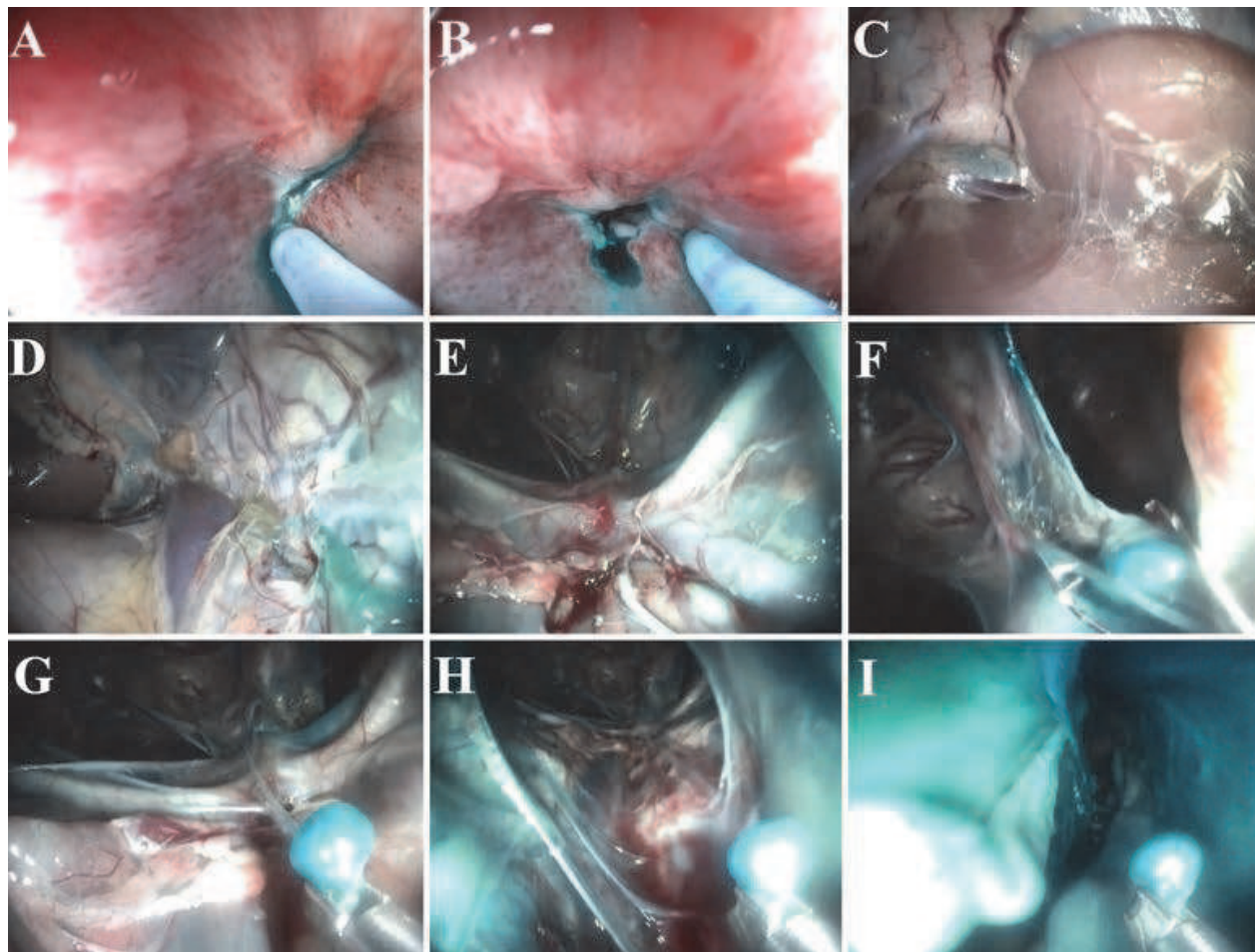


Fig. 1. Sentinel lymph node biopsy by retroperitoneal transvaginal NOTES in an animal model. (A and B) Injection of methylene blue in the paracervical region. (C) Visualization of the left kidney. (D) Identification of the right kidney and inferior vena cava. (E) Bifurcation of the iliac vessels. (F, G, H and I) Removal of the blue-stained sentinel lymph node in the region of the iliac vessels.

2.2.2 Urology

Allemann et al. (2010) described their experience with the pure transvaginal access for exploration of the retroperitoneum in cadavers to simulate the procedure of nephrectomy, adrenalectomy and pancreatectomy. The experiments were conducted in three fresh human cadavers, warmed at room temperature for 12 hours. The colpotomy was performed on the posterior wall of the vagina approximately 3 cm proximal to the posterior fornix. A posterior and left lateral tunnel was created under direct vision, using open surgical and laparoscopic instruments. Upon entry into the pararectal space, a 12mm dual channel endoscope was introduced and the carbon dioxide insufflation was achieved through one of the channels. The anatomic landmarks identified were the obturator nerve and artery entering the canal of Alcock, the sacral nerves, the median rectal artery, external iliac vessels, the inferior epigastric artery and the left lower pole of the kidney. The access was performed correctly up to the level of the iliac vessels in three cadavers. In the first case, the frozen tissue prevented the complete dissection up to the kidney. In the other two cadavers, the inferior pole of the kidney was clearly visualized. The mean surgical access time was 52 minutes.

Perretta et al. (2009b) confirmed the feasibility of the transvaginal retroperitoneal access for nephrectomy in two cadavers but a complete dissection of the kidney was not possible because of the rigor of the surrounding tissues. This access was also effectively reproduced in a cadaver model for adrenalectomy by the same authors (Perretta et al., 2009a).

Aron et al. (2009) tried a novel port called QuadPort (Advanced Surgical Concepts, Wicklow, Ireland) to perform transvaginal nephrectomy using standard and articulating laparoscopic instruments in four fresh female cadavers. One procedure was aborted due to dense pelvic adhesions from previous pelvic surgery. In the first 2 cadavers the assistance from an umbilical port was required to divide the attachments between the upper renal pole and the diaphragm. In the third case the dissection was completely performed by transvaginal means using a flexible gastroscope.

2.2.3 Gynecology

The gynecology group of Clermont-Ferrand (CHU Estaing) also performed the endoscopic approach for transvaginal retroperitoneal evaluation in cadavers, but the results were not published. The same surgical steps described above by Allemann et al. (2010) were performed in two cadavers with a mean operative time of 60 minutes (Figures 2A and 2B).

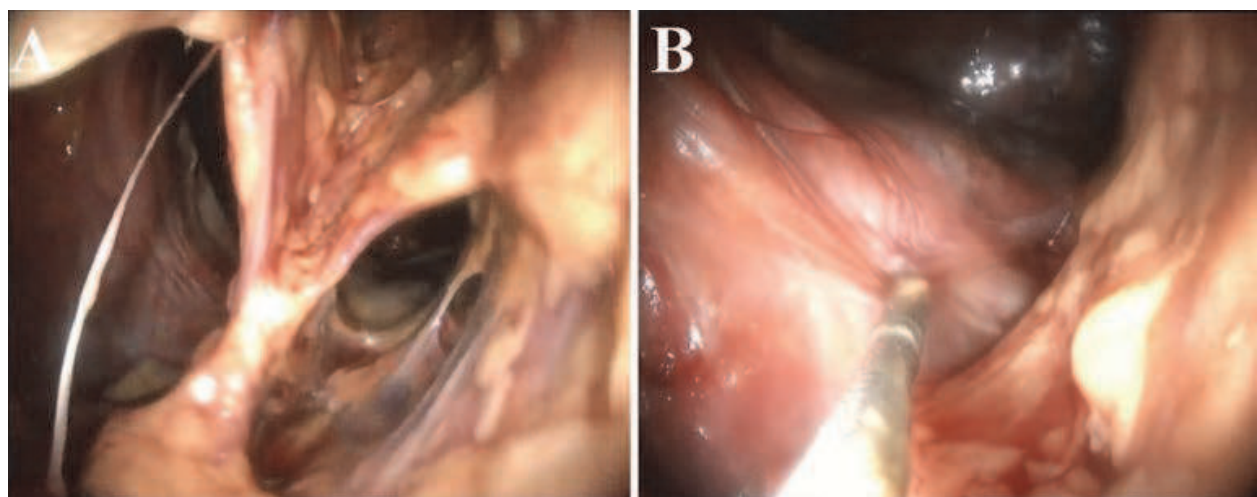


Fig. 2. (A) Retroperitoneal dissection prior to the sacral bone. (B) Identification of the promontory and the bifurcation of the iliac vessels.

2.3 Transvaginal endoscopic access in humans

2.3.1 Use of the rigid endoscope

The vaginal access has been used to visualize pelvic and intra-abdominal organs since the early 1900s, when it was called culdoscopy. On April 19, 1901, the Russian surgeon Dr. Dmitri von Ott first described the ventroscopy through colpotomy in Trendelenburg position at the Meeting of the Society of Gynaecology and Obstetrics of Saint Petersburg (Von Ott, 1902). In 1940, TeLinde was recognized as the author of one of the first accounts of rigid culdoscopy in The United States (Frenkel et al., 1952). In 1942, Palmer introduced the rigid transvaginal culdoscopy in a supine position (Brosens et al., 2003). In the same year, Decker (1952) invented what became known as the Decker's culdoscope, a rigid instrument with a light adjacent to the lens at the distal end. Clyman (1963) used a rigid culdoscope to carry out several procedures, such as lysis of adhesions, biopsies and aspirations of ovarian cysts.

In 1999, Watrelot et al. described the fertiloscopy, a minimally invasive technique for investigation of female infertility. It uses a minimally invasive transvaginal access to the pelvic organs and generally combines the following diagnostic procedures: hydrolaparoscopy (or hydropelviscopy), tubal patency test with methylene blue, salpingoscopy, micro-salpingoscopy and hysteroscopy. The use of videoscopic instruments inserted by transvaginal route to explore the pelvic peritoneal cavity is feasible and the technique has been applied in thousands of patients with complication rates below 1% (Gordts et al., 2008). Nohuz et al. (2006) retrospectively evaluated 229 women with primary or secondary infertility without any condition that would justify a laparoscopy and who could benefit from a fertiloscopy (Figures 3 to 5). Two hundred and three (88.6%) procedures were successfully performed, revealing lesions in 58 cases (28.6%).

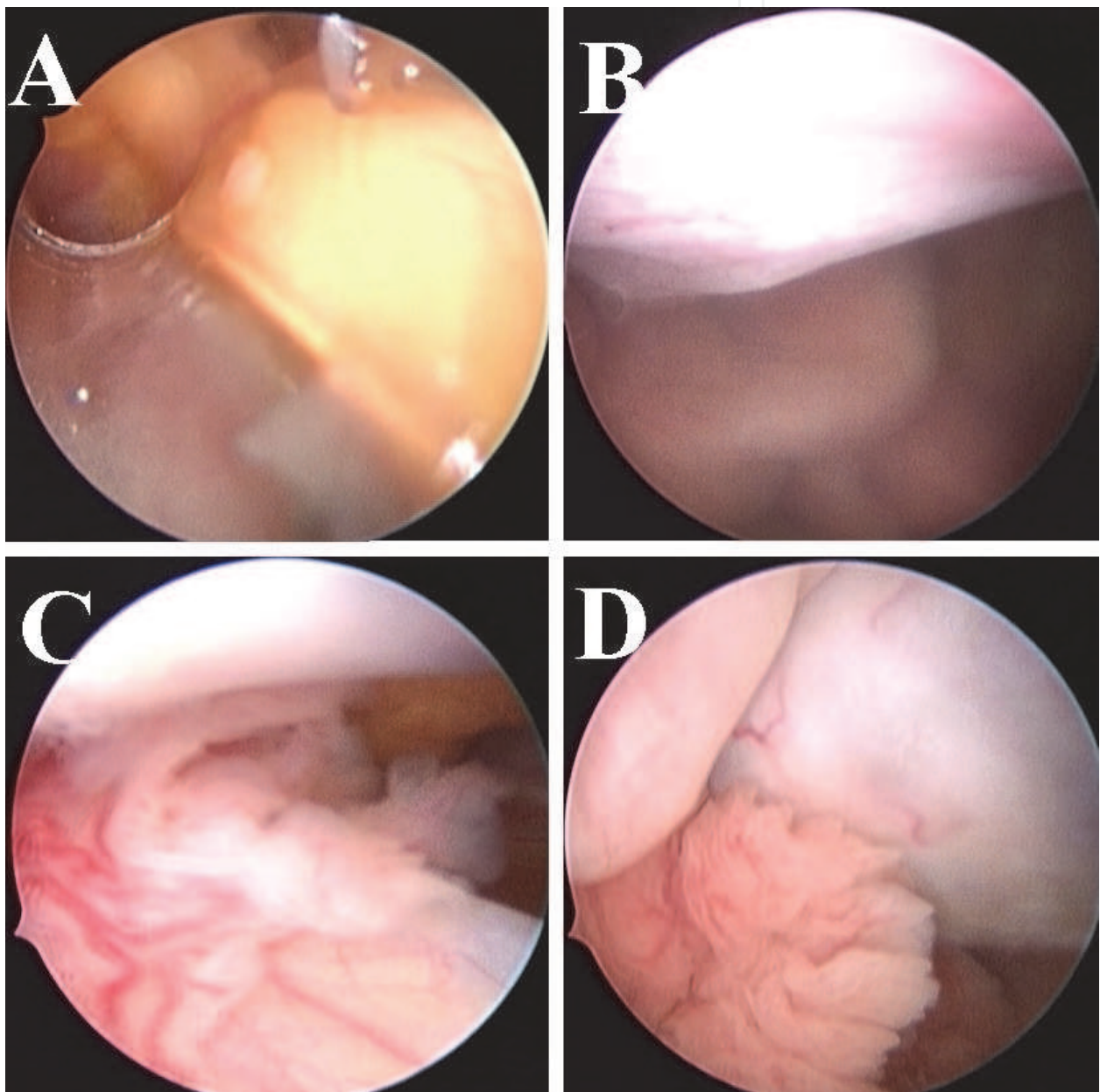


Fig. 3. Fertiloscopy: (A) Transvaginal access. (B) Posterior uterine wall. (C) Left fallopian tube. (D) Right fallopian tube.

Five complications (2.5%) were observed: two involving the rectum, two bleedings and a postoperative salpingitis. The biggest drawback of the rigid endoscope is the inability to explore the entire peritoneal cavity, especially the anterior uterine wall and the peritoneum covering the surface of the bladder and broad ligaments (Hackethal et al., 2011).

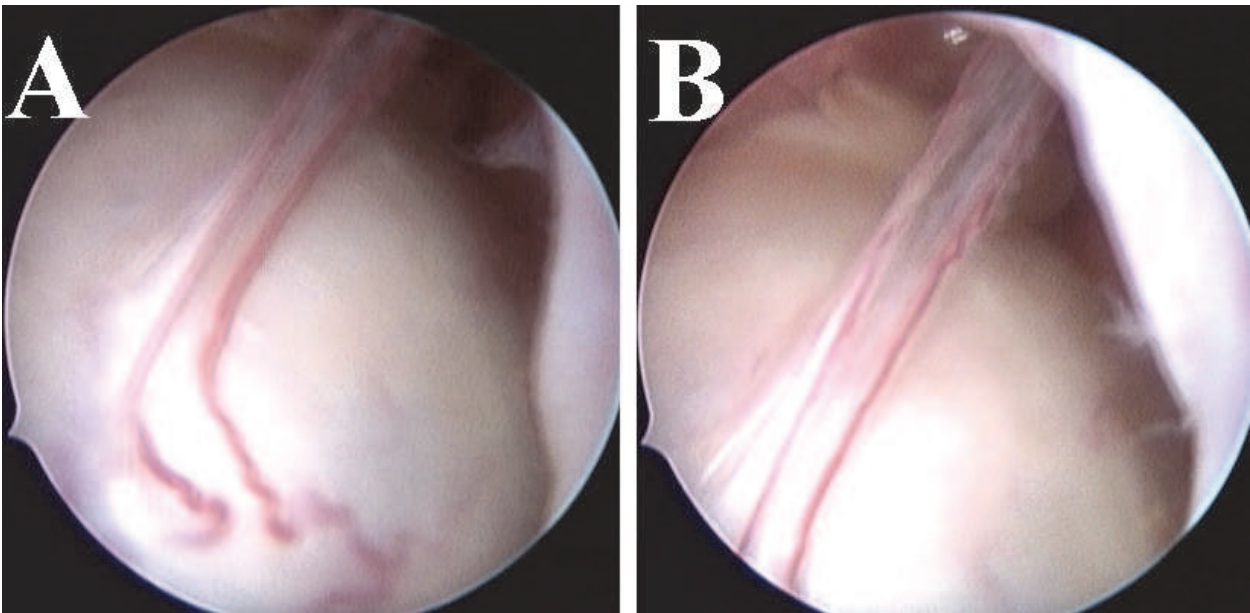


Fig. 4. Identification of adhesion over the left ovary during fertiloscopy.

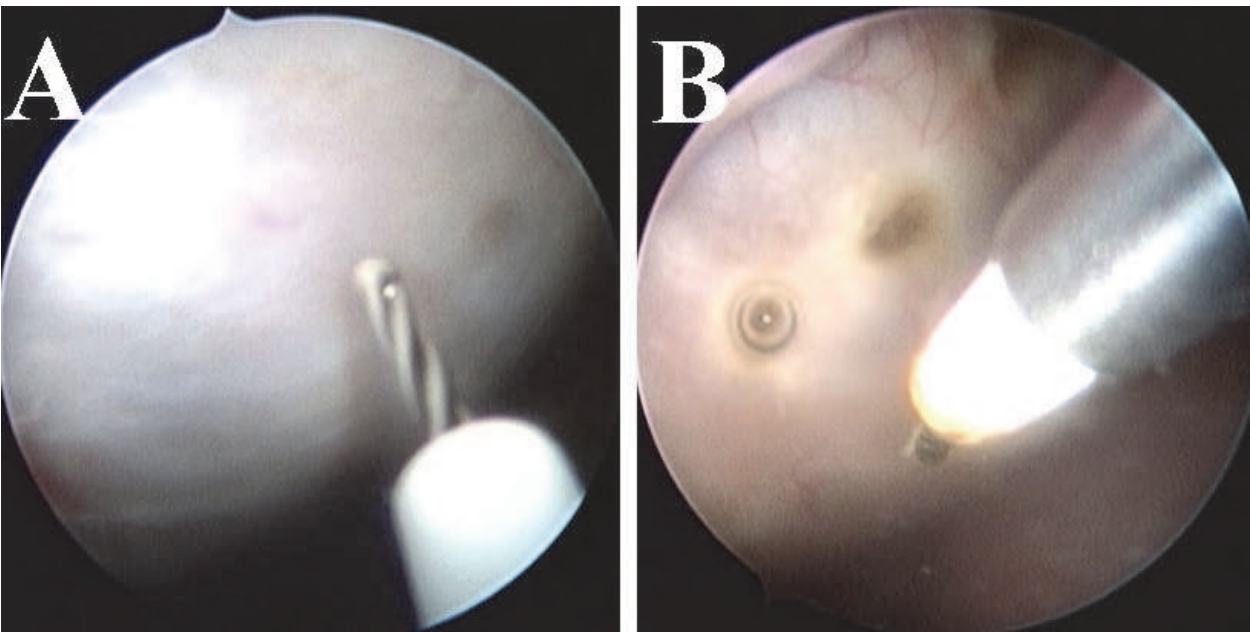


Fig. 5. Ovarian drilling by fertiloscopy.

In 2011, Hackethal et al. tested two new rigid endoscopes that allowed adjustable angles of view for evaluating women via transvaginal surgery: the 10mm rigid endoscope EndoCAMEleon (Karl Storz, Tuttlingen, Germany) that allowed viewing angles ranging from 0 to 120 degrees and the EndoEYE LTF-VH (Olympus, Hamburg, Germany) with a flexible tip that reaches an angle of 100 degrees. It was believed that the use of these new endoscopes

could facilitate the surgical access and the visualization of the entire female pelvis. Four patients with infertility ($n = 3$) and chronic pelvic pain ($n = 1$) were included in the study. They concluded that these new endoscopes did not allow a good view of the anterior portion of the pelvis to rule out endometriosis or other diseases. For transvaginal surgery with intent to explore the pelvic cavity, non-rigid endoscopes are as easy to manipulate as the rigid endoscopes and provide good visualization of the pelvic anatomy. The obvious disadvantages of rigid endoscopes and its fixed axis of vision have not been overcome by these new endoscopes. The inability of the endoscope to be angled back to inspect the pelvic structures undermines the efficiency of the diagnostic evaluation of the patient.

2.3.2 Use of the flexible endoscope

The first description of transvaginal endoscopic surgery was from 2007, when the team of Professor Marescaux in Strasbourg performed a cholecystectomy via hybrid transvaginal access (Marescaux et al., 2007). That same year, several reports of cholecystectomy using this technique were published worldwide (Branco Filho et al., 2007; Dolz et al., 2007; Zorrón et al., 2007). Since then, this access has been used to perform several procedures, including nephrectomy (Branco et al., 2008b; Castillo et al., 2009; Kaouk et al., 2010; Ribal Caparrós et al., 2009), tubal sterilization (Kondo et al., 2009), liver resection (Noguera et al., 2008), sleeve gastrectomy (Fischer et al., 2009; Ramos et al., 2008b), adjustable gastric banding (Michalik et al., 2010), incisional hernia repair (Jacobsen et al., 2010), cancer diagnostic staging (Zorrón et al., 2008), splenectomy (Targarona et al., 2009), retroperitoneoscopy (Zorrón et al., 2010a) among others.

More recently, some case series have been published (Alcaraz et al., 2010; Asakuma et al., 2009; Cuadrado-Garcia et al., 2011; Hackethal et al., 2010; Horgan et al., 2009; Lehmann et al., 2010; Niu et al., 2010; Noguera et al., 2009; Noguera et al., 2010; Palanivelu et al., 2008; Pugliese et al., 2010; Ramos et al., 2008a; Sotelo et al., 2010; Zornig et al., 2010a; Zornig et al., 2010b; Zorrón et al., 2010b). In China (Niu et al., 2010), cholecystectomies were successfully performed via laparoscopic assisted endoscopic transvaginal surgery. No intra- or postoperative complications were observed. All patients were satisfied with the cosmetic results.

Linke et al. (2010) assessed the feasibility and safety of rigid-hybrid transvaginal NOTES approach in routine practice for symptomatic cholelithiasis or acute cholecystitis in a patient population with low selection. One hundred and two consecutive patients were included in the study. Only two patients had conversion to conventional laparoscopic cholecystectomy. There were no intraoperative complications. Two major complications occurred: one stroke and one herniation within the transumbilical access. Minor complications were reported in 13 patients (12.7%) and there were no serious postoperative gynecological findings. At the 6th postoperative week, there were fewer dyspareunia symptoms than preoperatively ($p = 0.049$). Likewise, Zornig et al. (2010a) reported that by means of rigid laparoscopic instruments, transvaginal cholecystectomy can be routinely performed.

Palanivelu et al. (2008) described the transvaginal approach for endoscopic appendectomy in 6 patients. A totally endoscopic transvaginal appendectomy was successfully performed for one patient. The other five patients were either converted to conventional laparoscopy or aided by a laparoscope. The mean operating time was 103.5 minutes. Hospital stay varied from one to two days. The vaginal wound was examined by the gynecologist and was found to be completely healed within the first (7 days) and second (30 days) follow-up.

Noguera et al. (2010) described 10 women with intra-abdominal infections treated successfully with using hybrid NOTES by transvaginal access. The procedure was performed on an emergency basis by the surgical team on call. The indications for surgery were 6 cases of acute cholecystitis, 2 cases of acute appendicitis, and 2 cases of pelvic peritonitis.

Buesing et al. (2010) performed 14 cases of transvaginal assisted sleeve gastrectomies. Using the transvaginal technique the number of trocars could be reduced by 1-2 and in all cases the resected stomach was retrieved transvaginally. No complications occurred due to the vaginal access.

Alcaraz et al. (2010) evaluated the feasibility of transvaginal NOTES-assisted laparoscopic nephrectomy in female patients with and without renal cancer. Fourteen patients were submitted to the procedure for T1-T3a N0 M0 renal cancer (n=10), lithiasis (n=2), or renal atrophy (n=2). The procedure was completed in all patients. The mean operative time was 132.9 minutes and the mean estimated blood loss was 111.2ml. None of the patients required a blood transfusion and the use of analgesics was low. The mean hospital stay was 4 days. In one case, a major complication (a colon injury) occurred. The patient underwent surgery and a temporary colostomy was performed.

A German NOTES register (Lehmann et al., 2010) included 551 patients on whom surgery was performed in a 14-month period. Cholecystectomy accounted for 85.3% of all procedures. All procedures were performed on women using the hybrid transvaginal technique. Complications occurred in 3.1% of patients and conversion to laparoscopy or open surgery in 4.9%.

Zorron et al. (2010b) reported a multicenter study of 16 centers in 9 countries which included 362 patients who underwent transgastric and transvaginal NOTES. The most common procedures were transvaginal cholecystectomy (66.3%), transvaginal appendectomy (10.2%), transgastric cholecystectomy (8.01%) and transgastric appendectomy (3.87%), accounting for 88.38% of total procedures. The overall rate of complications was 8.84%, including 5.8% of grades I and II complications and 3.04% of grades III and IV complications.

Zornig et al. (2010b) analyzed 108 women who underwent hybrid transvaginal NOTES cholecystectomy with 192 women undergoing laparoscopic cholecystectomy and selected 100 patients in each group for comparison. The duration of the hybrid transvaginal procedure was longer than the conventional laparoscopic cholecystectomy (52 vs. 35 minutes; $p<0.001$). There were no intraoperative complications. There was no statistically significant difference regarding the need for reoperation, wound infections, consumption of analgesics and length of hospital stay. Seventy-five women who underwent hybrid transvaginal surgery and 73 undergoing laparoscopic cholecystectomy had intercourse after surgery with no complaints.

Hensel et al. (2010) performed a retrospective case-controlled study comparing 47 women undergoing transvaginal cholecystectomy with 46 women undergoing conventional laparoscopic cholecystectomy. Women of the former group reported less postoperative pain ($p<0.001$), less nausea or vomiting ($p<0.001$) and a lower analgesic consumption in both opiates ($p<0.001$) and non-opiates ($p<0.001$). Furthermore, the duration of stay in recovery room was shorter in the former group (40 minutes vs. 60 minutes, $p<0.001$). The rate of general and surgical complications was lower in the transvaginal group (1/47) compared to the laparoscopic group (4/46). In 9 women undergoing transvaginal cholecystectomy negligible vaginal bleeding was seen which stopped spontaneously in each case.

3. Preoperative preparation

The transvaginal access requires no special prior preparation. The only important step is the gynecological evaluation preoperatively to rule vulvovaginitis. In the presence of vaginal infections, we recommend antibiotic treatment at least one week before surgery in order to avoid pelvic infectious and its associated complications which result from the introduction of microorganisms into the peritoneal cavity during the development of the transvaginal access.

It is important to obtain the informed consent from the patient, especially in the young and nulliparous women. Although not frequent, the transvaginal access can lead to colpotomy-related dyspareunia postoperatively and only a few studies^{66, 83} have evaluated this potential complication with favorable results. In addition, the scar on the posterior vaginal fornix and the posterior cul-de-sac, can lead to the development of which can complicate a future pregnancy in nulliparous women.

The most important point of evaluation and preoperative preparation is the careful selection of patients for transvaginal endoscopic surgery. Although the surgical indications are the same, regardless of the approach being used, some relative and absolute contra-indications must be respected when this new access route is used.

3.1 Contra-indications

The transvaginal endoscopic access cannot be applied to all patients. There is no work showing what would constitute relative and absolute contraindications to the procedure, but based on our experience, we cite the following situations as potential contraindications:

- Deep endometriosis: the patients with severe endometriosis often have their lesions located posterior to the uterus, either in utero-sacral ligaments, in the retrocervical region or in the rectovaginal septum. This prevents access to the pelvic cavity through the posterior fornix of the vagina due to the high risk of iatrogenic injuries of adjacent organs during the creation of the access to the pelvic cavity. Also, the presence of resulting intense inflammatory/fibrotic disease hinders access to the cavity.
- Suspected adnexal lesions: all suspicious adnexal lesions are to be addressed with surgical oncologic principles. The precariousness of endoscopic instruments still makes meticulous surgical gestures difficult using this access. We cannot expose patients to the risk of a possible rupture of a malignant adnexal lesion and consequent contamination of the pelvic cavity with tumor cells.
- Previous pelvic surgery and history of pelvic inflammatory disease: surgical procedures in the pelvic region and previous episodes of pelvic inflammatory disease may lead to the formation of dense adhesions in this region and the instruments currently available for the performance of transvaginal endoscopy does not facilitate the perfect exposure and careful dissection which is required to access areas of the pelvis with large amount of adhesions.
- Complex surgical procedures: the lack of triangulation of the instruments and the endoscope image obtained through the retroflected view (upside down and mirror) do not allow complex surgical gestures can be accomplished.

4. Decision-making, anatomy, and key steps in the operations

Briefly, the important criteria for selecting patients for endoscopic surgery by transvaginal access include:

- Surgical indication for the proposed procedure (independent of the surgical route to be used).
- Female patient.
- Experience of the surgical team with advanced laparoscopic surgery, transvaginal access, and rigid and flexible endoscopic equipment.
- Absence of contraindications to the access.

4.1 Surgical technique

The patient is positioned in the dorsal lithotomy position with the legs in stirrups and the arms tucked at her sides. An orogastric tube and a Foley's catheter are placed. A prophylactic antibiotic (1g of cefazolin) is administered after induction of anesthesia. The surgical field (vaginal cavity) is prepared with povidone iodine or chlorhexidine solution.

The transvaginal access can be performed under direct vision (posterior colpotomy) or guided by laparoscopy.

4.1.1 Transvaginal access by direct visualization (Branco et al., 2008a; Kondo et al., 2009)

A Sims speculum is inserted in the vagina, and the posterior lip of the cervix is grasped by a Pozzi clamp. The vaginal walls are retracted by 2 lateral retractors, and anterior traction is given to the cervix to stretch the posterior fornix. The vaginal mucosa in the posterior cul-de-sac is opened at the cervico-vaginal junction by a semilunar 2.5-cm incision. The posterior margin is grasped by 1 Allis forceps, and sharp dissection is performed with the index finger. The posterior cul-de-sac peritoneum is identified and opened (Figure 6).

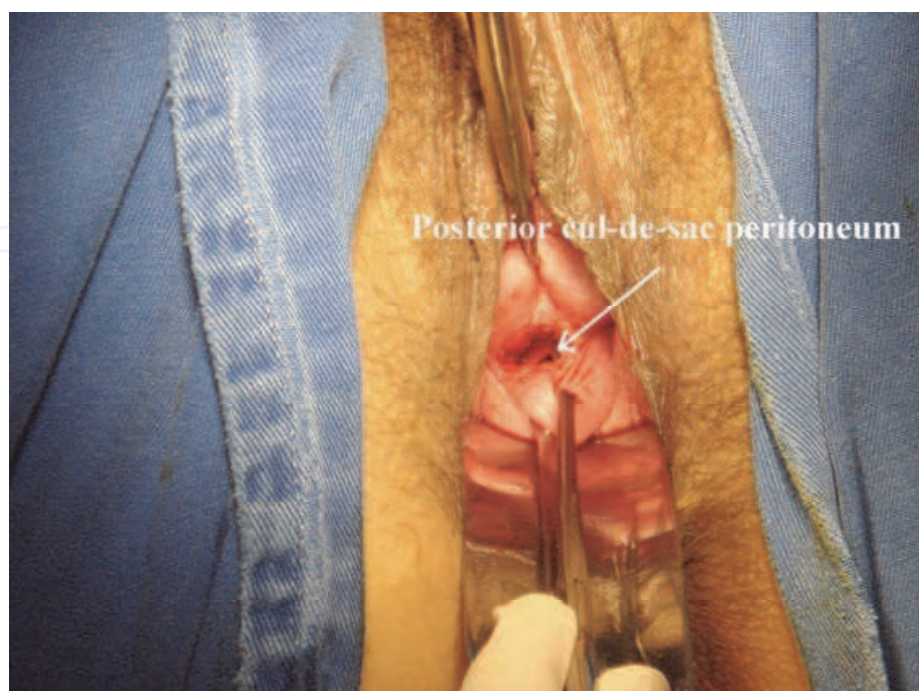


Fig. 6. Vaginal access by direct visualization.

The endoscope is inserted into the pelvic cavity (Figure 7), carbon dioxide insufflation can be achieved via a working channel of the endoscope or through a nasogastric tube connected externally to the endoscope, allowing for the introduction of forceps in each working channel (Figure 8).

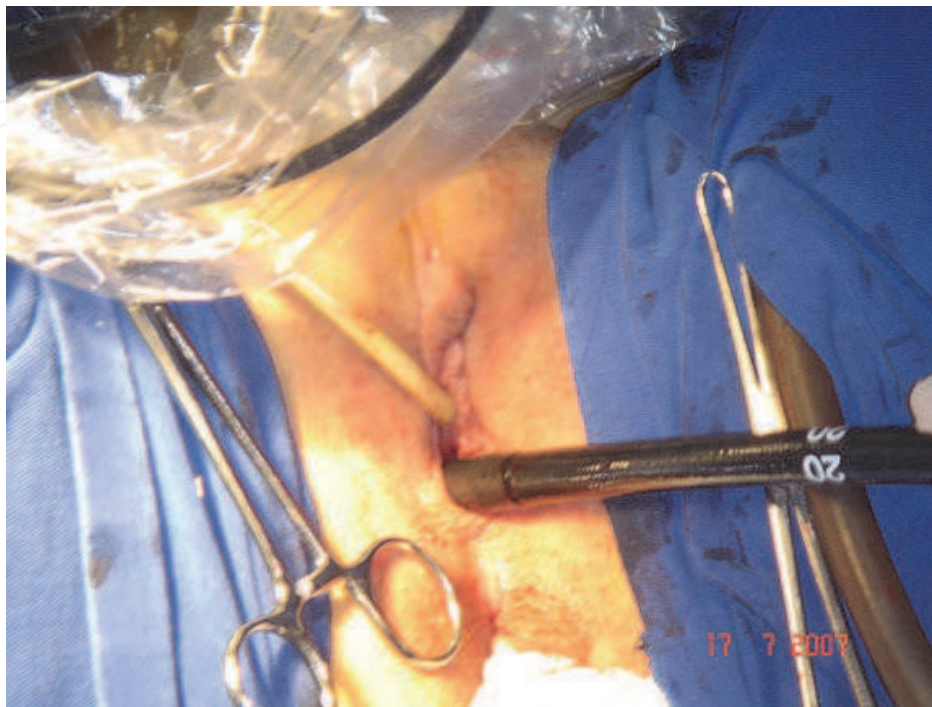

Fig. 7. Introduction of the endoscope through the vaginal cavity.

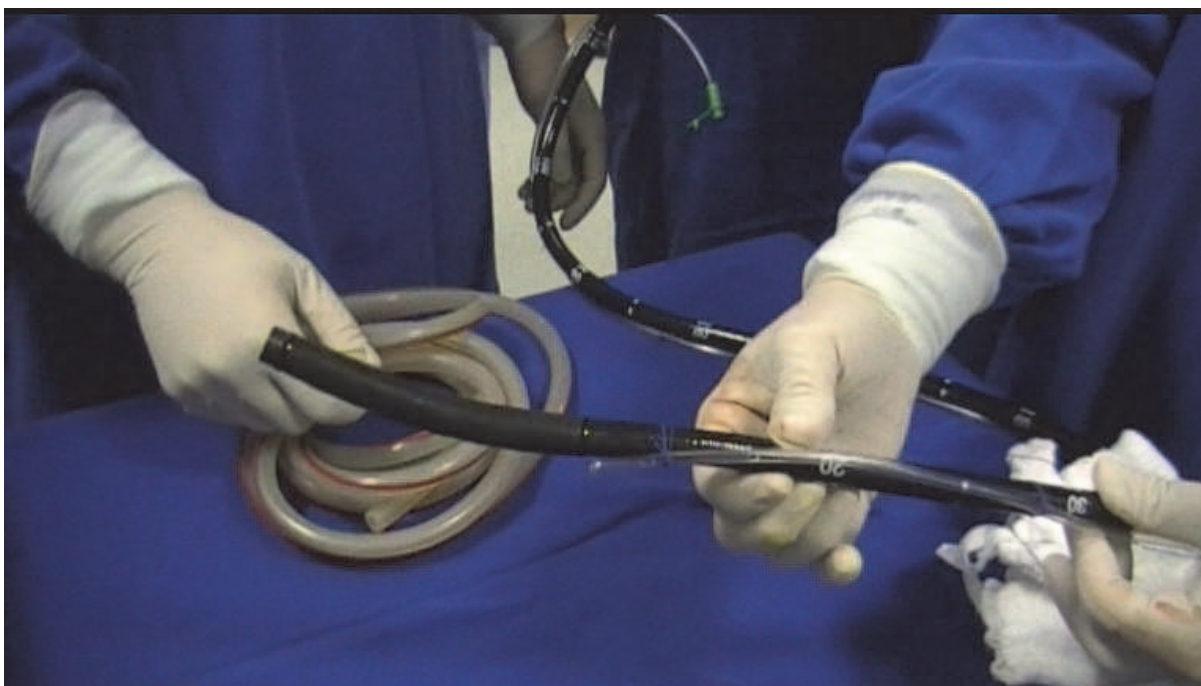

Fig. 8. Preparation of endoscope securing a nasogastric tube to the dual-channel endoscope, through which carbon dioxide was inflated to obtain the pneumoperitoneum.

4.1.2 Transvaginal access via laparoscopic guidance (Zorron et al., 2010b)

The surgeon is placed standing between the patient's legs; the first and second assistants stand on the left and right sides of the patient, respectively. In this setting, 2 visualization systems, one for the abdominal laparoscopic camera and the other for the TV flexible endoscope, are used. The procedure starts with a Veress puncture through an incision in the umbilicus to avoid a visible scar. Pneumoperitoneum is then insufflated through the Veress needle.

A 5-mm trocar is inserted, and a 5-mm laparoscopic optic used to inspect the abdominal cavity. To avoid the risk of injuring pelvic organs, some surgeons perform a thorough examination of the pelvis, looking for adhesions that might prohibit the TV cul-de-sac puncture. In patients who had had a previous hysterectomy, or unknown endometriosis, adhesions obliterating the pouch of Douglas contraindicate the further vaginal insertion of the trocar and conversion to formal laparoscopy is usually indicated. After inventory, a longer 10- to 12-mm laparoscopic trocar is inserted in the vaginal posterior cul-de-sac under laparoscopic guidance (Figure 9). The endoscope is progressed after extraction of the laparoscopic trocar.

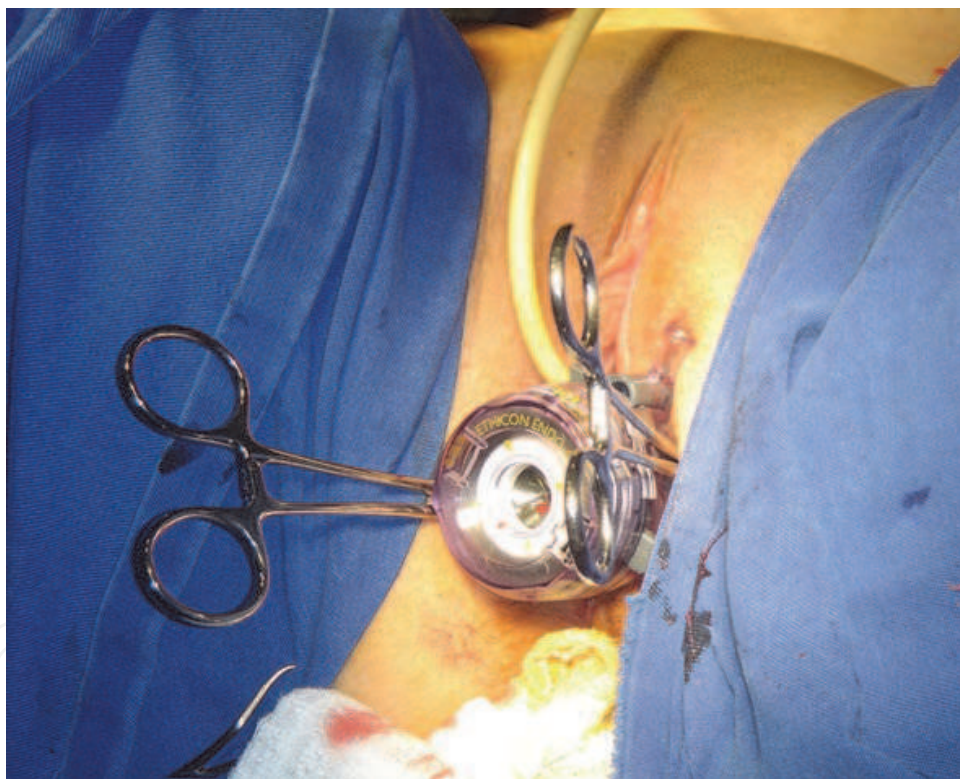

Fig. 9. Placement of transvaginal trocar guided by laparoscopy.

4.1.3 Technical details of the procedure

Technical details of the entire procedure vary according to the surgery to be performed. Here we focused on technical variations that exist specifically for transvaginal NOTES access, regardless of the structure to be operated on.

Four distinct techniques for transvaginal NOTES cholecystectomy have been described by different centers, regarding pure natural orifice surgery or combined hybrid techniques to facilitate efficiency and safety for the procedures (Zorron et al., 2010b):

- Totally NOTES dual scope method (de Sousa et al., 2009): utilizes two endoscopes inserted via the vaginal route (one single-channel gastroscope with the insufflation tube attached and one double-channel colonoscope). The former was used to retract the gallbladder and the latter to perform the cholecystectomy, thus avoiding the necessity of using transabdominal puncture for the introduction of laparoscopic forceps to expose the gallbladder (Figure 10).

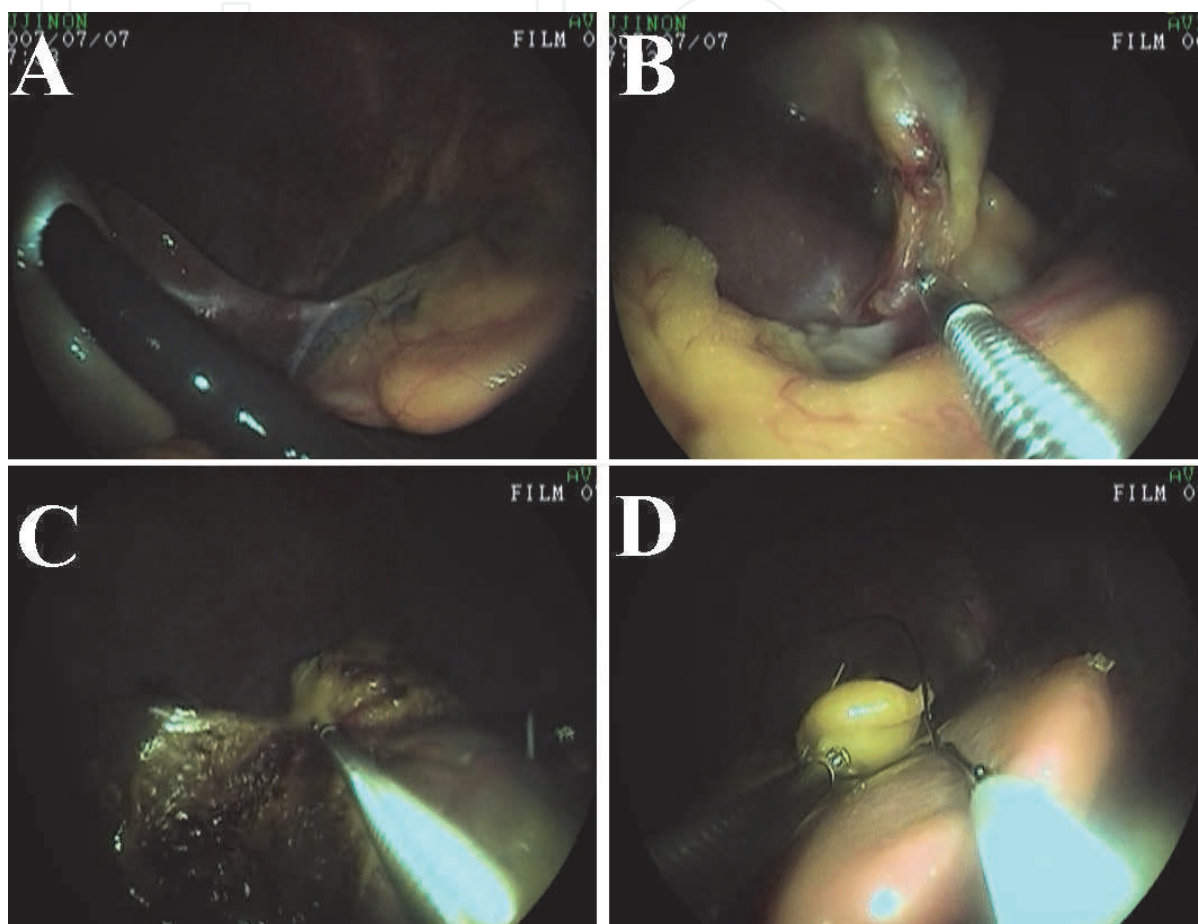


Fig. 10. Totally NOTES cholecystectomy (de Sousa et al., 2009) using two endoscopes. (A) One endoscope is used to retract the gallbladder. (B and C) The second endoscope is used to perform the procedure. (D) The gallbladder is retrieved from the abdominal cavity using an endoscopic polypectomy snare.

- Hybrid NOTES with transvaginal access and abdominal laparoscopy: laparoscopy was used in this technique for purposes such as safe access, visualization, and dissection, usually accomplished by endoscopic instruments or laparoscopy. Avoiding maximally the difficult endoscopic dissection and instrumentation, this method allowed for faster operations in a similar critical laparoscopic view (Figure 11 and 12).
- Transvaginal multipurpose port with flexible surgery: vaginal access and dissection were obtained by a transvaginal port (local adapted trocar) that permitted independent entry of the flexible endoscope (double-channel colonoscope), insufflation channel from a laparoflator, and semiflexible instruments used for retraction, cutting, and clipping using transvaginal laparoscopic titanium clips. Dissection was accomplished by available flexible endoscopic instruments, such as as polipectomy snares and hot-biopsy forceps.

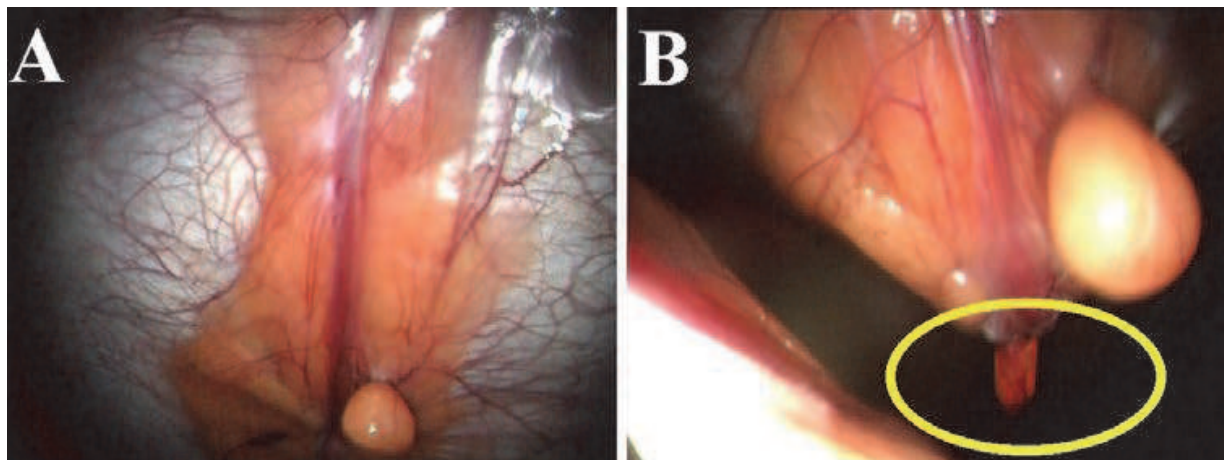


Fig. 11. Placement of a transumbilical trocar (yellow circle) guided by transvaginal endoscopic vision.

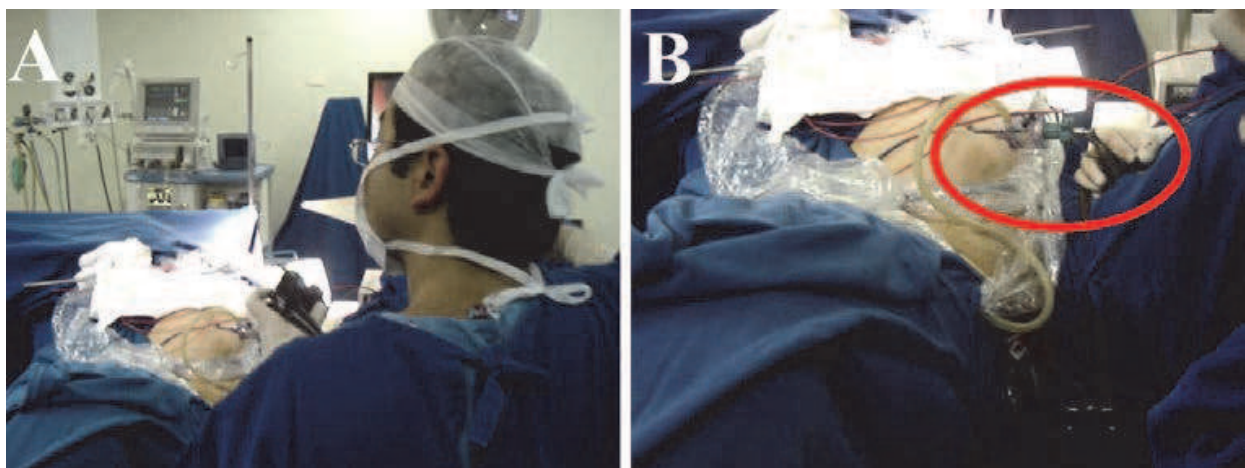


Fig. 12. (A) The surgeon is placed standing between the patient's legs. (B) One conventional laparoscopic instrument (red circle) placed transumbilically (hybrid NOTES).

- Transvaginal trocars (flexible or rigid optic) combined with umbilical minilaparoscopy: pneumoperitoneum was achieved by umbilical Veress needle puncture. After insufflation, opening of the posterior vaginal fornix was performed by direct vision to allow the introduction of a 1- or 2-channel gastroscope in the abdominal cavity. By retroflected view, a specially designed long 10-mm trocar was placed in the vagina, parallel to the endoscope. Two 3-mm trocars were placed transumbilically under direct endoscopic vision. Dissection of Calot's Triangle was performed using endoscopic instruments such as hot-biopsy forceps, polypectomy snares, endoscopic hook, and the umbilical 3-mm instruments. Cystic duct and artery were dissected and clipped using long laparoscopic clipator through the vaginal trocar.

NOTES appendectomies through vaginal access have been performed using direct access to the cavity with or without umbilical laparoscopic assistance. Usually the appendix could be managed without endoscopic retroflexion, or using vaginal rigid camera. Although a simple solution would be to perform the dissection through umbilical trocar, most teams used endoscopic dissection with hot-biopsy forceps and polypectomy snare. In case of need for peritoneal lavage due to pus, transvaginal endoscopic aspiration was performed or a laparoscopic irrigator aspirator was used (Zorron et al., 2010b).

For the endoscopic tubal sterilization (Kondo et al., 2009), a uterine manipulator was positioned to facilitate exposure of the tubes for the procedure (Figure 13). The tubes were coagulated and transected using endoscopic instruments inserted through the flexible endoscope with dual working channel (Figure 14).

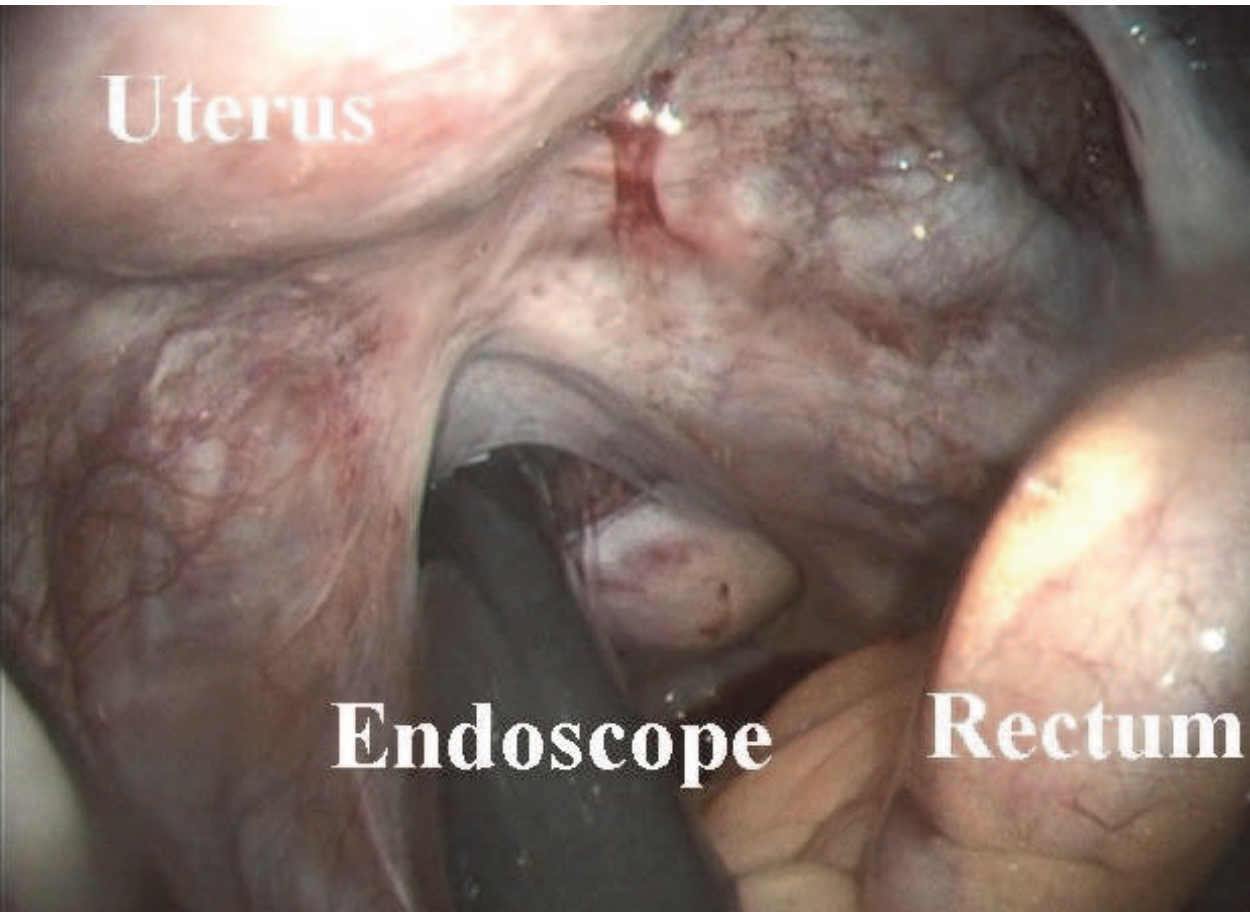


Fig. 13. The manipulation of the uterus using a uterine manipulator allows excellent exposure of the posterior cul-de-sac.

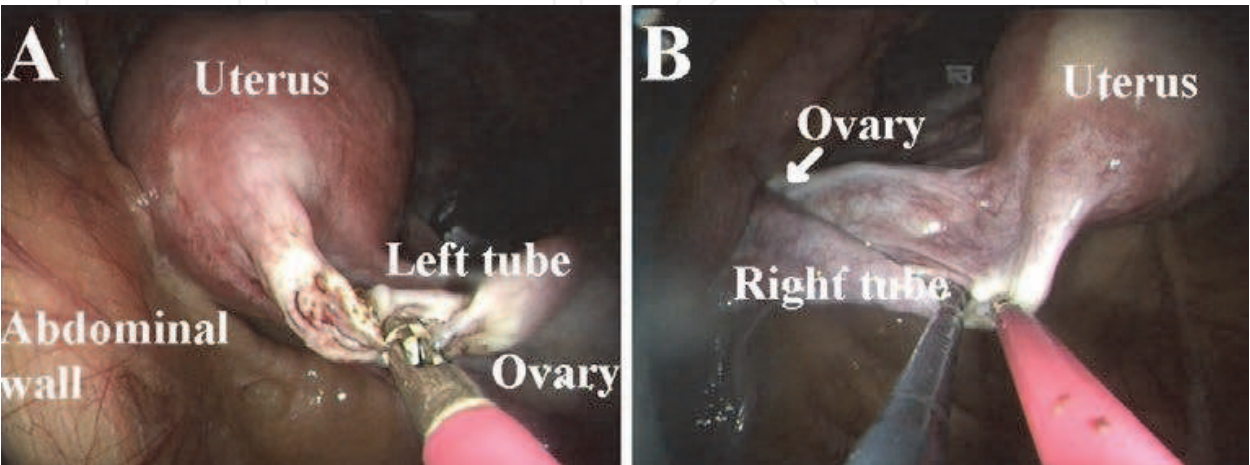


Fig. 14. Transvaginal endoscopic tubal sterilization.

4.1.4 Closure of the vagina

After the procedure, the posterior cul-de-sac and the posterior vaginal fornix are closed with a running 2-0 vicryl suture.

5. Surgical tricks

The presence of an endoscopist in the operating room is of paramount importance in the early learning curve, since he is more familiar with the performance of the maneuvers using the flexible endoscopic equipment.

The use of hybrid technique (endoscopic transvaginal access associated with transabdominal punctures) seems to be a natural transition from the traditional laparoscopic approach to surgery by natural orifices. Some details, which were previously discussed, highlight the measures, which serve to increase the safety of this method and reduce risks to patient:

- Execution of laparoscopic-guided vaginal access: access to the abdominal cavity through the vagina was known long ago by gynecologists (Box et al., 2009), but general surgeons are not familiar with this surgical approach. In this case, we recommend the creation of the pneumoperitoneum through the umbilicus, followed by placement of trocar. With the use of a 5-mm laparoscope and the placement of the patient in maximum Trendelenburg position, the posterior cul-de-sac is exposed. At this surgical step, the placement of a curette through the cervix assists with uterine manipulation (uterine anteversion), allowing to the correct exposure of the posterior cul-de-sac. Thus, one can introduce a trocar through the posterior vaginal fornix under direct vision.
- Hybrid NOTES: hybrid techniques have been used in most case series published to date. The endoscope with two working channels is introduced by vaginal route for the flexible endoscopy forceps and the surgeon uses one or more additional conventional laparoscopy instruments positioned by the transabdominal route for easy handling and checking of structures to achieve triangulation for more complex procedures.
- The use of long rigid endoscope by transvaginal route is also an option for surgery of upper abdomen. In the case of pelvic surgery, requiring a retroflected view, this modification method is not applicable.

6. Postoperative care

The patient is given a clear liquid diet 6 hours after the procedure and a regular diet the following morning. Intravenous dypirone (1 g per 6 hours) is administered for pain relief and usually no supplemental analgesia is necessary.

If the postoperative course is uneventful, patients can be discharged on the first postoperative day. They must be advised to avoid vaginal intercourse for 40 days.

The other postoperative recommendations are inherent to the surgical procedure, varying according to the type of surgery for which the patient was referred.

7. Impact of the technique on modern practice

The use of less aggressive surgical techniques for patients is the goal of modern surgery. The surgical approaches by natural orifices have arisen for this purpose and their role in clinical practice should be established in the future. So far, only a few centers have performed this type of surgery, with promising results.

The transvaginal endoscopic approach has several potential advantages (Dubcenco et al., 2009; Tonouchi et al., 2004):

- Good acceptance by patients, since it leaves no scars on the abdomen.
- Mirrors laparoscopic surgery.
- Associated with minimal morbidity.
- Allows viewing of all the pelvic anatomy.
- Minimal postoperative pain.
- Limited postoperative recovery time.
- Prevents hernias in trocar ports and can decrease the formation of intra-abdominal adhesions.

The disadvantages of this method include:

- Inability to use in all patients (see contraindications) and in men.
- Need for a long learning curve.
- Need for prolonged periods of sexual abstinence after the procedure to complete vaginal healing.

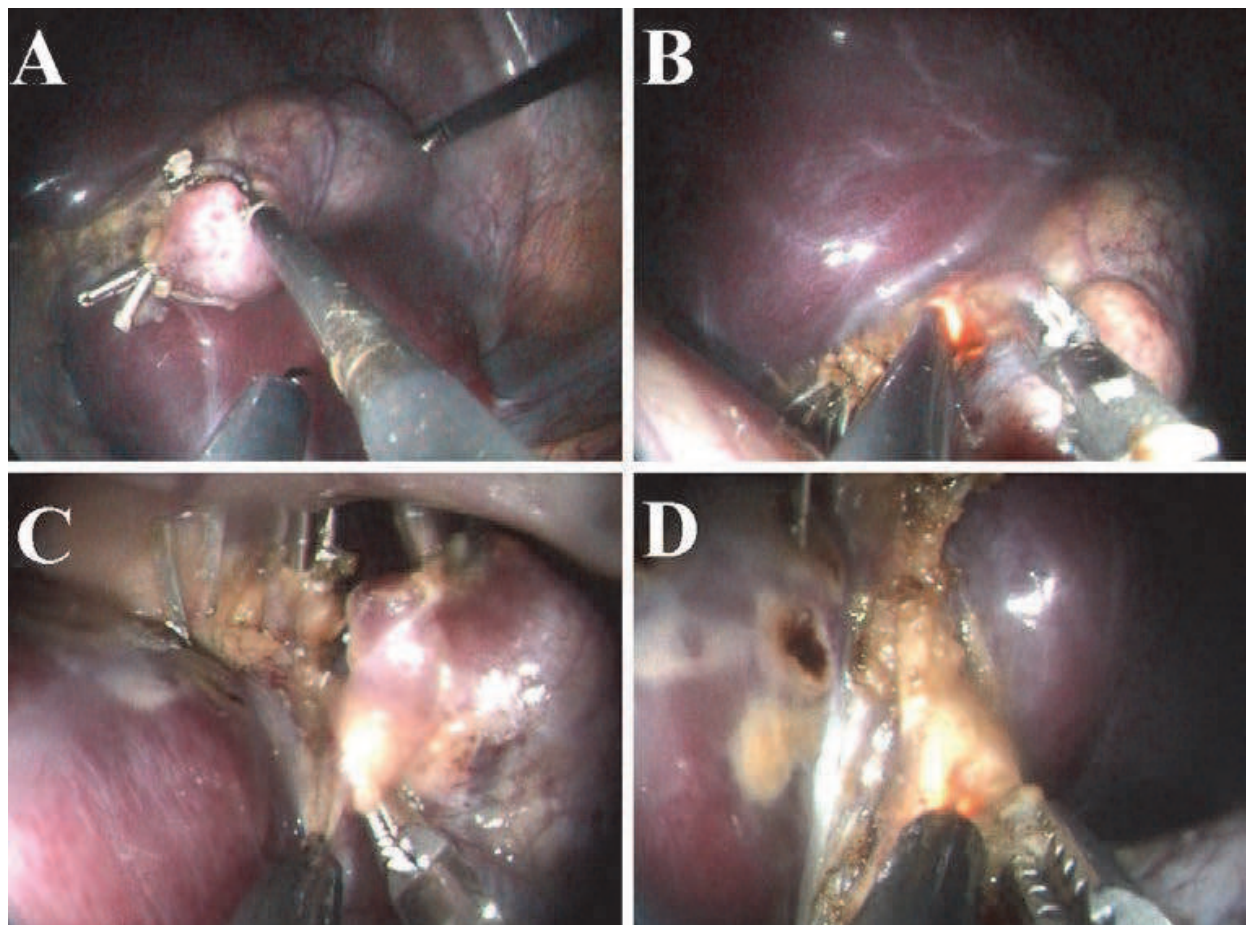


Fig. 15. Hybrid NOTES cholecystectomy. Both endoscopic instruments work in parallel, without triangulation.

7.1 Difficulties

As NOTES involves the use of a flexible scope in a large abdominal cavity, with operating instruments in line with the light source, difficulties associated with poor visibility,

maintenance of spatial orientation, maneuverability and grasping are evident. These technical difficulties are well demonstrated in the literature for the transvaginal NOTES (Branco et al., 2008b; Branco Filho et al., 2007; Kondo et al., 2009):

- Flexibility of conventional endoscopes: allows limited control of instruments during surgery.
- Lack of triangulation: the instruments are inserted through the two working channels of the flexible endoscopes, arriving in parallel into the peritoneal cavity, which restricts the movements of the surgeon (Figure 15).
- Lack of stability of the endoscope: the endoscope does not remain stationary within the peritoneal cavity during surgery; thus optimal surgical exposure is constantly lost. Moreover, the commensurate movement of the instruments and the endoscope results in loss of the surgical field of view.
- Retroflected view (U-turn): pelvic surgery is performed with retroflected view, which implies an image upside down and reversed, making difficult the notion of movement of the instruments and the endoscope. It is not always possible to obtain a front view with U-turn, and often a lateral view is obtained, which makes the procedure more laborious (Figure 16). This is not a problem for surgeries of upper abdomen.

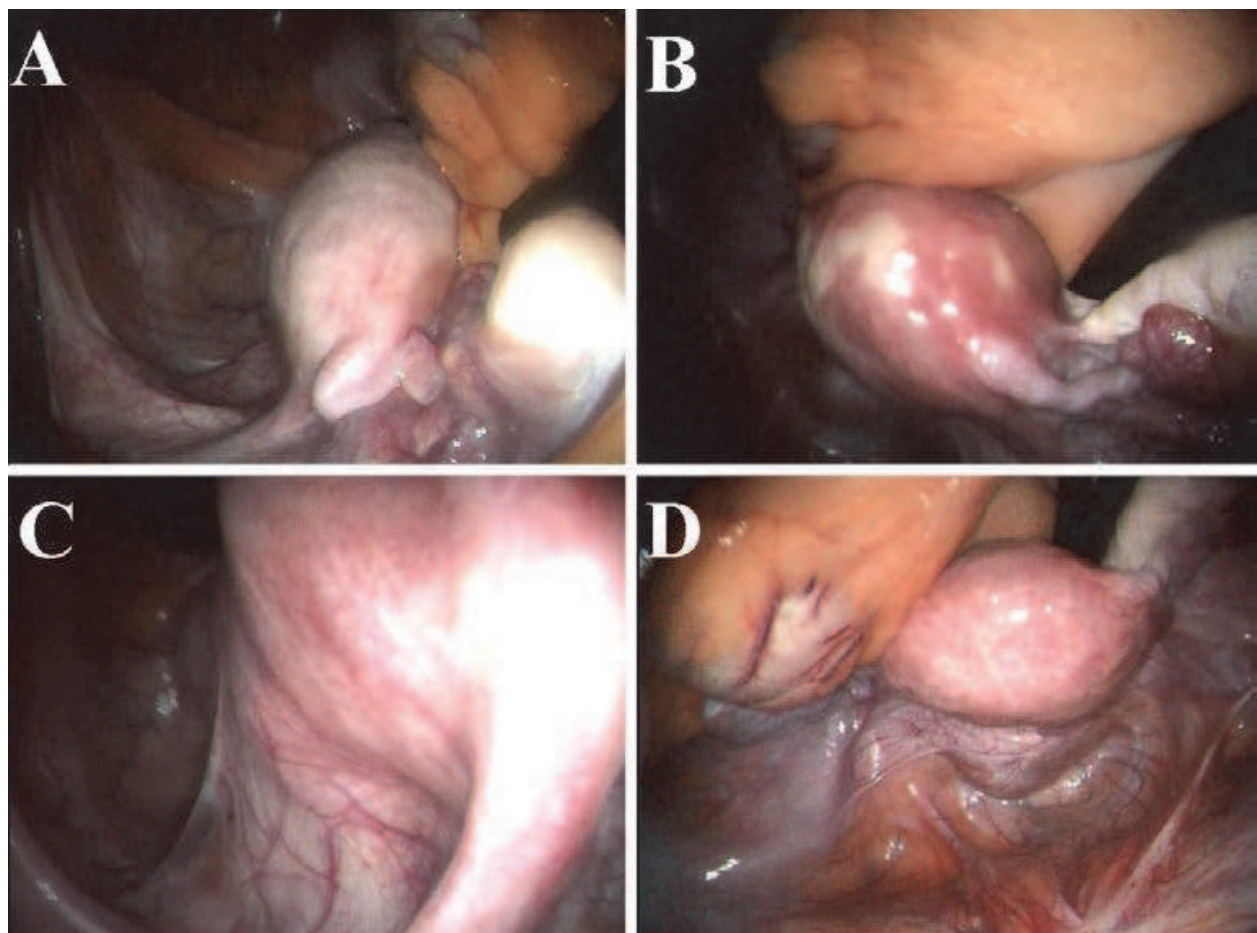


Fig. 16. U-turn to visualize the pelvis. (A to C) The endoscope is turned to inspect the pelvis and the image obtained is lateral. (D) The image is upside down and reversed when the entire pelvis is visualized.

8. Recommendations and conclusions

NOTES using the vagina as an entry point to the peritoneal cavity is very promising and several surgical procedures have been performed using this route. With the development of new instruments and platforms that facilitate handling and stabilization of flexible endoscopes, the surgical approach has the potential to have broad clinical applications in the future.

9. References

- Alcaraz, A., Peri, L., Molina, A., Goicoechea, I., García, E., Izquierdo, L. & Ribal, MJ. (2010). Feasibility of transvaginal NOTES-assisted laparoscopic nephrectomy. *Eur Urol*, 57, 2, (Feb 2010), pp. (233-237), ISSN 0302-2838.
- Allemann, P., Perretta, S., Asakuma, M., Dallemagne, B., Mutter, D. & Marescaux, J. (2009). NOTES retroperitoneal transvaginal distal pancreatectomy. *Surg Endosc*, 23, 4, (Apr 2009), pp. (882-883), ISSN 1432-2218.
- Allemann, P., Perretta, S., Asakuma, M., Dallemagne, B. & Marescaux, J. (2010). NOTES new frontier: Natural orifice approach to retroperitoneal disease. *World J Gastrointest Surg*, 2, 5, (May 2010), pp. (157-164), ISSN 1948-9366.
- Aminsharifi, A., Taddayun, A., Shakeri, S., Hashemi, M. & Abdi, M. (2009). Hybrid natural orifice transluminal endoscopic surgery for nephrectomy with standard laparoscopic instruments: experience in a canine model. *J Endourol*, 23, 12, (Dec 2009), pp. (1985-1989), ISSN 0892-7790.
- Aron, M., Berger, AK., Stein, RJ., Kamoi, K., Brandina, R., Canes, D., Sotelo, R., Desai, MM. & Gill, IS. (2009). Transvaginal nephrectomy with a multichannel laparoscopic port: a cadaver study. *BJU Int*, 103, 11, (Jun 2009), pp. (1537-1541), ISSN 1464-410X.
- Asakuma, M., Perretta, S., Allemann, P., Cahill, R., Con, SA., Solano, C., Pasupathy, S., Mutter, D., Dallemagne, B. & Marescaux, J. (2009). Challenges and lessons learned from NOTES cholecystectomy initial experience: a stepwise approach from the laboratory to clinical application. *J Hepatobiliary Pancreat Surg*, 16, 3, (2009), pp. (249-254), ISSN 1868-6982.
- Bessler, M., Stevens, PD., Milone, L., Hogle, NJ., Durak, E. & Fowler, D. (2008). Transvaginal laparoscopic cholecystectomy: laparoscopically assisted. *Surg Endosc*, 22, 7, (Jul 2008), pp. (1715-1716), ISSN 1432-2218.
- Bourdel, N., Kondo, W., Botchorishvili, R., Poincloux, L., Niro, J., Rabischong, B., Jardon, K., Pouly, JL., Mage, G. & Canis, M. (2009). Assessment of sentinel nodes for gynecologic malignancies by natural orifices transluminal endoscopic surgery (NOTES): preliminary report. *Gynecol Oncol*, 115, 3, (Dec 2009), pp. (367-370), ISSN 0090-8258.
- Box, GN., Bessler, M. & Clayman, RV. (2009). Transvaginal access: current experience and potential implications for urologic applications. *J Endourol*, 23, 5, (May 2009), pp. (753-757), ISSN 0892-7790.
- Branco, AW., Branco Filho, AJ., Noda, RW., George, MA., Camargo, AH., & Kondo, W. (2008a). New minimally invasive surgical approaches: transvaginal and transumbilical. *Braz J Video-Sur*, 1, 1, (Jan-Mar 2008), pp. (29-36), ISSN 1983-9901.
- Branco, AW., Branco Filho, AJ., Kondo, W., Noda, RW., Kawahara, N., Camargo, AA., Stunitz, LC., Valente, J. & Rangel, M. (2008b). Hybrid transvaginal nephrectomy. *Eur Urol*, 53, 6, (Jun 2008), pp. (1290-1294), ISSN 0302-2838.

- Branco Filho, AJ., Noda, RW., Kondo, W., Kawahara, N., Rangel, M. & Branco, AW. (2007). Initial experience with hybrid transvaginal cholecystectomy. *Gastrointest Endosc*, 66, 6, (Dec 2007), pp. (1245-1248), ISSN 0016-5107.
- Brosens, I., Campo, R., Puttemans, P. & Gordts, S. (2003). Transvaginal laparoscopy. *Clin Obstet Gynecol*, 46, 1, (Mar 2003), pp. (117-122), ISSN 1532-5520.
- Buesing, M., Utech, M., Halter, J., Riege, R., Saada, G. & Knapp, A. (2010). Sleeve gastrectomy in the treatment of morbid obesity : Study results and first experiences with the transvaginal hybrid NOTES technique. *Chirurg*, in press (2010), ISSN 1433-0385.
- Castillo, OA., Vidal-Mora, I., Campos, R., Fonerón, A., Feria-Flores, M., Gómez, R. & Sepúlveda, F. (2009). Laparoscopic simple nephrectomy with transvaginal notes assistance and the use of standard laparoscopic instruments. *Actas Urol Esp*, 33, 7, (Jul-Aug 2009), pp. (767-770), ISSN 0210-4806.
- Clayman, RV., Box, GN., Abraham, JB., Lee, HJ., Deane, LA., Sargent, ER., Nguyen, NT., Chang, K., Tan, AK., Ponsky, LE. & McDougall, EM. (2007). Rapid communication: transvaginal single-port NOTES nephrectomy: initial laboratory experience. *J Endourol*, 21, 6, (Jun 2007), pp. (640-644), ISSN 0892-7790.
- Clyman, MJ. (1963). A new panculdoscope - diagnostic, photographic, and operative aspects. *Obstet Gynecol*, 21, (1963), pp. (343-348), ISSN 0029-7844.
- Cuadrado-Garcia, A., Noguera, JF., Olea-Martinez, JM., Morales, R., Dolz, C., Lozano, L., Vicens, JC. & Pujol, JJ. (2011). Hybrid natural orifice transluminal endoscopic cholecystectomy: prospective human series. *Surg Endosc*, 25, 1, (Jan 2011), pp. (19-22), ISSN 1432-2218.
- de la Fuente, SG., Demaria, EJ., Reynolds, JD., Portenier, DD. & Pryor, AD. (2007). New developments in surgery: Natural Orifice Transluminal Endoscopic Surgery (NOTES). *Arch Surg*, 142, 3, (Mar 2007), pp. (295-297), ISSN 0004-0010.
- de Sousa, LH., de Sousa, JÁ., de Sousa Filho, LH., de Sousa, MM., de Sousa, VM., de Sousa, AP. & Zorron, R. (2009). Totally NOTES (T-NOTES) transvaginal cholecystectomy using two endoscopes: preliminary report. *Surg Endosc*, 23, 11, (Nov 2009), pp. (2550-2555), ISSN 1432-2218.
- Decker, A. (1952). Culdoscopy. *Am J Obstet Gynecol*, 63, (1952), pp. (854-859), ISSN 0002-9378.
- Dolz, C., Noguera, JF., Martín, A., Vilella, A. & Cuadrado, A. (2007). Transvaginal cholecystectomy (NOTES) combined with minilaparoscopy. *Rev Esp Enferm Dig*. 2007 Dec;99(12):698-702, ISSN 1130-0108.
- Dubcenco, E., Assumpcao, L., Dray, X., Gabrielson, KL., Ruben, DS., Pipitone, LJ., Donatelli, G., Krishnamurty, DM., Baker, JP., Marohn, MR. & Kalloo, AN. (2009). Adhesion formation after peritoneoscopy with liver biopsy in a survival porcine model: comparison of laparotomy, laparoscopy, and transgastric natural orifice transluminal endoscopic surgery (NOTES). *Endoscopy*, 41, 11, (Nov 2009), pp. (971-978), ISSN 0013-726X.
- Fischer, LJ., Jacobsen, G., Wong, B., Thompson, K., Bosia, J., Talamini, M. & Horgan, S. (2009). NOTES laparoscopic-assisted transvaginal sleeve gastrectomy in humans - description of preliminary experience in the United States. *Surg Obes Relat Dis*, 5, 5, (Sep-Oct 2009), pp. (633-636), ISSN 1550-7289.
- Frenkel, DA., Greenem BA. & Siegler, SL. (1952). Technical improvements in culdoscopic examination. *Am J Obstet Gynecol*, 64, (1952), pp. (1303-1309), ISSN 0002-9378.
- Gettman, MT., Lotan, Y., Napper, CA. & Cadeddu, JA. (2002). Transvaginal laparoscopic nephrectomy: development and feasibility in the porcine model. *Urology*, 59, 3, (Mar 2002), pp. (446-450), ISSN 0090-4295.

- Gordts, S., Campo, R., Puttemans, P., Gordts, SY. & Brosens, I. (2008). Transvaginal access: a safe technique for tubo-ovarian exploration in infertility? Review of the literature. *Gynecol Surg*, 5, 3, (2008), pp. (187-191), ISSN 1613-2076.
- Haber, GP., Brethauer, S., Crouzet, S., Berger, A., Gatmaitan, P., Kamoi, K. & Gill, I. (2009). Pure natural orifice transluminal endoscopic surgery for transvaginal nephrectomy in the porcine model. *BJU Int*, 104, 9, (Nov 2009), pp. (1260-1264), ISSN 1464-410X.
- Hackethal, A., Sucke, J., Oehmke, F., Münstedt, K., Padberg, W. & Tinneberg, HR. (2010). Establishing transvaginal NOTES for gynecological and surgical indications: benefits, limits, and patient experience. *Endoscopy*, 42, 10, (Oct 2010), pp. (875-878), ISSN 0013-726X.
- Hackethal, A., Ionesi-Pasacica, J., Eskef, K., Oehmke, F., Münstedt, K. & Tinneberg, HR. (2011). Transvaginal NOTES with semi-rigid and rigid endoscopes that allow adjustable viewing angles. *Arch Gynecol Obstet*, 283, 1, (Jan 2011), pp. (131-132), ISSN 1432-0711.
- Hagen, ME., Wagner, OJ., Swain, P., Pugin, F., Buchs, N., Cadeddu, M., Jamidar, P., Fasel, J. & Morel, P. (2008). Hybrid natural orifice transluminal endoscopic surgery (NOTES) for Roux-en-Y gastric bypass: an experimental surgical study in human cadavers. *Endoscopy*, 40, 11, (Nov 2008), pp. (918-924). ISSN 0013-726X.
- Hensel, M., Schernikau, U., Schmidt, A. & Arlt, G. (2010). Comparison between Transvaginal and Laparoscopic Cholecystectomy - A Retrospective Case-Control Study. *Zentralbl Chir*, in press, (2010), ISSN 0044- 409X.
- Horgan, S., Cullen, JP., Talamini, MA., Mintz, Y., Ferreres, A., Jacobsen, GR., Sandler, B., Bosia, J., Savides, T., Easter, DW., Savu, MK., Ramamoorthy, SL., Whitcomb, E., Agarwal, S., Lukacz, E., Dominguez, G. & Ferraina, P. (2009). Natural orifice surgery: initial clinical experience. *Surg Endosc*, 23, 7, (Jul 2009), pp. (1512-1518), ISSN 1432-2218.
- Horváth, S., Gál, I., Rákóczi, I., Jávör, S., Balatonyi, B., Takács, I., Ferencz, A., Ferencz, S. & Wéber, G. (2009). Transvaginal cholecystectomy in animal model: first series in Hungary. *Magy Seb*, 62, 3, (Jun 2009), pp. (120-124), ISSN 0025-0295.
- Isariyawongse, JP., McGee, MF., Rosen, MJ., Cherullo, EE. & Ponsky, LE. (2008). Pure natural orifice transluminal endoscopic surgery (NOTES) nephrectomy using standard laparoscopic instruments in the porcine model. *J Endourol*, 22, 5, (May 2008), pp. (1087-1091), ISSN 0892-7790.
- Jacobsen, GR., Thompson, K., Spivack, A., Fischer, L., Wong, B., Cullen, J., Bosia, J., Whitcomb, E., Lucas, E., Talamini, M. & Horgan, S. (2010). Initial experience with transvaginal incisional hernia repair. *Hernia*, 14, 1, (Feb 2010), pp. (89-91), ISSN 1265-4906.
- Jagannath, SB., Kantsevoy, SV., Vaughn, CA., Chung, SS., Cotton, PB., Gostout, CJ., Hawes, RH., Pasricha, PJ., Scorpio, DG., Magee, CA., Pipitone, LJ. & Kalloo, AN. (2005). Peroral transgastric endoscopic ligation of fallopian tubes with long-term survival in a porcine model. *Gastrointest Endosc*, 61, 3, (Mar 2005), pp. (449-453), ISSN 0016-5107.
- Jin, C., Hu, Y., Chen, XC., Zheng, FY., Lin, F., Zhou, K., Chen, FD. & Gu, HZ. (2009). Laparoscopic versus open myomectomy--a meta-analysis of randomized controlled trials. *Eur J Obstet Gynecol Reprod Biol*, 145, 1, (Jul 2009), pp. (14-21), ISSN 0028-2243.
- Kaloo, AN., Singh, VK., Jagannath, SB., Niiyama, H., Hill, SL., Vaughn, CA., Magee, CA. & Kantsevoy, SV. (2004). Flexible transgastric peritoneoscopy: a novel approach to diagnostic and therapeutic interventions in the peritoneal cavity. *Gastrointest Endosc*, 60, 1, (Jul 2004), pp. (114-7), ISSN 0016-5107.


- Kantsevov, SV., Jagannath, SB., Niiyama, H., Chung, SS., Cotton, PB., Gostout, CJ., Hawes, RH., Pasricha, PJ., Magee, CA., Vaughn, CA., Barlow, D., Shimonaka, H. & Kalloo, AN. (2005). Endoscopic gastrojejunostomy with survival in a porcine model. *Gastrointest Endosc*, 62, 2, (Aug 2005), pp. (287-292), ISSN 0016-5107.
- Kantsevov, SV., Hu, B., Jagannath, SB., Vaughn, CA., Beitler, DM., Chung, SS., Cotton, PB., Gostout, CJ., Hawes, RH., Pasricha, PJ., Magee, CA., Pipitone, LJ., Talamini, MA. & Kalloo, AN. (2006). Transgastric endoscopic splenectomy: is it possible? *Surg Endosc*, 20, 3, (Mar 2006), pp. (522-525), ISSN 1432-2218.
- Kantsevov, SV., Hu, B., Jagannath, SB., Isakovich, NV., Chung, SS., Cotton, PB., Gostout, CJ., Hawes, RH., Pasricha, PJ., Nakajima, Y., Kawashima, K. & Kalloo, AN. (2007). Technical feasibility of endoscopic gastric reduction: a pilot study in a porcine model. *Gastrointest Endosc*, 65, 3, (Mar 2007), pp. (510-513), ISSN 0016-5107.
- Kaouk, JH., Haber, GP., Goel, RK., Crouzet, S., Brethauer, S., Firoozi, F., Goldman, HB. & White, WM. (2010). Pure natural orifice transluminal endoscopic surgery (NOTES) transvaginal nephrectomy. *Eur Urol*, 57, 4, (Apr 2010), pp. (723-726), ISSN 0302-2838.
- Keus, F., Gooszen, HG. & van Laarhoven, CJ. (2010). Open, small-incision, or laparoscopic cholecystectomy for patients with symptomatic cholecystolithiasis. An overview of Cochrane Hepato-Biliary Group reviews. *Cochrane Database Syst Rev*, 20, 1, (Jan 2010), p. (CD008318), ISSN 1469-493X.
- Kondo, W., Rangel, M., Tirapelle, RA., Garcia, MA., Bahten, LCV., Laux, GL. & Smaniotto, B. (2006). Emprego da laparoscopia em mulheres com dor abdominal aguda. *Rev Bras Videocir*, 4, 1, (2006), pp. (3-8), ISSN 1983-9901.
- Kondo, W., Noda, RW., Branco, AW., Rangel, M. & Branco Filho, AJ. (2009). Transvaginal endoscopic tubal sterilization. *J Laparoendosc Adv Surg Tech A*, 19, 1, (Feb 2009), pp. (59-61), ISSN 1092-6429.
- Lehmann, KS., Ritz, JP., Wibmer, A., Gellert, K., Zornig, C., Burghardt, J., Büsing, M., Runkel, N., Kohlhaw, K., Albrecht, R., Kirchner, TG., Arlt, G., Mall, JW., Butters, M., Bulian, DR., Bretschneider, J., Holmer, C. & Buhr, HJ. (2010). The German registry for natural orifice transluminal endoscopic surgery: report of the first 551 patients. *Ann Surg*, 252, 2, (Aug 2010), pp. (263-270), ISSN 0003-4932.
- Lima, E., Rolanda, C., Pêgo, JM., Henriques-Coelho, T., Silva, D., Osório, L., Moreira, I., Carvalho, JL. & Correia-Pinto, J. (2007). Third-generation nephrectomy by natural orifice transluminal endoscopic surgery. *J Urol*, 178, 6, (Dec 2007), pp. (2648-2654), ISSN 0022-5347.
- Linke, GR., Tarantino, I., Hoetzel, R., Warschkow, R., Lange, J., Lachat, R. & Zerz, A. (2010). Transvaginal rigid-hybrid NOTES cholecystectomy: evaluation in routine clinical practice. *Endoscopy*, 42, 7, (Jul 2010), pp. (571-575), ISSN 0013-726X.
- Lomanto, D., Chua, HC., Myat, MM., So, J., Shabbir, A. & Ho, L. (2009a). Microbiological contamination during transgastric and transvaginal endoscopic techniques. *J Laparoendosc Adv Surg Tech A*, 19, 4, (Aug 2009), pp. (465-469), ISSN 1092-6429.
- Lomanto, D., Dhir, U., So, JB., Cheah, WK., Moe, MA. & Ho, KY. (2009b). Total transvaginal endoscopic abdominal wall hernia repair: a NOTES survival study. *Hernia*, 13, 4, (Aug 2009), pp. (415-419), ISSN 1265-4906.
- Madan, AK., Tichansky, DS. & Khan, KA. (2008). Natural orifice transluminal endoscopic gastric bypass performed in a cadaver. *Obes Surg*, 18, 9, (Sep 2008), pp. (1192-1199), ISSN 1708-0428.

- Marescaux, J., Dallemagne, B., Perretta, S., Wattiez, A., Mutter, D. & Coumaros, D. (2007). Surgery without scars: report of transluminal cholecystectomy in a human being. *Arch Surg*, 142, 9, (sep 2007), pp. (823-827), ISSN 0004-0010.
- Matthes, K., Yusuf, TE., Willingham, FF., Mino-Kenudson, M., Rattner, DW. & Brugge, WR. (2007). Feasibility of endoscopic transgastric distal pancreatectomy in a porcine animal model. *Gastrointest Endosc*, 66, 4, (Oct 2007), pp. (762-766), ISSN 0016-5107.
- Michalik, M., Orłowski, M., Bobowicz, M., Frask, A. & Trybull, A. (2010). The First Report on Hybrid NOTES Adjustable Gastric Banding in Human. *Obes Surg*, in press, (2010), ISSN 1708-0428.
- Nakajima, K., Takahashi, T., Souma, Y., Shinzaki, S., Yamada, T., Yoshio, T. & Nishida, T. (2008). Transvaginal endoscopic partial gastrectomy in porcine models: the role of an extra endoscope for gastric control. *Surg Endosc*, 22, 12, (Dec 2008), pp. (2733-2736), ISSN 1432-2218.
- Nassif, J., Zacharopoulou, C., Marescaux, J. & Wattiez, A. (2009). Transvaginal extraperitoneal lymphadenectomy by Natural Orifices Transluminal Endoscopic Surgery (NOTES) technique in porcine model: feasibility and survival study. *Gynecol Oncol*, 112, 2, (Feb 2009), pp. (405-408), ISSN 0090-8258.
- Niu, J., Song, W., Yan, M., Fan, W., Niu, W., Liu, E., Peng, C., Lin, P., Li, P. & Khan, AQ. (2010). Transvaginal laparoscopically assisted endoscopic cholecystectomy: preliminary clinical results for a series of 43 cases in China. *Surg Endosc*, in press, (2010), ISSN 1432-2218.
- Noguera, JF., Dolz, C., Cuadrado, A., Olea, JM. & Vilella, A. (2008). Transvaginal liver resection (NOTES) combined with minilaparoscopy. *Rev Esp Enferm Dig*, 100, 7, (Jul 2008), pp. (411-415), ISSN 1130-0108.
- Noguera, J., Dolz, C., Cuadrado, A., Olea, J., Vilella, A. & Morales, R. (2009). Hybrid transvaginal cholecystectomy, NOTES, and minilaparoscopy: analysis of a prospective clinical series. *Surg Endosc*, 23, 4, (Apr 2009), pp. (876-881), ISSN 1432-2218.
- Noguera, JF., Cuadrado, A., Sánchez-Margallo, FM., Dolz, C., Asencio, JM., Olea, JM., Morales, R., Lozano, L. & Vicens, JC. (2010). Emergency transvaginal hybrid natural orifice transluminal endoscopic surgery. *Endoscopy*, in press, (2010), ISSN 0013-726X.
- Nohuz, E., Pouly, JL., Bolandard, F., Rabischong, B., Jardon, K., Cotte, B., Rivoire, C. & Mage, G. (2006). Fertiloscopy: Clermont-Ferrand's experiment. *Gynecol Obstet Fertil*, 34, 10, (Oct 2006), pp. (894-899), ISSN 1297-9589.
- Palanivelu, C., Rajan, PS., Rangarajan, M., Parthasarathi, R., Senthilnathan, P. & Prasad, M. (2008). Transvaginal endoscopic appendectomy in humans: a unique approach to NOTES - world's first report. *Surg Endosc*, 22, 5, (May 2008), pp. (1343-1347), ISSN 1432-2218.
- Park, PO., Bergström, M., Ikeda, K., Fritscher-Ravens, A. & Swain, P. (2005). Experimental studies of transgastric gallbladder surgery: cholecystectomy and cholecystogastric anastomosis (videos). *Gastrointest Endosc*, 61, 4, (Apr 2005), pp. (601-606), ISSN 0016-5107.
- Perretta, S., Allemann, P., Asakuma, M., Dallemagne, B. & Marescaux, J. (2009a). Adrenalectomy using natural orifice transluminal endoscopic surgery (NOTES): a transvaginal retroperitoneal approach. *Surg Endosc*, 23, 6, (Jun 2009), p. (1390), ISSN 1432-2218.
- Perretta, S., Allemann, P., Asakuma, M., Cahill, R., Dallemagne, B. & Marescaux, J. (2009b). Feasibility of right and left transvaginal retroperitoneal nephrectomy: from the

- porcine to the cadaver model. *J Endourol*, 23, 11, (Nov 2009), pp. (1887-1892), ISSN 0892-7790.
- Powell, B., Whang, SH., Bachman, SL., Astudillo, JA., Sporn, E., Miedema, BW. & Thaler, K. (2010). Transvaginal repair of a large chronic porcine ventral hernia with synthetic mesh using NOTES. *JSLs*, 14, 2, (Apr-Jun 2010), pp. (234-239), ISSN 1086-8089.
- Pugliese, R., Forgione, A., Sansonna, F., Ferrari, GC., Di Lernia, S. & Magistro, C. (2010). Hybrid NOTES transvaginal cholecystectomy: operative and long-term results after 18 cases. *Langenbecks Arch Surg*, 395, 3, (Mar 2010), pp. (241-245), ISSN 1435-2443.
- Raman, JD., Bergs, RA., Fernandez, R., Bagrodia, A., Scott, DJ., Tang, SJ., Pearle, MS. & Cadeddu, JA. (2009). Complete transvaginal NOTES nephrectomy using magnetically anchored instrumentation. *J Endourol*, 23, 3, (Mar 2009), pp. (367-371), ISSN 0892-7790.
- Ramos, AC., Murakami, A., Galvão Neto, M., Galvão, MS., Silva, AC., Canseco, EG. & Moyses, Y. (2008a). NOTES transvaginal video-assisted cholecystectomy: first series. *Endoscopy*, 40, 7, (Jul 2008), pp. (572-575), ISSN 0013-726X.
- Ramos, AC., Zundel, N., Neto, MG. & Maalouf, M. (2008b). Human hybrid NOTES transvaginal sleeve gastrectomy: initial experience. *Surg Obes Relat Dis*, 4, 5, (Sep-Oct 2008), pp. (660-663), ISSN 1550-7289.
- Ribal Caparrós, MJ., Peri Cusí, L., Molina Cabeza, A., García Larrosa, A., Carmona, F. & Alcaraz Asensio, A. (2009). First report on hybrid transvaginal nephrectomy for renal cancer. *Actas Urol Esp*, 33, 3, (Mar 2009), pp. (280-283), ISSN 0210-4806.
- Sánchez-Margallo, FM., Asencio Pascual, JM., Del Carmen Tejonero Alvarez, M., Sánchez Hurtado, MA., Pérez Duarte, FJ., Usón Gargallo, J. & Sánchez-Gijón, SP. (2009). Training design and improvement of technical skills in the transvaginal cholecystectomy (NOTES). *Cir Esp*, 85, 5, (May 2009), pp. (307-313), ISSN 0009-739X.
- Sotelo, R., de Andrade, R., Fernández, G., Ramirez, D., Di Grazia, E., Carmona, O., Moreira, O., Berger, A., Aron, M., Desai, MM. & Gill, IS. (2010). NOTES hybrid transvaginal radical nephrectomy for tumor: stepwise progression toward a first successful clinical case. *Eur Urol*, 57, 1, (Jan 2010), pp. (138-144), ISSN 0302-2838.
- Targarona, EM., Gomez, C., Rovira, R., Pernas, JC., Balague, C., Guarner-Argente, C., Sainz, S. & Trias, M. (2009). NOTES-assisted transvaginal splenectomy: the next step in the minimally invasive approach to the spleen. *Surg Innov*, 16, 3, (Sep 2009), pp. (218-222), ISSN 1553-3506.
- Tonouchi, H., Ohmori, Y., Kobayashi, M., Kusunoki, M. (2004). Trocar site hernia. *Arch Surg*, 139, 11, (Nov 2004), pp. (1248-1256), ISSN 0004-0010.
- Sugimoto, M., Yasuda, H., Koda, K., Suzuki, M., Yamazaki, M., Tezuka, T., Kosugi, C., Higuchi, R., Watayo, Y., Yagawa, Y., Uemura, S., Tsuchiya, H., Hirano, A. & Ro, S. (2009). Evaluation for transvaginal and transgastric NOTES cholecystectomy in human and animal natural orifice transluminal endoscopic surgery. *J Hepatobiliary Pancreat Surg*, 16, 3, (2009), pp. (255-260), ISSN 1868-6982.
- Von Ott, D. (1902). Die Beleuchtung der Bauchhöhle (Ventroskopie) als Methode bei Vaginaler Coeliotomie. *Abl Gynakol*, 231, (1902), pp. (817-823).
- Wagh, MS., Merrifield, BF. & Thompson, CC. (2005). Endoscopic transgastric abdominal exploration and organ resection: initial experience in a porcine model. *Clin Gastroenterol Hepatol*, 3, 9, (Sep 2005), pp. (892-896), ISSN 1542-3565.
- Wagh, MS., Merrifield, BF. & Thompson, CC. (2006). Survival studies after endoscopic transgastric oophorectomy and tubectomy in a porcine model. *Gastrointest Endosc*, 63, 3, (Mar 2006), pp. (473-478), ISSN 0016-5107.

- Watrelet, A., Dreyfus, JM. & Andine, JP. (1999). Evaluation of the performance of fertiloscopy in 160 consecutive infertile patients with no obvious pathology. *Hum Reprod*, 14, 3, (Mar 1999), pp. (707-711), ISSN 1460-2350.
- Zacharopoulou, C., Nassif, J., Allemann, P., Dallemagne, B., Perretta, S., Marescaux, J. & Wattiez, A. (2009). Exploration of the retroperitoneum using the transvaginal natural orifice transluminal endoscopic surgery technique. *J Minim Invasive Gynecol*, 16, 2, (Mar-Apr 2009), pp. (198-203), ISSN 1553-4650.
- Zornig, C., Mofid, H., Siemssen, L. & Wenck, CH. (2010a). Transvaginal access for NOTES. *Chirurg*; 81, 5, (May 2010), pp. (426-430), ISSN 1433-0385.
- Zornig, C., Siemssen, L., Emmermann, A., Alm, M., von Waldenfels, HA., Felixmüller, C. & Mofid, H. (2010b). NOTES cholecystectomy: matched-pair analysis comparing the transvaginal hybrid and conventional laparoscopic techniques in a series of 216 patients. *Surg Endosc*, in press, (2010), ISSN 1432-2218.
- Zorrón, R., Filgueiras, M., Maggioni, LC., Pombo, L., Lopes Carvalho, G. & Lacerda Oliveira, A. (2007). NOTES. Transvaginal cholecystectomy: report of the first case. *Surg Innov*, 14, 4, (Dec 2007), pp. (279-283), ISSN 1553-3506.
- Zorrón, R., Soldan, M., Filgueiras, M., Maggioni, LC., Pombo, L. & Oliveira, AL. (2008). NOTES: transvaginal for cancer diagnostic staging: preliminary clinical application. *Surg Innov*, 15, 3, (Sep 2008), pp. (161-165), ISSN 1553-3506.
- Zorron, R., Goncalves, L., Leal, D., Kanaan, E., Cabral, I. & Saraiva, P. (2010a). Transvaginal hybrid natural orifice transluminal endoscopic surgery retroperitoneoscopy--the first human case report. *J Endourol*, 24, 2, (Feb 2010), pp. (233-237), ISSN 0892-7790.
- Zorron, R., Palanivelu, C., Galvão Neto, MP., Ramos, A., Salinas, G., Burghardt, J., DeCarli, L., Henrique Sousa, L., Forgione, A., Pugliese, R., Branco, AJ., Balashanmugan, TS., Boza, C., Corcione, F., D'Avila Avila, F., Arturo Gómez, N., Galvão Ribeiro, PA., Martins, S., Filgueiras, M., Gellert, K., Wood Branco, A., Kondo, W., Inacio Sanseverino, J., de Sousa, JA., Saavedra, L., Ramírez, E., Campos, J., Sivakumar, K., Rajan, PS., Jategaonkar, PA., Ranagrajan, M., Parthasarathi, R., Senthilnathan, P., Prasad, M., Cuccurullo, D. & Müller, V. (2010b) International multicenter trial on clinical natural orifice surgery - NOTES IMTN study: preliminary results of 362 patients. *Surg Innov*, 17, 2, (Jun 2010), pp. (142-158), ISSN 1553-3506.

IntechOpen



Advanced Gynecologic Endoscopy

Edited by Dr. Atef Darwish

ISBN 978-953-307-348-4

Hard cover, 332 pages

Publisher InTech

Published online 23, August, 2011

Published in print edition August, 2011

The main purpose of this book is to address some important issues related to gynecologic laparoscopy. Since the early breakthroughs by its pioneers, laparoscopic gynecologic surgery has gained popularity due to developments in illumination and instrumentation that led to the emergence of laparoscopy in the late 1980's as a credible diagnostic as well as therapeutic intervention. This book is unique in that it will review common, useful information about certain laparoscopic procedures, including technique and instruments, and then discuss common difficulties faced during each operation. We also discuss the uncommon and occasionally even anecdotal cases and the safest ways to deal with them. We are honored to have had a group of world experts in laparoscopic gynecologic surgery valuably contribute to our book.

How to reference

In order to correctly reference this scholarly work, feel free to copy and paste the following:

William Kondo, Anibal Wood Branco, Alcides José Branco Filho, Rafael William Noda, Monica Tessmann Zomer, Lorne Charles, Nicolas Bourdel and Ricardo Zorrón (2011). Transvaginal Natural Orifice Transluminal Endoscopic Surgery (Notes): Surgical Technique and Results, *Advanced Gynecologic Endoscopy*, Dr. Atef Darwish (Ed.), ISBN: 978-953-307-348-4, InTech, Available from: <http://www.intechopen.com/books/advanced-gynecologic-endoscopy/transvaginal-natural-orifice-transluminal-endoscopic-surgery-notes-surgical-technique-and-results>

INTECH
open science | open minds

InTech Europe

University Campus STeP Ri
Slavka Krautzeka 83/A
51000 Rijeka, Croatia
Phone: +385 (51) 770 447
Fax: +385 (51) 686 166
www.intechopen.com

InTech China

Unit 405, Office Block, Hotel Equatorial Shanghai
No.65, Yan An Road (West), Shanghai, 200040, China
中国上海市延安西路65号上海国际贵都大饭店办公楼405单元
Phone: +86-21-62489820
Fax: +86-21-62489821

© 2011 The Author(s). Licensee IntechOpen. This chapter is distributed under the terms of the [Creative Commons Attribution-NonCommercial-ShareAlike-3.0 License](https://creativecommons.org/licenses/by-nc-sa/3.0/), which permits use, distribution and reproduction for non-commercial purposes, provided the original is properly cited and derivative works building on this content are distributed under the same license.

IntechOpen

IntechOpen