

We are IntechOpen, the world's leading publisher of Open Access books Built by scientists, for scientists

6,900

Open access books available

185,000

International authors and editors

200M

Downloads

Our authors are among the

154

Countries delivered to

TOP 1%

most cited scientists

12.2%

Contributors from top 500 universities



WEB OF SCIENCE™

Selection of our books indexed in the Book Citation Index
in Web of Science™ Core Collection (BKCI)

Interested in publishing with us?
Contact book.department@intechopen.com

Numbers displayed above are based on latest data collected.
For more information visit www.intechopen.com



When Cardiac Computed Tomography Becomes the Gold Standard Technique to Evaluate Coronary Artery Disease Patients

Mohamed Bamoshmoosh

*Fanfani Clinical Research Institute, Florence,
Italy*

1. Introduction

Worldwide the health expenditures as a percentage of each national gross domestic product continue to rise. Cardiovascular diseases as part of the noncommunicable disease group, according to the World Health Organization and the most important scientific associations, are growing due to the aging of the population and the increase of cardiovascular risk factors, due to the epidemiologic as well as to the health transition, especially in the developing countries, which account for the majority of the population in the world (Lopez et al., 2006).

In the last few decades we witnessed a proliferation of diagnostic tests to evaluate cardiac heart diseases and in particular coronary artery disease (CAD): exercise stress test, transthoracic echocardiography, stress echocardiography, stress single photon emission computed tomography, myocardial perfusion imaging, magnetic resonance, fractional flow reserve, electron beam computed tomography.

Each diagnostic test, which continuously evolves due to technological improvements, proved to have a high sensibility, specificity and good accuracy in identifying symptomatic as well asymptomatic CAD patients.

All these tests are however unable to give us information about the anatomy of the coronary arteries, which is essential to provide a treatment that goes beyond the medical treatment and in particular when cardiac surgery is needed.

In fact catheter angiography or invasive coronary angiography (ICA), since its introduction in the second half of last century, was the only test able to visualize, in vivo, the coronary tree and to provide images of the coronary artery anatomy upon which both cardiologists and surgeons decide if a patient should be revascularized or medically treated.

With time ICA increased its performance due to the improvement in its software and hardware (quantitative coronary angiography, flat panel digital detectors), and due to the introduction of important tools which can be used routinely like intravascular coronary ultrasound, that for the first time visualized, in vivo, the presence of non calcified plaques and vessel's positive remodeling.

There are other interesting tools that can be associated to ICA, but, for the moment, are the armamentarium of some specialized centers and mainly used for research purposes like elastography, spectroscopy, angioscopy, thermography and optical coherence tomography.

All this data places ICA as the “reference” technique or “gold standard” technique to study the anatomy of coronary arteries.

ICA has been widely employed to validate the results obtained with functional procedures, even though the anatomical findings of ICA are also judged by functional tests (Winchester et al., 2010).

These interdependence of validation shows how a technique, even ICA, cannot be considered the unique “gold standard” technique to study CAD patients. In fact clinicians while studying their patients have to consider more than one question (diagnostic question, prognostic question, therapeutic question) and ICA alone is unable to give an exhaustive answer to all these questions (Mark et al., 2010).

This is the reason why we are in search for technologies to evaluate CAD patients and in particular to study the anatomy of their coronary arteries keeping in mind that these new tests have to be feasible, able to compete with ICA in providing accurate information and, last but not least, economically affordable.

2. Cardiac computed tomography

The introduction of multidetector row systems in the field of computed tomography have made imaging of the heart and in particular that of epicardial coronary arteries feasible. The first and most important force behind the rapid growth of cardiac computed tomography (CCT) imaging in less than a decade is the possibility to obtain information of the anatomy of coronary arteries (Mark et al., 2010).

Since its introduction in the last years of the second millennium, CCT, for the moment, is the only real alternative to ICA able to visualize coronary arteries and most interestingly to obtain this information non-invasively.

Both CCT and ICA visualize only the epicardial vessels, which are also the ones that are usually treated by surgical or percutaneous revascularization procedures.

There are also other factors which may indicate the use of CCT instead of ICA.

There is a significant number of patients who perform ICA (10-20% of the patients) who have normal coronary arteries. Moreover not all patients who have a diseased coronary artery at the ICA should undergo catheter based or surgical based revascularization procedures. For a significant number of patients in whom ICA demonstrates the presence of some degree of CAD it is enough to introduce or change the medical treatment associated with life-style modifications. For this wide group of patients having a non-invasive way to visualize coronary arteries would be preferable to the invasive one, and for them ICA cannot be considered the real “gold standard” technique. On the other side there is an unacceptable high percentage (2%-8%) of patients with acute coronary syndromes who are discharged from the emergency department without a correct diagnosis and who may benefit from a CCT examination (Hoffmann et al., 2006).

There are also other disadvantages in ICA procedures that could be avoided if instead CCT is performed.

The first group of disadvantages is related to the so called major adverse events that occur within the first 24 hours after selective coronary angiography procedures although they have a relatively low incidence, which ranges between 0.2 to 0.3% and is related to the invasiveness of the procedure itself. The catheter during its movement inside the cardiovascular system may cause the rupture of an atherosclerotic plaque and a dislodgment of an embolus to the heart, brain or abdomen causing respectively a

myocardial infarction, stroke or intestinal infarction. All these complications can be resolved, if correctly addressed, but sometimes may cause a severe morbidity and even the death of the patient.

There are also the so called minor complications present in all the hemodynamic laboratories, although their incidence is higher in smaller laboratories and with less skilled operators. The incidence of the minor complications is relatively high, roughly between 1% to 2%. Most of these minor complications are related to problems with the peripheral vessels through which catheters are inserted like dissection of the femoral artery, arteriovenous fistulas, groin and retro-peritoneal haematomas which may lead to severe anaemization, prolonged morbidity and may require surgery to be solved (Bluemke et al., 2008).

There are also other important limits that must be considered while using CCT, that the evolving technologies are trying to overcome. One of these limits, still present with the currently available 64 channel systems, is related to patient's heart rate which must be rhythmic and around or less than 60-64 beats per minute. Patients with atrial fibrillation or with a heart rate that can not be reduced pharmacologically with beta-blockers to the rate of 60-64 beats per minute, for the moment, are not eligible to undergo this kind of examination. The introduction of some new tools like the "tube current modulation" and the "step and shoot" procedures and the 128, 256, 320 channel scanners will offer the possibility to study also patients with higher heart rates and with atrial fibrillation, making it possible to image the entire heart not only, as it is now, in a single breath hold, but in a single heartbeat. Moreover performing CCT in patients with high body mass index or with chronic obstructive pulmonary disease may add some additional technical problems (Mark et al., 2010).

Finally it is worth noting that both ICA and CCT use non-ionic contrast medium to visualize coronary artery lumen. For this reason particular attention must be given in allergic patients who may develop anaphylactoid reactions and especially in patients with a pre-existing renal impairment which is the major risk factor for the development of contrast medium-induced nephropathy. Contrast medium-induced nephropathy is associated with adverse outcomes including higher mortality. For these reasons patients before CCT should be screened by noting their baseline serum creatinine, presence of comorbidities and by ensuring adequate hydration before and after contrast exposure (Mark et al., 2010).

3. Cardiac computed tomography and patients with suspected coronary artery disease

The most interesting indication for CCT to the public and physicians is the possibility to evaluate patients with suspected CAD who highly outnumber those who were already diagnosed to have CAD or those who underwent surgical or percutaneous revascularization procedures. The 64 or more channel CCT systems are currently considered adequate to study symptomatic as well as asymptomatic patients suspected to have CAD (Taylor et al., 2010).

In patients with suspected CAD, CCT non-invasively provides important information about coronary calcium scoring, left ventricular function and coronary artery anatomy. However while calcium scoring can be obtained also with electron beam computed tomography, left ventricular function can be assessed also with echocardiography, magnetic resonance and myocardial perfusion imaging, coronary artery anatomy, besides ICA, can be evaluated only with CCT.

In a recent meta-analysis CCT compared to ICA had an average sensitivity and specificity of 98% and 91% respectively, to detect/exclude significant stenosis on a patient basis (Abdulla et al., 2007).

The majority of the studies performed with CCT has been done to determine its role in the assessment of patients with suspected CAD by comparing it with the “anatomic” test (ICA) or/and “functional” tests like stress echocardiography, single emission computed tomography, myocardial perfusion imaging or fractional flow reserve.

Till now there are no large scale studies to evaluate the predictive value of the results obtained with CCT. Nevertheless while a negative CCT rules out significant CAD (negative predictive value between 98 and 100% in most studies) a positive CCT test does not have a similar high positive predictive value (93% with a range from 64% to 100%) due to the tendency of this test to overestimate disease severity in small, distal and calcified vessels. This is the reason why CCT is considered an “ideal test” to study patients who have a low or intermediate pre-test probability to have hemodynamically relevant coronary artery stenosis. In those with high pre-test probability to have significant coronary stenosis, the clinical benefit of CCT decreases with the increased probability to have a treatment through surgical or percutaneous revascularization procedures (Achenbach, 2006, Schuijff et al., 2011).

In the recent American Appropriate Use Criteria Task Force for CCT, the use of CCT in the detection of CAD in symptomatic as well as asymptomatic patients with low and intermediate pretest probability to have CAD, was pointed to be appropriate (i.e. the test is acceptable and considered a reasonable approach to study the disease and its expected incremental information, combined with clinical judgment exceeds the expected negative consequences by a sufficiently wide margin) with a quite high appropriateness score (between 7 and 8 out of the highest value of 9; an indication to be appropriate had to have a score from 7-9) (Taylor et al., 2010).

3.1 Cardiac computed tomography and invasive coronary angiography

The published literature in which CCT's ability to evaluate coronary artery anatomy, compared to ICA, in patients suspected to have CAD, although applied in high quality studies in selected subjects and interpreted by experts, has a high diagnostic accuracy, but probably may not reflect its real use in the daily clinical practice. In most of the published papers CCT has an overall high sensitivity and specificity both on a per-patient and on a per vessel basis for the presence of more than 50% obstructive lesions.

Invasive coronary angiography in evaluating coronary arteries is still considered the “gold standard” or “reference standard” technique mainly because in more than 50 years experience it provided an extensive evidence of its value in patient management and because it has, for the moment, the highest spatial (<0.16 mm vs approximately 0.4 mm of CCT) and temporal resolution (33 msec. vs 140 to 200 msec. of the recent cardiac computed systems or 83 msec. of the dual source system). It is however worth noting that ICA visualizes coronary arteries by creating only a limited number of 2D coronary luminograms, whereas CCT gives an unlimited number of 2D reformatted images as well as 3D volume-rendered images from transverse reconstructions that can rule out eccentric lesions that are difficult to be studied by traditional invasive angiography (Mark et al., 2010)

Invasive coronary angiography estimates the coronary artery severity as a percent diameter stenosis by comparing the narrowing of the lumen of the vessel with the adjacent segment,

which arbitrarily is considered normal, while it could have a non-visualized, non calcified, eccentric plaque. This visual procedure to estimate lesions has a high degree of intra and inter-observer variability that can be somehow reduced by a computer assisted interpretation (quantitative coronary angiography).

Cardiac computed tomography on the other hand is, and in the future probably will be able to provide more information not currently available from ICA, and this may be the basis for its more extensive use in patients with suspected CAD. Invasive coronary angiography can visualize the first stages of the atherosclerotic process (vessel's positive remodeling and the presence of non calcified plaques) only if it is performed using expensive and specialized tools like intravascular ultrasound and optical coherence tomography. All this information is already available with CCT and helps to understand the atherosclerotic burden of CAD patients "better" than with ICA.

Although CCT provides images of the plaque both internal and external to the lumen helping in having a more precise evaluation of lumen narrowing, its ability in assessing the real vessel stenosis has still some technical limits. In fact in the presence of calcified lesions, especially in small and distal vessels, CCT tends to overestimate lesion severity because of the "blooming effect", which is related to the X-rays not absorbed by the calcified lesion that during image reconstruction causes the lesion to seem bigger than it actually is (Ropers et al., 2006a).

Another important limit of CCT is related to the fact that less than or equal to 5% of patients have a non-valuable scans due to motion artefacts, because the patient cannot follow breathing commands, involuntary motion of the diaphragm or to arrhythmias occurring during the CCT scan. To study the coronary anatomy of these patients ICA must be performed.

3.2 Cardiac computed tomography and functional tests

Although CCT was introduced to provide information regarding the anatomy of coronary arteries as an alternative procedure to ICA, it is also possible to compare its results with those obtained with functional tests. The utility in performing such comparison is to evaluate if CCT has a similar or superior accuracy than functional tests in the characterization of patients with suspected CAD. In doing so it is however necessary to keep in mind that, as with ICA, functional tests are often not concordant with the results of CCT because they consider different parameters. Cardiac computed tomography allows the detection of atherosclerotic plaques, that may be hemodynamically non significant resulting in a negative functional test, while a positive functional test may be present in a patient with normal epicardial coronary arteries, but with diseased coronary microcirculation able to produce clinically significant ischemia.

When CCT was compared to dobutamine stress echocardiography the positive and negative likelihood ratios for dobutamine stress echocardiography were 4.37 and 0.36 compared with 3.5 and 0.11 for coronary computed tomography respectively (Nixdorff et al., 2008).

Several studies have been performed comparing both CCT and stress myocardial perfusion imaging to ICA. Cardiac computed tomography proved to have a higher sensitivity and specificity than myocardial perfusion imaging (respectively 94% vs 81% and 96% vs 78%; Budoff et al., 2007).

When CCT was compared to fractional flow reserve, which is considered the reference standard for hemodynamically significant obstructive disease, it was found that the sensitivity and specificity of CCT for fractional flow reserve-defined hemodynamically significant lesions were 94% and 40% respectively (Gaemperli et al., 2007).

3.3 Cardiac computed tomography and patients with acute chest pain

The performance of CCT was also tested in specific environments such as the emergency department, comparing it with functional tests as well as combined clinical and marker data. The results obtained from these studies show that a negative CCT exam improves the diagnostic accuracy in ruling out subjects with a low risk to have acute coronary syndromes. Goldstein et al. (Goldstein et al., 2007) found that CCT compared to myocardial perfusion imaging in addition to standard care had a reduced diagnostic time (3.4 h vs 15.0 h; $p < 0.001$) and lower costs (\$1586 vs \$1872; $p < 0.001$) while no adverse cardiovascular events occurred in either group after 6 months of follow-up. On the other side according to Hadamitzky et al. finding an obstructive CAD on CCT at the emergency department is associated with an odd ratio of 17.3 to have severe cardiac events (cardiac death, myocardial infarction or unstable angina) while in patients without CAD at the CCT the rate of cardiac events is better predicted than with the Framingham risk score (Hadamitzky et al., 2009).

4. Cardiac computed tomography and anomalous coronary arteries

Invasive coronary angiography provides only a 2D view of the coronary arteries and sometimes fails to clearly visualize the relationship between coronary vessels and the surrounding structures. This issue becomes critical when anomalous coronary arteries must be visualized. Moreover, it is not always easy to selectively engage the anomalous coronary vessel, which may lead to the erroneous assumption that the coronary vessel is occluded. In addition, the declining use of pulmonary artery catheters during the routine invasive angiography procedures has made it more difficult to understand the course of the coronary vessels within the heart and discern the anterior versus the posterior direction of the anomalous vessels.

Congenital coronary artery anomalies are rare and occur in 0.17% of the autopsy cases. The incidence of anomalous origin of the coronary vessels is higher in the population of patients referred for ICA (0.6–1.3%). Although anomalous coronary vessels lack clinical significance in the majority of patients, there are some “malignant” anomalies that may cause non-fatal or fatal acute myocardial infarction or sudden death, especially in young athletes without atherosclerotic CAD (Angelini et al, 2002). In older patients, both CAD and coronary vessel anomalies may be present and in these cases it is difficult to clarify the exact mechanism of myocardial ischemia.

In the last few years, several studies showed the usefulness of the non-invasive modalities for the detection of coronary vessel anomalies such as magnetic resonance imaging and especially multidetector computed tomography. Magnetic resonance imaging, as it is free from X-radiations would be preferable to multidetector computed tomography, especially for younger patients in whom an anomalous artery origin is suspected, and in those who have a cardiac anomaly which may be associated with coronary vessel anomalies (i.e. tetralogy of Fallot) or in patients who have to be followed for the presence of coronary artery aneurysms like in the Kawasaki disease (Mark et al, 2010).

Although there are multiple published series of patients who underwent comparison of coronary magnetic resonance angiography with ICA with a quite good accuracy, CCT due to its excellent spatial resolution, which allows an excellent detection of the origin of the coronary vessels and visualizes their course within the heart, is the real alternative to invasive angiography (Cademartiri et al., 2007) and sometimes it can be considered the real “gold standard” technique in studying the anomalous coronary arteries. In fact in the recent

American Appropriate Use Criteria Task Force for CCT, the use of CCT in the “assessment of anomalies of coronary arterial and other thoracic arteriovenous vessels” was pointed to be the most appropriate indication (score 9 out of 9) (Taylor et al., 2010).

5. Cardiac computed tomography and cardiac bypass surgery

Another indication for CCT is to follow up patients who performed coronary artery by-pass grafting. This was indeed the first clinical application of CCT. In fact arterial as well venous by-passes are easier to be studied than epicardial coronary arteries because they are bigger vessels (typically 2 to 4 mm), have lower motion and usually not calcified.

By-passes have been evaluated beginning with the 4 slice CCT with good results (Moore et al., 2005) and now with the latest generation of CCT systems their accuracy is very high (Stein et al., 2008).

There are however several difficulties in the assessment of by-passes related to the presence of artifacts caused by metal clips, especially when they are at the level of the distal anastomotic site where there can be found also calcified lesions and the grafts have a greater motion.

Cardiac computed tomography has a good accuracy in assessing graft occlusion; the sensitivity, specificity and accuracy of CCT for detection of bypass occlusion in studies performed with 16-slices computed tomography was respectively of 97%, 100% and 99% (Martuscelli et al., 2004) and in the most recent meta-analysis on the diagnostic accuracy of the 64-channel CCT the sensibility and specificity in the detection of graft occlusion calculated on a per-graft rather than a per-patient basis were respectively 97% and 100% (Stein et al., 2008).

Cardiac computed tomography's accuracy in assessing graft stenosis is however lower and reduces the overall specificity to 97% while the overall sensitivity remains almost unchanged (98%). The latest generation CCT systems have a positive likelihood ratio above 10 and a negative likelihood ratio of 0.02 which leads to a very high positive predictive value and especially a very high negative predictive value compared with traditional ICA indicating that CCT can rule out or rule in graft disease with a very high accuracy (Stein et al., 2008).

It is however important to consider that assessing the native coronary arteries downstream from the grafts and in the un-grafted segments in patients in whom in the meantime CAD may have progressed, can be very challenging since these vessels tend to be small and sometimes heavily calcified (sensitivity 86%, specificity 76% and accuracy 78%) (Ropers et al., 2006b).

In the recent American Appropriate Use Criteria Task Force for CCT the use of CCT in the “evaluation of graft patency after cardiac surgery” was pointed to be appropriate with a high indication score (8 out of the highest value of 9) (Taylor et al., 2010).

Another issue is related to the area that must be studied during CCT examination. While patients who did not perform a coronary bypass are studied from the level of the carina to the diaphragm, those who have performed a bypass surgery should be studied from the level of the aortic arch and sometimes even from the clavicle in case we want to study the origin of the internal mammary arteries. Nevertheless CCT is preferred by patients because it is considered “non-invasive”, even if it needs a greater amount of contrast medium and greater amount of radiation. In fact patients who performed bypass surgery have already experienced a pre-operative ICA, cardiac surgery and sometimes, after the cardiac bypass surgery, a second or third diagnostical and/or interventional ICA.

There are some cases where CCT could be considered the “gold standard” technique to follow-up patients who underwent bypass surgery. These patients are those who underwent a gastroepiploic bypass to the posterior descending coronary artery. It is easier to study the gastroepiploic bypass with CCT rather than performing a challenging ICA, which may need a great amount of contrast medium and a great amount of radiation (Ropers et al., 2006b).

Cardiac computed tomography can be also the “ideal technique” in planning the re-do cardiac bypass surgery patients as it provides the exact relationship between the intra-thoracic organs and the chest wall (spatial relationship between grafts, epicardial coronary arteries, right ventricle and sternum) (Mark et al., 2010).

Another field in which CCT could be used is that of patients who have to undergo cardiac bypass surgery. Cardiac computed tomography, unlike ICA, does not explore the coronary circulation dynamically and is unable to provide information regarding the direction of the blood inside the vessel and, because of its limited spatial resolution, is unable to detect the presence of homo and/or hetero coronary collateral circulation, which is very important to characterize patients with CAD and is useful in deciding their management. This information however is not always essential for the surgeon. In fact although CCT does not supply the surgeon with images showing the presence and direction of collateral circulation in most of the cases, it clearly indicates if the vessels after the stenosis or occlusion are pervious and could be grafted. Having preoperatively clear images of the diseased vessels for the presence of calcified or soft plaques is also useful for the surgeon to decide where to perform the anastomosis. Moreover, the study of the wall-thickness changes over the cardiac cycle obtained with CCT may guide both surgeons and interventional cardiologists to decide the real necessity for the revascularization and could help to avoid sudden decisions during ICA procedures for patients who may benefit more from cardiac bypass surgery rather than percutaneous interventions (Bamoshmoosh et al., 2008).

Recently some published papers hypnotized that CCT could be judged enough to decide if a patient can be directly sent to perform bypass cardiac surgery without confirming CCT results with traditional ICA. In fact the information obtained with CCT supplies the surgeon with a virtual 3D images showing the diseased vessel and help in pre-planning the length of the required conduit. This can be of great importance especially in off pump and in minimally invasive surgery.

In a recent interesting prospective clinical trial, CCT was compared to conventional coronary angiography to evaluate if CCT alone was adequate for proceeding in cardiac bypass surgery without coronary angiography. In this study 50 patients with proven severe CAD underwent CCT and ICA prior to cardiac bypass surgery. CCT images were compared with those of ICA for the accuracy, sensitivity and specificity in detecting significant stenosis. An excellent correlation was found between ICA and CCT results. The overall sensitivity, specificity, positive and negative predictive values for quantitative assessment of stenosis > 70% by CCT compared to ICA were 98.5 %, 99.1 %, 82.3 % and 99.8%, respectively. The Authors conclude that the improved spatial and temporal resolution of the 64 row scanners provided an excellent correlation of CCT with ICA, and in selected patients, they even recommend the consideration of CCT as a sole criteria for proceeding in cardiac bypass surgery without coronary angiography (Bedi et al., 2008).

These interesting results that indicate a possible future use of CCT not only complementary but also as an alternative to ICA in the flow chart in the evaluation of CAD patients prior to cardiac bypass surgery needs however to be further analyzed in multi-centric interdisciplinary studies.

6. Cardiac computed tomography and prior coronary stenting

The evaluation of coronary stents by CCT is challenging because there are important technical limitations related to the presence of the metal in the stent struts that cannot be completely bypassed by “convolution algorithms”. The metal present in the stent absorbs the lower-energy portion of the X-ray beam leaving the not absorbed X-rays to reach the detector realising what is called the “blooming artefact”, that causes the stent struts to appear thicker than they actually are and to produce also the “partial volume averaging” which is an artefact that affects the voxels immediately adjacent to the stent struts. During the reconstruction of the images both the “blooming artefact” and the “partial volume averaging” produced by the stent, associated with the eventually “blooming artefact” of the calcified plaque beneath the stent, interfere with the ability to assess the presence of in-stent restenosis and in general to evaluate if and how much the vessel is diseased (Mark et al., 2010)

All these data led the American Heart Association to consider in 2006 statement CCT non advisable to study patients with prior coronary stenting (class III with a level of evidence C) (Budoff et al., 2006).

However stents are not to be considered as equivalent because they have different metal composition, different designs and more importantly different sizes. With the new generation CCT systems the indication changed and stents 3.5 mm or larger are now judged 100% assessable. The ability to evaluate in stent restenosis reduces to 80% in the 3 mm stents and to 33% in the smaller stents (Sheth et al., 2007). Thus in a patient with a known large stent, like those in the left main, CCT could be considered a real alternative to ICA to rule out significant in-stent restenosis. In fact in the recent American Appropriate Use Criteria Task Force for CCT the use of CCT in the “risk assessment in asymptomatic patients with prior left main coronary stent with stent diameter ≥ 3 mm ” was pointed to be appropriate with a high indication score (7 out of the highest value of 9) (Taylor et al, 2010).

Moreover as it is pointed by the writing group of the American Appropriate Use Criteria Task Force for CCT the 2010 appropriateness criteria reflect the actual most common clinical scenarios, keeping in mind that from the 2006 appropriateness criteria to those of 2010 some indications shifted up 1 category from either uncertain to appropriate and from inappropriate to uncertain (Taylor et al, 2010). The increasing amount of published papers with the most advanced computed tomography machines indicate the usefulness of CCT in the daily work to rule out or to rule in the presence of in-stent restenosis of CAD patients who may have performed several diagnostical and/or interventional coronary angiography procedures and ask for CCT instead of ICA (Sun & Almutairi, 2010). In the daily experience both patients and their physicians more and more frequently ask for an alternative to ICA at least at the time of the characterization of the CAD and want to have the opportunity to choose off-line the therapeutical decision.

This is the reason why the writing group of the American Appropriate Use Criteria Task Force for CCT do not believe that an uncertain rating must be used as a reason to deny reimbursement for CCT imaging, but consider that in these cases additional documentations have to be presented to justify reimbursement (Taylor et al, 2010).

7. Cardiac computed tomography and radiation dose

Since the introduction of CCT in the clinical practice the dose of radiation delivered to patients during the exams is the most often discussed drawback, because it has been

considered a critical safety issue, especially when besides CCT, ICA and/or stress myocardial perfusion imaging have to be performed. In the commonly used CCT systems the amount of radiation, expressed as units of millisieverts (equivalent to millijoules per kilogram of tissue), absorbed by patients during the test is 2-4 folds that of ICA (Mark et al., 2010). The introduction of improvements in CCT technologies like the “ECG-controlled tube-current modulation” and the “step and shoot” protocols, which use a prospective gating and predict when diastole will occur, decrease x-ray tube current during systole leading to a significant reduction of the radiation dose from about 18 millisieverts to less than 4 millisieverts, which is almost equal to that of traditional coronary angiography (Scheffel et al., 2008; Hausleiter et al., 2006). As with ICA patient radiation dose is directly correlated with cardiac tomography equipment, practice and experience of the center where the CCT is performed and patient related factors like patient weight and heart rate.

If it is difficult to ascertain the developing of malignancy as a consequence of a biologic damage due to radiation in adults, the population most likely studied with CCT. Nevertheless as a consequence of a good clinical practice CCT must be performed only when its indication is appropriate (see the 2010 appropriateness criteria of the American Appropriate Use Criteria Task Force for CCT) and if patient’s diagnostic question cannot be adequately addressed by other investigations (Taylor et al., 2010).

8. Illustrative case

The patient is a 63-year-old man who was in treatment for arterial hypertension (Amlodipine 10 mg, Ramipril 10 mg and Furosemide 25 mg) and hyperlipidemias (Atorvastatin 10 mg). In 2000 he was operated for an adenoma of the adrenal cortex. In 2004 for a “type A” aortic dissection, in extra-corporeal circulation, he underwent prosthesis implantation (26 mm).

The patient was doing fine till June 2006 when he began to suffer of chest pain associated with dyspnoea. For this reason he performed a maximal treadmill stress test which was positive by electrocardiographic criteria (2.5 mm ST depression in lead V4-V6) and typical effort chest pain.

The patient was sent to perform ICA. The test, which was performed through a femoral approach, was however unable to selectively catheterize the right coronary artery and a severe left main and left anterior descending CAD were suspected. The indication given to the patient by the interventional cardiologist was to undergo bypass surgery.

However, in such a complex patient, the surgeon wanted to have a complete anatomical description of the coronary tree and the aorta to better pre-plan the surgical intervention and asked for a CCT test.

Cardiac computed tomography was performed with 64-slice multidetector computed tomography Brilliance scanner (Philips, USA) by administering 100 ml of iodinated contrast medium (Iomeron 400 mg/dl, Bracco Imaging, Milano, Italia) at a rate of 5 ml/s through a 18 gauge cannula placed in the antecubital vein.

To reduce patient’s heart rate, 30 minutes before the test he was given 100 mg of Metoprolol per os. Cardiac computed tomography provided images which were judged of good quality and both right and left coronary arteries were correctly visualized (Fig. 1).

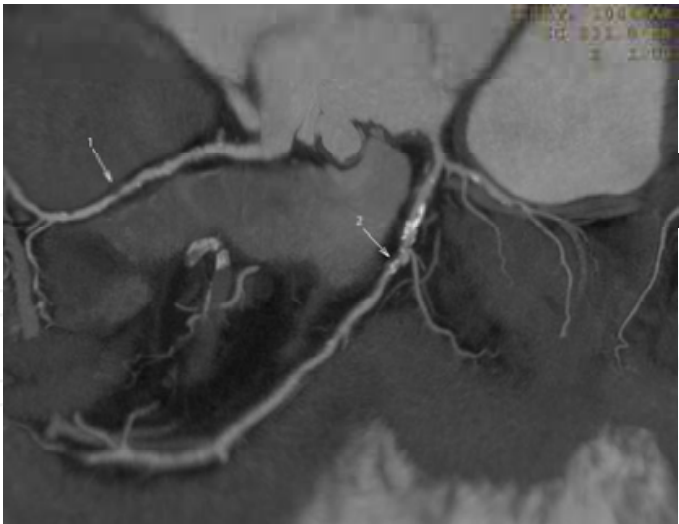


Fig. 1. 2D map in which in the middle segment of the right coronary artery (arrow n°1) there is a non calcified plaque (50% stenosis) and in the middle segment of the left anterior descending coronary artery (arrow n°2) a mixed plaque (50-75% stenosis).

Right coronary artery was the dominant vessel; in the proximal segment there were small, mixed, non critical lesions; in the middle segment there was a non calcified plaque that produced a 50% stenosis; no lesions were seen in the distal segment and in the posterior descending coronary artery (Fig. 2).

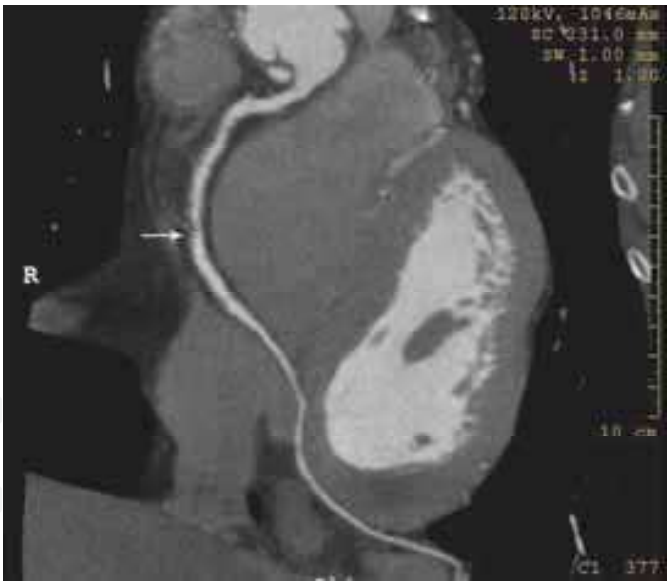

Fig. 2. Multiplanar reconstructed image of the right coronary artery and posterior descending coronary artery: in the middle segment (arrow) there is a non calcified eccentric plaque (50% stenosis).

The left main had a non calcified lesion which caused less than 20% stenosis. The left anterior descending coronary artery had in the proximal segment a non significant lesion followed in the middle segment by a mixed stenosis that caused a critical 50-75% stenosis; no lesions were seen in the distal segment and in the diagonal branches (Fig. 3 A). No significant lesions were seen in the circumflex coronary artery (Fig. 3 B).

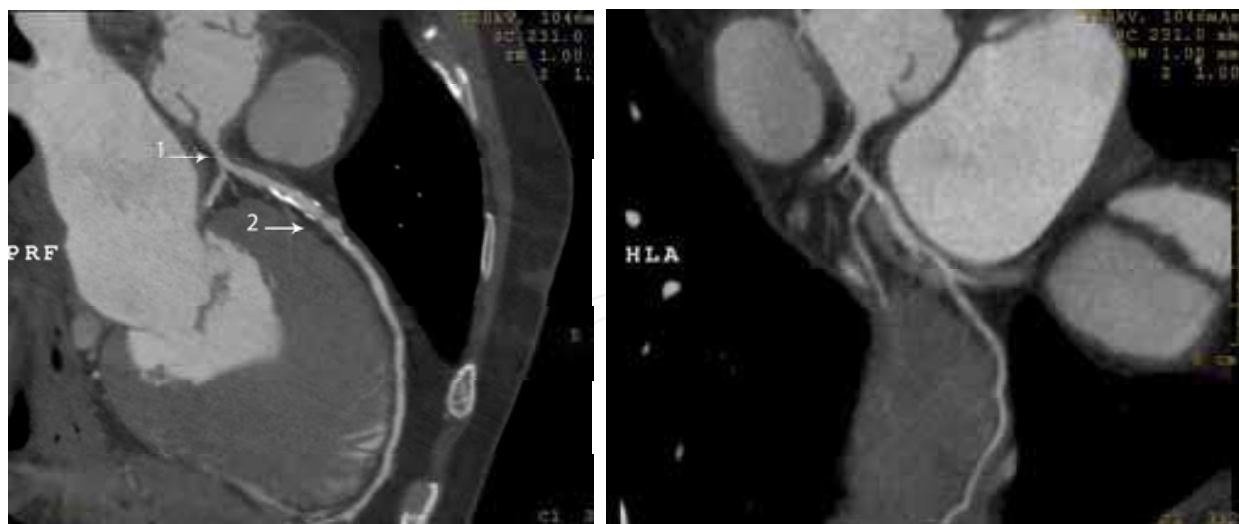


Fig. 3. Multiplanar reconstructed image of the left coronary artery. In A the left main (arrow n°1) has a non calcified lesion (20% stenosis); in the middle segment of left anterior descending coronary artery (arrow n°2) there is a mixed, eccentric lesion (50-75% stenosis). In B there are no significant lesions in the circumflex artery.

However more interestingly CCT showed also a severe aortic dissection due to a rupture of an intimal flap ahead of the ascending aorta prosthesis from where the false lumen was supplied (Fig. 4)

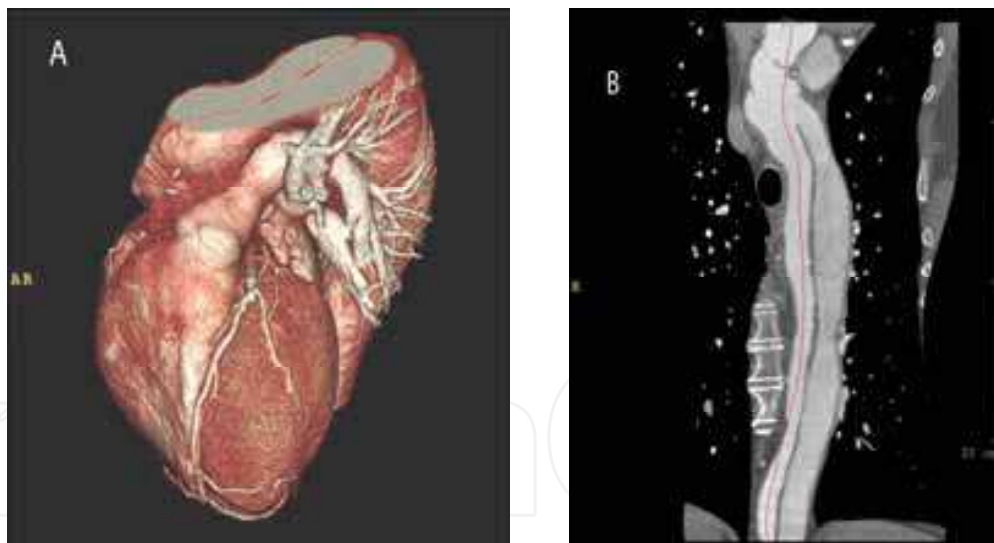


Fig. 4. Volume rendering image of the heart and aorta (A) and lumen image of the aorta (B) where the aortic dissection with the true and false lumen are visible.

In this case ICA was unable to visualize coronary arteries because the catheters during the exam were engaging the false lumen due to the presence of the aortic dissection. CCT on the other side was very useful as it was the only test that provided the correct anatomical view of the coronary tree. Moreover CCT indicated the presence of a severe aortic dissection in a patient already treated for “type A” aortic dissection.

In this case CCT was also a very useful test for the surgeon to pre-plan the operation. In fact the patient underwent a second extra-corporeal circulation surgery for a radical aortic

replacement employing simultaneous modified Bentall and elephant trunk procedure and a coronary artery bypass surgery for the anterior descending coronary artery using the left internal mammary artery. At the 2 year follow up the patient was doing fine.

9. Conclusion

Invasive coronary angiography is an indispensable test to evaluate coronary arteries and in more than a half century experience it proved to be extremely reliable in the diagnostical as well therapeutical processes of CAD patients. For this reason it is considered the “gold standard” or “reference standard” technique upon which we compare the results of the other cardiac exams. However ICA is not always the most appropriate test with which we can evaluate CAD patients. The introduction in the cardiac arena of CCT, that with very good accuracy investigates coronary arteries, provided us with a complementary and sometimes an alternative test to ICA. In particular settings that can range from quite simple cases (identification of a coronary artery with an anomalous origin) to very complex cases (need to pre-plan a re-do bypass surgery), or that of the patient of the illustrative case it can be even considered the “real gold” standard technique. However to better understand the real usefulness of CCT and correctly allocate it in the flow chart of the evaluation of CAD patients more experience must be gained by routine users, further multi-centric interdisciplinary studies must be performed till the production of approved clinical practice guidelines.

10. Acknowledgments

I gratefully thank the radiology team of Fanfani Clinical Research Institute and in particular Dr. F. Fanfani for their support, Dr. G. Fradella for the clinical evaluation of the patient in the illustrative case and Dr. H. Alsakkaf for the assistance with the manuscript.

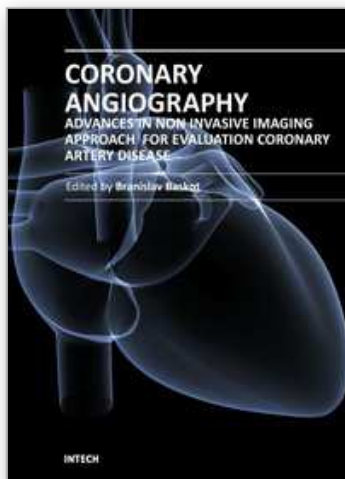
11. References

- Abdulla, J.; Abildstrom, SZ. ; Gotzsche, O. ; Christensen, E. ; Kober, L. & Torp-Peterson C. (2007). 64-multislice detector computed tomography coronary angiography as potential alternative to conventional coronary angiography: a systematic review and meta-analysis. *Eur Heart J* Vol.28, No.24, (December 2007) pp. 3042-50, ISSN 0195-668X
- Achenbach, S. (2006). Computed tomography coronary angiography. *Journal of the American College of Cardiology*, Vol.48, No.210, (November 21 2006), pp. 1919-28, ISSN 0735-1097
- Angelini, P.; Velasco, JA. & Flamm, S. (2002) Coronary anomalies: incidence, pathophysiology and clinical relevance. *Circulation*, Vol.105, No.20, (May 21 2002), pp. 2449-2454, ISSN 1524-4539
- Bamoshmoosh, M. ; Fanfani, F. & Carusi, LM. (2007). Could MDCT be enough to send a patient with left main and tree vessel coronary artery disease to surgery? *European Journal of Radiology Extra*, Vol. 65, No.3, (March 2008), pp. 87-89, ISSN 1571-4675
- Bedi, HS.; Gill, JA. & Bakshi, SS. (2008). Can we perform coronary artery bypass grafting on the basis of computed tomographic angiography alone? A comparison with

- conventional coronary angiography. *Eur J Cardiothorac Surg*, Vol.33, No.4, (April 2008), pp. 633-8 ISSN 1010-7940
- Bluemke, DA.; Achenbach, S.; Budoff, M.; Gerber, TC.; Gersh, B.; Hills, D.; Hundley, G.; Manning, WJ.; Printz, BF.; Stuber, M. & Woodard, PK. (2008). Noninvasive coronary artery Imaging: magnetic resonance angiography and multidetector tomography angiography. *Circulation*, Vol.118, No.21, (July 29, 2008), pp. 586-606, ISSN 1524-4539
- Budoff, MJ.; Achenbach, S.; Blumenthal, RS.; Carr, JJ.; Goldin, JG.; Greenland, P.; Guerci, AD.; Lima, JAC.; Rader, DJ.; Rubin, GD.; Shaw, LJ. & Wieggers, SE. (2006). Assessment of Coronary Artery Disease by Cardiac Computed Tomography. *Circulation*. Vol.114, No.16, (October 17 2006), pp. 1761-1791, ISSN 1524-4539
- Budoff, MJ.; Rasouli, ML.; Shavelle, DM.; Gopal, A.; Gul, KM.; Mao, SS.; Liu, SH. & McKay, CR. (2007). Cardiac CT angiography and nuclear myocardial perfusion imaging: a comparison in detecting significant coronary artery disease. *Acad Radiol*, Vol.14, No.3, (March 2007), pp. 252-57, ISSN 0284-1851
- Cademartiri, F.; Malagò, R.; La Grutta, L.; Alberghina, F.; Palumbo, A.; Maffei, E.; Brambilla, V.; Pugliese, F.; Runza, G.; Midiri, M.; Mollet, NR. & Krestin, GP. (2007). Coronary variants and anomalies: methodology of visualisation with 64-slice CT and prevalence in 202 consecutive patients. *Radiol Med*, Vol.112, No.8, (December 2007), pp. 1117-31
- Gaemperli, O.; Schepis, T.; Valenta, I.; Husmann, L.; Scheffel, H.; Duerst, V.; Eberli, FR.; Luscher, TF.; Alkadhi, H. & Kaufmann, PA. (2007). Cardiac image fusion from stand-alone SPECT and CT: clinical experience. *JNuc Med*, Vol.48, No.5, (July 2007), pp. 696-705
- Goldstein, JA.; Gallagher, MJ.; O'Neill, WW.; Ross, MA.; O'Neil, BJ. & Raff, GL. (2007). A randomized controlled trial of multi-slice coronary computed tomography for evaluation of acute chest pain. *Journal of the American College of Cardiology*, Vol.49, No.8, (February 27 2007), pp. 863-71, ISSN 0735-1097
- Hadamitzky, M.; Freissmuth, B.; Meyer, T.; Hein, F.; Kastrati, A.; Martinoff, S.; Schömig, A. & Hausleiter, J. (2009). Prognostic value of coronary computed tomographic angiography for prediction of cardiac events in patients with suspected coronary artery disease. *JACC Cardiovasc Imaging*, Vol.2, No.4, (April 2009), pp. 404-411, ISSN 1936-878X
- Hausleiter, J.; Meyer, T.; Hadamitzky, M.; Huber, E.; Zankl, M.; Martinoff, S.; Kastrati, A. & Schömig, A. (2006). Radiation dose estimates from cardiac multislice computed tomography in daily practice: impact of different scanning protocols on effective dose estimates. *Circulation*, Vol.113, No.10, (March 14 2006), pp. 1305-10, ISSN 1524-4539
- Hoffmann, U.; Nagurney, JT.; Moselewski, F.; Pena, A; Ferencik, M.; Chae, CU.; Cury, R.; Butler, J.; Abbara, S.; Brown, DF.; Manini, A.; Nichols, JH.; Achenbach, S. & Brady, TJ. (2006). Coronary multidetector computed tomography in the assessment of patients with acute chest pain. *Circulation*, Vol.114, No.21, (November 21 2006), pp. 2251-60, ISSN 1524-4539
- Lopez, AD.; Mathers, CD.; Ezzati, M.; Jamison, DT. & Murray, CJL. (2006). Global and regional burden of disease and risk factors, 2001: systematic analysis of population health data. *Lancet*, Vol.367, No.9524, (May 27 2006), pp. 1747-57, ISSN 0140-6736

- Mark, DB.; Berman, DS.; Budoff, MJ.; Carr, JJ.; Gerber, TC.; Hecht, HS.; Hlatky, MA.; Hodgson, JM.; Lauer, MS.; Miller, JM.; Morin, RL.; Mukherjee, D.; Poon, M.; Rubin, GD. & Schwartz, RS. (2010). ACCF/ACR/AHA/NASCI/SAIP/SCAI/SCCT 2010 Expert Consensus Document on Coronary Computed Tomographic Angiography. *Journal of the American College of Cardiology*, Vol.55, No.23, (June 8 2010), pp. 2663-99, ISSN 0735-1097
- Martuscelli, E.; Romagnoli, A.; D'Eliseo, A.; Tomassini, M.; Razzini, C.; Sperandio, M.; Simonetti, G.; Romeo, F. & Mehta, JL. (2004). Evaluation of venous and arterial conduit patency by 16-slice spiral computed tomography. *Circulation*, Vol.110, No.20, (November 16 2004), pp. 3234-8, ISSN 1524-4539.
- Moore, RK.; Sampson, C.; MacDonald, S.; Moynahan, C.; Groves, D. & Chester, MR. (2005). Coronary artery bypass graft imaging using ECG-gated multislice computed tomography: comparison with catheter angiography. *Clin Radiology*, Vol.60, No.9, (September 2005) pp. 990-8, ISSN 0009-9260
- Nixdorff, U.; Küfner, C.; Achenbach, S.; Stilianakis, N.; Voigt, JU.; Flachskampf, FA.; Daniel, WG. & Ropers, D. (2008). Head-to-head comparison of dobutamine stress echocardiography and cardiac computed tomography for the detection of significant coronary artery disease. *Cardiology*, Vol.110, No.2, pp. 81-86, ISSN 1479-6678
- Ropers, D.; Rixe, J.; Anders, K.; Kutter, A.; Baum, U.; Bautz, W.; Daniel, WG. & Achenbach, S. (2006). Usefulness of multidetector Row spiral computed tomography with 64 x0.6 collimation and 333-ms rotation of the noninvasive detection of significant coronary artery stenosis. *American Journal of Cardiology*, Vol.97, No.3, pp. 343-8, ISSN 0002-9149
- Ropers, D.; Pohle, FK.; Kuettner, A.; Pflederer, T.; Anders, K.; Daniel, WG.; Bautz, W.; Baum, U. & Achenbach, S. 2006. Diagnostic accuracy of noninvasive coronary angiography in patients after bypass surgery using 64-slice spiral computed tomography with 330-ms gantry rotation. *Circulation*, Vol.114, No.22, (November 28 2006), pp. 2334-41, ISSN 1524-4539
- Scheffel, H.; Alkadhi, H.; Leschka, S.; Plass, A.; Desbiolles, L.; Guber, I.; Krauss, T.; Gruenenfelder, J.; Genoni, M.; Luescher, TF.; Marincek, B. & Stolzmann, P. (2008). Low-dose CT coronary angiography in the step-and-shoot mode: diagnostic performance. *Heart*, Vol.94, No.9, (September 2008), pp. 1132-7, ISSN 1081-4698
- Schuijf, JD.; Achenbach, S.; de Feyter, PJ. & Bax, JJ. (2011). Current applications and limitations of coronary computed tomography angiography in stable coronary artery disease. *Heart*, Vol.97, No.4, (February 2011), pp. 330-7, ISSN 1081-4698
- Sheth, T.; Dodd, JD.; Hoffmann, U.; Abbara, S.; Finn, A.; Gold, HK.; Brady, TJ. & Cury, RC. (2007). Coronary stent assessability by 64 slice multi-detector computed tomography. *Catheter Cardiovasc Interv*, Vol.69, No.7, (June 1 2007), pp. 933-8, ISSN 1522-1946
- Stein, PD.; Yaekoub, AY.; Matta, F. & Sostman, HD. (2008). 64-slice CT for diagnosis of coronary artery disease: a systematic review. *Am J Med*, Vol.121, No.8, (August 2008), pp. 715-25, ISSN 0002-9343
- Sun, Z. & Almutairi, AM. (2010). Diagnostic accuracy of 64 multislice CT angiography in the assessment of coronary in-stent restenosis: a meta-analysis. *Eur J Radiol*, Vol.73, No.2, (February 2010), pp. 266-73, ISSN 0720-048X

- Taylor, AJ.; Cerqueira, M.; Hodgson, JM.; Mark, D.; Min, J.; O'Gara, P. & Rubin, GD. (2010). ACCF/SCCT/ACR/AHA/ASE/ASNC/NASCI/SCAI/SCMR 2010 appropriate use criteria for cardiac computed tomography. *Journal of the American College of Cardiology*, Vol.56, No.22, (November 23 2010), pp. 1864-94, ISSN 0735-1097
- Winchester, DE.; Wymer, DC.; Shifrin, RY.; Kraft, SM. & Hill, JA. (2010). Responsible use of computed tomography in the evaluation of coronary artery disease and chest pain. *Mayo Clinic Proceedings*, Vol.85, No.4, (April 2010), pp. 358-64, ISSN 0025-6196



Coronary Angiography - Advances in Noninvasive Imaging Approach for Evaluation of Coronary Artery Disease

Edited by Prof. Baskot Branislav

ISBN 978-953-307-675-1

Hard cover, 414 pages

Publisher InTech

Published online 15, September, 2011

Published in print edition September, 2011

In the intervening 10 years tremendous advances in the field of cardiac computed tomography have occurred. We now can legitimately claim that computed tomography angiography (CTA) of the coronary arteries is available. In the evaluation of patients with suspected coronary artery disease (CAD), many guidelines today consider CTA an alternative to stress testing. The use of CTA in primary prevention patients is more controversial in considering diagnostic test interpretation in populations with a low prevalence to disease. However the nuclear technique most frequently used by cardiologists is myocardial perfusion imaging (MPI). The combination of a nuclear camera with CTA allows for the attainment of coronary anatomic, cardiac function and MPI from one piece of equipment. PET/SPECT cameras can now assess perfusion, function, and metabolism. Assessing cardiac viability is now fairly routine with these enhancements to cardiac imaging. This issue is full of important information that every cardiologist needs to now.

How to reference

In order to correctly reference this scholarly work, feel free to copy and paste the following:

Mohamed Bamoshmoosh (2011). When Cardiac Computed Tomography Becomes the Gold Standard Technique to Evaluate Coronary Artery Disease Patients, *Coronary Angiography - Advances in Noninvasive Imaging Approach for Evaluation of Coronary Artery Disease*, Prof. Baskot Branislav (Ed.), ISBN: 978-953-307-675-1, InTech, Available from: <http://www.intechopen.com/books/coronary-angiography-advances-in-noninvasive-imaging-approach-for-evaluation-of-coronary-artery-disease/when-cardiac-computed-tomography-becomes-the-gold-standard-technique-to-evaluate-coronary-artery-dis>

INTECH
open science | open minds

InTech Europe

University Campus STeP Ri
Slavka Krautzeka 83/A
51000 Rijeka, Croatia
Phone: +385 (51) 770 447
Fax: +385 (51) 686 166
www.intechopen.com

InTech China

Unit 405, Office Block, Hotel Equatorial Shanghai
No.65, Yan An Road (West), Shanghai, 200040, China
中国上海市延安西路65号上海国际贵都大饭店办公楼405单元
Phone: +86-21-62489820
Fax: +86-21-62489821

© 2011 The Author(s). Licensee IntechOpen. This chapter is distributed under the terms of the [Creative Commons Attribution-NonCommercial-ShareAlike-3.0 License](https://creativecommons.org/licenses/by-nc-sa/3.0/), which permits use, distribution and reproduction for non-commercial purposes, provided the original is properly cited and derivative works building on this content are distributed under the same license.

IntechOpen

IntechOpen