

# We are IntechOpen, the world's leading publisher of Open Access books Built by scientists, for scientists

6,900

Open access books available

186,000

International authors and editors

200M

Downloads

Our authors are among the

154

Countries delivered to

TOP 1%

most cited scientists

12.2%

Contributors from top 500 universities



WEB OF SCIENCE™

Selection of our books indexed in the Book Citation Index  
in Web of Science™ Core Collection (BKCI)

Interested in publishing with us?  
Contact [book.department@intechopen.com](mailto:book.department@intechopen.com)

Numbers displayed above are based on latest data collected.  
For more information visit [www.intechopen.com](http://www.intechopen.com)



# Non-Invasive Imaging in Approaching Ischemic Coronary Artery Disease

Lucia Agoston-Coldea, Teodora Mocan and Silvia Lupu  
*The "Iuliu Hațieganu" University of Medicine and Pharmacy, Cluj-Napoca, Romania*

## 1. Introduction

Ischemic coronary artery disease represents one of the major contemporary health problems because of its elevated vital risk. Nowadays, atherosclerosis-related cardiovascular disease is the most significant non-traumatic mortality factor and the prime "killer" of the 21<sup>st</sup> century.

Increased morbidity and mortality in coronary artery disease (Rosamond et al., 2008), the significant impact on quality of life, negatively affecting the physical, psychological and social well-being of the patient (Xie et al., 2008) as well as the high costs of diagnosis and treatment for this disease (Rosamond et al., 2008) have lead to developing new imaging techniques in order to explore such patients more efficiently.

Cardiac imaging has developed greatly since the chest radiograph was first used to describe the heart's shape. Nowadays, non-invasive imaging, including echocardiography, Single Photon Emission Computer Tomography (SPECT), coronary angiography and, more recently, Positron Emission Tomography (PET), multidetector computed tomography angiography as well as cardiac magnetic resonance imaging (MRI), represent standard procedures in clinical practice (Budoff et al., 2008) (Gaemperli et al., 2008).

The latter, especially, have a crucial importance in approaching patients with suspected or known coronary artery disease, as well as in assessing risk stratification, prognosis and reperfusion indications in patients with ischemic coronary artery disease (Mark et al., 2010).

The purpose of this chapter is to help promote new ways of integrating the non-invasive diagnostic imaging in the diagnosis and management of coronary artery disease patients.

## 2. The value of non-invasive cardiac imaging in patients with coronary artery disease

Epicardial arteries visualization is essential for confirming coronary artery disease and for accurately establishing its severity. Over the last 40 years, coronary angiography has been the key exploration in assessing coronary artery obstruction, as well as the need for reperfusion, despite its invasive character and high costs. Nowadays, invasive coronary angiography is still considered the "gold standard" for diagnostic coronary testing, although it has a few major disadvantages and limitations (patient exposure to ionizing radiation, two-dimensional image acquisition of coronary arteries, inappropriate atherosclerotic plaques assessment).

16-channel computed tomography coronary angiography has recently become a leading procedure in cardiac imaging, as it allows an accurate visualization of the coronary artery lumen, as well as an appropriate assessment of stenosis severity; computed tomography coronary angiography results can now be used as an essential tool for prognosis assessment in patients with coronary heart disease (Mark et al., 2010).

### **2.1 The diagnostic value of non-invasive cardiac imaging in patients with coronary artery disease**

However, non-invasive imaging techniques (e.g. coronary multidetector computed tomography angiography and magnetic resonance imaging angiography), which are valuable and comparatively cheaper, can currently be used for studying the coronary artery wall. Both contribute to the diagnosis of coronary artery ischemic disease and the image quality produced by coronary multidetector computed tomography angiography favorably compares to that of coronary angiography. These explorations have their own limitations, including poor image acquisition due to cardiac motion or important calcium deposits, but, most of the times, good quality images are obtained.

Coronary multidetector computed tomography angiography allows outer-luminal plaque visualization and can assess subsequent luminal stenosis. As with invasive coronary angiography, visual grading of coronary segment narrowing by ranges of stenosis is the current standard of practice and has been shown to provide useful clinical information relative to invasive coronary angiography (Cheng et al., 2008) (Miller et al., 2008).

Quantitative coronary multidetector computed tomography angiography is a high accuracy procedure which allows noninvasive detection of suspected obstructive coronary artery disease; it has been used in some research applications but is not currently a routine part of clinical interpretation. This promising technology has potential as an additional diagnostic tool, which will most likely complement invasive coronary angiography in routine clinical care (Hoffmann et al., 2005).

In a recent multicenter study, visual and quantitative assessments of stenosis severity by coronary multidetector computed tomography angiography were quite similar (Miller et al., 2008). Technical progress in coronary multidetector computed tomography technology (increased number of detectors – 64, prolonged rotation time and, consequently, good spatial resolution) a careful patient selection and multi-slice coronary analysis led to a current sensitivity of 90-100%, a specificity of 95-100% (Hamon et al., 2006) and a negative predictive value of 97-100% (Yang et al., 2010) in coronary artery disease evaluation. The use of coronary multidetector computed tomography versus conventional coronary angiography and intravascular ultrasound for diagnostic purposes has been assessed in several studies and meta-analysis.

In older studies, in which the computed tomography apparatus had less than 64 detection channels, coronary multidetector computed tomography seemed to provide less useful and less accurate information than conventional coronary angiography. However, the accuracy improved over the years, while the number of detectors continued to increase from 4 to 16 and then to 64, allowing a more faithful description of a larger number of coronary artery segments, previously impossible to visualize. (Hamon et al., 2007) (Vanhoenacker et al., 2007) (Janne d'Othec et al., 2008). Later studies affirmed that coronary multidetector computed tomography might allow a more accurate atherosclerosis evaluation, despite their lower efficacy in assessing stenosis severity.

Recently, other studies tried to compare the diagnostic performance of 64-channel computed tomography with that of invasive coronary angiography in identifying obstructive coronary disease in various populations; the average sensitivity per-patient for identifying obstructive coronary artery disease was 98%, with an average per-patient specificity of 88% (Stein et al., 2008). The mean prevalence of obstructive coronary artery disease in these studies was 61%. The negative predictive value for multidetector computed tomography was estimated at 96%, while the positive predictive value proved to be rather insignificant, with large variations within the interval 64% to 100%.

Recently, most multicenter studies which compared 64-channel coronary multidetector computed tomography with conventional angiography have proved that multidetector computed tomography angiography had excellent sensitivity and very good negative predictive value in detecting coronary artery disease (Mowatt et al. 2008). Nevertheless, the positive predictive values are less important, since coronary artery stenosis is often overestimated by coronary multidetector computed tomography angiography, when compared to coronary angiography. This tends to happen because calcium blooming artifacts diminish the signal acquisition accuracy, whilst invasive coronary angiography fails to appreciate the extent of positive vessel remodelling by atherosclerosis.

In the prospective ACCURACY (Assessment by Coronary Computed Tomographic Angiography of Individuals Undergoing Invasive Coronary Angiography) study, 230 patients with typical or atypical chest pain were enrolled, all of which were referred for invasive coronary angiography and agreed to have a coronary multidetector computed tomography prior to their catheterization (Budoff et al., 2008). After having carefully interpreted the data, the sensitivity, specificity, as well as positive and negative predictive values for detecting  $\geq 50\%$  or  $\geq 70\%$  stenosis were 95%, 83%, 64%, and 99%, respectively, and 94%, 83%, 48%, 99%, respectively. In this prospective multicenter trial of chest pain patients without known coronary artery disease, 64-multidetector row coronary multidetector computed tomography proved a very high diagnostic accuracy in detecting obstructive coronary stenosis for both 50% and 70% stenosis thresholds. Moreover, the high (99%) negative predictive value of coronary multidetector computed tomography angiography pleads for its current use as an effective noninvasive alternative to invasive coronary angiography to rule out coronary artery obstructive stenosis.

The CORE 64 (Coronary Artery Evaluation Using 64-Row Multidetector Computed Tomography Angiography) study was conducted in 9 international centers and enrolled 316 symptomatic patients, aged 40 years or more, with suspected or known coronary disease. All patients whose calcium scores were less than 600 were referred for invasive coronary angiography, 291 (92%) of which completed coronary multidetector computed tomography prior to invasive coronary angiography. Obstructive coronary artery disease was diagnosed in 56% of the patients. Quantitative computed tomography angiography showed a sensitivity of 85%, a specificity of 90%, a positive predictive value of 91% and a negative predictive value of 83% in detecting or ruling out significant ( $>50\%$ ) coronary artery stenosis when compared to conventional angiography, thus proving that it can very accurately assess the presence and severity of obstructive coronary artery disease. However, the negative and positive predictive values estimated by this study are not significant enough to consider completely replacing conventional coronary angiography by multidetector computed tomography. Only two patients in the study group had contrast agent-related side effects after computed tomography angiography. (Miller et al., 2008) (Dewey et al., 2010). One study conducted in the Netherlands showed that multidetector computed

tomography has a considerable value in diagnosing obstructive coronary disease, but is slightly less valuable for stenosis severity assessment when compared to both conventional coronary angiography and intravascular ultrasound. In this study, 100 patients underwent coronary multidetector computed tomography angiography followed by both conventional coronary angiography and intravascular ultrasound. Only those segments in which intravascular ultrasound imaging was performed were included for coronary multidetector computed tomography and quantitative coronary angiography analysis. On coronary multidetector computed tomography angiography, each segment was evaluated for significant stenosis (defined as  $\geq 50\%$  luminal narrowing, as in conventional coronary angiography). Secondly, on coronary multidetector computed tomography angiography, each segment was evaluated for the presence of atherosclerotic plaques. Atherosclerosis was defined on intravascular ultrasound as a plaque burden covering  $\geq 40\%$  from the vessel's cross-sectional area. Multidetector computed tomography angiography correctly ruled out significant stenosis in 53 of 53 (100%) patients. However, 19% patients were incorrectly diagnosed as having significant lesions on coronary multidetector computed tomography angiography, which finally led to 100% sensitivity, 85% specificity, 81% positive and 100% negative predictive values. (van Velzen et al., 2011).

Nowadays, coronary multidetector computed tomography angiography is used to diminish the large number of normal coronary angiographies (by 25-30 %) (Blanchard et al., 2002).

Although coronary multidetector computed tomography angiography results prior to 64-channel technology were once considered adequate, the current trend in cardiac imaging is to ignore such studies, which are only limited to assessing coronary calcium (Otero et al. 2009). To this day, the incremental diagnostic value of 128 -, 256 - and 320-channel coronary multidetector computed tomography systems over 64-channel systems has not been proven. (Mark et al., 2010) (Hein et al., 2009). However, non-invasive methods might completely replace the expensive and rather unpleasant coronary angiography in the future.

64-slice coronary angiography can be as effective as conventional coronary angiography in patient selection for coronary artery by-pass graft surgery, especially when 3-vessel or left main coronary artery disease and its equivalents are present. The overall sensitivity, specificity, positive predictive value and negative predictive value of coronary multidetector computed tomography angiography for coronary artery bypass graft surgery candidates selection were 85.9%, 96.0%, 93.8%, and 90.7%, respectively. (Lee et al., 2011).

Despite all its advantages, all cases should be thoroughly selected, as coronary multidetector computed tomography angiography exposes the patient to a fairly large amount of radiation. Since coronary artery disease has become the main cause for mortality in recently developed countries, a noninvasive test that would not imply patient exposure to radiation is greatly needed.

In addition to coronary multidetector computed tomography, magnetic resonance imaging angiography can also provide accurate data concerning cardiac morphology, as well as coronary and cardiac functions (Hoffmann et al., 2008). Over the last 20 years, cardiac magnetic resonance imaging techniques have developed greatly, but their current use in coronary artery disease assessment is rather limited, despite the high initial expectations. In an expert consensus document on "appropriate" indications for cardiac multidetector computed tomography (Tayloret al., 2010) and magnetic resonance imaging published in 2006 (Hendel et al 2006), only coronary multidetector computed tomography angiography is recommended as an "adequate" imaging method for coronary artery disease assessment, while cardiac magnetic resonance imaging angiography is firmly rejected.



As far as spatial resolution and study success rates are concerned, coronary multidetector computed tomography angiography is superior to coronary magnetic resonance imaging angiography. The latter also has the major disadvantages of long image acquisition times and operator dependency, which limit its use to diagnosing congenital abnormal coronary artery origin and coronary artery aneurysms in patients with Kawasaki disease (Sakuma et al., 2011).

In a recent study, multidetector computed tomography and magnetic resonance imaging angiography were compared. 7516 patients were evaluated by multidetector computed tomography, whilst 989 underwent magnetic resonance imaging angiography. Bivariate analysis of data yielded a mean sensitivity and specificity of 97.2% and 87.4% for computed tomography and 87.1% and 70.3% for magnetic resonance imaging. In other studies which only included patients with suspected coronary artery disease, sensitivity and specificity of computed tomography were 97.6% and 89.2%. Covariate analysis showed that 16-detector row scanners had a greater sensitivity (98.1%) in diagnosing coronary artery disease than older-generation scanners (95.6%) (Schuetz et al., 2010).

When using steady-state free precession magnetic resonance imaging angiography, no contrast agents are needed; however, the accuracy of this approach has not yet been determined in a multicenter trial. So far, in a patient-based analysis, the sensitivity, specificity, positive and negative predictive values of magnetic resonance imaging angiography were 88%, 72%, 88%, and 79%, respectively, all significantly lower than for multidetector computed tomography. The non-contrast-enhanced whole-heart coronary magnetic resonance imaging angiography at 1.5-T can noninvasively detect significant coronary artery disease with high sensitivity and moderate specificity. A negative predictive value of 88% indicates that whole-heart coronary magnetic resonance imaging angiography can rule out coronary artery disease (Kato et al., 2010).

A single MRI study can provide very useful information regarding ischaemic heart disease. This technique allows the assessment of rest function, as well as gadolinium chelate contrast evaluation. The latter comprises three postcontrast temporal phases: phase one provides information regarding microvascular obstruction, which is the equivalent of the no-reflow phenomenon, at rest and during stress; early perfusion is used to evaluate microvascular obstruction and to track down thrombi, while late gadolinium enhancement technique provides data regarding the presence of myocardial infarction and focal myocardial damage. In most cases of acute chest pain, biomarkers and electrocardiographically can identify high risk patients; however, in some circumstances, coronary artery disease cannot be detected by such methods, thus imposing the evaluation by contrast cardiac MRI; first-pass perfusion or early enhancement techniques (Nijveldt et al., 2008) can be used for this purpose. Ingkanisorn et al, appealed to MRI examination after adenosine stress perfusion to investigate patients with typical angina and negative troponin; in such cases, adenosine stress results proved to have a 100% sensitivity and 93% specificity and thus a very high negative predictive value (Ingkanisorn et al., 2006). Cardiac MRI-measured microvascular obstruction is frequently associated with extensive myocardial damage and poor left ventricular function and, by consequence, with a poor functional recovery and clinical outcome (Rubenstein et al., 2008).

A multi-center clinical trial proved that delayed-enhancement cardiac magnetic resonance imaging can provide solid evidence for the presence of acute and chronic myocardial infarction, particularly in patients with negative troponins. Moreover, this type of investigation can accurately discriminate between ischemic and non-ischemic myocardial

injury, which helps identify the correct diagnosis in patients with normal angiographic results. This technique is useful even in cases of confirmed coronary artery disease, as it allows the examiner to identify details such as microvascular damage, myocardial stunning, residual viability or right ventricular infarction. Post-myocardial infarction complications such as pericarditis or left ventricular thrombi can also be identified, which can help in choosing the right therapy for these patients. MRI evaluation also allows the quantification of infarct size by delayed-enhancement techniques and can be a valuable surrogate end point for clinical trials, with significant reductions in sample size when compared to other methods (Kim et al., 2010).

Cardiac magnetic resonance imaging can complete or replace echocardiographic findings in patients with dilated ischemic cardiomyopathy and can provide useful information concerning myocardial perfusion and viability (Maceira et al., 2006). Left ventricular dysfunction after myocardial infarction may be due to necrosis, to post infarction stunning or hibernation of viable myocardium (Schinkel et al., 2007). Recurrent stunning may lead to myocardial hibernation and requires revascularization for function recovery.

Regional myocardial function can be evaluated by regional kinesis or regional parietal thickening assessment using standard or post-apnoea cardiac magnetic resonance imaging techniques, in normal conditions or after pharmacologically induced stress (using adenosine or dobutamine) (Kuijpers et al., 2004). Stress cardiac magnetic resonance imaging is particularly useful for assessing lesions in stable coronary patients who have no indication for coronary angiography (Kuijpers et al., 2004).

By using cine-cardiac magnetic resonance imaging in post-apnoea, major coronary arteries images can be obtained, while morphology and tissue analysis of the atherosclerotic plaque allows an accurate assessment of its composition and rupture risk. It is possible to evaluate the atherosclerotic plaques while using echo-spin sequences with  $T_1$ ,  $T_2$  pondering or by measuring proton density. However, the low temporal resolution of this technique limits its current use. In this case, MRI signal improvement by using contrast agents, especially gadofluorine (Sirol et al., 2004), allows a more appropriate examination of the atherosclerotic plaque because of its fast and persistent (as long as 24 hours) accumulation in lipid-rich atherosclerotic plaques. The gadofluorine-M-enhanced MRI can accurately identify atherosclerotic plaque inflammation and neovascularization in animal models of atherosclerosis, which can help identify high rupture risk atherosclerotic plaques (Sirol et al., 2009).

Since macrophage activity is an essential factor in atherosclerosis development and complications, macrophage imaging can be used as a biomarker for subclinical inflamed lesions, allowing risk assessment and therapy guiding. A sufficient  $T_2$  signal intensity after superparamagnetic phagocytosable nanoparticles administration can help identify inflamed plaques and closely monitor early tissue response to adequate therapy (Morishige et al., 2010). Cardiac magnetic resonance imaging can also highlight neofunctional blood vessels in the atherosclerotic plaque by using Gadolinium, which binds  $\alpha v \beta 3$  vessel wall integrin. Other contrast agents, with high affinity for lipidic structures, muscular and inflammatory cells, can also be used for assessing subclinical coronary artery disease by cardiac magnetic resonance imaging (Barkhausen et al., 2003).

Velocity encoding techniques in post-apnoea can be used to measure the coronary flow with the purpose of establishing the coronary flow reserves. Last, but not least, the fast echo-gradient with phase contrast technique allows perfusion evaluation in normal and stress conditions (using vasodilators) and normal or pathological coronary flow velocities. Other

technologies are able to provide an accurate image of diseased vessel walls, such as intravascular ultrasound, magnetic resonance imaging, and optical coherence tomography (Mark et al., 2010).

Cardiac magnetic resonance imaging allows a fast, radiation-free investigation of the myocardial function, perfusion and viability and can provide useful data concerning coronary arteries and atherosclerotic plaques. However, precise indications for the use of this technique, based on a balanced risk-advantage ratio, are yet to be established.

## **2.2 Prognostic value of non-invasive cardiac imaging in patients with coronary artery disease**

Coronary calcifications are vascular degenerative phenomena determined by active vascular remodeling processes. The calcium burden is an important risk factor for vascular remodeling (Schmermund et al., 2001) and plaque instability (Burke et al., 2002). Histopathological studies (Rumberger et al., 1995) have shown a significant relationship between calcified areas and the level of arterial atherosclerosis, indicating that coronary calcifications are direct markers of coronary artery disease.

Coronary multidetector computed tomography is a sensitive method for detecting coronary artery calcium. Multidetector computed tomography coronary angiography allows a pseudo-quantitative assessment of coronary artery calcifications using the Agatston calcium score (Corti et al., 2001) as well as calcium mass and volume calculations for certain coronary segments (Ulzheimer et al., 2003). Although the latter method proved to have higher reproducibility, the Agatston score is more frequently used in clinical practice. The prognostic value of coronary calcification assessment by multidetector computed tomography coronary angiography has been reported in several studies, but with mixed results (Chow et al., 2010) (Carrigan et al., 2009) (Hay et al., 2010).

Coronary multidetector computed tomography is also important for identifying high risk asymptomatic patients, especially if calcium scoring is used (Detrano et al., 1996) and has proved to be more accurate than the Framingham score (Greendland et al., 2004) or the SCORE method. In asymptomatic patients, low detectable coronary artery calcium scores are significantly less reliable in predicting plaque burden due to their association with high overall noncalcified coronary artery plaque prevalence and nearly a 10% rate of significantly occlusive noncalcified coronary artery plaque (Cheng et al., 2007). In one study, in which 632 subjects were enrolled, Raggi et al. have demonstrated that elevated coronary artery calcium can increase the odds of acute myocardial infarction and cardiac death in asymptomatic patients (Raggi et al., 2000). The MESA study also proved that the coronary artery calcium score was a better predictor for cardiovascular events in 6772 asymptomatic patients, when compared to classic risk factors (Detrano et al., 2008). The target is to emphasize risk stratification and primary risk prevention in asymptomatic patients in order to decrease cardiovascular mortality and morbidity. The Framingham Risk Score only predicts coronary heart disease events moderately well when family history is not included as a risk factor. There is a current preoccupation for developing new risk stratification tests and establishing new and more accurate risk factors. While the Framingham Risk Score, European Systematic Coronary Risk Evaluation Project and European Prospective Cardiovascular Munster Study still provide excellent tools for risk factor modification, the coronary artery calcium score may bring an additional benefit in risk assessment. There have been several studies supporting the role of coronary artery calcium score in predicting myocardial infarction and cardiovascular mortality, which proved to be significant for risk



stratification in asymptomatic patients presenting in the emergency room (Sharma et al., 2010). In CORE study done on 291 patients (5% patients had low, 75% had intermediate, and 20% had high pre-test probability of obstructive coronary artery disease) was observed that the absence of coronary calcification does not exclude obstructive stenosis or the need for revascularization among patients with high enough suspicion of coronary artery disease to be referred for coronary angiography, in contrast with the published recommendations (Gottlieb et al., 2010).

Also, the total coronary calcium score measured by multidetector computed tomography can be used as an independent prediction factor for major acute coronary events in patients with chest pain. A recent study on 263 patients presenting in the emergency room with acute chest pain and low-to-intermediate cardiovascular risk, defined by traditional risk factors, showed that computed tomography coronary artery calcium assessment is a powerful tool for prognosis evaluation. The absence of coronary artery calcium suggests an excellent long-term (5-year) prognosis, with no primary or secondary cardiac outcomes occurring in study patients at 5-year follow-up (Laudon et al., 2010). However, it has not yet been established whether there is a significant correlation between the total coronary calcium score and long-term clinical outcomes in patients who underwent percutaneous coronary intervention with drug eluting stents. In a recent study on 286 patients with coronary artery disease, Jeong showed that the total coronary calcium score measured by multidetector computed tomography was highly associated with chronic and significant coronary lesions, while the coronary calcium score  $\geq 400$  predicted lower procedural success rate and poor long-term clinical outcomes (Jeong et al., 2010).

One recently published meta-analysis (Hay et al., 2010) established the prognostic value of multidetector computed tomography in 9592 symptomatic patients with suspected coronary artery disease, reporting major adverse cardiovascular events such as death, myocardial infarction and revascularization. The sensitivity was 0.99 for major adverse cardiovascular events after normal multidetector computed tomography findings, with a specificity of 0.41. Stratifying by no coronary artery disease, nonobstructive coronary artery disease, or obstructive coronary artery disease, there were incrementally increasing adverse events. Adverse cardiovascular events among patients with normal multidetector computed tomography findings are very rare and comparable to a baseline risk among healthy patients. Increasing burden of coronary artery disease on multidetector computed tomography is associated with an increasing rate of revascularization necessity, myocardial infarction, and death. In predicting the incidence of adverse clinical events, normal findings in multidetector computed tomography are comparable to reported values for stress myocardial perfusion scan or stress echocardiography.

The critical analysis of these studies shows that there is a moderate correlation between the Agatston score and coronary artery stenosis assessed by coronarography (Detrano et al., 1996); secondly, the total calcium scoring seems to have a rather low positive predictive value, which tends to vary according to sex and age, but a significantly high negative predictive value ( $>95\%$  in asymptomatic patients and  $98\%$  in patients presenting with chest pain) (McLaughlin et al., 1999). Some of these studies were not adequately powered to detect differences in rates of clinical outcomes such as death, myocardial infarction, and coronary revascularization. Adequate outcome evaluation studies require the submission of large samples and often long periods of follow-up. A recent multidetector computed tomography expert consensus statement sponsored by the American College of Cardiology and 6 additional medical societies points to the need for continued collection and

assessment of prognostic data after multidetector computed tomography (Mark et al., 2010).

### **2.3 Therapeutic value of non-invasive cardiac imaging in patients with coronary artery disease**

It is quite difficult to establish whether there is a perfect diagnostic test, since there are quite many indirect issues to consider. A diagnostic test can only be considered valuable if it provides additional information that can help alter the clinical approach. So far, stress testing has not proven useful in such patients. However, some tests were validated by clinical trials as useful tools for every day practice. For instance, the choice between early emergency revascularization versus elective angiography seemed to favor the latter, as the clinical outcome tends to be better (Mark et al., 2010). Although it is reasonable to assume that fully validated diagnostic tests that show a direct impact on the clinical outcome are better, such level of validation is quite difficult to obtain, since large trial funding is scarce and the studies themselves are time consuming. Some statistical models including chi-square, p values with adjusted hazard ratios or calculation of c-indexes and proportion of subjects with reclassified risk have shown that some anatomic imaging tests are more likely to provide useful additional information in patients with acute coronary syndromes. However, favorable statistical analysis does not imply that a certain diagnostic test should alter clinical outcomes more than others and usually does not influence clinical decisions, as the test's value is often overestimated (Mark et al., 2010).

### **2.4 Non-invasive cardiac imaging in clinical practice of patients with coronary artery disease**

The evolution of atherosclerosis is progressive and clinically silent for a long period of time before stable angina is installed, followed by non-stable angina and other acute coronary syndromes. The term "acute coronary syndrome" includes unstable angina pectoris, non-ST-segment elevation myocardial infarction and ST-segment elevation myocardial infarction, all of which are life-threatening events (Figure 1). Over the past decades, following the use of evidence-based guidelines for the diagnosis and treatment of these conditions, the prognosis has improved considerably, as mortality rates became lower.

Current guidelines provide vital information which can help assess the appropriate use (Taylor et al.; 2010), performance (Abbara et al., 2009), and interpretation (Raff et al.; 2009) of multidetector computed tomography and magnetic resonance imaging (Hendel et al.; 2006) in order properly establish the diagnostic and therapeutic approach towards patients with coronary artery disease.

#### **2.4.1 Asymptomatic patients with coronary artery disease**

In asymptomatic patients with high risk for developing silent or manifest coronary artery disease, including acute myocardial infarction or coronary heart disease death, risk stratification is essential and three different classes have been established (Taylor et al.; 2010):

- Low risk of coronary artery disease development; the age-specific risk level is below average and correlates with a 10-year absolute coronary heart disease risk <10%.
- Intermediate risk of coronary artery disease development; the age-specific risk level is average or above average and correlates with a 10-year absolute coronary heart disease risk between 10% and 20%.

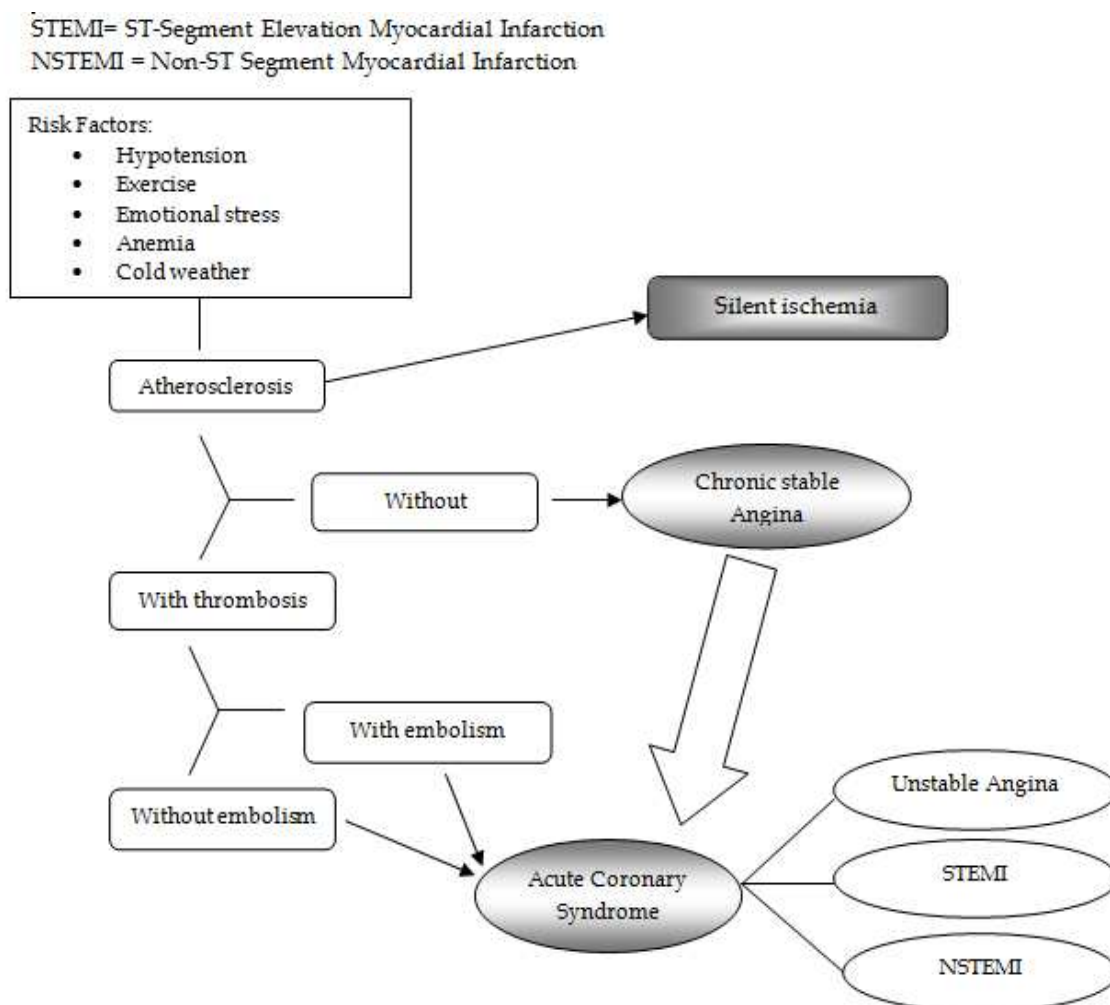


Fig. 1. Algorithm of diagnostic in coronary artery disease

- High risk of coronary artery disease development; in patients >40 years of age, with diabetes mellitus, peripheral arterial disease or other coronary risk equivalents; it correlates with an absolute or 10-year risk of coronary heart disease >20%.

Multidetector computed tomography angiography (64-slice scanner) has high sensitivity and specificity in patients presenting to the emergency department with atypical chest pain, normal cardiac biomarkers and/or non-diagnostic ECG (Hoffmann et al., 2009).

Symptomatic patients with coronary artery disease are stratified in three classes according to the risk of major cardiovascular events development:

- Low risk for developing cardiovascular events (<10%).
- Intermediate risk for developing cardiovascular events (10% to 90%).
- High risk for developing cardiovascular events (>90%).

#### 2.4.2 Symptomatic patients with stable angina pectoris

Several studies have shown that multidetector computed tomography helps assess non-significant, but possibly unstable atherosclerotic plaques with high risk for rupture and embolisation. This is the more important as the negative predictive value of stress tests with regard to major cardiovascular events is rather low (Vignaux, 2008). The role of cardiac magnetic resonance imaging in such patients is not established (Figure 2).

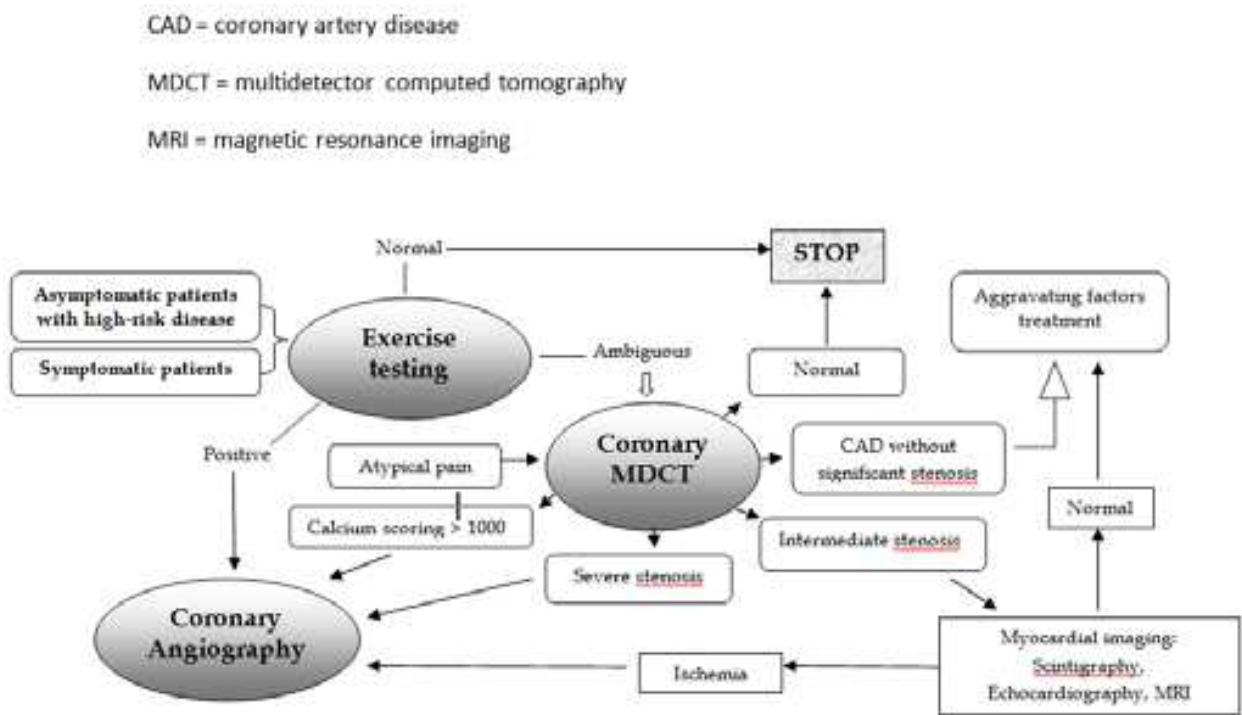


Fig. 2. Non-invasive imaging in stable coronary artery disease detection algorithm

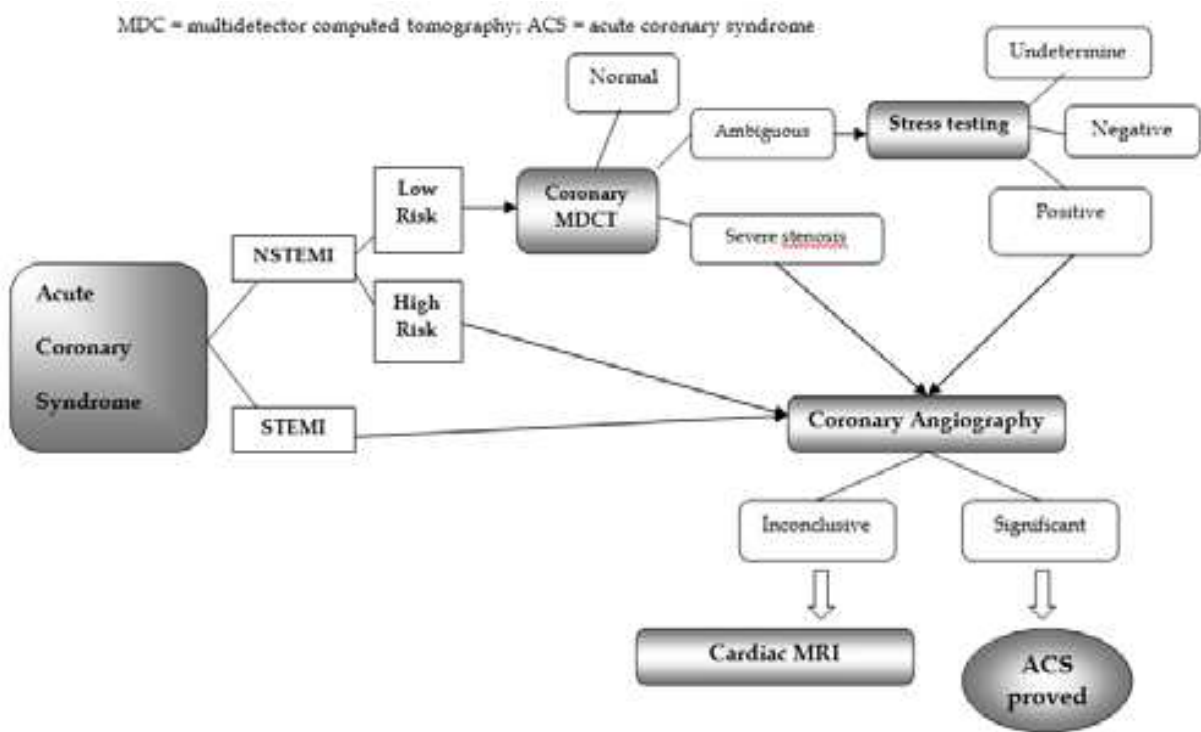


Fig. 3. Algorithm for non-invasive imaging use in detecting coronary artery disease in patients with Acute Coronary Syndrome



### **2.4.3 Symptomatic patients with acute coronary syndromes**

Non-invasive imaging techniques should be employed according to the type of coronary syndrome (ST-segment elevation myocardial infarction, non-ST-segment elevation myocardial infarction or UI) or the possible risk (whether high or low) for developing major cardiovascular events (Figure 3).

#### **2.4.3.1 ST-segment elevation myocardial infarction patients**

In ST-segment elevation myocardial infarction patients, non-invasive cardiac imaging is used only in accordance with the intended moment for revascularization (before or after revascularization), with the time passed from the onset of pain until hospitalization (acute or recent myocardial infarction) or with invasive coronary angiography results (coronary lesions versus normal arteries). In ST-segment elevation myocardial infarction patients which present within the first hours from the onset of pain, emergency revascularization is required and non-invasive imaging is of no use. However, non-invasive imaging can prove useful in patients with previously revascularized ST-segment elevation myocardial infarction for assessing residual ischaemia and establishing the need for late revascularization. Multidetector computed tomography is particularly useful if common trunk or right coronary artery sinus lesions, non-detected by invasive techniques, are suspected or in quantifying lesion length, as well as the vascular bed down-stream in order to provide the necessary information pending aorto-coronary by-pass. Cardiac magnetic resonance imaging in post-revascularization ST-segment elevation myocardial infarction patients is useful for morphology and global and segmentary left ventricle systolic function assessment, mechanical complication evaluation, infarctus size, stress and rest myocardial perfusion. Cardiac magnetic resonance imaging is particularly efficient in establishing the cause of acute coronary syndromes in ST-segment elevation myocardial infarction patients with normal coronary arteries, who sometimes have a Tako-Tsubo syndrome or suffer from myocarditis. In some cases, coronary multidetector computed tomography can help identify intra-stent restenosis or unstable atherosclerotic plaques, as well as coronary artery abnormalities that have not been identified during the invasive procedure. At patients with ST-segment elevation myocardial infarction and normal coronaries (Vignaux, 2008), cardiac magnetic resonance imaging have an important role in establishment of infarctus diagnosis and for excluding Tako-Tsubo syndrome or myocarditis.

#### **2.4.3.2 Non-ST-segment elevation myocardial infarction patients**

Myocardial revascularization is not a top priority in patients presenting with non-ST-segment elevation myocardial infarction, since no major long term benefit has been proven. The most appropriate approach is a late (48 hours) angiography. Multidetector computed tomography angiography could help select patients at risk who have normal myocardial biomarker values and non-diagnostic ECGs and allow the early discharge of subjects with normal coronary arteries. (Goldstein et al., 2007) (O'Connor et al, 2010).

#### **2.4.3.3 Patients with unstable angina and atypical chest pain**

Multidetector computed tomography is very useful in patients with atypical thoracic pain and normal cardiac enzymes, as well as in patients with valvular or vascular disease, dilated cardiomyopathy, congenital heart disease or left ventricular aneurysms, intracardiac thrombi and confirmed coronary artery disease. In addition to that, only 15-25% of hospitalized patients presenting with nonspecific acute chest pain prove to have genuine acute coronary syndromes (Yoo et al., 2010)

Coronary artery disease can also provide additional data when common trunk or right coronary ostium stenosis are present, in case of myocardial infarction with normal coronary arteries or in patients with confirmed coronary artery disease. Cardiac magnetic resonance imaging can be used for confirmation and risk stratification in patients with coronary artery disease and for sustaining differential diagnosis with myocarditis or pericarditis.

### 3. Conclusion

Over the last few years, new non-invasive imaging techniques that allow heart exploration such as coronary multidetector computed tomography and cardiac magnetic resonance imaging have demonstrated their diagnostic and prognostic value, as well as their impact on clinical outcomes, when properly used. However, despite convincing evidence concerning their high efficiency, sustained by several studies, clinical trials and meta-analyses, there is still an acute need for proper algorithms which can be used for basic approach in relation to cardiovascular risk and coronary artery disease severity.

### 4. References

- Abbara, S.; Arbab-Zadeh, A.; Callister, TQ.; Desai, MY.; Mamuya, W.; Thomson, L. & Weigold, WG. (2009). SCCT guidelines for performance of coronary computed tomographic angiography: a report of the Society of Cardiovascular Computed Tomography Guidelines Committee. *J Cardiovasc Comput Tomogr*, Vol.3, No.3, (March-Avril 2009), pp.190-204, ISSN 1934-5925.
- Barkhausen, J.; Ebert, W.; Heyer, C.; Debatin, JF. & Weinmann, HJ. (2003). Detection of atherosclerotic plaque with gadofluorine-enhanced magnetic resonance imaging. *Circulation* 2003; Vol.108, No.5, (August 2003), pp. 605-609, ISSN 0009-7322.
- Blanchard, D.; Chevalier, B.; Danchin N.; Finet, G.; Lablanche, JM. & Lancelin, B. (2002). National observational study of diagnostic and interventional cardiac catheterization by the French Society of Cardiology. *Arch Mal Coeur Vaiss*, Vol.95, pp. 843-849, ISSN 1261-694X.
- Budoff, MJ.; Dowe, D.; Jollis, JG.; Gitter, M.; Sutherland, J.; Halamert, E.; Scherer, M.; Bellinger, R.; Martin, A.; Benton, R.; Delago, A. & Min, JK. (2008). Diagnostic performance of 64-multidetector row coronary computed tomographic angiography for evaluation of coronary artery stenosis in individuals without known coronary artery disease: results from the prospective multicenter ACCURACY (Assessment by Coronary Computed Tomographic Angiography of Individuals Undergoing Invasive Coronary Angiography) trial. *J Am Coll Cardiol*, Vol.52, No.21, (November 2008), pp. 1724-1732, ISSN 0735-1097.
- Burke, AP.; Kolodgie, FD.; Farb, A.; Weber, D. & Virmani, R. (2002). Morphological predictors of arterial remodeling in coronary atherosclerosis. *Circulation*, Vol.105, No.3, (January 2002), pp.297-303, ISSN 0009-7322.
- Carrigan, TP.; Nair, D.; Schoenhagen, P.; Curtin, RJ.; Popovic, ZB.; Halliburton, S.; Kuzmiak, S.; White, RD.; Flamm, SD. & Desai, MY. (2009). Prognostic utility of 64-slice computed tomography in patients with suspected but no documented coronary artery disease. *Eur Heart J*, Vol.30, No.3, (February 2009), pp. 362-371, ISSN 1522-9645.
- Cheng, V.; Gutstein, A.; Wolak A.; Suzuki, Y.; Dey, D.; Gransar, H.; Thomson, LEJ.; Hayes, SW.; Friedman, JD. & Berman, DS. (2008). Moving beyond binary grading of coronary arterial stenoses on coronary computed tomographic angiography:

- insights for the imager and referring clinician. *J Am Coll Cardiol Img*, Vol. 1, No.4, (July 2008), pp. 460-471, ISSN 0390-6078.
- Cheng, VY.; Lepor, NE.; Madyoon, H.; Eshaghian, S.; Naraghi, AL. & Shah, PK. (2007). Presence and severity of noncalcified coronary plaque on 64-slice computed tomographic coronary angiography in patients with zero and low coronary artery calcium. *Am J Cardiol*, Vol.99, No.9, (March 2007), pp. 1183-1186, ISSN 0002-9149.
- Chow. BJ.; Wells, GA.; Chen, L.; Yam, Y.; Galiwango, P.; Abraham, A.; Sheth, T.; Dennie, C.; Beanlands. & Ruddy, TD. (2010). Prognostic value of 64-slice cardiac computed tomography severity of coronary artery disease, coronary atherosclerosis, and left ventricular ejection fraction. *J Am Coll Cardiol*, Vol.55, No.10 (March 2010), pp.1017-1028, ISSN 0735-1097.
- Detrano, R.; Guerci, AD.; Carr, JJ.; Bild, DE.; Burke, G.; Folsom, AR.; Liu, K.; Shea, S.; Szklo, S.; Bluemke, DA.; O'Leary, DH.; Tracy, R.; Watson, K. & Kronmal, RA. (2008). Coronary calcium as a predictor of coronary events in four racial or ethnic groups. *N Engl J Med*, Vol.358, No.13, (March 2008), pp.1336-1345, ISSN 0028-4793.
- Detrano, R.; Hsiai, T.; Wang, S.; Puentes, G.; Fallavollita, J.; Shields, P.; Stanford, W.; Wolfkiel, C.; Georgiou, D.; Budoff, M. & Reed, J. (1996). Prognostic value of coronary calcification and angiographic stenoses in patients undergoing coronary angiography. *J Am Coll Cardiol*, Vol.27, No.2, (February 1996), pp.285-290, ISSN 0735-1097.
- Dewey, M.; Vavere, AL.; Arbab-Zadeh, A.; Miller, JM.; Sara, L.; Cox, C.; Gottlieb, I.; Yoshioka, K.; Paul, N.; Hoe, J.; de Roos, A.; Lardo, AC.; Lima, JA. & Clouse, ME. (2010). Patient characteristics as predictors of image quality and diagnostic accuracy of MDCT compared with convention coronary angiography for detecting coronary artery stenoses: CORE-64 Multicenter International Trial. *Am J Roentgenol*, Vol.194, No.1, (January 2010), pp. 93-102, ISSN 1546-3141.
- Gaemperli, O.; Valenta, I.; Schepis, T.; Husmann, L.; Scheffel, H.; Desbiolles, L.; Leschka, S.; Alkadhi H. & Kaufmann, PA. (2008). Coronary 64-slice CT angiography predicts outcome in patients with known or suspected coronary artery disease. *Eur Radiol*, Vo.18, No.6, (June 2008), pp. 1162-1173, ISSN 0938-7994.
- Goldstein, JA.; Gallagher, MJ.; O'Neill, WW.; Ross, MA.; O'Neil, BJ. & Raff GL. (2007). A randomized controlled trial of multi-slice coronary computed tomography for evaluation of acute chest pain. *J Am Coll Cardiol*, Vol.49, No.8, (February 2007), pp. 863-871, ISSN 0735-1097.
- Gottlieb, I.; Miller, JM.; Arbab-Zadeh, A.; Dewey, M.; Clouse, ME.; Sara, L.; Niinuma, H.; Bush, DE.; Paul, N.; Vavere, AL.; Texter, J.; Brinker, J.; Lima, JA. & Rochitte, CE. (2010). The absence of coronary calcification does not exclude obstructive coronary artery disease or the need for revascularization in patients referred for conventional coronary angiography. *J Am Coll Cardiol*, Vol.55, No.7, (February 2010), pp.627-634, ISSN 0735-1097.
- Greenland, P.; Abrams, J.; Aurigemma, GP.; Bond, MG.; Clark, LT.; Criqui, MH.; Crouse, JR 3rd.; Friedman, L.; Fuster, V.; Herrington, DM.; Kuller, LH.; Ridker, PM.; Roberts, WC.; Stanford, W.; Stone, N.; Swan, HJ.; Taubert, KA. & Wexler, L. (2000). Prevention Conference V: Beyond secondary prevention: identifying the high-risk patient for primary prevention: noninvasive tests of atherosclerotic burden: Writing Group III. *Circulation*, Vol.101, No.1, (January 2000), pp.E16-22. ISSN 0009-7322.
- Hamon, M.; Biondi-Zoccai, GG.; Malagutti P.; Agostoni, P.; Morello, R.; Valgimigli, M. & Hamon, M. (2006). Diagnostic performance of multislice spiral computed tomography of coronary arteries as compared with conventional invasive coronary

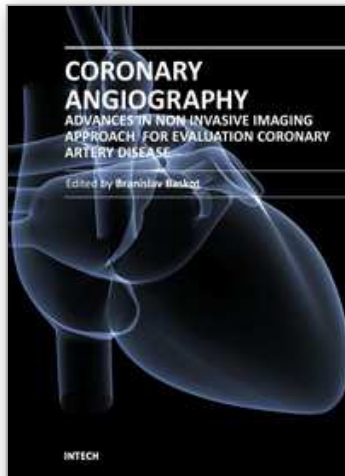
- angiography: a meta-analysis. *J Am Coll Cardiol*, Vol.48, No.9, (November 2006), pp. 1896-1910, ISSN 0735-1097.
- Hamon, M.; Morello, R.; Riddell, JW. & Hamon M. (2007). Coronary arteries: diagnostic performance of 16- versus 64-section spiral CT compared with invasive coronary angiography – meta-analysis. *Radiology*, Vol.245, No.3, (December 2007), pp. 720-731, ISSN 0033-8419.
- Hay, CS.; Morse, RJ.; Morgan-Hughes, GJ.; Gosling, O.; Shaw, SR. & Roobottom, CA. (2010). Prognostic value of coronary multidetector CT angiography in patients with an intermediate probability of significant coronary heart disease. *Br J Radiol*, Vol.83, No.988, (April 2010), pp. 327-330, ISSN 0938-7994.
- Hein, PA.; Romano, VC.; Lembcke A.; May, J. & Rogalla, P. (2009). Initial experience with a chest pain protocol using 320-slice volume MDCT. *Eur Radiol*, Vol.19, No. 5, (May 2009), pp. 1148-1155, ISSN 0938-7994.
- Hendel, RC.; Patel, MR.; Kramer, CM.; Poon, M.; Hendel, RC.; Carr, JC.; Gerstad, NA.; Gillam, LD.; Wolk, MJ.; Allen, JM. & Patel, MR. (2006). ACCF/ACR/SCCT/SCMR/ASNC/NASCI/SCAI/SIR 2006 appropriateness criteria for cardiac computed tomography and cardiac magnetic resonance imaging: a report of the American College of Cardiology Foundation Quality Strategic Directions Committee Appropriateness Criteria Working Group, American College of Radiology, Society of Cardiovascular Computed Tomography, Society for Cardiovascular Magnetic Resonance, American Society of Nuclear Cardiology, North American Society for Cardiac Imaging, Society for Cardiovascular Angiography and Interventions, and Society of Interventional Radiology. *J Am Coll Cardiol*, Vol.48, No.7, (October 2006), 1475-1497, ISSN 0735-1097.
- Hoffmann, MH.; Shi, H.; Schmitz, BL.; Schmid, FT.; Lieberknecht, M.; Schulze, R.; Ludwig, B.; Kroschel, U.; Jahnke, N.; Haerer, W.; Brambs, HJ. & Aschoff, AJ. (2005). Noninvasive coronary angiography with multislice computed tomography. *JAMA*, Vol.293, No.20, (May 2005), pp. 2471-2478, ISSN 0098-7484.
- Hoffmann, U.; Bamberg, F.; Chae, CU.; Nichols, JH.; Rogers, IS.; Seneviratne, SK.; Truong, QA.; Cury, RC.; Abbara, S.; Shapiro, MD.; Moloo, J.; Butler, J.; Ferencik, M.; Lee, H.; Jang, IK.; Parry, BA.; Brown, DF.; Udelson, JE.; Achenbach, S.; Brady, TJ. & Nagurney, JT. (2009). Coronary computed tomography angiography for early triage of patients with acute chest pain: the ROMICAT (Rule Out Myocardial Infarction using Computer Assisted Tomography) trial. *J Am Coll Cardiol*, Vol.53, No.18, (May 2009), pp. 1642-1650, ISSN 0735-1097.
- Inganisorn, WP.; Kwong, RY.; Bohme, NS.; Geller, NL.; Rhoads, KL.; Dyke, CK.; Paterson, DI.; Syed, MA.; Aletras, AH. & Arai, AE. (2006). Prognosis of negative adenosine stress magnetic resonance in patients presenting to an emergency department with chest pain. *J Am Coll Cardiol*, Vol.47, No.7, (March 2006), pp.1427-1432, ISSN 0735-1097.
- Janne d'Othez, B.; Siebert, U.; Cury, R.; Jadvar, H.; Dunn, EJ. & Hoffmann, U. (2008). A systematic review on diagnostic accuracy of CT-based detection of significant coronary artery disease. *Eur J Radiol*, Vol.65, No.3, (March 2008), pp. 449-461, ISSN 0720-048X.
- Jeong, HC.; Ahn, Y.; Doo, SS.; Yoon, HJ.; Yoon NS.; Hong, YJ.; Park, HW.; Kim, JH.; Jeong, MH.; Cho, JG.; Park, JC. & Kang, JC. (2010). Impact of total coronary calcium score on procedural and long-term outcomes in patients who underwent percutaneous coronary intervention with drug eluting stents: three years follow-up. *J Am Coll Cardiol* 55; A70, ISSN 0735-1097.



- Kato, S.; Kitagawa, K.; Ishida, N.; Ishida, M.; Nagata, M.; Ichikawa, Y.; Katahira, K.; Matsumoto, Y.; Seo, K.; Ochiai, R.; Kobayashi, Y. & Sakuma H. (2010). Assessment of Coronary Artery Disease Using Magnetic Resonance Coronary Angiography. *J Am Coll Cardiol*, Vol.56, No.12, (September 2010), pp. 983-991, ISSN 0735-1097.
- Kim, HW.; Farzaneh-Far A. & Kim RJ. (2010). Cardiovascular Magnetic Resonance in Patients with Myocardial Infarction. *J Am Coll Cardiol*, Vol.55, No.1, (March 2009), pp.1-16. ISSN 0735-1097.
- Kuijpers, D.; Janssen, CH.; van Dijkman, PR. & Oudkerk, M. (2004). Part I. Safety and feasibility of dobutamine cardiovascular magnetic resonance in patients suspected of myocardial ischemia. *Eur Radiol*, Vol.14, No.10, (October 2004), pp.1823-1828, ISSN 0938-7994.
- Kuijpers D, van Dijkman PR, Janssen CH.; Vliegenthart, R.; Zijlstra, F. & Oudkerk, M. (2004). Part II. Risk stratification with dobutamine cardiovascular magnetic resonance in patients suspected of myocardial ischemia. *Eur Radiol*, Vol.14, No. 11, (November 2004), pp. 2046-2052, ISSN 0938-7994.
- Laudon, DA.; Behrenbeck, TR.; Wood, CM.; Bailey, KR.; Callahan, CM.; Breen, JF. & Vukov, LF. (2010). Computed tomographic coronary artery calcium assessment for evaluating chest pain in the emergency department: long-term outcome of a prospective blind study. *Mayo Clin Proc*, Vol.85, No.4, (April 2010), pp. 314-322, ISSN 1942-5546.
- Lee, HJ.; Kim, JS.; Kim, YJ.; Hur, J. & Yoo, KJ. (2011). Diagnostic accuracy of 64-slice multidetector computed tomography for selecting coronary artery bypass graft surgery candidates. *J Thorac Cardiovasc Surg*, Vol.141, No.2, (January 2011) pp. 571-577, ISSN 0022-5223.
- Maceira, AM.; Prasad, SK.; Khan, M. & Pennell, DJ. (2006). Normalized left ventricular systolic and diastolic function by steady state free precession cardiovascular magnetic resonance. *J Cardiovasc Magn Reson*, Vol.8, No.3, pp. 417-426, ISSN 1097-6647.
- Mark, DB.; Berman, DS.; Budoff ,MJ.; Carr, JJ.; Gerber, TC.; Hecht, HS.; Hlatky, MA.; Hodgson, JM.; Lauer, MS.; Miller, JM.; Morin, RL.; Mukherjee, D.; Poon, M.; Rubin, GD. & Schwartz, RS. (2010). ACCF/ACR/AHA/NASCI/SAIP/SCAI/ SCCT 2010 Expert Consensus Document on Coronary Computed Tomographic Angiography: A Report of the American College of Cardiology Foundation Task Force on Expert Consensus Documents. *J Am Coll Cardiol*, Vol.55, No.23, (June 2010), pp.2663-2699, ISSN 0735-1097.
- McLaughlin, VV.; Balogh, T. & Rich, S. (1999). Utility of electron beam computed tomography to stratify patients presenting to the emergency room with chest pain. *Am J Cardiol*, Vol.84, No.3, (August 1999), pp. 327-328, A8, ISSN 0002-9149.
- Miller, JM.; Rochitte, CE.; Dewey, M.; Arbab-Zadeh, A.; Niinuma, H.; Gottlieb, I.; Paul, N.; Clouse, ME.; Shapiro, EP.; Hoe, J.; Lardo, AC.; Bush, DE.; de Roos, A.; Cox, C.; Brinker, J. & Lima, JA. (2008). Diagnostic performance of coronary angiography by 64-row CT. *N Engl J Med*, Vol.359, No.22, (November 2008), pp.2324-2336, ISSN 0028-4793.
- Mowatt, G.; Cummins, E.; Waugh N.; Walker, S.; Cook, J.; Jia, X.; Hillis, GS. & Fraser, C. (2008). Systematic review of the clinical effectiveness and cost effectiveness of 64-slice or higher computed tomography angiography as an alternative to invasive coronary angiography in the investigation of coronary artery disease. *Health Technol Assess*, Vol.12, No.17, (May 2008), pp. iii-iv, ix-143, ISSN 0266-4623.
- Nijveldt, R.; Beek, AM.; Hirsch, A.; Hofman, MBM.; Umans, VAWM.; Algra, PR. & van Rossum AC. (2008). No-reflow after acute myocardial infarction: direct

- visualisation of microvascular obstruction by gadolinium-enhanced CMR. *Neth Heart J*, Vol.16, No.5, (May 2008), pp.179–181. ISSN 1568-5888.
- O'Connor RE.; Brady, W.; Brooks, SC.; Diercks, D.; Egan, J.; Ghaemmaghami, C.; Menon, V.; O'Neil, BJ.; Travers, AH. & Yannopoulos D. (2010). Part 10: Acute Coronary Syndromes: 2010 American Heart Association Guidelines for Cardiopulmonary Resuscitation and Emergency Cardiovascular Care. *Circulation*, Vol.122, No.18 (suppl 3), (November 2010), pp. S787-S817. ISSN 0009-7322.
- Otero, HJ.; Steigner, ML. & Rybicki, FJ. (2009). The “post-64” era of coronary CT angiography: understanding new technology from physical principles. *Radiol Clin North Am*, Vol.47, No. 1, (January 2009), pp. 79-90, ISSN 0033-8389.
- Raff, GL.; Abidov, A.; Achenbach, S.; Berman, DS.; Boxt, LM.; Budoff, MJ.; Cheng, V.; De France, T.; Hellinger, JC. & Karlsberg, RP. (2009). SCCT guidelines for the interpretation and reporting of coronary computed tomographic angiography. *J Cardiovasc Comput Tomogr*, Vol.3, No.2, (March-Avril 2009), pp. 122–136, ISSN 1934-5925.
- Raggi, P.; Callister, TQ.; Cooil, B.; He, ZX.; Lippolis, NJ.; Russo, DJ.; Zelinger, A. & Mahmarian, JJ. (2000). Identification of patients at increased risk of first unheralded acute myocardial infarction by electron-beam computed tomography. *Circulation*, Vol.101, No.8, (February 2000), pp.850-855, ISSN 0009-7322.
- Rosamond, W.; Flegal, K.; Furie, K.; Go, A.; Greenlund, K.; Haase, N.; Hailpern, SM.; Ho, M.; Howard, V.; Kissela, B.; Kittner, S.; Lloyd-Jones, D.; McDermott, M.; Meigs, J.; Moy, C.; Nichol, G.; O'Donnell, C.; Roger, V.; Sorlie, P.; Steinberger, J.; Thom, T.; Wilson, M. & Hong, Y. (2008). Heart disease and stroke statistics – 2008 update: a report from the American Heart Association Statistics Committee and Stroke Statistics Subcommittee. *Circulation*, Vol.117, No.14, (January 2008), pp. e25-e146, ISSN 0009-7322.
- Rubenstein, JC.; Ortiz, JT.; Wu, E.; Kadish, A.; Passman, R.; Bonow, RO. & Goldberger, JJ. (2008). The use of periinfarct contrast-enhanced cardiac magnetic resonance imaging for the prediction of late postmyocardial infarction ventricular dysfunction. *Am Heart J*, Vol.156, No.5, (September, 2008), pp.498–505. ISSN 1751-7168.
- Rumberger, JA.; Simons, DB.; Fitzpatrick, LA.; Sheedy, PF. & Schwartz RS. (1995). Coronary artery calcium area by electron-beam computed tomography and coronary atherosclerotic plaque area. A histopathologic correlative study. *Circulation*, Vol.92, No.8, (October 1995), pp.2157-2162. ISSN 0009-7322.
- Sakuma H. (2011). Coronary CT versus MR Angiography: The Role of MR Angiography. *Radiology*, Vol.258, No. 2, (February 2011), pp. 340-349. ISSN 0033-8419.
- Schinkel, AF.; Bax, JJ.; Poldermans, D.; Elhendy, A.; Ferrari, R. & Rahimtoola SH. (2007). Hibernating myocardium: diagnosis and patient outcomes. *Curr Probl Cardiol*, Vol.32, No.7, (July 2007), pp. 375-410, ISSN 0146-2806.
- Schmermund, A. & Erbel, R. (2001). Unstable coronary plaque and its relation to coronary calcium. *Circulation*, Vol.104, No.14, (October 2001), pp.1682-1687, ISSN 0009-7322.
- Schuetz, GM.; Zachropoulou, NM.; Schlattmann, P. & Dewey, M. (2010). Meta-analysis: Noninvasive Coronary Angiography Using Computed Tomography Versus Magnetic Resonance Imaging. *Ann Intern Med*, Vol.152, No.3, (February 2010), pp.167-177, ISSN 0003-4819.
- Sharma, RK.; Sharma RK.; Voelker, DJ.; Singh, VN.; Pahuja, D.; Nash, T. & Reddy, HK. (2010). Cardiac risk stratification: role of the coronary calcium score. *Vasc Health Risk Manag*, Vol.6, (August 2010), pp.603-611, ISSN 1178-2048.
- Sirol, M.; Itskovich, VV.; Mani, V.; Aguinaldo, JGS.; Fallon, JT.; Misselwitz, B.; Weinmann HJ.; Fuster V.; Toussaint, JF. & Fayad ZA. (2004). Lipid-rich atherosclerotic plaques

- detected by Gadofluorine-enhanced in vivo magnetic resonance imaging. *Circulation*, Vol. 109, No. 23, (December 2003), pp.2890-2896, ISSN 0009-7322.
- Sirol, M.; Moreno, PR.; Purushothaman, KR.; Vucic, E.; Amirbekian, V.; Weinmann, HJ.; Muntner, P.; Fuster, V. & Fayad, Z. (2009). Increased neovascularization in advanced lipid-rich atherosclerotic lesions detected by gadofluorine-M-enhanced MRI: Implications for plaque vulnerability. *Circ Cardiovasc Imaging*, Vol.2, No.5, (September 2009), pp.391-396, ISSN 1941-9651.
- Stein, PD.; Yaekoub, AY.; Matta, F. & Sostman, HD. (2008). 64-slice CT for diagnosis of coronary artery disease: a systematic review. *Am J Med*, Vol.121, No.8, (August 2008), pp. 715-725, ISSN 0002-9343.
- Taylor, AJ.; Cerqueira, M.; Hodgson, JM.; Mark, D.; Min, J.; O’Gara, P. & Rubin, GD. (2010). ACCF/SCCT/ACR/AHA/ASE/ASNC/ NASCI/SCAI/SCMR 2010 appropriate use criteria for cardiac computed tomography: a report of the American College of Cardiology Foundation Appropriate Use Criteria Task Force, the Society of Cardiovascular Computed Tomography, the American College of Radiology, the American Heart Association, the American Society of Echocardiography, the American Society of Nuclear Cardiology, the North American Society for Cardiovascular Imaging, the Society for Cardiovascular Angiography and Interventions, and the Society for Cardiovascular Magnetic Resonance. *J Am Coll Cardiol*, Vol.56, No.22, (November 2010), pp. 1864-1894, ISSN 0735-1097.
- Ulzheimer, S.& Kalender, WA. (2003). Assessment of calcium scoring performance in cardiac computed tomography. *Eur Radiol*, Vol.13, No.3, (March 2003), pp. 484-497, ISSN 0938-7994.
- van Velzen J, Schuijf JD, de Graaf FR.; Boersma, E.; Pundziute G.; Spano, F.; Boogers, MJ.; Schalij, MJ.; Kroft, LJ.; de Roos, A.; Jukema, JW.; van der Wall, EE. & Bax, JJ. (2011). Diagnostic performance of non-invasive multidetector computed tomography coronary angiography to detect coronary artery disease using different endpoints: detection of significant stenosis vs. detection of atherosclerosis. *Eur Heart J*, Vol.32, No.5, (March 2011), pp. 637-645, ISSN 1522-9645.
- Vanhoenacker, PK.; Heijenbrok-Kal, MH.; Van Heste, R.; Decramer, I.; van Hoe, LR.; (2007). Diagnostic performance of multidetector CT angiography for assessment of coronary artery disease: meta-analysis. *Radiology*, Vol.244, No.2, (August 2007), pp. 419-428, ISSN 0033-8419.
- Vignaux, O. (2008). *Imagerie du Coeur et des arteres coronaries*. Flammarion Medecine-Scionces, ISBN 978-2-2570-0008-8, Paris, France.
- Xie, J.; Wu, EQ.; Zheng, Z-J.; Sullivan, PW.; Zhan, L. & Labarthe DR. (2008). Patient-reported health status in coronary heart disease in the United States: age, sex, racial, and ethnic differences. *Circulation*, Vol.118, No.5, (July 2008), pp. 491-497, ISSN 0009-7322.
- Yang, X.; Gai, LY.; Li, P.; Chen, YD.; Li, T. & Yang, L. (2010). Diagnostic accuracy of dual-source CT angiography and coronary risk stratification. *Vasc Health Risk Manag*, Vol.6, (October 2010), pp. 935-941, ISSN 1176-6344.
- Yoo SM, MD, Rho JY, Lee HY.; Song IS.; Moon, JK. & White, CS. (2010). Current Concepts in Cardiac CT angiography for Patients with Acute Chest Pain. *Korean Circ J*, Vol.40, No.11, (November 2010), pp. 543–554. ISSN 1738-5520.



## **Coronary Angiography - Advances in Noninvasive Imaging Approach for Evaluation of Coronary Artery Disease**

Edited by Prof. Baskot Branislav

ISBN 978-953-307-675-1

Hard cover, 414 pages

**Publisher** InTech

**Published online** 15, September, 2011

**Published in print edition** September, 2011

In the intervening 10 years tremendous advances in the field of cardiac computed tomography have occurred. We now can legitimately claim that computed tomography angiography (CTA) of the coronary arteries is available. In the evaluation of patients with suspected coronary artery disease (CAD), many guidelines today consider CTA an alternative to stress testing. The use of CTA in primary prevention patients is more controversial in considering diagnostic test interpretation in populations with a low prevalence to disease. However the nuclear technique most frequently used by cardiologists is myocardial perfusion imaging (MPI). The combination of a nuclear camera with CTA allows for the attainment of coronary anatomic, cardiac function and MPI from one piece of equipment. PET/SPECT cameras can now assess perfusion, function, and metabolism. Assessing cardiac viability is now fairly routine with these enhancements to cardiac imaging. This issue is full of important information that every cardiologist needs to now.

### **How to reference**

In order to correctly reference this scholarly work, feel free to copy and paste the following:

Lucia Agoston-Coldea, Teodora Mocan and Silvia Lupu (2011). Non-Invasive Imaging in Approaching Ischemic Coronary Artery Disease, *Coronary Angiography - Advances in Noninvasive Imaging Approach for Evaluation of Coronary Artery Disease*, Prof. Baskot Branislav (Ed.), ISBN: 978-953-307-675-1, InTech, Available from: <http://www.intechopen.com/books/coronary-angiography-advances-in-noninvasive-imaging-approach-for-evaluation-of-coronary-artery-disease/non-invasive-imaging-in-approaching-ischemic-coronary-artery-disease>

**INTECH**  
open science | open minds

### **InTech Europe**

University Campus STeP Ri  
Slavka Krautzeka 83/A  
51000 Rijeka, Croatia  
Phone: +385 (51) 770 447  
Fax: +385 (51) 686 166  
[www.intechopen.com](http://www.intechopen.com)

### **InTech China**

Unit 405, Office Block, Hotel Equatorial Shanghai  
No.65, Yan An Road (West), Shanghai, 200040, China  
中国上海市延安西路65号上海国际贵都大饭店办公楼405单元  
Phone: +86-21-62489820  
Fax: +86-21-62489821



© 2011 The Author(s). Licensee IntechOpen. This chapter is distributed under the terms of the [Creative Commons Attribution-NonCommercial-ShareAlike-3.0 License](https://creativecommons.org/licenses/by-nc-sa/3.0/), which permits use, distribution and reproduction for non-commercial purposes, provided the original is properly cited and derivative works building on this content are distributed under the same license.

IntechOpen

IntechOpen