

We are IntechOpen, the world's leading publisher of Open Access books Built by scientists, for scientists

6,900

Open access books available

186,000

International authors and editors

200M

Downloads

Our authors are among the

154

Countries delivered to

TOP 1%

most cited scientists

12.2%

Contributors from top 500 universities



WEB OF SCIENCE™

Selection of our books indexed in the Book Citation Index
in Web of Science™ Core Collection (BKCI)

Interested in publishing with us?
Contact book.department@intechopen.com

Numbers displayed above are based on latest data collected.
For more information visit www.intechopen.com



Clinical Application of Ultrasound Imaging in Radiation Therapy

Hayeon Kim, Edward Brandner, M. Saiful Huq and Sushil Beriwal
University of Pittsburgh Cancer Institute
 USA

1. Introduction

Radiation therapy plays an important role in cancer treatment. It is well known that good local control is achieved when planned dose of radiation is delivered to the target.

Recent advances in technology, in particular in image guided radiation therapy (IGRT), has significantly improved the accuracy of target localization for daily radiation treatment. Daily localization of the target is critical to the delivery of the prescription dose to the target. Thus, to achieve accurate targeting and reduce the irradiation of normal tissues and to potentially escalate dose to target volumes, IGRT needs to be implemented for daily use in the clinic.

Various IGRT techniques are currently available. One of the techniques integrates an On Board low kilovoltage imaging capability into the linear accelerator that produces diagnostic quality images. However, this imaging technique requires that extra radiation dose be delivered to the patient. Another IGRT imaging system that has been integrated recently with the linear accelerator is 3D ultrasound imaging. This technique is non invasive, requires no extra radiation to a patient and provides capabilities for daily target localization and verification prior to the delivery of radiation treatment.

Currently, 3D ultrasound imaging is used for target localization and verification of prostate, gynecological and breast cancers. Since the late nineties, 2D ultrasound imaging has been used for prostate localization only, but only recently has 3D ultrasound localization been available. This has also led to the use of 3D ultrasound for localizing other treatment sites as well; although, each site requires unique methods.

For the prostate cancer treatment, the prostate can move daily compared to the reference planning CT (radiation therapy planning and dose calculation for all disease sites is done with CT image based) due to bladder and rectal filling. Ultrasound imaging can be used to image and localize the prostate target daily. The prostate and bladder can all typically be well visualized and compared to the reference ultrasound image or CT image. Shifts are then identified and made to reposition the patient to the point that the treatment volumes identified each day are aligned with where they were on the planning CT images relative to the linear accelerator's isocenter. This isocenter is the point in space about which the linear accelerator rotates and all planning and radiation beam delivery for a daily treatment is performed relative to it.

For gynecological cancer treatment, the ultrasound image does not show the entire target because target definition is complex and composed of multiple structures. The purpose of

ultrasound is to visualize the vaginal canal (for hysterectomy patients) or uterus and cervix motion with respect to change in bladder filling volume and rectal motion. Daily changes of these organs relative to their planned locations can be found by ultrasound localization and treatment margins for organ motions can be adjusted accordingly to avoid geographical miss especially when patients are being treated with Intensity Modulated Radiation Therapy (IMRT).

For breast cancer treatment, ultrasound is used to image the lumpectomy cavity daily with each radiation treatment. This provides an actual visual image and location of the tumor cavity. The standard way to treat lumpectomy cavities is based on a reference CT scan before the radiation treatment course starts. Using 3D ultrasound, daily tumor bed is visualized with the excellent soft tissue imaging and shifts can be made to align the planned and treatment locations relative to the isocenter for the boost or partial breast treatments.

Ultrasound image use is user dependent and requires special skills to acquire good quality images compared to other imaging systems used in radiation therapy. This includes techniques for acquiring good images and evaluation of the images acquired.

In this chapter, we will review the application of 3D ultrasound imaging as a tool for daily image guidance in radiation therapy. Application of this imaging technique will be discussed for various tumor sites such as prostate, gynecological and breast cancers. We will also report on the findings of our clinical investigations for these disease sites. Quality assurance of the equipment and process, detailed scan acquisition techniques and steps for the use of ultrasound for the visualization of various tumors will also be provided based on our clinical experiences with the Resonant/Clarity system. Other ultrasound systems are commercially available, and they use similar techniques to visualize and localize targets. Finally, we will also provide a brief review of other imaging modalities that are used for target localization in radiation therapy and a comparison of each of these modalities as well.

2. Basic concepts for treatment planning and delivery in external beam radiation therapy

2.1 Linear accelerator

In radiation therapy, a beam (typically photons and/or electrons) is delivered from the linear accelerator toward a single point in space—the isocenter. The linear accelerator is a device that uses high-frequency electromagnetic waves to accelerate charged particles such as electrons to high energies (Mega voltage level) through a linear tube. High -energy electron beam or photon beam (electrons can be made to strike a target to produce X-rays) can be used for treating cancers. The linear accelerator rotates around the isocenter so that at every angle the central axis of the beam is directed through the isocenter. Therefore, within the patient, the target to be treated must be precisely placed relative to isocenter.

2.2 Target definition and prescription for treatment planning

The treatment target volume is initially identified and outlined by a radiation oncologist on a computed tomographic (CT) image. CT scan is the standard method for creating image based plans in radiation oncology. The visualized tumor is outlined as the gross tumor volume (GTV). A margin or shell is added to this GTV to include volumes that may be expected to contain cancerous cells that are too small to be visualized. This larger volume is the clinical target volume (CTV). An additional margin is added to the CTV to account for uncertainties due to day to day variations such as internal organ motions and setup of a

patient. This larger volume is the planning target volume (PTV) and is planned to receive the prescribed dose of radiation. The radiation oncologist's prescription defines the target, the type of radiation to be used, the total dose to be delivered to the target, the daily radiation dose per fraction to the target, the total number of fractions to deliver that dose, and any special instructions regarding how the dose is to be delivered. Typical radiation treatments are delivered daily for five to six weeks.

If imaging is to be used to localize the target, the special instructions will include the type and frequency of imaging to be done for this purpose.

2.3 Process of generating treatment plan

Once the target has been outlined and a prescription is written, a plan for delivering the prescription dose is developed by physicists/dosimetrists with treatment planning software. Planning software needs CT scan images for dose calculations and simulation. The plan determines the angles from which the linear accelerator will deliver a radiation beam for selected beam energy (within the parameters of the prescription), the shape of treatment fields (or portals) for each beam angle, and any special devices in the path of the beams to further tailor them. The portals are shaped using blocks or a series of thin leaves collectively referred to as a multi-leaf collimator (MLC). The blocks or MLCs must be sufficiently thick (parallel to the beam direction) to block nearly all of the radiation outside of the block or MLC opening so that it can attenuate the beam to an intensity of less than 5.0 percent, and each leaf of the MLC must be thin enough, typically 5.0mm or 10.0mm at the level of isocenter, and perpendicular to the beam direction to conform to the PTV shape.

In addition to covering the PTV with the prescription dose, the treatment plan must limit dose to nearby critical structures. All tissues within the human body have tolerances of radiation dose that they can receive before the risk of radiation damage becomes significant. Conventionally generous margins are applied around the target to incorporate uncertainties due to organ motion and setup error. This ensures that the PTV receives the prescription dose. However, this can result in an increased dose to the normal tissues thus increasing risks of normal tissue complications. Maximizing setup accuracy is one of the most important ways to reduce the margin added to the CTV and thus reduce risks of normal tissues complications.

Daily imaging of the target on the linear accelerator is an accurate way to localize it relative to the isocenter and a key factor in aligning the patient so that the planned dose is delivered to the target and critical structures are spared.

2.4 Verification and confirmation of daily patient setup

Once the plan is completed, the radiation oncologist will review it and subsequently approve the final plan. The patient will then be scheduled for a confirmation simulation by radiation therapists. During confirmatory simulation, the patient is setup on a special table that is used to move the patient so that the target is aligned to the isocenter as planned. Images are taken to confirm isocenter location and shape of beam portals if necessary. Once in the final position, the patient's skin is marked at the points where the central axis of the beam enters the skin directly from above and from both sides (these are orthogonal angles). The radiation oncologist reviews and approves these images before the patient is treated.

Each day the patient is setup using the skin marks placed during the confirmatory simulation to align the target to the isocenter. Room lasers, sagittal, vertical and lateral are used for this setup. The margins in the PTV must account for the uncertainties of where the

target is relative to the skin marks. Daily imaging reduces much of this uncertainty by directly viewing internal soft tissues or fiducial markers placed inside the tumor. Small (e.g. 1 mm diameter and 5 mm long) fiducial markers are radio-opaque to kilovoltage radiation and are therefore well visualized in kilovoltage images. They can be implanted into soft tissues to assist with comparing daily images to reference images. These images can be reviewed daily by the radiation oncologist before treatment is delivered.

Several types of daily imaging are now used in radiation oncology to aid in Image Guided Radiation Therapy (IGRT). These new innovative technologies include megavoltage (MV) and kilovoltage (KV) X-ray energies to acquire individual radiographs or cone beam CT (CBCT). Also, ultrasound images—either planar or volume images—can be used for daily localization of certain targets such as gynaecological, prostate, or breast.

In next couple of sections, 3D ultrasound application as an IGRT in radiation oncology will be reviewed.

3. Applications of ultrasound imaging in prostate cancer

The prostate location is particularly conducive to ultrasound imaging in that it is located beneath the bladder which when full creates a favourable ultrasound path from the skin surface of the lower abdomen to the prostate. The bladder-prostate interface is well visualized.

In addition, the prostate is displaced by rectal and bladder filling. This displacement is unpredictable and can approach 2 cm (Scarborough et al., 2006). Such a large displacement is rare (typically less than 7 % of the time). A few millimetres are more typical on a daily basis, and it is less than 1 cm (0.8 – 0.9 mm) with a 95 % confidence interval (Scarborough et al., 2006; Serago et al., 2006). Therefore, 1 cm is a typical expansion around the prostate CTV to create the PTV without imaging (Hanks et al., 2000; Boersma et al., 1998). With daily ultrasound imaging, we have found that the 95 % confidence interval is reduced to 0.7 cm which agrees with Serago et al (Serago et al., 2006). Boda-Heggemann et al and Langen et al also demonstrated that ultrasound imaging improves prostate localization (Boda-Heggemann et al., 2008; Langen et al., 2003). Serago et al and Langen et al identified a significant improvement in localization in the anterior-posterior direction which is the direction of largest prostate displacement because of rectal filling (Serago et al., 2006; Langen et al., 2003). Further, the rectum and bladder are adjacent to the prostate, but are critical structures that should be spared as much dose as is possible without compromising the delivery of the prescribed dose to the prostate.

Prescribed total doses of 70 to 78 Gy to the entire prostate at 1.8 Gy per daily fraction are common for treating prostate cancer (Pollack et al., 2002). Because of the proximity of the bladder and rectum to the prostate, a portion of each of these organs typically receives the entire dose. In order to avoid serious toxicities to these organs, their volumes receiving such large doses of radiation must be limited. A recent review of the literature evaluating bladder and rectal tolerances to radiation has suggested the following dose constraints (Michalski et al., 2010; Viswanathan et al., 2010): (Table 1)

Toxic effects are graded using one a few standardized criteria including the Common Terminology Criteria for Adverse Events version 3.0 (CTCAE 3.0) and Radiation Therapy Oncology Group (RTOG) scoring criteria. Long term toxic effects can include rectal stricture, rectal bleeding, diminished rectal compliance, decreased storage capacity with resultant small and frequent bowel movements, urgency to empty the bladder frequently,

incontinence, reduced flow, bladder spasms, hematuria, fistula, obstruction, ulceration, and necrosis (Michalski et al., 2010; Viswanathan et al., 2010). The tabulated limits are expected to avoid these serious long term toxic effects in 90% or more of patients (Michalski et al., 2010; Viswanathan et al., 2010). These criteria were developed over many years without the benefits of daily localization; however, daily localization can be expected to help reduce the doses to these critical structures (Michalski et al., 2010; Viswanathan et al., 2010) by helping us treat with smaller margins thereby reducing toxic effects of radiation.

Specified Dose	Percentage of Organ Volume Receiving Greater than Specified Dose (%)	
(Gy)	Bladder	Rectum
50		50
60		35
65	50	25
70	35	20
75	25	15
80	15	

Table 1. Summary of critical organ and dose volume limits in prostate cancer treatment

Each day the new ultrasound image is aligned to the reference image right before a treatment starts. Our technique included acquiring a reference ultrasound image at the time of initial CT scan for the planning.

At this time, positioning reference volume (PRV) of prostate from ultrasound scan (US) is created and this PRV is compared to daily US image during radiation treatment. The reference ultrasound image is aligned to the planning CT image with the co-registration of the planning CT and PRV to confirm that the prostate, bladder, and rectum are well localized and readily visible on both images near the prostate. It is not necessary to visualize the entire bladder or rectum in order to localize the prostate in US image. However, patient positioning is critical. Ultrasound image is acquired by pressing the ultrasound probe against the patient’s lower abdomen and rolling it in the sagittal plane while continuously acquiring ultrasound image slices. These slices are then reconstructed based on the position and tilt of the ultrasound probe relative to the reference point to create a 3D image of the patient.

The images are acquired through the bladder which serves as a high transmission interface between the skin and the prostate. It is therefore necessary that the bladder be relatively full. In order to accomplish this, patients are asked to drink 16 ounces of fluid 30 minutes before the simulation and every day of treatment. Each day the patient’s skin marks are used to align the patient to isocenter. An ultrasound is acquired in the same way that it was acquired at the time of the planning CT. The newly acquired image is then compared to the PRV and the images of the prostates are aligned Fig 1. This alignment requires a directional couch shift which is then made. The treatment is then delivered.

Other localization techniques exist such as kilovoltage and megavoltage imaging, and fiducial markers implanted into the prostate can be used. Studies have demonstrated that ultrasound localization is not as precise as these other localization techniques particularly when implanted fiducial markers are used where it is possible to align the prostate to within 4mm at the 95% confidence interval (Moseley et al, 2007). However, kilovoltage and

megavoltage imaging use ionizing radiation which may have long term radiation effects, and implanting fiducial markers is an invasive procedure. Ultrasound can therefore be considered an alternative localization method.

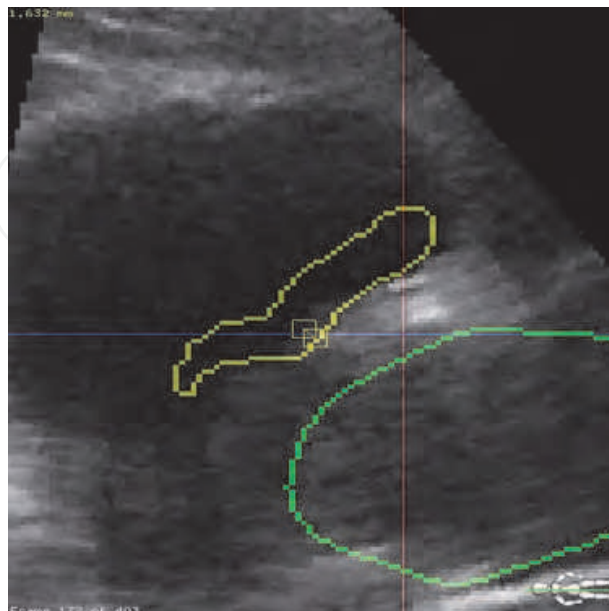


Fig. 1. Contour of the PRV and inferior bladder wall aligned on a daily ultrasound in the sagittal view.

4. Applications in gynaecological cancers

For gynaecological cancers (endometrial cancer or cervical cancer), clinical target volume (CTV) definition for external beam radiation therapy is more complex compared to other cancer sites. It has been challenging to create accurate PTV margins because the CTV is composed of multiple structures and they move relative to each other as well as deform during the radiation therapy course. Also adjacent normal tissues move randomly daily. In order to reproduce a daily consistent setup, patients are instructed to empty their rectum and have a full bladder before the acquisition of planning CT and radiation treatment.

4.1 Anatomy and organ motions

Pelvic anatomy consists of movable organs such as small bowel, sigmoid, bladder, rectum, and cervix/uterus. With radiation therapy for gynaecological cancer treatment, there are risks of small bowel and bladder complications due to anatomical close relationship. A full bladder can push away small bowel out of the radiation field and reduce target motion (cervix/uterus) variability. Therefore, it is important to have a full bladder prior to the acquisition of planning CT and the daily radiation treatments. This also ensures consistency and reproducibility of target positioning daily during radiation treatment. All patients who undergo radiation treatments are given guidelines for bladder filling.

4.2 Ultrasound images with full bladder for daily treatment

Patients are instructed to drink 24-32oz of water or fluids 30 minutes prior to scanning for daily treatment. Bladder is an easy structure to identify in ultrasound image and full

bladder impacts the ultrasound image quality by enhancing the image and sharpening the edge between bladder and uterus/cervix/vaginal canal. (Fig.2) For cervical cancer patients with an intact uterus, the vaginal canal, cervix and uterus are posterior to the bladder (Fig.3). For patients who had a hysterectomy, only the vaginal canal is seen posterior to the bladder.

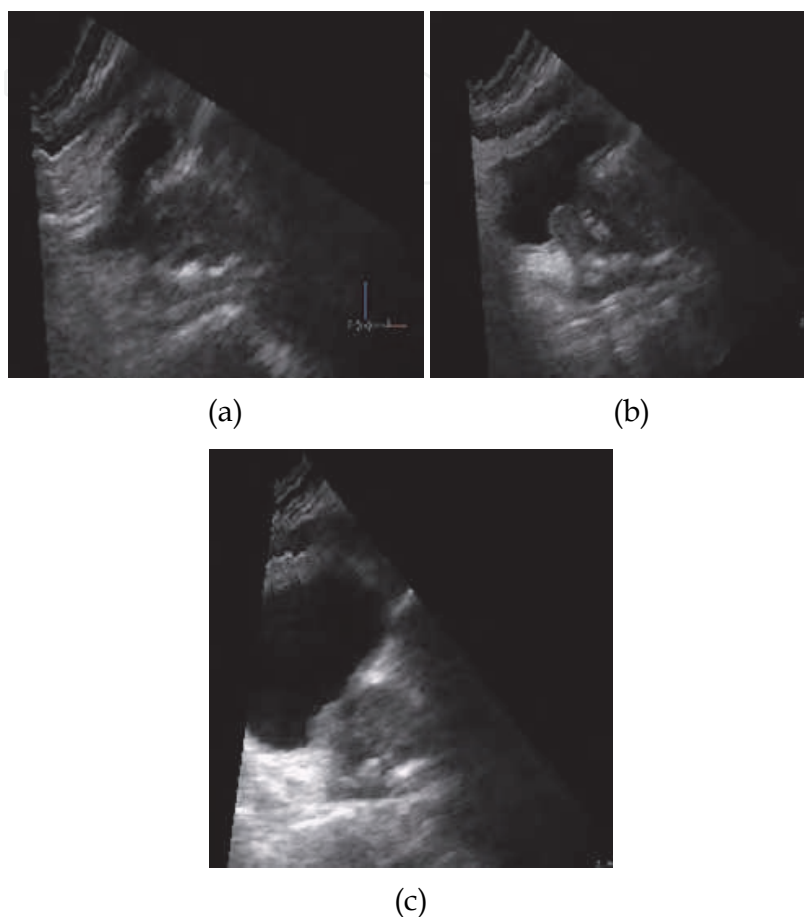


Fig. 2. a. Empty bladder, b. Partially filled and c. Full bladder in ultrasound images. Used with permission of the Resonant/Clarity.

Before radiation therapy is started for each patient, a treatment planning CT scan is done with a full bladder followed by acquisition of an ultrasound scan. The reference ultrasound image is aligned to the CT image. At this time, a positioning reference volume (PRV) of the bladder from the ultrasound scan (US) are created and this PRV are compared to the daily US images taken during radiation treatment course.

The US image is acquired as follows. The US probe is placed with firm pressure on the pubic symphysis and slowly rotated. The probe is then swept across the abdomen toward the patient's head. Since a full bladder provides good propagation of the sound waves, the uterus/cervix/vagina images are acquired by scanning through the bladder. As seen from Fig. 4, the outline of bladder and other organs such as the uterus, cervix and vaginal canal can be drawn on the US image directly, and their volumes can be measured too. After acquisition of the daily US image, 3D reconstructions of the images are made. These 3D images are then used for the calculation of any directional shift that are necessary for target alignment prior to radiation treatment (Fig.5) Also, with the co-registration of the planning

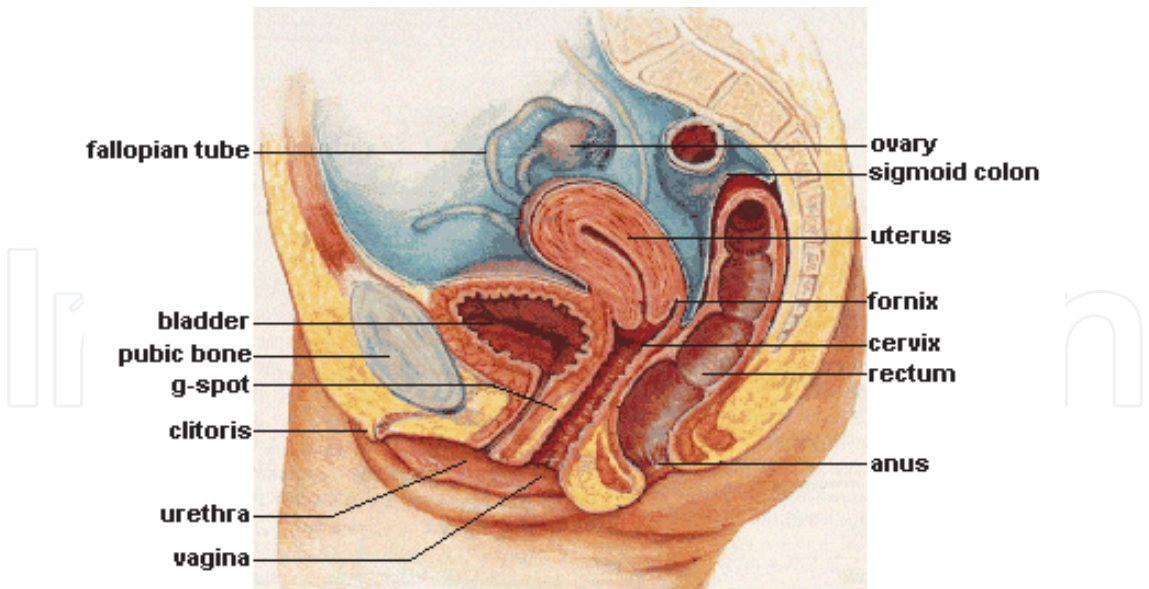


Fig. 3. Anatomy location of bladder, vaginal canal, cervix and uterus.

CT and the reference US image, the radiation treatment fields (each portal) and target contours can be overlaid on the daily US images as a verification of the setup of the patient prior to daily treatment (Fig. 6). However, patient repositioning solely by daily US imaging for gynaecological cancers is questionable because the target is of complicated shape and is composed of multiple other structures such as the common iliac, external iliac, and internal iliac with inguinofemoral and periaortic nodes as well as the uterus, cervix, parametrium and vagina. As mentioned before, ultrasound can only image the vaginal canal and uterus in the target. In our clinic, as shown in Fig 6, daily US image is compared to the PTV contour from the planning CT and verified if the uterus/cervix or vaginal canal is still within the PTV. This is a major difference in using US images as an IGRT method between gynecological use and other disease sites use such as prostate and breast.

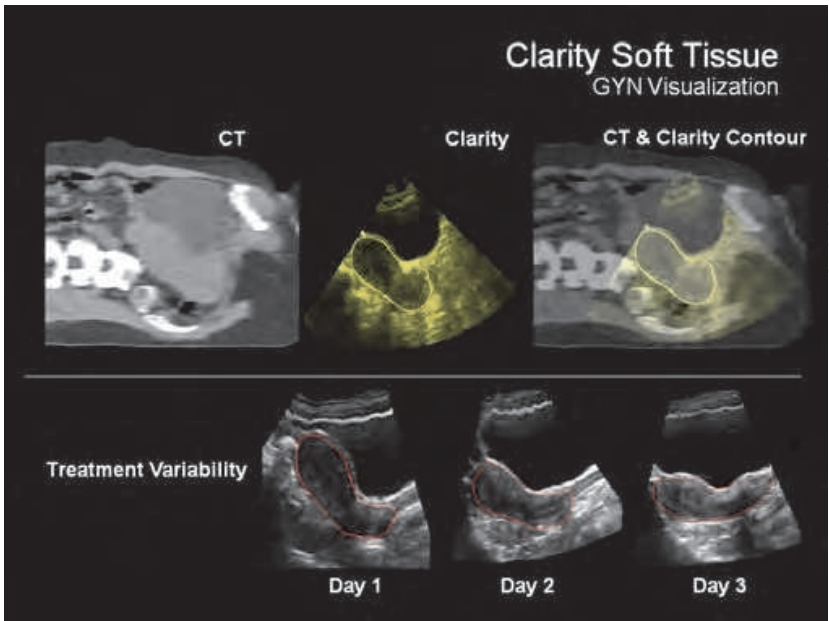


Fig. 4. Daily US image. Used with permission of the Resonant/Clarity.

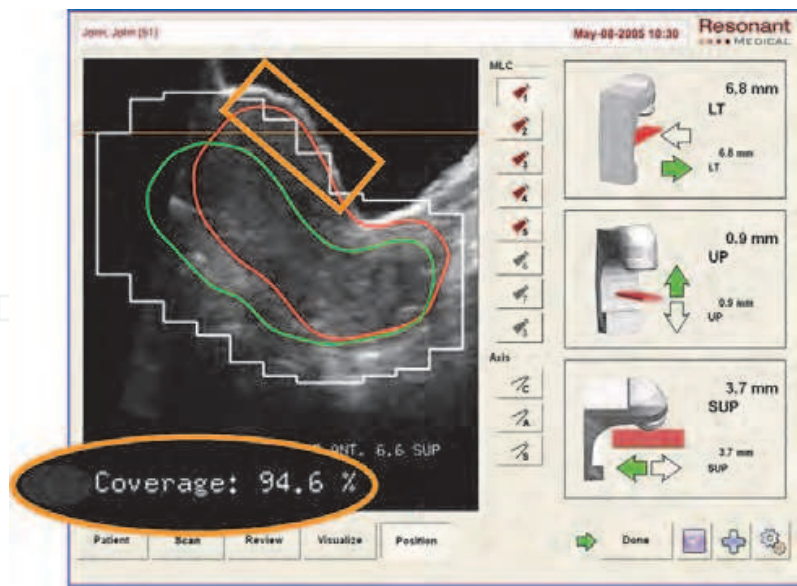


Fig. 5. Daily US image and PRV comparison and calculated positional shift. Used with permission of the Resonant/Clarity.

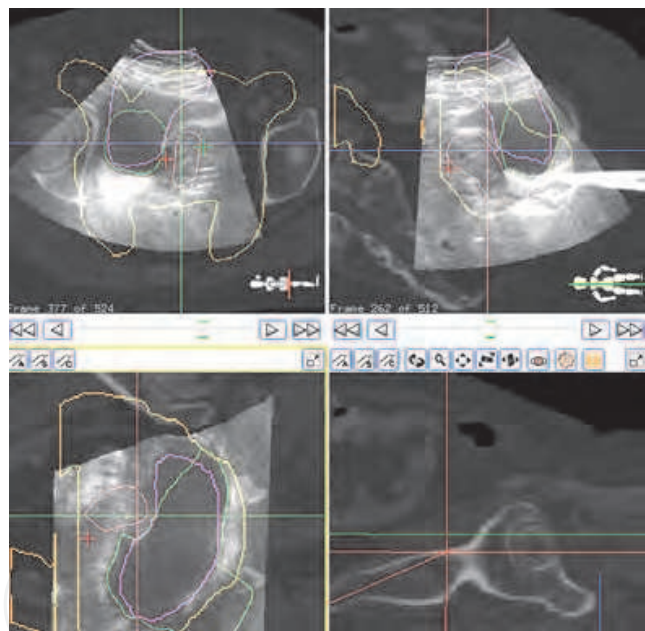


Fig. 6. Image co-registration of planning CT and US PRV with PTV contours from CT overlaid to daily US. Orange colored shape is PTV defined in CT image. Pink shows bladder on reference CT and green for bladder with daily US.

4.3 Clinical data for bladder and target motion during radiation treatment course

Data quantifying bladder motion during radiation therapy have been published in the literature (Ahmad et al., 2008; Jhingran et al., 2010; Jurgenliemk-Schulz et al., 2011; Lim et al., 2009; McBain et al., 2009; Thawani et al, 2008; Yee et al., 2010). From the experiences gained with US imaging at our institution we found that inter-fraction bladder volume variations are prominent for gynaecological cancer treatments. Mean bladder volume was 254.2 cc with a standard deviation of 138.5 cc for 202 fractions with 11 patients.

From these patients, it was found to be a bladder volume change more than 30% compared to their PRV in 40%-94% of total treatment fractions.

A US study of 24 cervical patients by Ahmad et al. (2008) found that bladder volume decreases dramatically during the treatment course compared to the planning CT scan (mean total reduction of 71%). Using US imaging, McBain et al. (2009) investigated bladder volume change during the treatment course. Of the 24 patients studied, they found that seven patients had more than a 50 % volume change during the treatment course. Lim et al. (2009) assessed bladder volume change using weekly MRI scan for twenty cervical patients. They found bladder volume change of 7- 450% relative to baseline volumes.

Studies have shown that inter-fraction changes in bladder volume are unpredictable and it is very difficult to reproduce the daily bladder filling even though written and verbal instructions are given to patients. Because target location depends on the fullness of the bladder, the reproducibility of the target location daily cannot be guaranteed. Daily ultrasound imaging can help ensure that the change in target volume with respect to bladder filling is accounted for by PTV margin and if not then the margins should be adjusted for individual patient to avoid geographical miss.

Although many published data show that uterus/cervix positions can be at different locations depending on bladder filling (Ahmad et al., 2011; Buchali et al., 1999; Chan et al., 2004; Han et al., 2006; Huh et al., 2004; Jhingran et al., 2010; Kerkhof et al., 2009; Taylor & Powell, 2008; Van de Bunt et al., 2008), one study reported recently that motion of the vagina after the hysterectomy varies in a random manner daily and found no correlation with changes in bladder and rectum volumes (Jurgenliemk- Schulz et al. ,2011). Also some studies claimed that uterus and cervix motion are weakly correlated with bladder and rectum filling status because change in target motion not only depends on adjacent bladder and rectal filling but also depends on tumor regression and deformation with a patient-specific correlation (Huh et al., 2004; Van de Bunt et al., 2008).

On the contrary, consistent clinical investigations with prostate demonstrate that the prostate motion strongly depends on bladder and rectum filling (Pinkawa et al., 2006; Schild et al.,1993; Stam et al, 2006; Ten Haken et al., 1991; Thawani et al, 2008; Van Herk et al., 1995)

5. Image guidance to minimize dosimetric impact on target and organs at risk

IMRT¹ has been proven to be beneficial and superior to conform the dose distribution to targets and spare critical organs reducing morbidity and toxicity by using sharp dose gradient compared to other conventional radiation therapy techniques. Thus IMRT is more attractive for the treatment of gynaecological and prostate cancer because of better tumor control and sparing critical organs thereby reducing the organ toxicity (Beriwal et al., 2006; Cahlon et al., 2008). As dose distribution has sharp gradient with IMRT, it is important to localize the target daily in order to reproduce the dose to critical organs and target as

¹ Intensity-modulated radiation therapy (IMRT) is an advanced mode of high-precision radiotherapy that utilizes computer-controlled linear accelerators to deliver precise radiation doses to a malignant tumor or specific areas within the tumor. IMRT allows for the radiation dose to conform more precisely to the three-dimensional (3-D) shape of the tumor by modulating the intensity of the radiation beam . IMRT also allows higher radiation doses to be focused to regions within the tumor while minimizing the dose to surrounding normal critical structures.

planned from the initial planning CT. The use of IGRT is critical to accomplish this goal because it enables localization of the target prior to treatment and thus account for inter-fraction motion.

6. Applications in partial breast irradiation or electron boost treatment

Standard of care for early stage breast cancer is to deliver photon radiation to the whole breast after segmental mastectomy (lumpectomy) as a breast conserving surgery. The photon radiation is followed by the electron radiation as a boost to the tumor bed (surgical cavity). The total treatment period is about 6-7 weeks of which whole breast radiation takes 5-6 weeks in 25-28 fractions and the boost is delivered in 4-8 fractions. This approach is well tolerated and has good cosmetic result with local control rates comparable to a mastectomy (Fisher et al., 1994, 2002; Holland et al., 1985; Veronesi et al., 2002).

An alternative technique to this standard approach is the APBI (accelerated partial breast irradiation) technique. In this technique radiation targeting is to the tumor bed area only instead of the whole breast. The reason is that high local recurrence of the tumor occurs at the primary tumor sites after the lumpectomy (Clark et al., 1987; Liljegren et al., 1999; Veronesi et al., 2002). APBI helps to avoid radiating normal tissue unnecessarily which will reduce the morbidity. Also, APBI offers a shorter treatment course (one week with twice daily treatments in contrast to 6-8 weeks for whole breast radiation therapy) which may be favourable over the conventional whole breast treatment technique.

6.1 Ultrasound imaging for tumor bed delineation

Historically, the palpable tumor bed predicted from the scar position on the skin with a clinical margin was the clinical description of the boost volume. This method has shown to inaccurately define the tumor bed and dosimetry is poor (Benda et al., 2003; Landis et al., 2007; Ringash et al. 2004). An ideal method for the delineation of the surgical cavity for the boost volume has not been established (Landis et al., 2007; Ringash et al., 2004). Ultrasound, MRI and CT scans with or without surgical clips are the currently available techniques for identifying the boost volume. Various studies reported difficulties in contouring the boost volume in CT images because of poor seroma clarity from the surrounding tissue specifically in patients with dense breast parenchyma (Berrang et al., 2009; Landis et al., 2007; Petersen et al., 2007). This can lead to high inter-observer variability. 3D US for defining the breast boost volume has been introduced recently. Unlike CT images, US can differentiate fluid-filled cavity (which is the lumpectomy cavity) from the surrounding tissue with high specificity because of excellent soft tissue imaging characteristics (Smitt et al., 2001; Yang & Dempsey, 2007; Weinstein et al., 2006). This helps to identify the tumor bed volume more accurately and has an improved inter-observer consistency.

6.2 Tumor bed volume localization between US and CT

Before daily treatment, the US probe is swept over the area near the surgical scar in one direction until the lumpectomy cavity is located. After the cavity is identified, it is compared to the PRV which is created at the time of the planning CT and directional shifts are made based on the comparison. Procedures for the CT and US scans at the time of planning CT are explained in previous sections.

Fig 7. shows a comparison of US to CT for tumor bed volume.

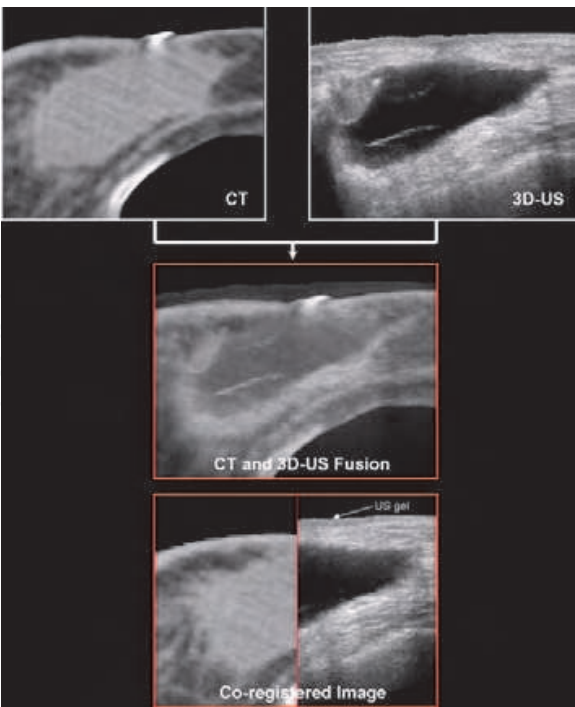


Fig. 7. Co-registered images of US and CT for a tumor bed. Used with permission of the Elsevier (International Journal of Radiation Oncology, Biology, Physics., vol. 73, No.2, pp 375-383,2009)

CT overestimates the true tumor bed volume compared to US images. One study (Wong et al., 2011) reported that the average difference of the tumor bed volume between US and CT is 55% because the seroma or fluid cavity is well visualized in US, but not as well in CT. On a CT scan, the fluid cavity plus the fibrotic tissue surrounding the cavity are drawn as the cavity/seroma. Fig.8 is one example.

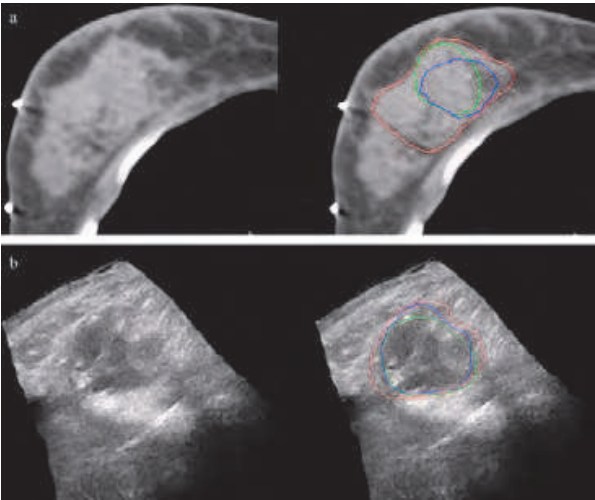


Fig. 8. Poor correlation between US and CT for the low seroma clarity from the CT. Upper: On CT image there are three different tumor bed drawn (low interobserver conformity index). Lower: improved interobserver conformity index with US guidance. Used with permission of the Elsevier (International Journal of Radiation Oncology, Biology, Physics., vol. 73, No.2, pp 375-383,2009)

6.3 Inter-fractional changes in tumor bed volume and position with US study

By the use of 3D US, daily localization of the tumor bed becomes viable. Few studies have quantified tumor bed volume changes during the course of treatment (Prendergast et al., 2009). Redefining the tumor bed right before the boost treatment will give a better assessment for the boost volume, and the ultrasound image provides a convenient method for this without giving extra dose to the patient. Wong et al., (2011) reported that the average tumor bed displacement in the radial direction was 10.8 mm with a standard deviation of 6.3 mm, and 50% of the time the fractions had displacements. Other study (Weed et al., 2004) using surgical clips or CT images identified average displacements of 3mm in the radial direction. This suggests that tumor bed localization is important and 3D US scans can play an important role in an assessment of surgical bed and localization before treatment. This is particularly important for 3D conformal or IMRT for accelerated partial breast radiation (APBI techniques) where better daily targeting becomes critical.

7. Technical issues

Acquiring ultrasound images requires special skill in the radiation oncology department because technicians, physicists, and physicians are not typically trained to scan and review ultrasound images. Traditionally ultrasound images have been reviewed by radiologists/radiology technicians. Technical skills for acquiring US images for different body sites by the radiation oncology staff can be highly user dependent thus affecting acquired image quality. In the absence of proper training, the interpretation of US images by the radiation staff can also be highly user dependent. Special consultation by a radiologist is thus needed until the radiation oncology staff is properly trained with this imaging modality.

The Resonant/Clarity ultrasound system for IGRT requires establishment of correspondence between the planning CT, acquired ultrasound images in the CT room and the treatment images acquired at the treatment vault. This is done by establishing an appropriate calibration procedure. In this way, the US workstations can create and save the PRV as a reference image by the image co-registration process, sharing the same coordinates with the treatment machine from the fusion of CT and the US images. MR and CT images are fused by mathematical methods such as pixel data or bony anatomy matching, and PET and CT images are fused by the automatic dicom match method. However, fusion of US and CT images is more challenging if it is done with manual registration, and it needs more careful consideration to achieve an accurate image co-registration if the images do not share a common reference point.

8. Quality assurance

As explained in previous sections, the US system is used for daily verification of the patient position as well as creating a reference volume for the target localization when fused with the CT images for a treatment plan. A calibration phantom is used to check the performance of the system which is referred to as a Quality Assurance (QA). QA for the Ultrasound system consists of the system integrity check (mechanical function), isocenter verification, directional shift calculation, imaging quality check and software performance check. Daily QA and monthly QA are routine check-ups for the system.

8.1 Daily QA

As a daily check, isocenter accuracy verification and directional shift calculations are performed by a therapist. The linear accelerator beam is calibrated at the isocenter and

intersections of the CT room lasers and treatment room lasers are referenced to the isocenter. The calibration phantom that contains a positional guidance volume (PGV) is used for QA. The phantom is calibrated at the isocenter by using the optical tracking camera in the system. The PGV has a known 3D coordinate position shared with the treatment room and CT unit lasers, and it can be verified with daily US scans. The calibration phantom is set up with the room lasers (at the isocenter) and scanned with the US probe. After the PGV is reconstructed, a 3D view of the US shows the isocenter coordinate. It is then compared to the known coordinates (reference value) by image co-registration between the reference PGV of the phantom and the daily PGV. Directional shifts and offsets are calculated (Fig 9). Tolerance level in isocenter position is 2.0mm in radiation therapy. Isocenter verification is done at CT room and treatment room both.

As for directional shifts calculations, it is performed at the treatment room after the isocenter accuracy is checked. The couch is moved from isocenter by a known amount of offset in all three directions (anterior-posterior, superior-inferior, medial-lateral), and the phantom is scanned. After reconstruction of the PGV is done, 3D coordinates are calculated and checked if the offset is correctly calculated.

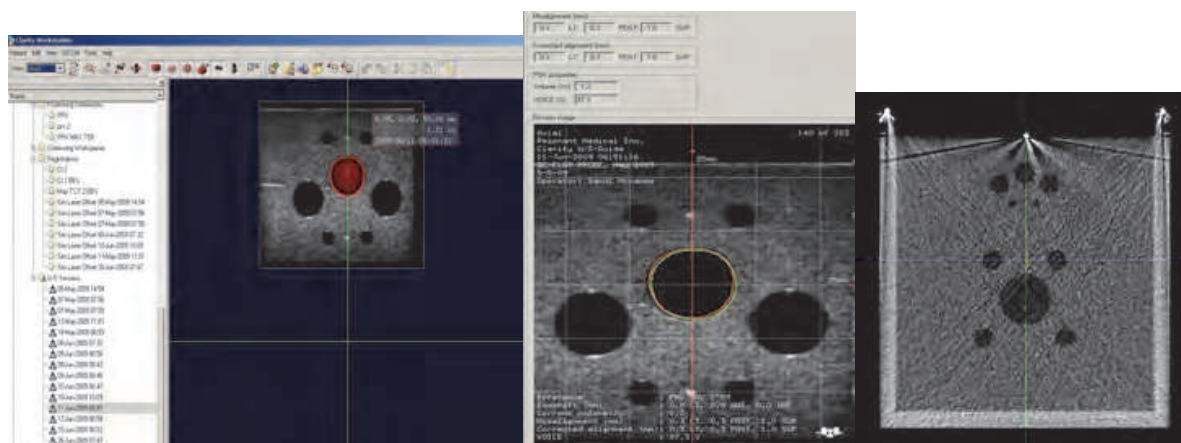


Fig. 9. Daily QA : Green circle is the reference PGV and red one is daily scan image of PGV: left image shows 3D coordinates of daily scan, middle image for comparison and directional shift between reference and daily PGV, right image is the QA phantom.

8.2 Monthly QA

The physicist performs monthly QA. For monthly QA, daily QA is repeated along with additional checks such as verification of the phantom PGV image in the US and CT images, registration of US and CT images, image reconstruction, and system integrity tests. A CT scan of the calibration phantom is performed and an US scan follows. Image co-registration is performed by fusing both images, the PGV is contoured, and the size of the PGV is measured and compared in both images. After that, the phantom is placed in the treatment room and the daily QA is performed. System functionality is checked for the each part of the system.

9. Other image modalities in radiation therapy

KV/MV verification imaging systems for patient set up such as kV planar images, kV CBCT, MV CBCT and MV portal images have been accepted more widely in radiation oncology

community for IGRT than US systems. In contrast to US systems, these other IGRT systems are integrated with the linear accelerator (Fig 10.) making data transfer and connectivity between treatment machine and imaging device easier. MV portal images have the oldest history for patient setup verification and renders verification only of bony anatomy because of the poor image quality from the MV photon beams. In addition, MV portal imaging can't be taken on a daily basis because of the extra dose from the high energy therapeutic MV beams. Traditionally portal images are taken once a week. kV x-ray based OBI (2D planner images) provides better image quality. It allows verifying the bony anatomy as well as soft tissues, and daily imaging can be acceptable because of low extra doses. CBCT can provide 3D volumetric images and renders visualization of soft tissue targets as well as adjacent organs. Although doses from kV imaging are low it still gives extra daily dose to a patient and careful consideration for the daily extra dose needs to be investigated.

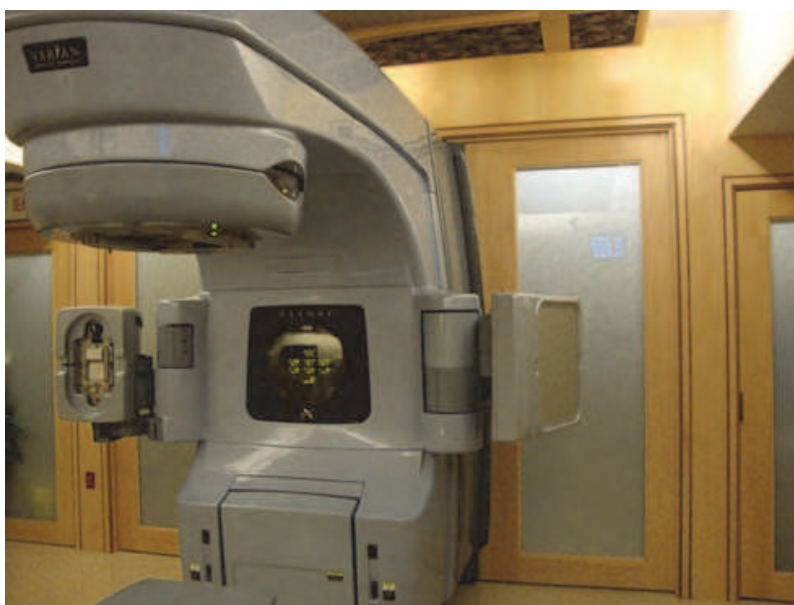

Fig. 10. Linear Accelerator with kV imaging arms attached. VARIAN 23 iX with OBI (On Board Imager).

10. Conclusion

Ultrasound application as IGRT in radiation therapy has been established. Because it is non-ionizing, provides excellent soft tissue image quality and non invasive in nature, it can be beneficial as an IGRT tool for radiation patients. The drawback of this technique is user dependence, challenging learning curve for radiation oncology staff and applicability to few disease sites only. Besides, it also doesn't account for intrafraction motion which is also important for daily target localization. Nevertheless, ultrasound guidance has been useful for daily localization in target position such as prostate, breast and gynaecological cancers as well as for monitoring inter-fractional bladder filling status and organ motion.

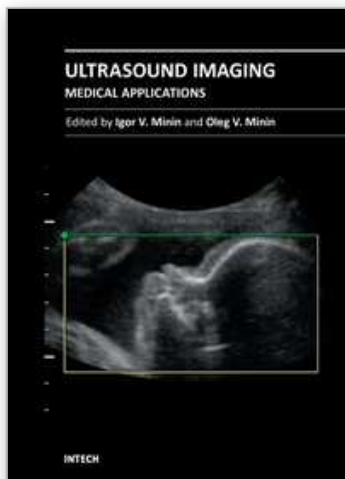
11. References

Ahmad, R et al (2008) Inter-fraction bladder filling variation and time trends for cervical cancer patients assessed with a portable 3-dimensional ultrasound bladder scanner.

- Radiotherapy and Oncology*, Vol. 89, No.2, (November 2008), pp. 172-179, ISSN 0167-8140
- Ahmad, R et al (2011) Increasing treatment accuracy for cervical cancer patients using correlations between bladder-filling change and cervix-uterus displacements: Proof of principle. *Radiotherapy and Oncology*, In Press, (n.d.2011), ISSN 0167-8140
- Benda, RK et al (2003) Breast boost: Are we missing the target? *Cancer*, Vol. 97, No. 4, (February 2003), pp. 905-909, ISSN 1097-0142
- Beriwal, S et al (2006) Clinical outcome with adjuvant treatment of endometrial carcinoma using IMRT. *Gynecologic Oncology*, Vol. 102, No.2, (August 2006), pp. 195-199, ISSN 0090-8258
- Berrang, T et al (2009) 3D ultrasound can contribute to planning CT to define the target for partial breast radiotherapy. *International Journal of Radiation Oncology, Biology, Physics*, Vol. 73, No.2, (February 2009), pp. 375-383, ISSN 0360-3016
- Boda-Heggemann, J et al (2008) Accuracy of Ultrasound-Based (BAT) Prostate-Repositioning: A Three-Dimensional On-Line Fiducial-Based Assessment with Cone-Beam Computed Tomography. *International Journal of Radiation Oncology, Biology, Physics*, Vol. 70, No. 4, (2008), pp. 1247-1255, ISSN 0360-3016
- Boersma, L et al (1998) Estimation of the Incidence of Late Bladder and Rectum Complications after High-Dose (70-78 Gy) Conformal Radiotherapy for Prostate Cancer, Using Dose-Volume Histograms. *International Journal of Radiation Oncology, Biology, Physics*, Vol. 41, No. 1, (1998), pp. 83-92, ISSN 0360-3016
- Buchali, A et al (1999) Impact of the filling status of the bladder and rectum on their integral dose distribution and the movement of the uterus in the treatment planning of gynaecological cancer. *Radiotherapy and Oncology*, Vol. 52, No.1, (January 1999), pp. 29-34, ISSN 0167-8140
- Cahlon, O et al (2008) Ultra high dose IMRT for localized prostate cancer :Toxicity and biochemical outcomes. *International Journal of Radiation Oncology, Biology, Physics*, Vol. 71, No.2, (June 2008), pp. 330-337, ISSN 0360-3016
- Chan, P et al (2008) Inter and intrafractional tumor and organ movement in patients with cervical cancer undergoing radiotherapy: A cinematic MRI point of interest study. *International Journal of Radiation Oncology, Biology, Physics*, Vol. 70, No.5, (April 2008), pp. 1507-1515, ISSN 0360-3016
- Clark, RM et al (1987) Breast cancer. Experiences with conservation therapy. *Am J Clin Oncol*. Vol. 10, No. 6, (December 1987), pp. 461-468, ISSN 0277-3732
- Fisher, B et al (1994) Conservative surgery for the management of invasive and non invasive carcinoma of the breast: NSABP trials. National Surgical Adjuvant Breast and Bowel Project. *World J Surg*, Vol. 18, No.1, (January 1994), pp. 63-69, ISSN 0364-2313
- Fisher, B et al (2002) Twenty year follow up of a randomized trial comparing total mastectomy, lumpectomy, and lumpectomy plus irradiation for the treatment of invasive breast cancer. *N Engl J Med*, Vol. 347, No.16, (October 2002), pp. 1233-1241, ISSN 0028-4793
- Han, Y et al (2006) Interfractional dose variation during intensity-modulated radiation therapy for cervical cancer assessed by weekly CT evaluation. *International Journal of Radiation Oncology, Biology, Physics*, Vol. 65, No.2, (June 2006), pp. 617-623, ISSN 0360-3016

- Hanks, G et al (2000) Dose Selection for Prostate Cancer patients Based on Dose Comparison and Dose Response Studies. *International Journal of Radiation Oncology, Biology, Physics*, Vol. 46, No. 4, (2000), pp. 823-832, ISSN 0360-3016
- Holland, R et al (1985) Histologic multifocality of Tis, T1-2 breast carcinomas. Implications for clinical trials of breast conserving surgery. *Cancer*, Vol. 56, No. 5, (September 1985), pp. 979-990, ISSN 1097-0142
- Huh, SJ et al (2004) Interfractional variation in position of the uterus during radical radiotherapy for cervical cancer. *Radiotherapy and Oncology*, Vol. 71, No. 1, (April 2004), pp. 73-79, ISSN 0167-8140
- Jhingran, A et al (2010) Vaginal motion and bladder and rectal volumes during pelvic intensity modulated radiation therapy after hysterectomy. *International Journal of Radiation Oncology, Biology, Physics*, In Press, (n.d. 2010), ISSN 0360-3016
- Jürgenliemk-Schulz, I et al (2011) Internal motion of the vagina after hysterectomy for gynaecological cancer. *Radiotherapy and Oncology*, Vol. 98, No.2, (February 2011), pp. 244-248, ISSN 0167-8140
- Kerkhof, E et al (2009) Intrafraction motion in patients with cervical cancer: The benefit of soft tissue registration using MRI. *Radiotherapy and Oncology*, Vol. 93, No.1, (October 2009), pp. 115-121, ISSN 0167-8140
- Landis, DM et al (2007) Variability among breast radiation oncologists in delineation of the postsurgical lumpectomy cavity. *International Journal of Radiation Oncology, Biology, Physics*, Vol. 67, No.5, (April 2007), pp. 1299-1308, ISSN 0360-3016
- Langen, K et al (2003) Evaluation of Ultrasound-Based Prostate Localization for Image-Guided Radiotherapy. *International Journal of Radiation Oncology, Biology, Physics*, Vol. 57, No. 3, (2003), pp. 635-644, ISSN 0360-3016
- Liljegren, G et al (1999) 10 year results after sector resection with or without postoperative radiotherapy for stage 1 breast cancer. A randomized trial. *J Clin Oncol*. Vol. 17, No. 8, (August 1999), pp. 2326-2333, ISSN 0732-183X
- Lim, K et al (2009) Pelvic radiotherapy for cancer of the cervix: Is what you plan actually what you deliver? *International Journal of Radiation Oncology, Biology, Physics*, Vol. 74, No.1, (May 2009), pp. 304-312, ISSN 0360-3016
- McBain, C.A. et al (2009) Ultrasound imaging to assess inter and intra fraction motion during bladder radiotherapy and its potential as a verification tool. *Clinical Oncology*, Vol. 21, No.5, (June 2009), pp. 385-393, ISSN 0936-6555
- Michalski, J et al (2010) Radiation Dose-Volume Effects in Radiation-Induced Rectal Injury. *International Journal of Radiation Oncology, Biology, Physics*, Vol. 76, No. 3, Supplement, (2010), pp. S123-S129, ISSN 0360-3016
- Moseley, D et al (2007) Comparison of Localization Performance with Implanted Fiducial Markers and Cone-Beam Computed Tomography for On-Line Image-Guided Radiotherapy of the Prostate. *International Journal of Radiation Oncology, Biology, Physics*, Vol. 67, No. 3, pp. 952-953, ISSN 0360-3016
- Petersen, RP et al (2007) Target volume delineation for partial breast radiotherapy planning: Clinical characteristics associated with low interobserver concordance. *International Journal of Radiation Oncology, Biology, Physics*, Vol. 69, No.1, (September 2007), pp. 41-48, ISSN 0360-3016
- Pinkawa, M et al (2006) Prostate position variability and dose- volume histograms in radiotherapy for prostate cancer with full and empty bladder. *International Journal*

- of *Radiation Oncology, Biology, Physics*, Vol. 64, No.3, (March 2006), pp. 856-861, ISSN 0360-3016
- Pollack, A et al (2002) Prostate Cancer Radiation Dose Response: Results of the M. D. Anderson Phase III Randomized Trial. *International Journal of Radiation Oncology, Biology, Physics*, Vol. 53, No. 5, (2002), pp. 1097-1105, ISSN 0360-3016
- Prendergast, B et al (2009) The dynamic tumor bed : Volumetric changes in the lumpectomy cavity during breast conserving therapy. *International Journal of Radiation Oncology, Biology, Physics*, Vol. 74, No.3, (July 2009), pp. 695-701, ISSN 0360-3016
- Ringash, J et al (2004) Accuracy of ultrasound in localization of breast boost field. *Radiotherapy and Oncology*, Vol. 72, No. 1, (July 2004), pp. 61-66, ISSN 0167-8140
- Scarborough, T et al (2006) Comparison of Ultrasound and Implanted Seed Marker Prostate Localization Methods: Implications for Image-Guided Radiotherapy. *International Journal of Radiation Oncology, Biology, Physics*, Vol. 65, No. 2, (2006), pp. 378-387, ISSN 0360-3016
- Schild, SE et al (1993) Movements of the prostate due to rectal and bladder distension: implications for radiotherapy. *Med Dosim*, Vol. 18, No. 1, (Spring 1993), pp. 13-15, ISSN 0958-3947
- Serago, C et al (2006) Comparison of Daily Megavoltage Electronic Portal Imaging or Kilovoltage Imaging with Marker Seeds to Ultrasound Imaging or Skin Marks for Prostate Localization and Treatment Positioning in Patients with Prostate Cancer. *International Journal of Radiation Oncology, Biology, Physics*, Vol. 65, No. 5, (2006), pp. 1585-1592, ISSN 0360-3016
- Smitt, MC et al (2001) Breast electron boost planning: Comparison of CT and US. *Radiology*, Vol. 219, No.1, (April 2001), pp. 203-206, ISSN 0033-8419
- Stam, MR et al (2006) Bladder filling variation during radiation treatment of prostate cancer: can the use of a bladder ultrasound scanner and biofeedback optimize bladder filling? *International Journal of Radiation Oncology, Biology, Physics*, Vol. 65, No.2, (June 2006), pp. 371-377, ISSN 0360-3016
- Taylor, A & Powell, M (2008) An assessment of interfractional uterine and cervical motion: Implications for radiotherapy target volume definition in gynaecological cancer. *Radiotherapy and Oncology*, Vol. 88, No. 2, (August 2008), pp. 250-257, ISSN 0167-8140



Ultrasound Imaging - Medical Applications

Edited by Prof. Oleg Minin

ISBN 978-953-307-279-1

Hard cover, 330 pages

Publisher InTech

Published online 23, August, 2011

Published in print edition August, 2011

This book provides an overview of ultrafast ultrasound imaging, 3D high-quality ultrasonic imaging, correction of phase aberrations in medical ultrasound images, etc. Several interesting medical and clinical applications areas are also discussed in the book, like the use of three dimensional ultrasound imaging in evaluation of Asherman's syndrome, the role of 3D ultrasound in assessment of endometrial receptivity and follicular vascularity to predict the quality oocyte, ultrasound imaging in vascular diseases and the fetal palate, clinical application of ultrasound molecular imaging, Doppler abdominal ultrasound in small animals and so on.

How to reference

In order to correctly reference this scholarly work, feel free to copy and paste the following:

Hayeon Kim, Edward Brandner, M. Saiful Huq and Sushil Beriwal (2011). Clinical Application of Ultrasound Imaging in Radiation Therapy, *Ultrasound Imaging - Medical Applications*, Prof. Oleg Minin (Ed.), ISBN: 978-953-307-279-1, InTech, Available from: <http://www.intechopen.com/books/ultrasound-imaging-medical-applications/clinical-application-of-ultrasound-imaging-in-radiation-therapy>

INTECH
open science | open minds

InTech Europe

University Campus STeP Ri
Slavka Krautzeka 83/A
51000 Rijeka, Croatia
Phone: +385 (51) 770 447
Fax: +385 (51) 686 166
www.intechopen.com

InTech China

Unit 405, Office Block, Hotel Equatorial Shanghai
No.65, Yan An Road (West), Shanghai, 200040, China
中国上海市延安西路65号上海国际贵都大饭店办公楼405单元
Phone: +86-21-62489820
Fax: +86-21-62489821

© 2011 The Author(s). Licensee IntechOpen. This chapter is distributed under the terms of the [Creative Commons Attribution-NonCommercial-ShareAlike-3.0 License](https://creativecommons.org/licenses/by-nc-sa/3.0/), which permits use, distribution and reproduction for non-commercial purposes, provided the original is properly cited and derivative works building on this content are distributed under the same license.

IntechOpen

IntechOpen