

We are IntechOpen, the world's leading publisher of Open Access books Built by scientists, for scientists

6,900

Open access books available

185,000

International authors and editors

200M

Downloads

Our authors are among the

154

Countries delivered to

TOP 1%

most cited scientists

12.2%

Contributors from top 500 universities



WEB OF SCIENCE™

Selection of our books indexed in the Book Citation Index
in Web of Science™ Core Collection (BKCI)

Interested in publishing with us?
Contact book.department@intechopen.com

Numbers displayed above are based on latest data collected.
For more information visit www.intechopen.com



Use of Three Dimensional Ultrasound Imaging in Evaluation of Asherman's Syndrome

Catha Fischer and Alan Copperman
Mount Sinai School of Medicine in New York
USA

1. Introduction

Asherman's syndrome is defined as the presence of intrauterine adhesions or fibrosis within the uterine cavity that either partially or completely obliterate the cavity. It was initially described by Heinrich Fritsch in 1894 and then further characterized by Joseph Asherman in 1948. (1) The most common etiology of the disease is dilation and curettage due to pregnancy complications such as incomplete abortion, postpartum hemorrhage, or retained placenta. (2, 3) While the disease is rare within the general population, it is commonly cited as a factor in pregnancy complications in the infertile population. (4) Clinical manifestations of the disease include recurrent pregnancy loss, infertility, menstrual abnormalities, and cyclic pelvic pain. (5) The extent of intrauterine adhesions is graded and the severity of disease classified by extent of cavity obliterated, location of adhesions within the cavity, and character of the adhesions. (6) The American Society of Reproductive Medicine recommends classification of disease based on extent of cavity obliterated ($<1/3$, $1/32/3$, $>2/3$), quality of adhesions seen on hysteroscopy (filmy, filmy and dense, dense), and patient's menstrual pattern (normal, hypomenorrhea, amenorrhea). (7) At present, there are several modalities useful in the screening and diagnosis of Asherman's syndrome. In this chapter, we will discuss these modalities in detail, explaining the benefits and drawbacks of each. We also suggest that three dimensional sonography appears to enhance the physician's ability to provide an accurate diagnosis and prognosis to patients with Asherman's syndrome.

Traditionally, the diagnosis of Asherman's syndrome was made by history and physical examination. (1) Over time, direct visualization via hysteroscopy, hysterosalpingography, and sonography have all led to improved diagnostic accuracy. The hysterosalpingogram (HSG) is a procedure that provides an indirect means of evaluating the uterine cavity, since by injecting radio opaque dye transcervically, information can be gathered on the location and extent of adhesions. (8) Unfortunately, several studies have shown that hysterosalpingogram produces a large number of false positives, specifically in those whose cavities contain lesions other than intrauterine adhesions such as cervical stenosis, endometrial polyps, and myomas. (8, 9) Another drawback of this procedure is its inability to characterize the uterine cavity beyond where the radioopaque dye perfused, and thus potentially not identifying lower uterine segment outflow obstructions. Therefore, patients with normal cavities except for the presence of adhesions in the lower uterine segment will have hysterosalpingograms that appear similar to patients with

severe disease, thus having their disease severity incorrectly classified and potentially leading to treatment errors. (10) Furthermore, even in patients who did not have lower tract obstruction, HSG over-estimated disease severity compared to three dimensional ultrasound due to decreased clarity. (10)

Sonohysterography is another modality used to survey the uterine cavity for adhesions. It is a simple procedure that involves injecting sterile saline into the uterus to distend the cavity. The saline outlines the cavity aiding the operator in identifying structural abnormalities on the two dimensional ultrasound. Unlike hysterosalpingography, sonohysterography does not use radiation and can be done in an office setting. Initially, in small studies and case reports sonohysterography was thought to have diagnostic superiority to hysterosalpingography. (11,12, 13) However, when a larger study was conducted, it showed that two dimensional sonohysterography and hysterosalpingography have similar sensitivities both with high false positive rates. (9) At this point, it was suggested by these authors that the use of three dimensional ultrasound may in fact improve sonohysterographic accuracy. (9)

The use of two dimensional transvaginal ultrasound to identify intrauterine adhesions is controversial. In two dimensional ultrasound, sound waves are sent straight and reflected back in a linear vector, allowing for an image to be constructed only from the x and y planes. This modality is very operator dependent making its efficacy at diagnosing and prognosticating Asherman's syndrome difficult to accurately assess. In small studies, sensitivities of 80 to 90 percent for diagnosing intrauterine adhesions have been reported, however these numbers have not been reproduced. (14, 15) Rather, in another small series, two dimensional transvaginal ultrasound failed to diagnose intrauterine adhesions in any of the 4 cases in the study and gave 3 false positive diagnoses. (11) In a larger study that included 209 patients, two dimensional transvaginal ultrasound had a 97% sensitivity and 11% specificity at identifying intrauterine adhesions. (9) Again suggesting that two dimensional transvaginal ultrasound has a high false positive rate but may be useful as a screening modality. However, it has been showed that hysterosalpingography is a more accurate screening test. (8)

In three dimensional ultrasound, sound waves are emitted across a sector. The intensity of these sound waves is the same as two dimensional ultrasound. The returning echoes are processed by a sophisticated algorithm resulting in a reconstructed three dimensional volume image with x, y, and z planes. This process is very similar to a CT scan. Three dimensional ultrasound allows clinicians to see width, height, and depth of images. A Voluson Endocavity transducer S-VDW 5-8 (Kretztechnik AG, Austria) with a center frequency of 6.5 MHz connected to a Voluson 530D (Medison, USA) 3D ultrasound machine is applied for scanning. Every examination starts with a 2D evaluation of the endometrial cavity. After switching into 3D-mode, the region of interest is selected with the volume box and the volume is acquired. When possible, information regarding the scan is stored on a 540-MB removable hard disk for further evaluation and calculations. One of the advantages of three dimensional ultrasound is the real time assessment of the uterine cavity. Unlike hysterosalpingography, three dimensional ultrasound uses no radiation and can be done during an office visit. In a study done by Knopman et al, 54 infertile patients with suspected Asherman's syndrome underwent both three dimensional ultrasound and hysterosalpingography prior to hysteroscopy. In this study, intrauterine adhesions were demonstrated on three dimensional ultrasound and hysterosalpingography in all cases. However, three dimensional ultrasound had a sensitivity of 100% and hysterosalpingography had a sensitivity of 66.7%. Furthermore,

in 61.1% of cases in which hysterosalpingography results were inconsistent with hysteroscopy, lower uterine segment outflow tract obstruction was present and the hysterosalpingogram misclassified findings as severe disease with complete cavity obstruction. (10) Therefore, as prognosis in patients with Asherman's syndrome is based on severity of disease, it appears from this data that three dimensional ultrasound more accurately assesses prognosis, which has strong clinical applications.

Clinically, many women presenting with fertility problems are found to have Asherman's syndrome during routine infertility work-up. Knopman et al suggest that because the data obtained from three dimensional ultrasound correlates more closely with the character and extent of Asherman's disease, it could be a helpful tool in predicting fertility outcome postoperatively. Furthermore, the high pregnancy rates achieved in their clinic may in part be due to the excellent pre-operative information obtained from the three dimensional ultrasound, ensuring a well informed surgical procedure. Three dimensional ultrasound has many other uses in obstetrics, gynecology, and reproductive medicine. Three dimensional volumetry of the gestational sac in the first trimester has been suggested as a sensitive predictor of pregnancy outcome. (16) Additionally, three dimensional sonography has been suggested in case reports to be an accurate tool to identify multiple gestations in the first trimester. (17) Due to the high risk nature of multiple gestation pregnancies, an early assessment of amnionicity and chorionicity is an essential part of perinatal management. In summary, three dimensional ultrasound has many promising uses in infertility(18, 19, 20, 21), early pregnancy (22, 23, 24), and fetal malformations (25, 26). As the technology matures and treating physicians obtain more training, skills, and comfort with this technology, we anticipate more widespread acceptance and patient benefit to ensue.

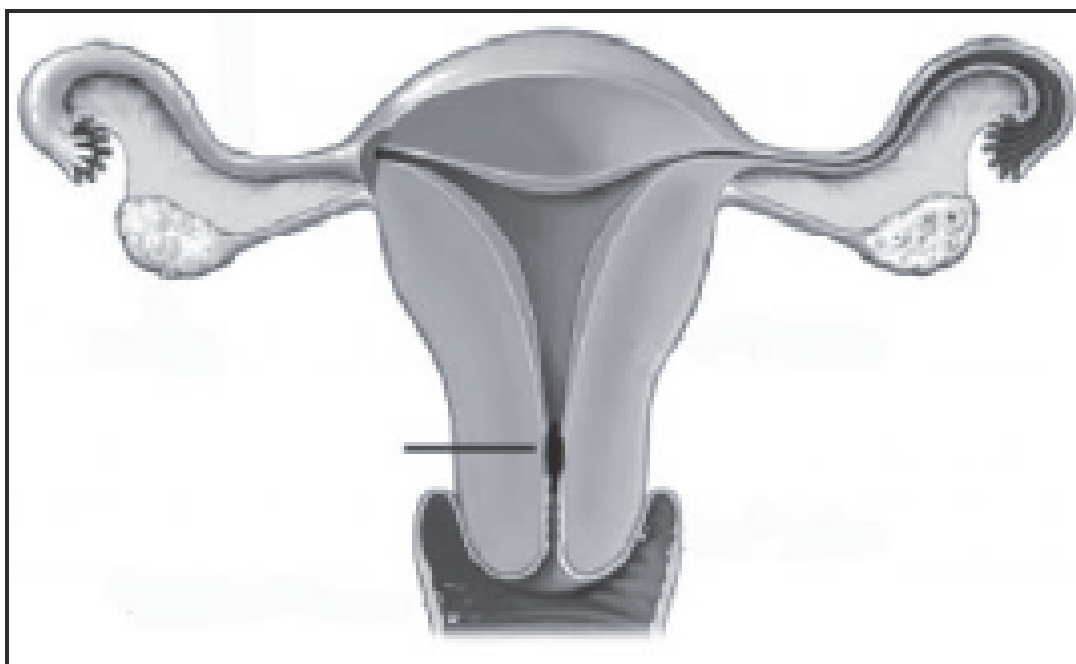


Fig. 1. Frontal plane demonstrating a cavity with <10% scarring. Normal cavity with outflow obstruction.

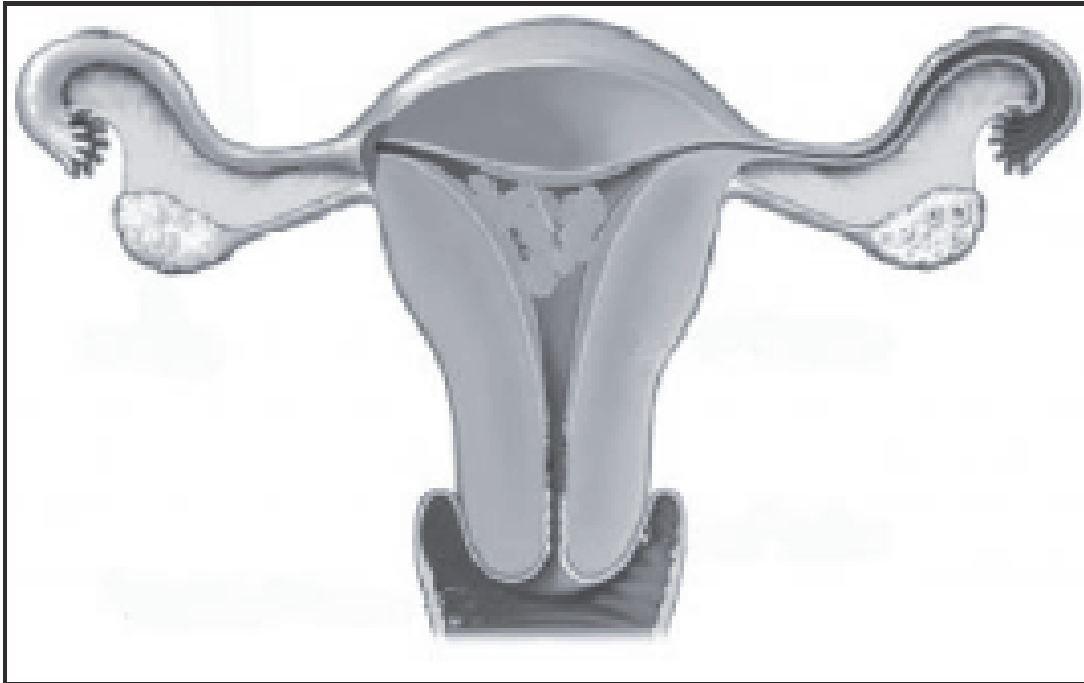


Fig. 2. Frontal plane demonstrating about 50% of cavity scarred. Abnormal cavity without outflow obstruction.

2. References

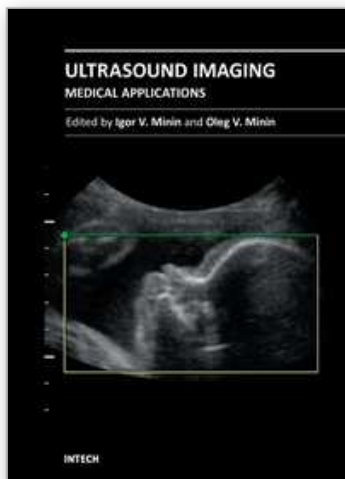
- [1] Asherman JG. (1950). Traumatic intrauterine adhesions. *J Obstet Gynaecol Br Em.* Dec;57(6):892-6
- [2] March CM. (1995). Intrauterine adhesions. *Obstet Gynecol Clin North Am.*22(3):491-505.
- [3] Schenker JG . (1996). Etiology of and therapeutic approach to synechia uteri. *Eur J Obstet Gynecol Reprod Biol.*65(1):109-13.
- [4] Al-Inany H. (2001). Intrauterine adhesions: An update. *Acta Obstet Gynecol Scand.*80:986-993.
- [5] Magos A. (2002). Hysteroscopic treatment of asherman's syndrome. *Reprod BioMed Online.*4:46-51
- [6] March CM, Israel R, March AD. (1978). Hysteroscopic management of intrauterine adhesions. *Am J Obstet Gynecol.*130:653-665
- [7] The American Fertility Society classifications of adnexal adhesions, distal tubal occlusion, tubal occlusion secondary to tubal ligation, tubal pregnancies, mullerian anomalies and intrauterine adhesions.(1988).*Fertil Steril.*49(6): 944-55.
- [8] Preutthipan S, Linasimita V. (2003). A prospective comparative study between hysterosalpingography and hysteroscopy in the detection of intrauterine pathology in patients with infertility. *J Obstet Gynaecol Res.*29:33-37

- [9] Sylvestre C, Child T, Tulandi T, et al.(2003). A prospective study to evaluate the efficacy of two- and three-dimensional sonohysterography in women with intrauterine lesions. *Fertil Steril*.79:1222-1225
- [10] Knopman J, Copperman AB. (2007). Value of 3D ultrasound in the management of suspected Asherman's syndrome. *J Reprod Med*. Nov;52(11):1016-22
- [11] Soares S, Reis M, Camargos A. (2000). Diagnostic accuracy of sonohysterography, transvaginal sonography, and hysterosalpingography in patients with uterine cavity diseases. *Fertil Steril*.73:406-411
- [12] Salle B, Gauchernad P, Hilaire P, et al.(1999). Transvaginal sonohysterographic evaluation of intrauterine adhesions. *J Clin Ultrasound*.27:131-134.
- [13] Widrich T, Bradely LD, Mitchinson AR, et al. (1996). Comparison of saline infusion sonography with office hysteroscopy for the evaluation of the endometrium. *Am j Obstet Gynecol*.174:1327-1334
- [14] Fedele L, Bianchi S, Dorta M, et al. (1996). Intrauterine adhesions: Detection with transvaginal ultrasound. *Radiology*.199:757-759
- [15] Shalev J, Meizner I, Bar-Hava I, et al. (2000). Predictive value of transvaginal sonography performed before routine diagnostic hysteroscopy for evaluation of infertility. *Fertil Steril*.73:412-417
- [16] Babinszki A, Nyari T, Jordan S, Nasser A, Mukherjee T, Copperman AB. (2001). Three-dimensional measurement of gestational and yolk sac volumes as predictors of pregnancy outcome in the first trimester. *Am J Perinatol*. Jun;18(4):203-11.
- [17] Babinszki A, Mukherjee T, Kerenyi T, Berkowitz RL, Copperman AB. (1999). Diagnosing amnionity at 6 weeks of pregnancy with transvaginal three-dimensional ultrasonography: case report. *Fertil Steril*. Jun;71(6): 1161-4
- [18] Lin MT, Chen GD, Lin LY, and Lee MS. (1991). Measurements of follicle size and the volume of follicular fluid by 3-dimensional ultrasound scanning compared with aspirated findings in IVF programs. *J. Obstet. Gynecol. Rep. China*, 30, 47-50
- [19] Brunner M, Obruca A, Bauer P, and Feichtinger W. (1995) Clinical application of volume estimation based on three dimensional ultrasonography. *Ultrasound Obstet. Gynecol.*,6,358-61
- [20] Kyei-Mensah A, Zaidi J, Pittrop R, Shaker AA, Campbell S, and Tan SL. (1996) Three-dimensional ultrasound: accuracy of follicular volume measurements. *Fertil. Steril.*, 65, 371-6
- [21] Bonilla-Musoles F, Raga F, Blanes J, Osborne N, and Siles CH. (1995) The use of three-dimensional ultrasound in reproduction: preliminary report. *Hum. Reprod.* Update.
- [22] Gregg A, Steiner H, Bogner G, Staudach A, and Weiner CP. (1993) The gestational sac and 3-D volumetry. *Am. J. Obstet. Gynecol.*, 168, 348
- [23] Kelly IM, Gardener JE, and Less WR. (1991) Three-dimensional fetal ultrasound. *Lancet*, 339, 1062-4
- [24] Kelly IM, Gardener JE, Brett AD, Richards RR, and Less WR. (1994). Three-dimensional ultrasound of the fetus. *Radiology*, 192, 253-9

- [25] Merz E, Bahlmann F, and Weber G. (1995) Volume scanning in the evaluation of fetal malformations: a new dimension in prenatal diagnosis. *Ultrasound Obstet. Gynecol.*, 5, 222-7
- [26] Lee A, Kratochwil A, Deutinger J, and Bernaschek G. (1995) Three-dimensional ultrasound in diagnosing phocomelia. *Ultrasound Obstet. Gynecol.*, 5, 238-40

IntechOpen

IntechOpen



Ultrasound Imaging - Medical Applications

Edited by Prof. Oleg Minin

ISBN 978-953-307-279-1

Hard cover, 330 pages

Publisher InTech

Published online 23, August, 2011

Published in print edition August, 2011

This book provides an overview of ultrafast ultrasound imaging, 3D high-quality ultrasonic imaging, correction of phase aberrations in medical ultrasound images, etc. Several interesting medical and clinical applications areas are also discussed in the book, like the use of three dimensional ultrasound imaging in evaluation of Asherman's syndrome, the role of 3D ultrasound in assessment of endometrial receptivity and follicular vascularity to predict the quality oocyte, ultrasound imaging in vascular diseases and the fetal palate, clinical application of ultrasound molecular imaging, Doppler abdominal ultrasound in small animals and so on.

How to reference

In order to correctly reference this scholarly work, feel free to copy and paste the following:

Catha Fischer and Alan Copperman (2011). Use of Three Dimensional Ultrasound Imaging in Evaluation of Asherman's Syndrome, *Ultrasound Imaging - Medical Applications*, Prof. Oleg Minin (Ed.), ISBN: 978-953-307-279-1, InTech, Available from: <http://www.intechopen.com/books/ultrasound-imaging-medical-applications/use-of-three-dimensional-ultrasound-imaging-in-evaluation-of-asherman-s-syndrome>

INTECH
open science | open minds

InTech Europe

University Campus STeP Ri
Slavka Krautzeka 83/A
51000 Rijeka, Croatia
Phone: +385 (51) 770 447
Fax: +385 (51) 686 166
www.intechopen.com

InTech China

Unit 405, Office Block, Hotel Equatorial Shanghai
No.65, Yan An Road (West), Shanghai, 200040, China
中国上海市延安西路65号上海国际贵都大饭店办公楼405单元
Phone: +86-21-62489820
Fax: +86-21-62489821

© 2011 The Author(s). Licensee IntechOpen. This chapter is distributed under the terms of the [Creative Commons Attribution-NonCommercial-ShareAlike-3.0 License](https://creativecommons.org/licenses/by-nc-sa/3.0/), which permits use, distribution and reproduction for non-commercial purposes, provided the original is properly cited and derivative works building on this content are distributed under the same license.

IntechOpen

IntechOpen