

We are IntechOpen, the world's leading publisher of Open Access books Built by scientists, for scientists

6,900

Open access books available

186,000

International authors and editors

200M

Downloads

Our authors are among the

154

Countries delivered to

TOP 1%

most cited scientists

12.2%

Contributors from top 500 universities



WEB OF SCIENCE™

Selection of our books indexed in the Book Citation Index
in Web of Science™ Core Collection (BKCI)

Interested in publishing with us?
Contact book.department@intechopen.com

Numbers displayed above are based on latest data collected.
For more information visit www.intechopen.com



Urothelial Carcinoma in Renal Transplant Recipients

Ming-Kuen Lai¹, Shuo-Meng Wang² and Huai-Ching Tai²

¹*Department of Surgery/Division of Urology,*

Chang Gung University/Chang Gung Memorial Hospital, Taoyuan,

²*Department of Urology, National Taiwan University Hospital, Taipei, Taiwan*

1. Introduction

The risk of renal transplant recipients to develop malignant disease is significantly higher than these in general population. The incidence of malignancy is estimated to be around 15-20% of renal recipients 10 years after renal transplantation and increases as high as 49.6% after 20 years. (Alberu, 2010; Kapoor, 2008; Penn, 2000; Gaya, et al, 1995). The most common malignancies are skin carcinomas and lymphomas (Lutz & Heemann, 2003). The immunosuppressive agents play an important role in contributing to such happenings. United Network for Organ Sharing (UNOS) registry data demonstrated that mammalian target of rapamycin (mTOR) inhibitors is associated with a reduced incidence of tumors compared to regimens that do not utilize mTOR-inhibitor (Rama & Grinyo, 2010). In UK transplant registry (UKTR) database, 1.9% of patients were reported to have a subsequent urological malignancy after renal transplantation (Besarani & Cranston, 2007).

2. Urothelial carcinoma after kidney transplantation

2.1 Urologic cancer after kidney transplantation

With increasing age of donor and recipient, the risk of post-transplant malignancy including genitourinary cancers is increasing. Urologists have an increasing likelihood of treating these cases. Melchior et al reported 29 urological de novo malignancies [12 renal cell carcinoma, 8 urothelial carcinoma (6 bladder, 2 renal pelvis), 7 carcinoma of the prostate, 2 seminoma] developed in a series of 802 patients after renal transplantation (Melchior et al, 2011). The overall incidence of urological neoplasms varied from 0.38% to 3.1% (Ravaud et al, 2010). Urothelial carcinoma (UC) of the bladder is not common in Western countries (Master et al, 2004) while it is the most common genitourinary tumor following kidney transplantation in China, Iran, Taiwan and Thailand (Einollahi et al, 2009; Ativitavas et al, 2008). Among the Chinese population, urological malignancies, especially UC, are an important complication after renal transplantation (Zhou et al, 2006). In some areas around the world, the incidence of UC (or "transitional cell carcinoma, TCC") of the urinary tract in renal transplant recipients is significantly higher than other parts of world. Majority of previous studies showing increased incidence of UC in renal transplant recipients came from Taiwan where it was attributed to environmental and occupational factors (Husain et

al, 2009). Urinary tract UC is the leading de novo malignancy following renal transplantation in Taiwan followed by hepatoma (Wang et al, 2010; Hung et al, 2007; Liao et al, 2004; Kang et al, 2004; Kao et al, 2003; Wang et al, 2002; Yang et al, 1998). This is very different from the Western countries or other Asian countries such as Japan, Korea.

Wu et al from Taiwan reported that as high as 17.5% of renal transplant recipients developed urinary tract UC at 10 years after transplantation. Compared with the general population in Taiwan, the standardized mortality ratio (SMR) was 398.4 among renal transplant recipients and the SMR was much higher among female patients (875.6). Painless gross hematuria was the cardinal initial symptom in 73.3% of patients (Wu et al, 2004). The male to female ratio is reported to be 1:1.7~3.5. Female predominance among these patients is uniformly found in the reports from Taiwan and China (Liao et al, 2004; Wu et al, 2004; Li et al, 2009; Wang et al, 2010). However, in our early report, although uremic patients were at greater risk of developing urologic cancer, UC was uncommon among the renal transplant recipients (Chen et al, 1995).

2.2 Carcinogenesis of urothelial carcinoma in renal transplant recipients

Among the general population, only 5% of UC arise in the upper urinary tract (UUT) and only 2.5% involved bilaterally. UUT-UC is restricted to the renal pelvis in 58% of cases, 35% in the ureter, especially in the distal ureter. Many environmental factors have been reported to contribute to the development of these cancers. Some are quite similar to bladder cancer-associated factors related to occupational and environmental exposure such as tobacco, industrial dye and certain aromatic amines, etc, while others are more specific to the carcinogenesis of the UC such as analgesic, Balkan endemic nephropathy (BEN), Chinese herb nephropathy (CHN) or association with Blackfoot disease (BFD) (Hall et al, 1998; Colin et al, 2009). In Western countries, analgesic nephropathy (AN) is implicated to contribute to development of UC following renal transplantation. UC occurred more frequently in the AN group (2.8%) than these in the control group (0.49%) (Swindle et al, 1998). In Taiwan, older age at kidney transplantation, female recipient, compound analgesics usage, Chinese herb usage, underground water intake and low educational status were the significant risk factors for the development of de novo UC (Wang et al, 2010; Liao et al, 2004).

2.2.1 Chinese herb nephropathy (Aristolochic acid nephropathy)

Chinese herbs nephropathy after taking a slimming regimen including Chinese herbs contaminated with *Aristolochia fangchi* was reported by Belgium groups. These patients experienced a rapid progression to renal failure compared with other interstitial nephropathies. Many patients developed UC (Vanherweghem et al, 1993; Reginster et al, 1997; Cosyns et al, 1998). Aristolochic acid contained in Chinese herbs has been proved to be nephrotoxic and carcinogenic (Thon et al, 1995). Li et al from China reported a 2-center cohort of 1,612 renal transplant recipients, the patients with aristolochic acid nephropathy (AAN) had significantly higher incidence of UC (52.9% vs 0.46% in the control group) (Li et al, 2009). Among these patients, 88.9% involved the upper urinary tract (37.5% bilateral, 62.5% unilateral). It was more common to see UC cases in the female patients (male to female ratio of 1:3.5). These are very similar to the happenings in Taiwan, i.e., high incidence of UC in the upper urinary tract and female predominance (Hung et al, 2007; Liao et al, 2004; Kang et al, 2004; Kao et al, 2003). Bilateral nephroureterectomy has been a standard procedure for these patients. Synchronous UC in bilateral upper urinary tracts was

confirmed in 36.7% of cases (Wu et al, 2004). Among the patients with bilateral upper tract UC, only 25% had bilateral abnormalities in preoperative image studies (Liao et al, 2004). High incidence rate of UUT-UC has been described in some rural areas of the Balkans after year 1950, but it has been decreased significantly in recent 20 years (Markovic et al, 2005). Bilateral involvement (8–10%) and female predominance are the unique characteristics in these patients with BEN which are quite similar to the cases with CHN. Several studies have shown the carcinogenic potential of aristolochic acid contained in *Aristolochia fangchi* (contamination in some Chinese herbs) and *Aristolochia clematis* (a plant popularly present in the farm field of the Balkans) (Arlt et al, 2007; Laing et al, 2006; Nortier et al, 2000; Consyns et al, 1999). Debelle et al. proposed to combine BEN and CHN under one name, i.e., aristolochic acid nephropathy (Debelle et al, 2008). Chen et al reported an increased risk for the professional persons working with Chinese herb medicine to develop chronic renal failure and urinary tract cancer. The age-adjusted relative risks of these professional persons to develop urinary tract cancer were 3.81 for male and 5.86~9.32 for female subjects. This finding supports the hypothesis that urinary tract cancer in Chinese herbalists could be related to the long-term exposure of aristolochic acid -containing herbal medicines (Chen et al, 2009; Yang et al, 2009). Lai et al using the reimbursement database of National Health Insurance from Taiwan to study 4594 patients and 174,701 control subjects (Lai et al, 2010). There was a statistically significant linear dose-response relationship between the cumulative dose of aristolochic acid and the risk of developing urinary tract cancer. Consumption of aristolochic acid-containing Chinese herbal medicine was associated with an increased risk of developing cancer of the urinary tract in a dose-dependent manner and it is independent of arsenic exposure.

2.2.2 Arsenic intoxication

An unusually high incidence of UUT-UC has been described in Taiwan. It occurred in the south-west part of Taiwan where the population was particularly susceptible to the development of UUT-UC which represented 20–25% of all UC cases. This area corresponds to the endemic area of Blackfoot disease (BFD), which is known to be a thromboangiitis of lower limbs leading to gangrene. The majority of cases required amputation of lower limbs. Contamination of drinking water with arsenic has been considered to be the reason for this endemic disease. The cases of UUT-UC in the endemic area of BFD are characterized by female predominance (male to female ratio of 1:2) and more ureteral tumors (twice as common as the renal pelvis tumors) (Tan et al, 2008; Yang et al, 2002; Chiou et al 2001, Chiang et al, 1993). The prevalence of UC in the BFD endemic area improved significantly after the government modernized the water supply system. However, for some reasons, the prevalence of UC in this area is still higher than other parts of Taiwan (Yang et al, 2005; Yang et al, 2002). Arsenic exposure is associated with an increased risk of UC. UC patients had a significantly higher sum of measured urinary arsenic species including inorganic arsenic, monomethylarsonic acid and dimethylarsinic acid (Pu et al, 2002; Chung et al, 2008). Arsenic intoxication also involves the formation of DNA adducts and DNA damage (Kato et al, 1994; Schwerdtle et al, 2003). Association between inorganic arsenic and UC risk focused on the total arsenic ingested from drinking water had been reported (Pu et al, 2002). Subjects of low exposure, were still observed to have higher UC risk in subjects with unfavorable urinary arsenic profile, i.e., poorer function of arsenic methylation. The primary methylation index (PMI) was defined as the ratio between monomethylarsonic acid and

inorganic arsenic. Secondary methylation index (SMI) was defined as the ratio between dimethylarsinic acid and monomethylarsonic acid. Unfavorable PMI and SMI levels indicate an increased risk of developing UC, especially in non-smokers although smoking has been well documented to cause carcinogenesis of UC (Zeegers et al, 2000). Undetectable or negligible environmental arsenic still plays an important role (Chung et al, 2008). The arsenic levels allowed in drinking water is not greater than 5µg/L. The WHO established the water quality guidelines for drinking water which included the arsenic levels to be undetectable to less than 10µg/L (WHO 1996/1998). Actually, the average arsenic concentration in Taipei City, the capital of Taiwan, is ranged from undetectable level to 4.0 µg/L. Smoking is associated with an increased risk of UC in a dose dependent manner (Kato et al, 1994). Arsenic contamination in drinking water and smoking are synergistic in the carcinogenesis of UC (Chung et al, 2008).

2.2.3 Role of virus in the carcinogenesis of urothelial carcinoma

Polyoma virus (PV), BK virus (BKV), human papillomavirus may play a role in the pathogenesis of UC following renal transplantation. There is lack of data to indicate a definitive association between BKV and human cancers (Noel et al, 1994; Husain et al, 2009; Abend et al, 2009; Wang et al, 2009; Roberts et al, 2008; Chen et al, 2010). Presence of polyoma virus in the biopsy specimen may mimic high grade transitional cell carcinoma (Seftel et al, 1996).

2.2.4 Urothelial carcinoma in hemodialysis patients and renal transplant recipients

In Taiwan, UC is the most common type of urological cancer in patients with end stage renal disease (Chang et al, 2007). The cumulative incidence of UC was between 0.77% to 1.7% in hemodialysis patients and 3.1% to 4.1% in renal transplant recipients. The cases of UC in hemodialysis patients and renal transplant recipients have similar characteristics of BEN, CHN and BFD. As compared with the incidence of UC in the general population of Taiwan (10.09/100,000), the standardized incidence ratio of UC in hemodialysis is very high (48.2). Women and middle-aged patients had a higher risk. Physicians who are taking care of hemodialysis patients and renal transplant recipients should be highly alert with presence of hematuria which warrants detailed study of the entire urinary system and image study of the native and transplanted kidneys (Wang et al, 2010; Tai et al, 2009; Liao et al, 2004). Only 19.4% of patients had history of long-term consumption of Chinese herbs and 3.1% had history of using analgesic compounds (Wang et al, 2011). Contamination of drinking water is considered to be another carcinogenic factor.

3. Treatment of Urothelial carcinoma after kidney transplantation

Patients with upper tract lesions are recommended to undergo bilateral nephroureterectomy and bladder cuff resection in one session or in separate sessions (Glassman et al, 2001; Kao et al, 2004; Zhang et al, 2009). Whether postoperative intravesical instillation of chemotherapeutic agents reduces the incidence of bladder recurrence is debating. Wu et al reported that intravesical instillation of epirubicin or mitomycin C appeared to be effective in preventing bladder recurrence and in prolonging time to first bladder recurrence (Wu et al, 2010). Transurethral resection of the bladder tumor is indicated in patients with concomitant or superficial bladder lesions. Intravesical chemotherapy is started after

transurethral resection and immunosuppressants are adjusted (Li et al, 2008). Laparoscopic bilateral nephroureterectomy and bladder cuff excision can be performed safely and gives similar oncologic results in experienced hands (Chen et al, 2003; Liao et al, 2004). Laparoscopic bilateral nephroureterectomy can be performed in a single session without repositioning of the patient if a specially designed inflatable cuff is used (Chueh et al, 2002). Retroperitoneal laparoscopic nephroureterectomy with bladder cuff excision can be safely performed by combining cystoscopic resection with open transperitoneal dissection. This might be a safe and feasible alternative for native UUT-UC ipsilateral to a transplanted kidney (Ye et al, 2010). Lymphovascular invasion was reported to be the only significant predictor of cancer specific survival in the univariate and multivariate analyses (Chung et al, 2009). The benefit of routine lymphadenectomy during nephroureterectomy of UC is debatable. The benefit of conversion from calcineurin inhibitors to mammalian target of rapamycin (mTOR) inhibitors (proliferation signal inhibitors) is another debating issue. Many patients experienced recurrence of UC after bilateral nephroureterectomy and conversion to mTOR inhibitors (Chung et al, 2008; Wang et al 2008; Hu et al, 2009). Systemic chemotherapy can be performed on these patients safely and effectively (Matzkies et al, 2000; Lin et al, 2006).

4. Conclusion

UC is the leading cause of malignancy in renal transplant recipients in some Asian countries such as China, Iran, Taiwan, Thailand, etc. It is characterized with female predominance, frequent bilateral upper urinary tract lesions. The pathogenesis of UC in renal transplant recipients is still under investigation. Aristolochic acid, arsenic intoxication, smoking and some virus may play important and complicated roles. Transplant physicians should be very alert with hematuria, hydronephrosis of native urinary tract which frequently implicates presence of UC. Bilateral nephroureterectomy in a single session or in separate sessions is recommended

5. References

- Abend, JR., Mengxi Jiang, M.& Imperiale, MJ. (2009). BK Virus and Human Cancer: Innocent until Proven Guilty. *Seminars of Cancer Biology*. Vol. 19, No. 4, pp. 252-260.
- Alberu, J. (2010). Clinical insights for cancer outcomes in renal transplant patients. *Transplantation Proceedings*. Vol. 42, No.9 Suppl, pp.S36-40.
- Arlt, VM., Stiborova, M., vom Brocke, J., Simões, ML., Lord, GH., Nortier, JL., Hollstein, M., Phillips, DH.& Schmeiser, HH. (2007). Aristolochic acid mutagenesis: molecular clues to the aetiology of Balkan endemic nephropathy-associated urothelial cancer. *Carcinogenesis*. Vol. 28, No.11, pp.2253-2261.
- Atitavass, T., Jirasiritham, S., Ngorsakun, P., Pipatpannawong, K.& Mavichak, V. (2008). Malignancies in renal transplant patients: 15 years experience in Thailand. *Transplantation Proceedings*. Vol. 40, No.7, pp.2403-2404.
- Besarani, D., Cranston, D. (2007) Urological malignancy after renal transplantation. *British Journal of Urology International*. Vol. 100, No.3, pp.502-505.
- Chang, CH., Yang, CM.& Yang, AH. (2007). Renal diagnosis of chronic hemodialysis patients with urinary tract transitional cell carcinoma in Taiwan. *Cancer*. Vol. 109, Issue 8, pp. 1487-1492.

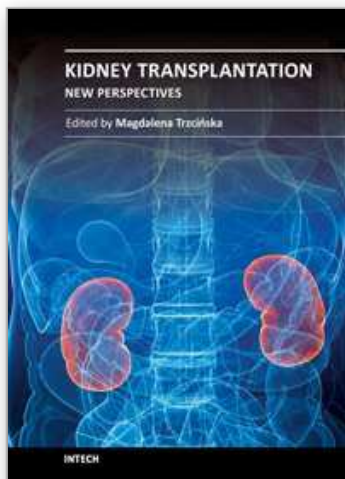
- Chen, CH., Huan, SK., Lin, JT. & Chiu, AW. (2003). Laparoscopic bilateral nephroureterectomy and bladder cuff excision for native renal pelvic and ureteral transitional cell carcinoma after renal transplantation. *Journal of Postgraduate Medicine*. Vol. 49, No. 2, pp. 148-150.
- Chen, CH., Wen, MC., Wang, M., Lian, JD., Cheng, CH., Wu, MJ., Yu, TM., Chuang YW., Chang, D. & Shu, KH. (2010). High incidence of malignancy in polyomavirus-associated nephropathy in renal transplant recipients. *Transplantation Proceedings*. Vol. 42, No. 3, pp. 817-8.
- Chen, KS., Lai, MK., Huang, CC., Chu, SH. & Leu, ML. (1995). Urologic cancers in uremic patients. *American Journal of Kidney Diseases*. Vol. 25, No. 5, pp. 694-700.
- Chen, PC., Chang, PJ. & Wang, JD. (2009). Chronic Renal Failure and Urinary Tract Cancer in Chinese Herbalists: Implications for the Safety Issues of Herbal Medicine. *Epidemiology*. Vol. 20, Issue 6, pp. S200.
- Chiang, HS., Guo, HR., Hong, CL., Lin, SM. & Lee, GF. (1993). The incidence of bladder cancer in the black foot disease endemic area in Taiwan. *British Journal of Urology*. , pp. 274-278.
- Chiou, HY., Chiou, ST., Hsu, YH., Chou, YL., Tseng, CH., Wei, ML. & Chen, CJ. (2001). Incidence of transitional cell carcinoma and arsenic in drinking water: a follow-up study of 8102 residents in an arseniasis-endemic area in northeastern Taiwan. *American Journal of Epidemiology*. Vol. 153, No. 5, pp. 411-418.
- Chueh, SC., Chen, J., Hsu, WT., Hsieh, MH. & Lai, MK. (2002). Hand assisted laparoscopic bilateral nephroureterectomy in 1 session without repositioning patients is facilitated by alternating inflation cuffs. *Journal of Urology*. Vol. 167, No. 1, pp. 44-47.
- Chung, CJ., Huang, CJ., Pu, YS., Su, CT., Huang, YK., Chen, YT. & Hsueh, YM. (2008). Urinary 8-hydroxydeoxyguanosine and urothelial carcinoma risk in low arsenic exposure area. *Toxicology and Applied Pharmacology*. Vol. 226, Issue 1, pp. 14-21.
- Chung, SD., Lai, MK., Wang, SM., Liao, CH., Yu, HJ. & Chueh, SC. (2008). Urothelial carcinoma in kidney transplant recipients: conversion from calcineurin inhibitor to proliferation signal inhibitor? Comment on: Am J Kidney Dis. 2008 Mar;51(3):471-7. *American Journal of Kidney Disease*. Vol. 52, No. 3, pp. 630; author reply 631.
- Chung, SD., Wang, SM., Lai, MK., Huang, CY., Liao, CH., Huang, KH., Pu, YS., Chueh, SC. & Yu, HJ. (2009). Lymphovascular invasion predicts poor outcome of urothelial carcinoma of renal pelvis after nephroureterectomy. *British Journal of Urology International*. Vol. 103, No. 8, pp. 1047-1051.
- Colin, P., Koenig, P., Ouzzane, A., Berthon, N., Villers, A., Biserte, J. & Rouprêt, M (2009). Environmental factors involved in carcinogenesis of urothelial cell carcinomas of the upper urinary tract. *British Journal of Urology International*. Vol. 104, No. 10, pp. 1436-1440.
- Consyns, JP., Jadoul, M., Squifflet, JP., Wese, FX. & van Ypersels de, SC. (1999). Urothelial lesions in Chinese-herb nephropathy. *American Journal of Kidney Disease*. Vol. 33, Issue 6, pp. 1011-1017.
- Cosyns, JP., Goebbels, RM., Liberton, V., Schmeiser, HH., Bieler, CA. & Bernard, AM. (1998). Chinese herbs nephropathy-associated slimming regimen induces tumours in the forestomach but no interstitial nephropathy in rats. *Archives of Toxicology*. Vol. 72, No. 11, pp. 738-743.

- Debelle, FD.; Vanherweghem, JL.; Nortier, JL. (2008). Aristolochic acid nephropathy: a worldwide problem. *Kidney International*. Vol. 74, No.2, pp.158-169.
- Einollahi,B., Simforoosh,N., Lessan-Pezeshki, M., Basiri, A., Nafar, M., Pour-Reza Gholi, F., Firouzan, A., Ahmadpour, P., Makhdomi, K., Ghafari, A., Taghizadeh, A., & Tayebi Khosroshahi, H. (2009). Genitourinary tumor following kidney transplantation: a multicenter study. *Transplantation Proceedings*. Vol. 41, No.7, pp.2848-2849.
- Gaya, SB., Rees, AJ., Lechler, RI., Williams, G. & Mason, PD. (1995). Malignant disease in patients with long-term renal transplants. *Transplantation*. Vol. 59 No. 12, pp.1705-1709.
- Glassman, DT. & Sklar, GN. (2001). Complete genitourinary exenteration for multifocal transitional cell carcinoma in renal transplant recipient. *Journal of Urology*. Vol.166, No.3, pp.986-987.
- Hall, MC., Womack,S., Sagalowsky,AI., Carmody,T.; Erickstad,MD.& Roehrborn,CG. (1998). Prognostic factors, recurrence, and survival in transitional cell carcinoma of the upper urinary tract: a 30-year experience in 252 patients. *Urology*. Vol.52, No.4, pp.594-601.
- Hu, XP., Ma, L., Wang, Y., Yin, H., Wang, W., Yang, XY.& Zhang, XD. (2009). Rapamycin instead of mycophenolate mofetil or azathioprine in treatment of post-renal transplantation urothelial carcinoma. *Chinese Medical Journal*. Vol. 122, No.1 , pp.35-38.
- Hung, YM., Chou, KJ., Hung, SY., Chung, HM.& Chang, JC. (2007). De novo malignancies after kidney transplantation. *Urology*. Vol. 69, No.6, pp.1041-1044.
- Husain, E., Prowse, DM., Ktori, E., Shaikh, T., Yaqoob, M., Junaid, I.& Baithun, S.(2009). Human papillomavirus is detected in transitional cell carcinoma arising in renal transplant recipients. *Pathology*. Vol. 41, No.3, pp.245-247.
- Husain, E., Khawaja, A., Shaikh, T., Yaqoob, M., Junaid, I.& Baithun, S. (2009). Transitional cell carcinoma of the urinary tract in renal transplant recipients. *Pathology*. Vol. 41, No.4, pp.406-408.
- Kang, CH., Yu, TJ., Hsieh, HH., Yang, JW., Shu, K.& Shiue, YL. (2004). Synchronous bilateral primary transitional cell carcinoma of the upper urinary tracts: ten patients with more than five years of follow-up. *Urology*. Vol.63, No.2, pp.380-382.
- Kao, YL., Ou, YC., Yang, CR., Ho, HC., Su, CK. & Shu, KH. (2003). Transitional cell carcinoma in renal transplant recipients. *World Journal of Surgery*. Vol.27, No.8, pp.912-916.
- Kao, YL., Yang, CR. & Chen, CH. (2004). Urinary exenteration on a renal transplant recipient with multifocal urothelial cancers and prostatic adenocarcinoma. *Journal of the Chinese Medical Association*. Vol.67, No. 8, pp.422-424.
- Kapoor, A.(2008). Malignancy in kidney transplant recipients. *Drugs*, Vol. 68, No. Suppl 1, pp.11-9.
- Kato, K., Hayashi,H., Hasegawa,A., Yamanaka,K.& Okada, S. (1994). DNA damage induced in cultured human alveolar (L-132) cells by exposure to dimethylarsinic acid. *Environmental Health Perspect*. Vol.102, Suppl 3, pp.285-288.
- Lai, MN., Wang, SM., Chen,PC., Chen, YY.& Wang, JD. (2010).

- Population-Based Case-Control Study of Chinese Herbal Products Containing Aristolochic Acid and Urinary Tract Cancer Risk. *Journal of National Cancer Institute*. Vol.102, No.3, pp.179-186.
- Laing, C., Hamour, S., Sheaff, M., Miller, R.& Woolfson, R. (2006). Chinese herbal uropathy and nephropathy? *Lancet*. Vol.368, Issue 9545, pp.1416.
- Li, HZ., Xia, M., Han, Y., Xu, XG.& Zhang, YS. (2009.). De novo urothelial carcinoma in kidney transplantation patients with end-stage aristolochic acid nephropathy in China. [Erratum appears in *Urol Int*. 2010;84(4):484] *Urologia Internationalis*. Vol.83, No.2, pp.200-205.
- Li, XB., Xing, NZ., Wang, Y., Hu, XP., Yin, H.& Zhang, XD. (2008). Transitional cell carcinoma in renal transplant recipients: A single center experience. *International Journal of Urology*. Vol. 15, Issue 1, pp. 53-57.
- Liao, CH., Chueh, SC., Lai, MK.& Chen J. (2004). Transitional cell carcinoma in renal transplant recipients. *Transplantation Proceedings*. Vol. 36, No.7, pp.2152-2153.
- Lin, CC., Hsu, CH. & Pu, YS. (2006).Complete response of urothelial carcinoma to chemotherapy in renal allograft recipients: a two-case study. *Anticancer Research*. Vol. 26, No.4B, pp.3191-3195.
- Lutz, J., Heemann, U. (2003). Tumours after kidney transplantation. *Current Opinions in Urology*. Vol. 13, No.2, pp.105-109.
- Markovic, N., Ignjatovic, I., Cukuranovic, R., Petrovic, B., Kocic, B.& Stefanovic, V. (2005). Decreasing incidence of urothelial cancer in a Balkan endemic nephropathy region in Serbia. A surgery based study from 1969 to 1998. *Pathologie Biologie*. Vol. 53, Issue 1, pp.26-29.
- Master, VA., Meng, MV., Grossfeld, GD., Koppie, TM., Hirose, R. & Carroll, PR. (2004). Treatment and outcome of invasive bladder cancer in patients after renal transplantation. *Journal of Urology*. Vol. 171, No. 3, pp.1085-1088.
- Matzkies, FK., Tombach, B., Dietrich, M., Kisters, K., Barenbrock, M., Schaefer, RM., Berdel, WE. & Rahn, KH. (2000). MVAC-therapy for advanced urothelial carcinoma in an anuric renal transplant recipient. *Nephrology Dialysis and Transplantation*. Vol. 15, No.1, pp.110-112.
- Melchior, S., Franzaring, L., Shardan, A., Schwenke, C., Plumpe, A., Schnell, R., Dreikorn, K. (2011). Urological de novo malignancy after kidney transplantation: a case for the urologist. *Journal of Urology*. Vol. 185, No. 2, pp.428-432.
- Noel, JC., Peny, MO., Mat, O., Antoine, M., Firket, C., Detremmerie, O., Thiry, L., Verhest, A. & Vereerstraeten, P. (1994). Human papillomavirus type 16 associated with multifocal transitional cell carcinomas of the bladder in two transplanted patients. *Transplant International*. Vol. 7, No.5, pp.340-343.
- Nortier, JL., Martinez, MCM., Schmeiser, HH., Arlt, VM., Bieler, CA., Petein, M., Depierreux, MF., De Pauw, L., Abramowicz, D., Vereerstraeten, P.& Vanherweghem, JL. (2000). Urothelial carcinoma associated with the use of a Chinese herb (*Aristolochia fangchi*). *New England Journal of Medicine*. Vol. 342, No. 23, pp.1686-1692.
- Penn, I.(2000). Cancers in renal transplant recipients. *Advance in Renal Replacement Therapy*. Vol. 7, No. 2, pp.147-156.

- Pu, YS., Hour, TC., Chen, J., Huang, CY., Guan, JY. & Lu, SH. (2002). Arsenic trioxide as a novel anticancer agent against human transitional carcinoma-characterizing its apoptotic pathway. *Anti-Cancer Drugs*. Vol. 13, Issue 3, pp.293-300.
- Rama, I., Grinyo, JM. (2010). Malignancy after renal transplantation: the role of immunosuppression. *Nature Reviews in Nephrology*. Vol. 6, No.9, pp.511-519.
- Ravaud, A., Ballanger, P., Ferriere, JM., Wallerand, H., Elkentaoui, H., Robert, G., Pasticier, G., Bernhard, JC., Couzi, L. & Merville, P. (2010). Therapeutic management of de novo urological malignancy in renal transplant recipients: the experience of the French Department of Urology and Kidney Transplantation from Bordeaux. *Urology*. Vol. 75, No. 1, pp.126-132.
- Reginster, F., Jadoul, M. & van Ypersele de Strihou, C. (1997). Chinese herbs nephropathy presentation, natural history and fate after transplantation. *Nephrology Dialysis Transplantation*. Vol.12, No.1, pp.81-86.
- Roberts, ISD., Besarani, D., Mason, P., Turner, G., Friend, PJ. & Newton, R. (2008). Polyoma virus infection and urothelial carcinoma of the bladder following renal transplantation. *British Journal of Cancer*. Vol. 99, No.9, pp.1383-1386.
- Schwerdtle, T., Walter, I., Mackiw, I. & Hartwig, A. (2003). Induction of oxidative DNA damage by arsenite and its trivalent and pentavalent methylated metabolites in cultured human cells and isolated DNA. *Carcinogenesis*. Volume 24, Issue 5, pp.967-974.
- Seftel, AD., Matthews, LA., Smith, MC. & Willis, J. (1996). Polyomavirus mimicking high grade transitional cell carcinoma. *Journal of Urology*. Vol.156, No. 5, pp. 1764
- Swindle, P., Falk, M., Rigby, R., Petrie, J., Hawley, C. & Nicol, D. (1998). Transitional cell carcinoma in renal transplant recipients: the influence of compound analgesics. *British Journal of Urology*. Vol.81, No.2, pp.229-233.
- Tai, HC., Lai, MK., Wang, SM., Chueh, SC. & Yu, HJ. (2009). High incidence of urinary tract malignancy among patients with haematuria following kidney transplantation in Taiwan. *Transplant International*. Vol.22, No. , pp.403-407.
- Tan, LB., Chen, KT. & Guo, HR. (2008). Clinical and epidemiological features of patients with genitourinary tract tumour in a blackfoot disease endemic area of Taiwan. *British Journal of Urology International*. Vol. 102, No. 1, pp. 48-54.
- Thon, WF., Kliem, V., Truss, MC., Anton, P., Kuczyk, M., Stief, CG. & Brunkhorst, R. (1995). Denovo urothelial carcinoma of the upper and lower urinary tract in kidney--transplant patients with end-stage analgesic nephropathy. *World Journal of Urology*. Vol.13, No.4, pp.254-261.
- Vanherweghem, JL., Tielemans, C., Abramowicz, D., Depierreux, M., Vanhaelen-Fastre, R., Vanhaelen, M., Dratwa, M., Richard, C., Vandervelde, D., Verbeelen, D., & Jadoul, M. (1993). Rapidly progressive interstitial renal fibrosis in young women: association with slimming regimen including Chinese herbs. *Lancet*. Vol. 341, Issue 8842, pp. 387-391
- Wang, HB., Hsieh, HH., Chen, YT., Chiang, CY. & Cheng YT. (2002). The outcome of post-transplant transitional cell carcinoma in 10 renal transplant recipients. *Clinical Transplantation*. Vol.16, No.6, pp.410-413.
- Wang, HH., Liu, KL., Chu, SH., Tian, YC, Lai, PC. & Chiang, YJ. (2009). BK virus infection in association with posttransplant urothelial carcinoma. *Transplant Proceedings*. Volume 41, Issue 1, pp. 165-166.

- Wang, LJ., Wong, YC.& Huang, CC. (2010). Urothelial carcinoma of the native ureter in a kidney transplant recipient. *Journal of Urology*. Vol.184, No.2, pp.728.
- Wang, SM., Tai, HC., Chueh, SC., Chung, SD.& Lai, MK. (2008). Sirolimus does not absolutely abolish the occurrence/recurrence of urothelial carcinoma in renal transplant recipients. *Transplant Proceedings*. Vol. 40, No.7, pp.2395-2396.
- Wang, TY., Hu, CJ., Kuo, CW., Chen, Y., Lin, JL., Yang, CW.& Yen, TH. (2011). High incidence and recurrence of transitional cell carcinoma in Taiwanese patients with end-stage renal disease. *Nephrology*. Vol. 16, Issue 2, pp. 225–231.
- WHO 1996/1998 Guidelines for Drinking Water Quality. Second edition (1996) Vol. 2, pp 940–949; and 1998 addendum to Vol. 2, pp 281–283. *World Health Organization*, Geneva.
- Wu, MJ., Lian, JD., Yang, CR., Cheng, CH., Chen, CH., Lee, WC., Shu, KH.& Tang, MJ. (2004). High cumulative incidence of urinary tract transitional cell carcinoma after kidney transplantation in Taiwan. *American Journal of Kidney Diseases*. Vol.43, No.6, pp.1091-1097.
- Wu, WJ., Ke, HL., Yang, YH., Li, CC., Chou, YH.& Huang, CH. (2010). Should patients with primary upper urinary tract cancer receive prophylactic intravesical chemotherapy after nephroureterectomy? *Journal of Urology*. Volume 183, Issue 1, pp.56-61.
- Yang, CY., Chiu, HF., Chang, CC., Ho, SC.& Wu, TN. (2005). Bladder cancer mortality reduction after installation of a tap-water supply system in an arsenious-endemic area in southwestern Taiwan. *Environmental Research*. Vol. 98, No.1, pp.127–132.
- Yang, HY., Wang, JD., Lo, TC.& Chen, PC. (2009). Increased Mortality Risk for Cancers of the Kidney and Other Urinary Organs among Chinese Herbalists. *Journal of Epidemiology*. Vol.19, No.1, pp.17-23.
- Yang, MH., Chen, KK., Yen, CC., Wang, WS., Chang, YH., Huang, WJ., Fan, FS., Chiou, TJ., Liu, JH.& Chen, PM. (2002). Unusually high incidence of upper urinary tract urothelial carcinoma in Taiwan. *Urology*. Vol. 59, No.5, pp.681-687.
- Yang, TC., Shu, KH., Cheng, CH., Wu, MJ.& Lian JD. (1998). Malignancy following renal transplantation. *Chung Hua i Hsueh Tsa Chih - Chinese Medical Journal*. Vol.61, No.5, pp.281-288.
- Ye, J., Ma, L., Huang, Y., Hou, X., Xiao, C., Zhao, L., Wang, G., Hong, K. & Lu, J. (2010). Retroperitoneal laparoscopic nephroureterectomy with bladder cuff excision for native upper tract transitional cell carcinoma ipsilateral to a transplanted kidney. *Urology*. Vol. 76, No. 6, pp.1395-1399.
- Zeegers, MP., Tan, FE., Dorant, E.& van Den Brandt, PA. (2000). The impact of characteristics of cigarette smoking on urinary tract cancer risk: a metaanalysis of epidemiologic studies. *Cancer*. Vol. 89, Issue 3, pp.630–639.
- Zhang, P., Wang, Y., Zhang, XD., Hu, XP., Wang, W., Zhang, Y. & Yin, H. (2009). Clinical character of renal transplant recipients with bilateral native upper urinary transitional cell carcinoma. *Chung-Hua i Hsueh Tsa Chih [Chinese Medical Journal]*. Vol. 89, No. 4, pp.248-250.
- Zhou, M., Zhu, Y., Wang, L., Wang, Y., Fu, S.& Min, Z. (2006). Urological malignancy as a complication of renal transplantation: a report of twelve clinical cases. *Clinical Transplants*. pp.395-398.



Kidney Transplantation - New Perspectives

Edited by Dr Magdalena Trzcinska

ISBN 978-953-307-684-3

Hard cover, 334 pages

Publisher InTech

Published online 23, August, 2011

Published in print edition August, 2011

Although many years have passed since the first successful kidney transplantation, the method, although no longer considered a medical experiment, is still perceived as controversial and, as such, it triggers many emotions and that's why conscious educational efforts are still needed for kidney transplantation, for many people being the only chance for an active lifestyle and improved quality of life, to win common social acceptance and stop triggering negative connotations. Apart from transplantation controversies piling up over years transplantologists also have to face many other medical difficulties. The chapters selected for this book are of high level of content, and the fact that their authors come from many different countries, and sometimes even cultures, has facilitated a comprehensive and interesting approach to the problem of kidney transplantation. The authors cover a wide spectrum of transplant-related topics.

How to reference

In order to correctly reference this scholarly work, feel free to copy and paste the following:

Ming-Kuen Lai, Shuo-Meng Wang and Huai-Ching Tai (2011). Urothelial Carcinoma in Renal Transplant Recipients, *Kidney Transplantation - New Perspectives*, Dr Magdalena Trzcinska (Ed.), ISBN: 978-953-307-684-3, InTech, Available from: <http://www.intechopen.com/books/kidney-transplantation-new-perspectives/urothelial-carcinoma-in-renal-transplant-recipients>

INTECH
open science | open minds

InTech Europe

University Campus STeP Ri
Slavka Krautzeka 83/A
51000 Rijeka, Croatia
Phone: +385 (51) 770 447
Fax: +385 (51) 686 166
www.intechopen.com

InTech China

Unit 405, Office Block, Hotel Equatorial Shanghai
No.65, Yan An Road (West), Shanghai, 200040, China
中国上海市延安西路65号上海国际贵都大饭店办公楼405单元
Phone: +86-21-62489820
Fax: +86-21-62489821

© 2011 The Author(s). Licensee IntechOpen. This chapter is distributed under the terms of the [Creative Commons Attribution-NonCommercial-ShareAlike-3.0 License](https://creativecommons.org/licenses/by-nc-sa/3.0/), which permits use, distribution and reproduction for non-commercial purposes, provided the original is properly cited and derivative works building on this content are distributed under the same license.

IntechOpen

IntechOpen