

We are IntechOpen, the world's leading publisher of Open Access books Built by scientists, for scientists

6,900

Open access books available

186,000

International authors and editors

200M

Downloads

Our authors are among the

154

Countries delivered to

TOP 1%

most cited scientists

12.2%

Contributors from top 500 universities



WEB OF SCIENCE™

Selection of our books indexed in the Book Citation Index
in Web of Science™ Core Collection (BKCI)

Interested in publishing with us?
Contact book.department@intechopen.com

Numbers displayed above are based on latest data collected.
For more information visit www.intechopen.com



Ventilator Associated Tracheobronchitis

Ignacio Martin-Loeches¹, Sara Rosich², Elisabeth Papiol²,
Pau Castell³, Angel Pobo² and Alejandro Rodriguez²

¹Critical Care Center, Hospital de Sabadell, CIBER Enfermedades Respiratorias, Sabadell,

²Critical Care Department. Joan XXIII University Hospital, University Rovira i Virgili,
IISPV, CIBER Enfermedades Respiratorias (CIBERes), Tarragona,

³Primary Care Center of Torreforta-La Granja, Tarragona,
Spain

1. Introduction

Mechanical ventilation (MV), while life saving, also carries significant risks and complications. There is a huge information regarding ventilator-associated pneumonia (VAP) in terms of diagnosis, treatment and impact on the outcome of critically ill patients^{1,2,3}. However, nosocomial tracheobronchitis, and specifically Ventilator associated Tracheobronchitis (VAT) in the ICU is a definition with a difficult and complicated diagnosis^{4,5,6}. VAT represents an entity with several definitions and different treatment options up to different authors, without knowing exactly the impact on the outcome of critically ill patients. VAT is “microbiologically confirmed” when a patient with clinically diagnosed tracheobronchitis yields culture specimens that identify a causative pathogen. When a patient lacks fever or leukocytosis (or if culture specimens reveal few organisms) the differentiation between colonization and infection is difficult and controversial. Furthermore, the significance of tracheobronchial colonization as a risk factor for subsequent lower respiratory tract infection remains unclear⁷. This review attempts to summarize the current knowledge on VAT with special interest in the following questions: 1) What is the most appropriate definition of VAT? 2) How is the diagnosis performed in VAT? 3) When a VAT requires antibiotic treatment? and finally 4) What antibiotic treatment options might be considered?

2. Definition

The incidence of VAT varies widely in the literature^{8,9,10,11}. Malacarne et al⁷ in a recent multicenter study found, in more than 9000 patients included, an incidence of 15.5% tracheobronchitis, which is the third most common infection after pneumonia (47%) and tract urinary infection (26%). Another study⁸ showed an incidence of VAT of 10.6%, with a prevalence significantly higher in surgical (15.3%) compared to medical patients (9.9%. P = 0.01). However, the true prevalence of VAT is difficult to compare between studies because of the different definitions being used for diagnosis^{12,13}. For the CDC (Centers for Disease Control)⁶ the definition of VAT in adult patients must meet the radiological criteria of absence of pneumonia in the X-ray and at least 2 of the following findings: 1) fever (> 38 ° C)

2) cough, 3) new or increased production of sputum, 4) rhonchi and wheezing and 5) bronchospasm. In addition, a positive culture of bronchial secretions obtained by endotracheal aspirate (ETA) or bronchoscopic technique should be positive. Recent studies^{7,8,14} have used a more updated definition that includes some changes from the CDC criteria (Table 1). The VAT is "microbiologically" confirmed if a patient with clinical suspicion of VAT has a growth of a potentially pathogenic microorganism with a number of colony-forming units (cfu) above the cut-off points for those used in a lower respiratory sample^{4,5,7,11,12,13}. However, the definition of VAT has not been validated by studies using a comparable diagnosis techniques as a "gold standard." In patients in whom some of the items of the definition (fever or leukocytosis) are not present or the number of colony-forming units (cfu/ml) are below the suggested cutoff points, the differentiation between VAT (infection) and colonization might be difficult.

Criteria frequently used for diagnosis
<ul style="list-style-type: none">• Fever (Temperature > 38°C)• New or increased sputum production.• Leukocytosis.• Absence of new pulmonary infiltrates in X-ray.

Table 1. Criteria for Nosocomial tracheobronchitis.

Another point to consider in diagnosis refers to the absence of pulmonary infiltrates, which remains a controversial issue. In intubated patients admitted to ICU, the clinical condition and the technical difficulties in carrying out a portable X-ray make the diagnosis of absence of "new thoracic infiltrates", which is required for the diagnosis of VAT, difficult to assure and has a marked character of subjectivity. Several authors^{4,5,11,12,13} have also suggested the need to confirm or to rule out the existence of new thoracic infiltrates by chest computerized tomography (CT). However, this procedure is not always possible or routinely indicated in all ventilated patients when suspected VAT and its cost-benefit needs to be clarified. Therefore, it is necessary to assume a broad definition for this entity to identify patients at risk for VAT in order to identify those who must confirm the diagnosis by using complementary techniques and to decide whether or not starting antibiotic treatment.

3. Immune system interactions

The upper and lower airways can become colonized independently of each other¹⁵, the lower respiratory tract becoming colonized as a primary event and does not necessary need an initial colonization of the oropharynx, particularly when Gram negative bacilli such as *Pseudomonas sp* are present. In mechanically ventilated patients suggest a similar dichotomy between upper and lower airway colonization patterns. The upper airways contact with pathogenic microbes, therefore immune recognition principles have to be tightly controlled. Nuclear factor (NF)-kB is an important and highly inducible transcriptional factor activated by a variety of microbial components that signal through innate immune toll-like-receptors (TLR) and with a pivotal role in the transcription of genes involved in inflammatory response⁷. Cytokines are important mediators in both tracheal defense and inflammation. A constitutive secretion

of TGF- β (Transforming Growth Factor) by bronchial and tracheal epithelial showed a direct inhibitory effect on T lymphocyte proliferation¹⁶.

Recent studies have demonstrated that bronchial/tracheal epithelial (BEC) cells are functionally different and represents a first step of injury¹⁷. BEAS-2B bronchial epithelial cells are able to inhibit the secretion of the pro-inflammatory cytokines such as TNF- and IL-12 by monocytes, macrophages and dendritic cells.

Moreover, epithelial cell-conditioned T lymphocytes showed increased differentiation towards IL-10-producing Tr1 cells¹⁸. Bronchial epithelial cells induce a non-inflammatory microenvironment that regulates local immune homeostasis. These include transforming growth factor (TGF)- /TGF receptor (TGFR) 1, TNF- /TNFR1, and Fas/Fas ligand (FasL)⁷

Human bronchial/tracheal epithelial cells are more sensitive than small airway epithelial cells to induced apoptosis apparently due to a Fas response by apoptosis (caspase-8 activation) stimulation via an amplification loop involving several elements of the caspase (-8, -9, -3 and -6 in BEC, but not in SAEC). Again several pathways have been reported to be involved in inducing apoptosis of T cells^{19,7}.

4. Diagnosis

As mentioned above, there is a lack of agreement for definition but also no consensus on how to make a diagnosis of VAT. Several ways of diagnosis have been used and are mainly differentiated on the need for laboratory confirmation and the value assigned to the cutoff points of the isolates^{4,5,6,9,10}.

Typically, the diagnosis of VAT it is considered when a patient under invasive mechanical ventilation starts with fever and increased mucus production by endotracheal tube and an absence of new radiographic infiltrates, but always after having ruled out other possible foci of infection. However, this case scenario is not uncommon in critically ill patients and the mere fact of making a diagnosis of VAT may be associated with an unnecessary antibiotic treatment resulting in selection pressure on pathogens. Additional information may help to accurate the diagnosis of VAT. With the use of a bronchoscopy, the characteristics of secretions might be evaluated and also by obtaining a deeper sample is a relatively simple procedure that can help in diagnosis¹³. If during the procedure purulent secretions come from the deep portions of the lung, the possibility of VAT diagnosis is increased¹³.

Obtaining a sample of respiratory secretions for subsequent quantitative culture is mandatory in all patients with suspected VAT. Performing a Gram stain technique in respiratory sample allows assessing the degree of inflammation based on the number of PML and quickly guiding the antibiotic therapy used. The discovery of a potentially pathogenic microorganism in number of 10^5 , 10^4 or 10^3 CFU for BAS, BAL and protected brush respectively can also help in minimizing antibiotic overtreatment. According to some authors^{4,5,6,11,14}, infection can be differentiated from airway colonization and therefore stop antibiotic therapy initiated if microbial growth is below the cut-off points mentioned. However, due to the complexity of the mechanically ventilated critical patients, it is often difficult to distinguish clearly to whom antimicrobial therapy may be discontinued based on the cutoff points and a more comprehensive therapeutic approach is needed in order to evaluate whether to continue antibiotic treatment.

Inflammatory biomarkers such as C-reactive protein (CRP) and procalcitonin (PCT) have been used for the diagnosis of VAP^{20,21,22} and may also help in the diagnosis of VAT. Sierra et al¹⁵ showed that CRP may be a good indicator of infection in patients with inflammatory

response syndrome. In addition, while Lisboa et al.¹⁶ showed a good correlation between bacterial load measured as CFU/ml on quantitative culture of respiratory secretions and serum CRP, Pova et al¹⁷ showed that the evolution of serum CRP could be related to the recognition and development of VAP. Finally, despite of there is a lack of evidence for VAT diagnosis based on CRP, high levels of PCT and CRP (> 30 U / L) probably suggest a high bacterial load and a greater inflammatory response secondary more evident when a VAP is present.

Whereas VAP and VAT present similar clinical features, VAT does not involve lung parenchyma manifested by thoracic infiltrates in X-ray, therefore to make a differential diagnosis remains difficult in critically ill patients. The VAT may represent an intermediate process between the colonization of the lower airway and the VAP and should probably be interpreted as a continuum and dynamic process between bronchitis and pulmonary parenchymal infection^{5,13}. Figure 1. It Therefore, VAT might be considered as "a particular clinical entity" that in certain patients may require specific treatment, rather than requiring a rigid and uniform definition.

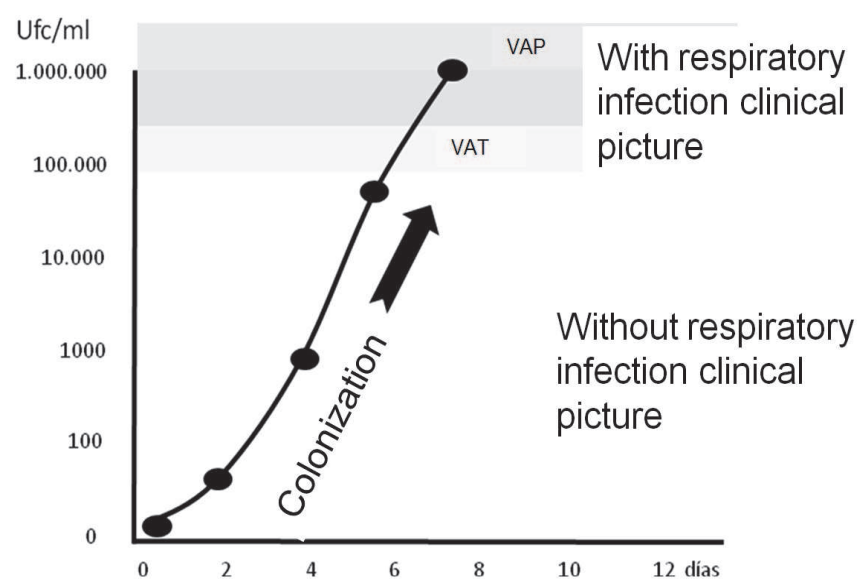


Fig. 1. Changes of tracheal colonization on mechanical ventilation patients in accordance to endotracheal bronchial aspirate. Note that colonization occurs without clinical signs of respiratory infection, Respiratory infection is present when colonization levels (CFU / ml) exceed 10⁵. The difference between pneumonia (VAP) and tracheobronchitis (VAT) would be determined only by the lack of involvement of lung parenchyma in the VAT (Modified from reference 5).

5. Prevention and treatment

In an attempt to prevent bacterial colonization several strategies might be taken into account. Coated ETTs induced a nonsignificant reduction of the tracheal colonization, reduced bacterial colonization of the ETT and ventilator circuits, and prevented lung bacterial colonization²³.

In addition the role of tracheostomy in mechanically ventilated patients remains controversial. A patient who has a colonized airway and who undergoes percutaneous

tracheotomy has an increased risk of VAP in the week following the procedure^{24,7}. The presence of a plastic device always causes a low grade of local mucocutaneous inflammation. Microorganisms show an affinity for the tracheotomy rather than the oropharynx as the site of acquisition. In addition, introduction of microorganisms directly into the lower airways via the tracheotomy as a result of repeated suctioning and manipulation of the trachea represents an important exogenous pathway. Recently, Nseir et al²⁵ reported that tracheotomy was independently associated with a decreased risk of VAP due to the fact that liberation of the vocal cords, resulting in a reduced risk of aspiration of contaminated oropharyngeal secretions into the lung and the reduction in bacterial biofilm formation associated with regular changing of the tracheotomy cannula, but rates of tracheobronchitis were not reported. The role of tracheostomy in development of tracheobronchitis has not been studied and future research should be performed. Prevention of lower respiratory infection in patients under MV is cornerstone in preventing the development of VAT. Different prevention strategies may also help to avoid the development of VAT and VAP subsequently which must be implemented systematically in every patient (Figure 2).

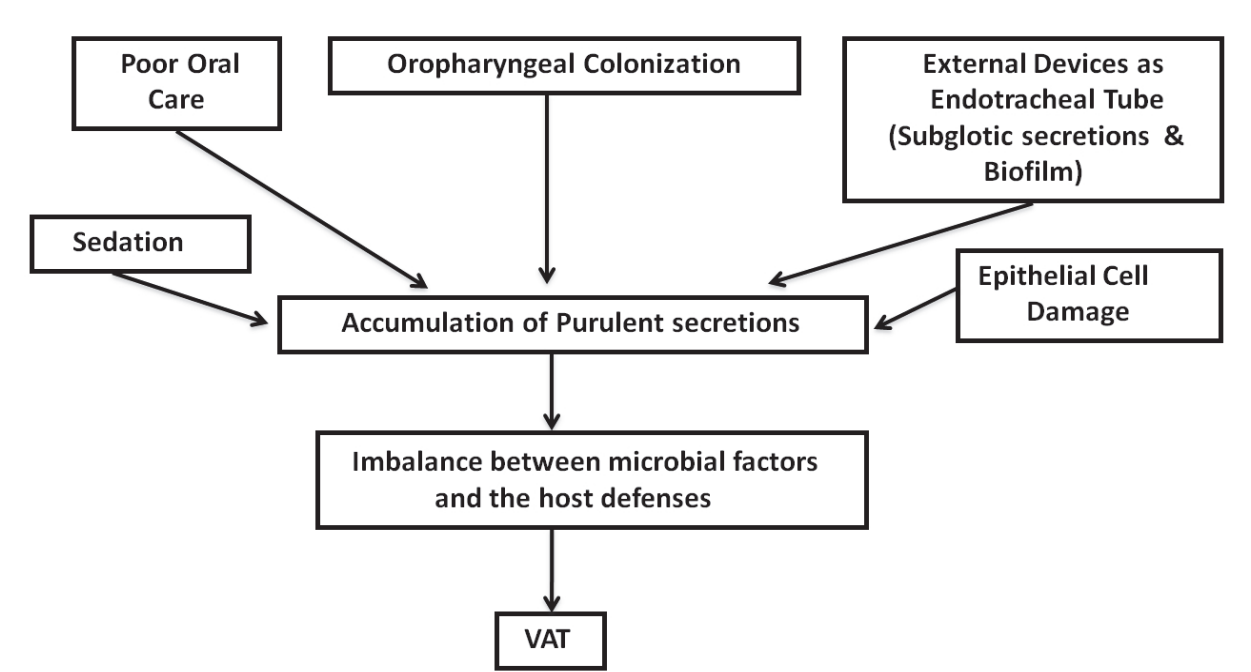


Fig. 2. Ventilator Associated Tracheobronchitis Pathophysiology

Antibiotic treatment, timing to start antimicrobial and route of administration when a patients is affected by a VAT is a subject of ongoing controversy^{4,5,13}. There is little doubt to start promptly intravenous antibiotic in a hemodynamically unstable patient under MV with fever when VAT is a reasonable diagnosis, and after rolling out other sources of infection. However, there are many critically ill patients presenting VAT without hemodynamic compromise. In these cases, antimicrobial therapy is questionable. The use of antibiotics in VAT has been evaluated in 2 recent Randomized Controlled Trials (RCT). Palmer et al²⁶ conducted a double-blind, placebo-control RCT in ICU. Patients were assigned to receive antibiotics (ATB) nebulized (gentamicin and / or vancomycin) for 14 days or until extubation or to receive placebo (saline). Patients assigned to receive nebulized

ATB had a lower incidence of VAP, faster weaning and less use of systemic ATB. These results should be interpreted with caution, since the administration of systemic ATB was not standardized and based on the attending physician. Moreover, quantitative culture of respiratory secretions was not performed. In the other hand, Nseir et al¹⁴ conducted a prospective, multicenter randomized study in intubated patients based on surveillance quantitative culture of tracheal aspirates obtained after intubation. Patients were randomized to receive or not intravenous ATB for 8 days after performing the diagnosis of VAT by a quantitative culture of bronchial secretions with $> 10^6$ CFU / ml and a growth of a new pathogen not present on admission. The main findings were that the group treated with ATB had a lower mortality rate, more VM free-days and lower incidence of VAP. While these results are interesting, some important limitations of this study make to consider the findings very carefully. The study included only 34 patients after 2 years of study but had to be interrupted by the low recruitment and showed lower mortality in the interim analysis with a non pre-defined number of patients. In addition, the increased mortality in the untreated group might be due to higher incidence of *Pseudomonas aeruginosa* VAP and not directly related to the VAT.

The results of these prospective studies, although inconclusive, are attractive and open the debate regarding when patients affected by VAT should be treated or not with ATB. In our opinion, if the patient has clinical signs of VAT with fever, leukocytosis, and purulent secretions, a short course of ATB (5-7 days) should be initiated after obtaining a respiratory specimen for culture. The administration of aerosolized ATB / nebulized in patients with uncomplicated VAT is also a attractive idea, but new well-designed prospective studies are warranted in order to implement future therapeutic decisions

6. Conclusions

VAT is a relatively common entity in ventilated patients admitted to an ICU. Differential diagnosis with VAP is difficult and might require additional information based on biomarkers such as CRP or PCT. The development of VAT seems to be associated with an increase development of VAP, a longer time under MV, longer hospital stay and possibly increased mortality with probably. Recent studies seem to suggest that ATB treatment of VAT is associated with lower mortality and a reduction of days of mechanical ventilation. Nevertheless and based on the limitations suggested for previous studies conducted, the indication to start antibiotic therapy as well as the most effective route of administration should be defined by future RCT.

Until these results are published, the most appropriate behavior in a patient with symptoms of VAT seems to correspond to the administration of a short course of systemic ATB.

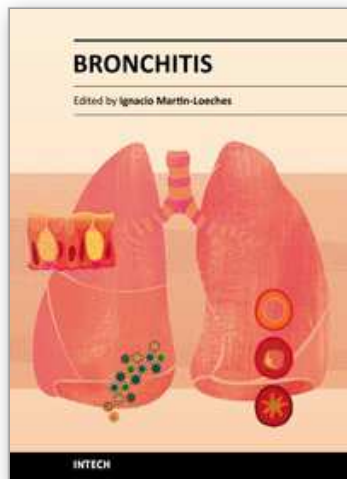
7. References

- [1] Vidaur L, Sirgo G, Rodríguez A, Rello J. Clinical approach to the patients with suspected ventilador-associated pneumonia. *Respir Care* 2005; 50:965-74
- [2] Agbaht K, Lisboa T, Pobo A et al. Management of ventilator-associated pneumonia in a multidisciplinary intensive care unit: does trauma make a difference?. *Intensive Care Med* 2007;33:1387-95
- [3] Garnacho-Montero J, Sa-Borges M, Solé-Violán J et al. Optimal management therapy for *Pseudomonas aeruginosa* ventilator-associated pneumonia: An observational,

- multicenter study comparing monotherapy with combination antibiotic therapy. *Crit Care* 2007; 35:1888-95
- [4] Nseir S, Ader F, Marquette CH. Nosocomial tracheobronchitis. *Curr Opin Infect Dis* 2009; 22: 148-153
- [5] Craven DE, Chroneou A, Zias K, Hijalmarson KI. Ventilator-associated tracheobronchitis. The impact of target antibiotic therapy on patient outcomes. *Chest* 2009;135:521-28
- [6] Garner JS, Jarvis WR, Emori TG, Horan TC, Hughes JM. CDC definitions for nosocomial infections, 1988. *Am J Infect Control* 1988;16:128-40
- [7] Martín-Loeches I, Pobo A. What is new in ventilator-associated tracheobronchitis? *Clin Pulm Med* 2009 (in press)
- [8] Malacarne P, Langer M, Nascimben E et al. Building a continuous multicenter infections surveillance system in the intensive care unit: finding from initial data set of 9493 patients from 71 Italian intensive care units. *Crit Care Med* 2008;36:1105-13.
- [9] Nseir S, Di Pompeo C, Pronnier P et al. Nosocomial tracheobronchitis in mechanically ventilated patients: incidence aetiology and outcome. *Eur Respir J* 2002;20:1483-89
- [10] Rouby JJ, De Lassale E, Poete P, et al. Nosocomial bronchopneumonia in the critically ill. Histologic and bacteriologic aspects. *Am Rev Respir Dis* 1992; 146:1059-66
- [11] Rello J, Ausina V, Castella J et al. Nosocomial respiratory tract infections in multiple trauma patients : influence of level of consciousness with implications for therapy. *Chest* 1992; 102:525-29.
- [12] Craven DE. Ventilator-associated tracheobronchitis (VAT): questions, answers, and a new paradigm?. *Crit Care* 2008;12:157
- [13] Torres A, Valencia M. Does ventilator-associated tracheobronchitis need antibiotic treatment?. *Crit Care* 2005;9:255
- [14] Nseir S, Favory R, Jozefowicz E et al. Antimicrobial treatment for ventilator-associated tracheobronchitis: a randomized, controlled, multicenter study. *Crit Care* 2008;12:R62.
- [15] Niederman MS, Ferranti RD, Ziegler A, Merrill WW, Reynolds HY. Respiratory infection complicating long-term tracheostomy: the implication of persistent gram-negative tracheobronchial colonization. *Chest* 1984; 85:39-44
- [16] Ward PA, Lentsch AB Endogenous regulation of the acute inflammatory response. *Mol Cell Biochem* 2002 234-235: 225-228
- [17] Mayer AK, Bartz H, Fey F, Schmidt LM, Dalpke AH Airway epithelial cells modify immune responses by inducing an anti-inflammatory microenvironment. *Eur J Immunol.* 2008 Jun;38(6):1689-99.
- [18] Sillett HK, Cruickshank SM, Southgate J, and Trejdosiewicz LK. Transforming growth factor-beta promotes 'death by neglect' in post-activated human T cells. *Immunology* 2001 102: 310-316.
- [19] R. Ray, B. Keyser, D. Andres, S. Hauck, B. Benton, C. Carpin, A. Daher, C. Simbulan-Rosenthal, and D. Rosenthal Human bronchial/tracheal epithelial cells (BEC) are more sensitive than small airway epithelial cells (SAEC) to sulfur mustard-induced apoptosis apparently due to a Fas (death receptor) response amplification loop *FASEB J.* 22: 648.6
- [20] Sierra R, Rello J, Bailén MA et al. C-reactive protein used as an early indicator of infection in patients with systemic inflammatory response syndrome. *Intensive Care Med* 2004; 30:2038-45

- [21] Lisboa T, Seligman R, Díaz E et al. C-reactive protein correlatos with bacterial load and appropriate antibiotic therapy in suspected ventilator-associated pneumonia. *Crit Care Med* 2008; 36:166-171
- [22] Pova P, Coelho L, Almeida E et al. C-reactive protein as a marker of ventilador-associated pneumonia. *Eur Respir J* 2005;25:804-12
- [23] Kollef MH, Afessa B, Anzueto A, Veremakis C, Kerr KM, Margolis BD, Craven DE, Roberts PR, Arroliga AC, Hubmayr RD, Restrepo MI, Auger WR, Schinner R; NASCENT Investigation Group. Silver-coated endotracheal tubes and incidence of ventilator-associated pneumonia: the NASCENT randomized trial. *JAMA*. 2008 Aug 20;300(7):805-13
- [24] Daniel T, Blandine M, Claude R,etal: Risk and routes for ventilator associated pneumonia with *Pseudomonas aeruginosa*. *Am J Respir Crit Care Med* 1998; 157:978-984
- [25] Nseir S, Di Pompeo C, Jozefowicz E, et al. Relationship between tracheotomy and ventilator-associated pneumonia: a case-control study. *Eur Respir J* 2007; 30: 314-320
- [26] Palmer LB, Smaldone GC, Chen JJ et al. Aerosolized antibiotics and venilator-associated tracheobronchitis in the intensive care unit. *Crit Care Med* 2008;36:2008-13

IntechOpen



Bronchitis

Edited by Dr. Ignacio MartÃn-Loeches

ISBN 978-953-307-889-2

Hard cover, 190 pages

Publisher InTech

Published online 23, August, 2011

Published in print edition August, 2011

Lung parenchyma has been extensively investigated. Nevertheless, the study of bronchial small airways is much less common. In addition, bronchitis represents, in some occasions, an intermediate process that easily explains the damage in the lung parenchyma. The main target of this book is to provide a bronchial small airways original research from different experts in the field.

How to reference

In order to correctly reference this scholarly work, feel free to copy and paste the following:

Ignacio Martin-Loeches, Sara Rosich, Elisabeth Papiol, Pau Castell, Angel Pobo and Alejandro Rodriguez (2011). Ventilator Associated Tracheobronchitis, Bronchitis, Dr. Ignacio MartÃn-Loeches (Ed.), ISBN: 978-953-307-889-2, InTech, Available from: <http://www.intechopen.com/books/bronchitis/ventilator-associated-tracheobronchitis>

INTECH
open science | open minds

InTech Europe

University Campus STeP Ri
Slavka Krautzeka 83/A
51000 Rijeka, Croatia
Phone: +385 (51) 770 447
Fax: +385 (51) 686 166
www.intechopen.com

InTech China

Unit 405, Office Block, Hotel Equatorial Shanghai
No.65, Yan An Road (West), Shanghai, 200040, China
中国上海市延安西路65号上海国际贵都大饭店办公楼405单元
Phone: +86-21-62489820
Fax: +86-21-62489821

© 2011 The Author(s). Licensee IntechOpen. This chapter is distributed under the terms of the [Creative Commons Attribution-NonCommercial-ShareAlike-3.0 License](https://creativecommons.org/licenses/by-nc-sa/3.0/), which permits use, distribution and reproduction for non-commercial purposes, provided the original is properly cited and derivative works building on this content are distributed under the same license.

IntechOpen

IntechOpen