

We are IntechOpen, the world's leading publisher of Open Access books Built by scientists, for scientists

6,900

Open access books available

186,000

International authors and editors

200M

Downloads

Our authors are among the

154

Countries delivered to

TOP 1%

most cited scientists

12.2%

Contributors from top 500 universities



WEB OF SCIENCE™

Selection of our books indexed in the Book Citation Index
in Web of Science™ Core Collection (BKCI)

Interested in publishing with us?
Contact book.department@intechopen.com

Numbers displayed above are based on latest data collected.
For more information visit www.intechopen.com



Electroretinogram in Hereditary Retinal Disorders

Fatih Cakir Gundogan¹, Ahmet Tas² and Gungor Sobaci³

¹*Etimesgut Military Hospital*

²*Ankara Mevki Military Hospital*

³*Gulhane Military Medical Academy
Turkey*

1. Introduction

Electroretinogram (ERG) represents the electrical response of retina to a light stimulus. The light stimuli may be either a pattern (spatially structured) stimulus or a flash (unstructured) stimulus, and the retina may be stimulated completely or partially. In this chapter, we will briefly mention about the recording procedures of electroretinographic tests. Electroretinographic testing procedures and findings in hereditary retinal dystrophies will be discussed from a clinical point of view.

1.1 The full-field electroretinogram

Full-field ERG is the diffuse response of both neural and nonneural cells of the retina to a light stimulus. The response recorded after such a stimulus represents the sum of the positive and negative components that originate from different stages of retinal processing overlap in time. The recorded electrical activity is the result of light-induced changes in the transretinal movements of ions, principally sodium and potassium, in the extracellular space (Fishman, 2001). The electrical responses originated in the retina are recorded by active electrodes that contact the cornea or nearby bulbar conjunctiva. These include contact lens electrodes, conductive fibers and foils, conjunctival loop electrodes and corneal wicks. The responses are amplified, averaged and displayed on screens.

The rod and cone responses may be functionally dissected with ERG in the light of International Society for Clinical of Vision (ISCEV) recommendations (Marmor et al., 2009) (Figure 1).

1.1.1 Clinical ERG recording

1.1.1.1 The rod ERG

The patient should be dark-adapted for at least 20 minutes. The recommended stimulus is a dim white flash of strength 2.5 log units below the white standard flash (3.43cd/m²) on a dark background. Instead, a blue stimulus equivalent to the white standard may be used to stimulate the rod photoreceptors (Figure 1A).

1.1.1.2 The standard combined ERG

After recording rod ERG, a brighter white flash (standard flash) on a dark background is used to stimulate the retina. The standard combined ERG is the combined response of both rod and cone photoreceptors (Figure 1B).

1.1.1.3 The oscillatory potentials

Oscillatory potentials may be recorded from dark-adapted or light-adapted eye (at least 10-min of light adaptation) by using standard flash after standard-combined ERG recording. By adjusting the high-pass and low-pass filters, only the high-frequency responses originated from the amacrine cells are obtained (Figure 1C).

1.1.1.4 The single-flash cone ERG

In order to be able to isolate cone photoreceptor response, the rod photoreceptors must be suppressed by a bright background. The patient should be light-adapted for at least 10-min before the recording. A standard flash is used to obtain cone responses (Figure 1D).

1.1.1.5 Flicker ERG

Flicker ERG is recorded under the same conditions of light-adaptation as the single-flash cone ERG. The standard flashes are presented at a rate of approximately 30 stimuli per second. Rod photoreceptors can not respond to flickering light with a frequency above 20 Hz (Figure 1E).

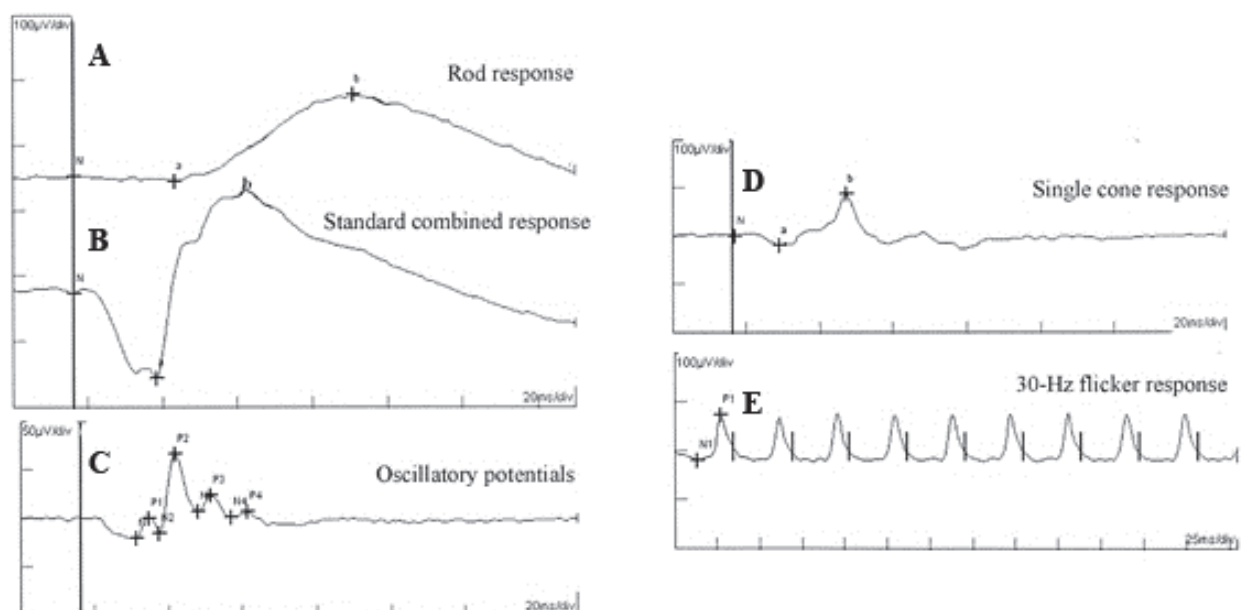


Fig. 1. Representative full-field electroretinogram recorded under ISCEV guidelines

1.1.2 The origins of ERG waves

The ERG generally consists of a negative deflection, called the a-wave, and a positive deflection, called the b-wave (Figure 1B). A-wave is mainly a response of photoreceptors, while the b-wave is mainly associated with on-bipolar cell function. A-wave is generally not recordable in rod ERG responses recorded under ISCEV recommendations (low-intensity flashes). There is a large magnification of electrical activity as signals are transmitted from

photoreceptors to inner retinal neurons, for this reason, b-wave may be recorded in lower intensity flashes which does not produce a-wave response (Figure 1A). However, as the intensity of the light stimulus increases, the a-wave begins to be recorded. But, in such intensities, the cone photoreceptors begin to respond to the light flash. This violates the recording of absolute rod photoreceptor function. For this reason, b-wave response in rod ERG shows the on-bipolar cell function originated from the rod photoreceptors. Standard flash stimulates both rod and cone photoreceptor and generates both a- and b-wave deflections (Figure 1B). Oscillatory potentials are a series of wavelets on the ascending limb of the ERG b-wave after stimulation by an intense light flash. These are high-frequency, low-amplitude components of the ERG with a frequency of about 100 to 160 Hz. These responses originate in the circuitry between the amacrine cells and other retinal neurons. By comparison, the a- and b-waves are dominated by frequency components of about 25 Hz (Fishman, 2001). Single-flash cone ERG and 30-Hz flicker ERG have a- and b-wave components representing the cone photoreceptors and cone on-bipolar cell functions, respectively.

1.2 Multifocal electroretinogram

The ERG is the sum activity of the cells of the retina and, small retinal defects may not be detected by standard ERG testing. Pattern electroretinogram (PERG) can provide valuable information about the macular function. However, both of these techniques still lack the topographical information of the retinal response. The multifocal ERG (mfERG) technique was developed by Sutter and Tran to deal with these problems (Sutter & Tran, 1992). The use of mfERG enables topographic mapping of retinal function in the central 40-50 degrees of the retina.

Typically, the multifocal stimulus is displayed on a computer monitor. The display contains an array of hexagons; the most commonly used displays contain either 61 or 103 hexagons (Figure 2). The hexagons may be scaled to produce local cone responses of approximately equal amplitude.

2. Hereditary retinal disorders

Hereditary retinal disorders constitute a heterogeneous group of eye disorders. These disorders differ one from another in many aspects, such as the mode of inheritance, the rate of progression, appearance of ophthalmoscopy and the type of visual handicap they cause among affected patients.

In this chapter, we will discuss the electroretinographic findings of hereditary retinal disorders under the main headings of; retinitis pigmentosa and pigmentary retinopathies, cone dystrophies, juvenile X-linked retinoschisis, congenital stationary night blindness, hereditary macular disorders, hereditary vitreoretinal disorders, and hereditary chorioretinal dystrophies.

2.1 Retinitis pigmentosa and pigmentary retinopathies

Retinitis pigmentosa is a significant cause of visual impairment all over the world and belongs to the group of pigmentary retinopathies, a generic name that covers all retinal dystrophies presented with a loss of photoreceptors and retinal pigment deposits. The

macular function is generally preserved until adulthood. The primary pathologic mechanism is the degeneration of the rod photoreceptors, and a secondary degeneration of cone photoreceptors. For this reason, classical retinitis pigmentosa may also be described as rod-cone dystrophy, rod photoreceptors being more affected than cones. The sequence of photoreceptor involvement explains why the patients experience night vision impairment in the early stages of the disease, with the visual acuity loss in later stages (Hamel, 2006). In the early stages the patients lose peripheral vision, but eventually central vision deteriorates. In advanced stages, signs include attenuated retinal vessels, intraretinal pigment, and waxy pallor of the optic discs.

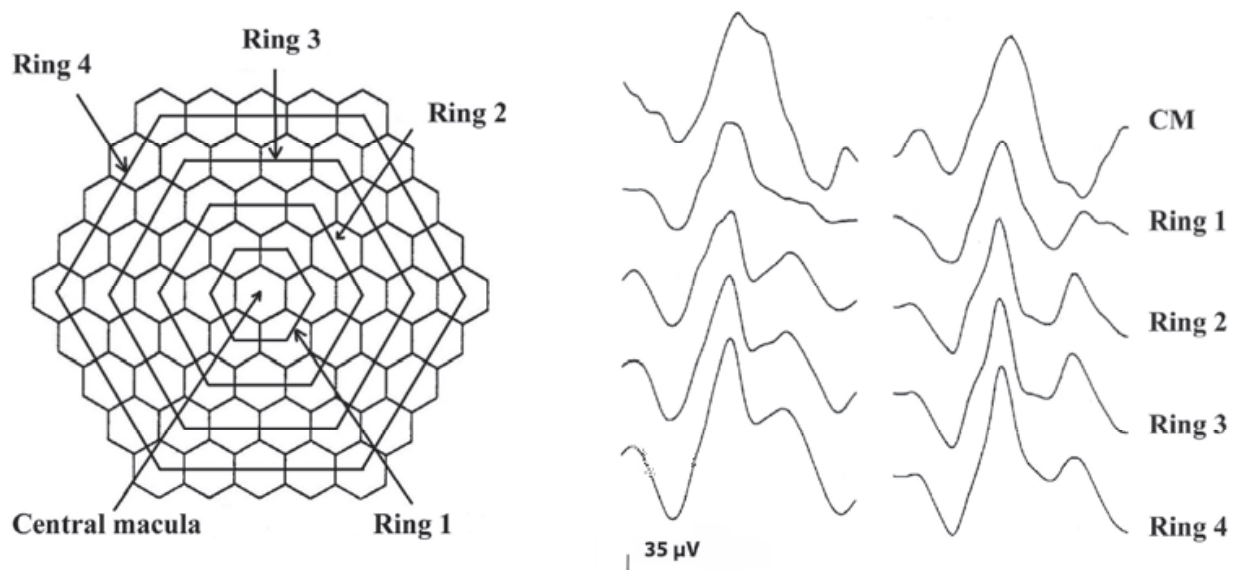


Fig. 2. Multifocal electroretinogram stimulus consisting of 61 hexagons (left) and corresponding multifocal electroretinogram responses belonging to the five concentric rings from both eyes (right).

The incidence of retinitis pigmentosa has been estimated to be 1 in 3500 to 1 in 3700 births in the United States (Boughman et al, 1980; Bunker et al, 1984) and 1 in 3400 to 1 in 8000 births in Japan (Berson, 1987). Genetic type of retinitis pigmentosa was reported to be 19% dominant, 19% recessive, 8% X-linked, 46% isolates, and 8% undetermined in the United States (Bunker et al, 1984).

Retinitis pigmentosa may be evaluated as syndromic and nonsyndromic from a clinical point of view. Most patients with RP are nonsyndromic; that is they do not have any other associated systemic disease. The syndromic conditions with associated RP are Usher syndrome, Bassen-Kornzweig syndrome (abetalipoproteinemia), Refsum disease, Laurence-Moon-Biedl syndrome, neuronal ceroid lipofuscinosis (Batten disease), Alström disease, and Kearns-Sayre syndrome.

2.1.1 Hereditary types of RP and ERG findings

The most significant factor determining the disease severity of the retinitis pigmentosa is the genetic type. Autosomal dominant retinitis pigmentosa is the mildest form. Some patients with autosomal dominant form experience vision impairment after the age of 50. Autosomal recessive and X-linked recessive types have a more severe course with the typical onset of

disease in the first decade (Hamel, 2006). Figure 3 shows classical examples of ERGs recorded from retinitis pigmentosa patients with different hereditary types.

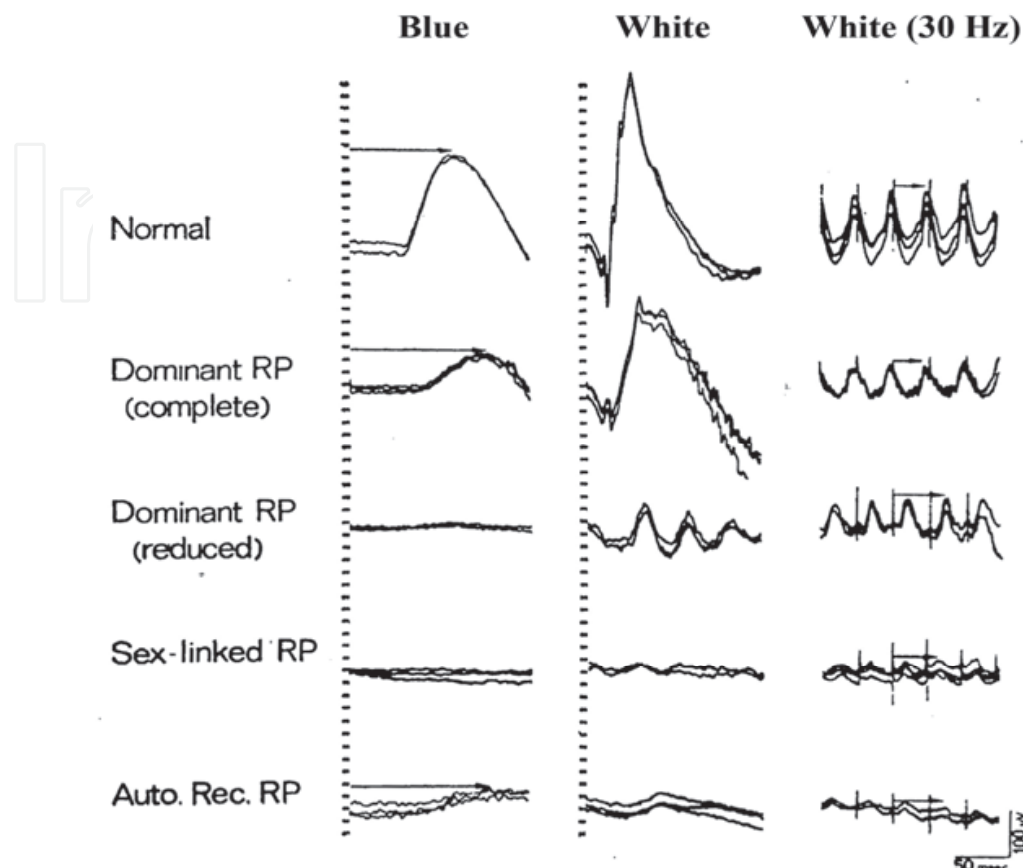


Fig. 3. Full-field electroretinography examples of autosomal dominant, autosomal recessive and, X-linked recessive retinitis pigmentosa. Patients with autosomal recessive and X-linked inheritance patterns have more severe disease course with earlier retinal functional impairment. (Used with permission of American Academy of Ophthalmology and Otolaryngology. From. Retinitis pigmentosa and allied retinal diseases: Electrophysiological findings, Berson, Transactions - American Academy of Ophthalmology and Otolaryngology, Vol 81, Number 4, pp. OP659-OP666, 1976)

Very small ERG responses may not be recorded under the standardized recording procedures in retinitis pigmentosa patients very with advanced disease. The response may be *nonrecordable* under conditions of ISCEV guidelines. In these circumstances, narrow band filtering method provides the recording of 30-Hz cone response amplitudes below 1 microvolt. In this method, hundreds of 30-Hz cone responses are averaged to reduce the effect of background noise. In addition, a narrow-band electronic filter with bandpass of 29-31 Hz and a center frequency of 30 Hz alters the recorded signal so that only the 30-Hz recorded signals are preserved. (Andreasson et al, 1988).

2.1.2 Implicit time in retinitis pigmentosa

Berson showed that cone b-wave implicit time delay is a consistent finding in generalized retinitis pigmentosa (Berson, 1987). Fishman et al. categorized autosomal dominantly inherited retinitis pigmentosa patients into 4 groups with respect to implicit time of the cone

responses (Fishman et al, 1985). Marmor reported that retinitis pigmentosa patients with normal cone b-wave implicit times have a better prognosis (Marmor, 1979). In the presence of *sector* retinitis pigmentosa, cone b-wave implicit time was reported to be normal by the same authors (Berson, Howard, 1971). In normal human eyes, rod-cone interaction mechanism was shown to be responsible for the relation of implicit time of the cone response and the amplitudes of rod response. Birch and Sandberg found that cone response b-wave implicit time seen in patients with retinitis pigmentosa is inversely correlated to the log amplitude of the dark-adapted rod b-wave (Birch & Sandberg, 1987) (Figure 4). Similarly, Iijima et al reported that patients with normal cone b-wave implicit times had better prognosis in terms of the onset of night blindness (Iijima et al, 1993).

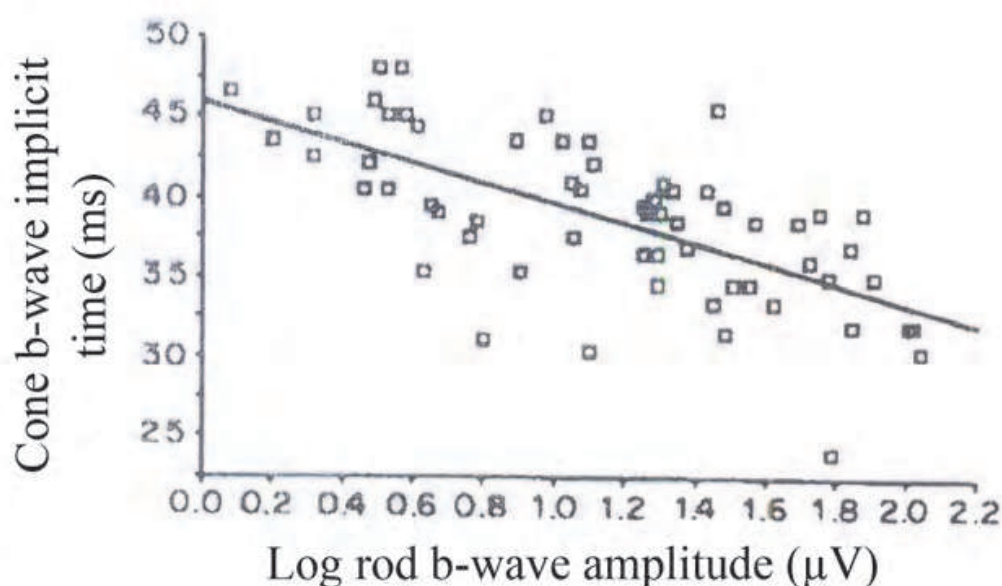


Fig. 4. Scatter plot and linear regression for cone b-wave implicit time as a function of log rod b-wave amplitude in retinitis pigmentosa. Regression line is $y=46-6.3x$ and does not control for the nonsignificant effect of cone b-wave amplitude on cone b-wave implicit time (used with permission of Pergamon Journals Ltd. From „Dependence of cone b-wave implicit time on rod amplitude in retinitis pigmentosa“, Birch et al, Vision Research, Volume 27, Number 7, 1987; permission conveyed through Copyright Clearance Center, Inc)

2.1.3 Electronegative ERG in RP

Electronegative ERG refers to an ERG in which the a-wave is normal and the b-wave is severely subnormal, being smaller in amplitude than the a-wave. This classic description was used for years. However, recently the term electronegative ERG has been used to describe any ERG in which the b-wave amplitude is smaller than the a-wave amplitude whether a-wave amplitude is normal or reduced (Weleber & Francis, 2006). Although the term was initially applied only to the dark-adapted mixed rod-cone ERG, the term has recently been used to describe a similar configuration for the cone ERG (Weleber & Francis, 2006; Kellner & Foerster, 1993; Swain et al, 1997).

There are approximately 120 million rods and 6 million cones in the retina. This difference constitutes the basis of the fact that the ERG is mainly rod-driven. The a-wave in standardized ERG is generated by the rod phototransduction. The b-wave arises from the

ON bipolar cell depolarization after the signal originated in the outer cell membranes of the photoreceptors. For this reason, electronegative ERG response reflects any pathophysiological process that prevents electrical signals reaching to ON-bipolar cells. This phenomenon is called *postphotoreceptor transmission defect*.

Cideciyan and Jacobson reported patients with typical clinical features of RP and negative ERG pattern (Cideciyan & Jacobson, 1993) (Figure 5). The authors speculated three mechanisms for this finding. One speculation is that this type of disease expression may be caused by an abnormal gene product at the photoreceptor terminal regions unlike classical retinitis pigmentosa which causes abnormalities in outer segment proteins such as rhodopsin and peripherin (Humphries et al, 1992). This could lead to defective signal transmission between photoreceptors and bipolar cells; the outer segment disease would be ascribed to secondary degenerative processes. Another speculation is that this phenotype of disease may be caused by functional and/or morphological involvement in both the photoreceptor and postphotoreceptor sites. The third speculation is that the inner retinal dysfunction in this patient group may be caused by a different secondary effect.

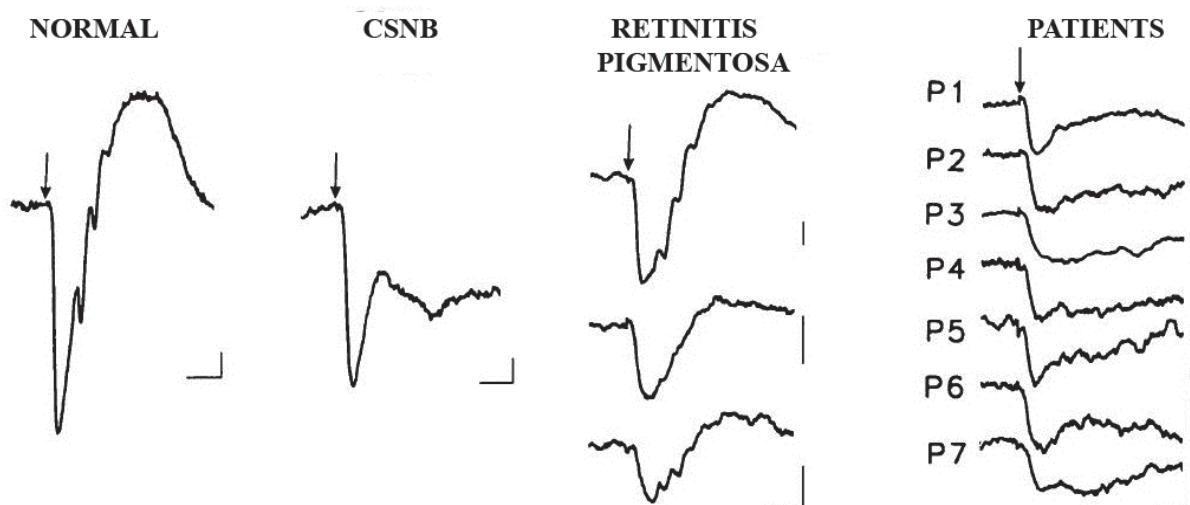


Fig. 5. Full-field electroretinograms in a normal subject, a congenital stationary night blindness (CSNB) patient, representative classical retinitis pigmentosa patients without negative electroretinograms, and seven patients with negative electroretinograms (Arrow indicates stimulus onset. Horizontal calibration is 20 ms for all traces; vertical calibration is 50 μ V) (used with permission of Association for Research in Vision and Ophthalmology. From: Negative Electroretinograms in Retinitis Pigmentosa, Cideciyan & Jacobson, Volume 34, Number 12, 1993; permission conveyed through Copyright Clearance Center, Inc)

2.1.4 Multifocal electroretinogram in RP

MfERG assesses local retinal cone functions. The normal mfERG amplitude declines with increasing eccentricity from fixation. MfERG amplitude decline is much more pronounced in patients with retinitis pigmentosa. MfERG may enable the progression of retinitis pigmentosa to be followed more accurately, facilitating a better understanding of the variants of the disease (Keating & Parks, 2006).

Retinitis pigmentosa patients were found to have significant reductions in response amplitudes at all retinal eccentricities and implicit times were generally normal in the central areas but became significantly delayed towards peripheral retina (Chan & Brown,

1998; Feliuss & Swanson, 1999; Holopigian et al, 2001; Hood et al, 1998; Kondo et al, 1995) (Figure 6). In the advanced stages of retinitis pigmentosa, ERG responses may even be non-detectable in the presence of good visual acuities. In these circumstances, mfERG not only shows the objective function of the fovea, but also the progression of the disease. Hood et al. found that implicit time changes but not amplitude changes in mfERG were correlated with the locations of visual field sensitivity loss (Hood et al, 1998).

2.1.5 The variants of classic RP

The variants of classic RP show diverse patterns both morphologically and electrophysiologically.

2.1.5.1 Unilateral RP

Unilateral retinitis pigmentosa is used to define unilateral retinal pigmentary degeneration with abnormal ERG while the other eye is clinically and functionally normal. In order to diagnose unilateral retinitis pigmentosa, the patient should be followed for a period of time by means of clinical and electroretinographic methods to ensure that retinal function in the unaffected eye does not impair with time. This method may explore asymmetric bilateral retinitis pigmentosa in most cases. ERG recording may document diminished response in the "normal" eye with normal fundoscopic appearance. In addition, pigmentary changes in the affected eye should not be due to acquired retinal disorders such as ophthalmic artery occlusion, syphilis, rubeola, diffuse unilateral subacute neuroretinitis and, traumatic retinal injuries (Auerbach et al, 1969). Kolb and Galloway stressed the importance of family history in diagnosing unilateral retinitis pigmentosa. The authors suggested that unilateral retinitis pigmentosa is probably a partial manifestation of a bilateral disease, however, true unilateral retinitis pigmentosa really exists (Kolb & Galloway, 1964). Kandori et al. reported two cases of ophthalmic artery occlusion causing unilateral pigmentary retinopathy mimicking retinitis pigmentosa (Kandori et al, 1968).

2.1.5.2 Sector RP

Sector retinitis pigmentosa defines typical retinitis pigmentosa signs including attenuated retinal vessels, and retinal pigmentary changes when confined to one or two quadrants of the retina. The most frequent inheritance pattern is autosomal dominant, but autosomal recessive and X-linked recessive traits were also reported. Mostly, inferior and nasal retina is involved which causes a superior or superotemporal visual field defect. Sector retinitis pigmentosa is mostly bilateral, and symmetric. In contrast to classical retinitis pigmentosa types, sector retinitis pigmentosa is considered stationary or only very slowly progressive, and the fovea preserves its normal function at old age (Abraham, 1975).

The ERG changes are generally proportional to the area involved in the retina. However, perimetric and electrophysiologic studies demonstrated that normal-appearing retina may also have functional deficits. Berson et al reported normal rod and cone implicit time in sector retinitis pigmentosa (Berson & Howard, 1971) in contrast to widespread retinitis pigmentosa which causes typical implicit time delays.

2.1.5.3 RP sine pigmento

Retinitis pigmentosa sine pigmento is used to define the condition of normal-appearing retina and diffuse photoreceptor cell dysfunction. However, whether this clinical condition is a distinct entity other than classical retinitis pigmentosa or an early stage or a variant of retinitis pigmentosa remains to be clarified (Fishman, 2001).

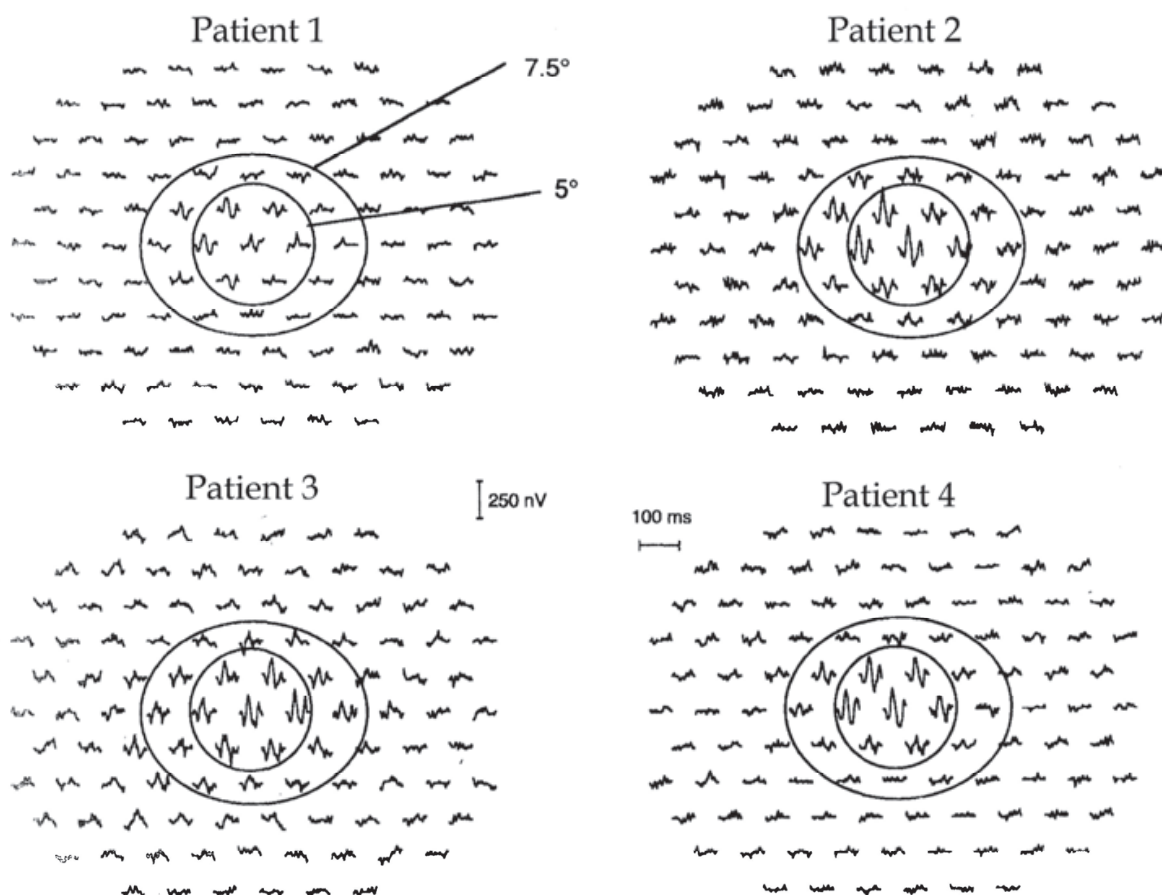


Fig. 6. Multifocal electroretinography responses from four patients. The circles in each panel indicate the areas with a radius of 5 or 7.5 degree. Multifocal electroretinogram responses are diminished in peripheral retina and preserved in the central areas (Used with permission of Elsevier Science Ltd. From: Vision Research, Vol 38, Number 1, Hood et al, Assessment of local retinal function in patients with retinitis pigmentosa using the multi-focal ERG technique, 1997, permission conveyed through Copyright Clearance Center, Inc).

2.1.5.4 Retinitis punctata albescens

Retinitis punctata albescens is a type of retinitis pigmentosa characterized by diffuse white, deep, punctate lesions throughout the retina. The retinal degeneration has a progressive nature with night blindness and peripheral visual field loss.

2.1.5.5 Usher syndrome

Usher syndrome is an autosomal recessive disease characterized by retinitis pigmentosa and bilateral sensorineural hearing loss or deafness. It is the most frequent cause of deaf-blindness. Based on clinical findings, three types of Usher syndrome were described (Van Aarem et al, 1995). The sensorineural hearing loss is profound in type 1, and moderate in type 2 (Fishman et al 1983; Kimberling et al, 1989). A rare third type was also described with progressive hearing loss (Sankila et al, 1995). Seeliger et al. found that type 1 patients and control subjects had almost identical 33-Hz flicker implicit times, and the same was true for type 2 and classical retinitis pigmentosa patients (Seeliger et al, 2001).

2.1.6 Treatable RP types

Classical retinitis pigmentosa is not a treatable disease. However, there are some forms of treatable retinitis pigmentosa associated with systemic involvement.

2.1.6.1 Abetalipoproteinemia

Abetalipoproteinemia or Bassen-Kornzweig syndrome is a hereditary disorder characterized by gastrointestinal symptoms (steatorrhea), haematologic disorders (acanthocytosis), neuromuscular disturbances (ataxia), and retinitis pigmentosa, all appearing in the first decade of life (Bishara et al, 1982). The first case was reported by Bassen and Kornzweig in 1950 in an 18 year-old girl who had generalized retinal degeneration, abnormal red blood cells and Freidreich ataxia (Lam, 2005). The disease is recessively inherited.

The early appearance of the retinal disease differs from the isolated retinitis pigmentosa, which usually appears during the second or third decade. The pathologic process is caused by a rare inborn error of lipoprotein metabolism (Runge et al, 1986). The primary defect appears to be an inability to secrete apolipoprotein B-100 which is a major protein of very low density lipoproteins and low density lipoproteins and an inability to secrete apolipoprotein B-48 which is a major protein of intestinal chylomicrons (Berson, 1987). Thus, the impairment in the production of chylomicrons causes the impairment in the fat absorption which in turn causes the impairment in the absorption of fat soluble vitamins, such as vitamin A, vitamin E, and vitamin K. Serum levels of cholesterol and triglyceride in abetalipoproteinemia are extremely low. The treatment consists of low-fat diet and oral vitamin A and vitamin E supplementation.

Studies showed that vitamin A supplementation results in a return of dark adaptation thresholds and ERG responses to normal in the early stages (Gouras et al, 1971). Bishara et al. reported that vitamin E also should be administered concomitantly with vitamin A (Bishara et al, 1982).

2.1.6.2 Refsum disease

Refsum disease was first described by Refsum in two consanguineous families. This syndrome was originally termed as *heredopathia ataxia polyneuritiformis*, and more recently *phytanic acid storage disease*. It is an autosomal recessive disorder characterized by peripheral neuropathy, ataxia and, retinitis pigmentosa (Refsum, 1981). Some of the patients have anosmia and neurogenic hearing loss. The metabolic defect is an inability in the conversion of phytanic acid to alpha-hydroxy-phytanic acid. Exogenous phytanic acid accumulates in a variety of tissues including the retinal pigment epithelium which causes impairment in the night vision (Avigan et al, 1966; Eldjarn et al, 1966). Visual field impairment generally begins until 20s before the onset of neurologic involvement. The fundus can be granular with areas of depigmentation around the periphery with a subnormal ERG in the early stages. In the more advanced stages, ERG may even be nondetectable (Berson, 1976, 1981).

The treatment is based on restricting dietary phytanic acid in order to reduce serum phytanic acid levels. Refsum has reported the beneficial effect of lowering serum phytanic acid levels in two patients who showed improvement in motor-nerve conduction velocity, some relief of ataxia, at least stabilizing the progression of retinitis pigmentosa. Similarly, Berson et al. reported the stabilizing effect of low phytanic acid diet in ERG (Berson, 1987).

2.1.7 Enhanced S-cone syndrome

In 1990, Marmor et al. reported eight patients who had night blindness, maculopathy, degenerative changes in the region of the vascular arcades, relatively mild visual field loss,

and an unusual but characteristic electroretinogram (Marmor et al, 1990). Conventional dark adaptation curves showed a normal initial cone limb, but little or no rod adaptation beyond the cone threshold. The dark-adapted ERG shows no response to low-stimuli that normally activate rods. With high-intensity stimuli that normally activate both rods and cones, the dark-adapted ERG demonstrates large, slow responses. The light-adapted ERG flash cone response also shows similar large, slow waveforms that are nearly identical to those elicited by scotopic high-intensity stimuli (Miyake, 2005) (Figure 7). The ERG responses to stimuli of increasing intensity show several unique characteristics with a large broad a-wave that remains almost constant with respect to b-wave timing under both photopic and, scotopic conditions. Normal scotopic responses show a decrease in b-wave implicit time with increasing stimulus intensity (Marmor et al, 1990). These characteristic ERG responses were found to be related to a larger than usual number of S-cones that apparently replace other cones (Jacobson et al, 1991). For this reason, this condition was termed as "enhanced S-cone syndrome". Abnormalities in the gene NR2E3 are associated with this syndrome in mouse and in man (Haider et al, 2000). The cones develop abnormally at the stage of cellular differentiation when the visual pigment is specified (Weleber, 2002).

The ERG pattern of increased S-cone sensitivity is not unique to enhanced S-cone syndrome but is also found in Goldman-Favre syndrome.

2.1.8 Goldman-Favre syndrome

The Goldman-Favre syndrome is an autosomal recessive disorder characterized by early onset night blindness, atypical peripheral pigmentary degeneration, degenerative changes of the vitreous humor, peripheral and less often central retinoschisis, macular cystic degeneration and, posterior subcapsular lens opacities (Fishman, 2001). Jacobson et al showed that the predominant ERG response was originated mainly from the short-wavelength sensitive cones (Jacobson et al, 1991). This feature of Goldman-Favre syndrome is similar to enhanced S-cone syndrome.

2.2 Cone dystrophies and cone-rod dystrophies

Cone dystrophies and cone-rod dystrophies constitute a major subgroup of hereditary retinal disorders. Cone dystrophies are characterized by impaired central vision and abnormal cone responses in ERG. However, rod-cone dystrophies refer to retinitis pigmentosa, that is, the rod function impairs before the cone function. In contrast, in cone-rod dystrophies, cone functions are impaired in advance to rod functions and rod functions is less severely affected than cone functions (Berson et al, 1968; Moore, 1992). The diagnosis of cone dystrophies and cone-rod dystrophies is mainly based on ERG which shows abnormal cone responses.

The most common symptoms of cone dystrophies include photophobia, loss of visual acuity, color vision and central visual fields. Most patients have dark-to-light adaptation problems (Goodman et al, 1963). "Urban night blindness" is a frequent finding in patients with cone dystrophies. Patients with cone dystrophy who settle in cities cannot see well in the semilighted urban areas, because cone functions are impaired and the semilighted conditions are not dark enough to adapt the rods. Sometimes, patients may have nystagmus. The most frequent fundoscopic finding is the atrophic appearing lesion in the macula. A bull's eye maculopathy may be present. However, in some patients, macula may show only minimal changes or nonspecific mottling of the RPE (Heckenlively, 2006).

In cone-rod dystrophies, diminished visual acuity and loss of color discrimination precedes nyctalopia and progressive visual field loss (Gregory-Evans et al 2000). Autosomal dominant, autosomal recessive and X-linked recessive patterns of inheritance have been described for both cone dystrophy and cone-rod dystrophy (Simunovic, 1998).

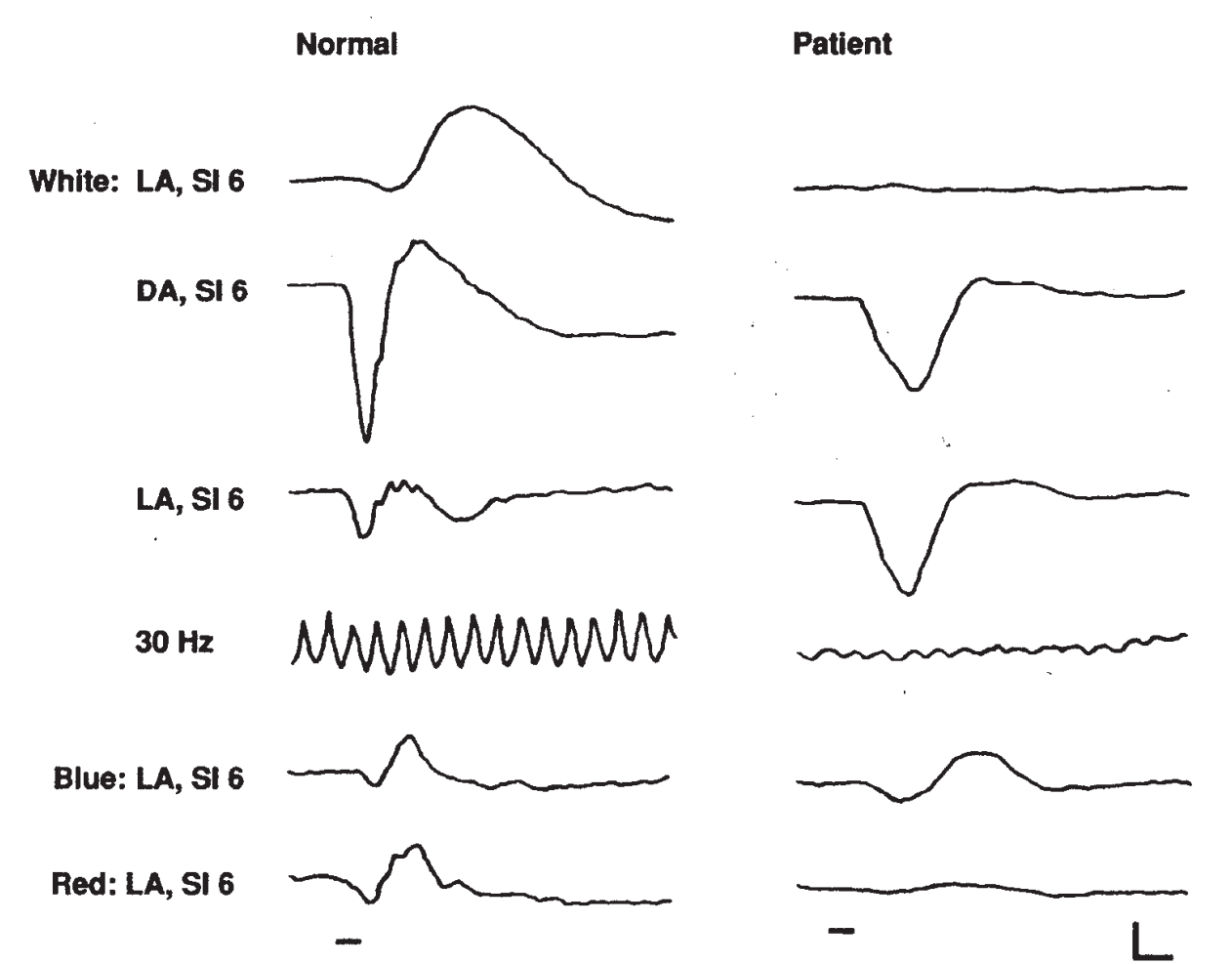


Fig. 7. Full-field electroretinogram in response to white and color stimuli of a normal person and patient with enhanced S-cone syndrome. In the patient, responses at dark and light adaptation are similar, the 30-Hz flicker response is reduced, and responses to blue stimuli are larger than to red. B-wave implicit times are markedly delayed at all stimulus conditions in the patient (DA: dark adaptation, LA: light adaptation, SI: stimulus intensity) (Used with permission of Pergamon Press Ltd. From. Enhanced S cone sensitivity syndrome: long-term follow-up, electrophysiological and psychophysical findings. Clinical Vision Sciences, Vol 8, Number 5, Kellner et al, 1993, permission conveyed through Copyright Clearance Center, Inc).

2.2.1 Cone dystrophy with negative photopic electroretinogram

Kellner and Foerster reported three patients with cone dystrophy who had negative photopic electroretinogram (Kellner & Foerster, 1993). This finding showed that at least in a subset of patients with cone dystrophy, additional inner retinal transmission defect may be present. The differential diagnosis of this condition from incomplete CSNB and X-linked retinoschisis may be performed with dark adaptation testing and fundoscopic examinations.

2.2.2 Cone dystrophy with Mizuo-Nakamura phenomenon

Heckenlively and Weleber described a new X-linked recessive cone dystrophy in which patients have a greenish-golden tapetal-like sheen of the retina (Heckenlively & Weleber, 1986). The authors reported that tapetal-like sheen disappeared after three hours of dark adaptation from greenish-golden shades to orange-red hues. This phenomenon (Mizuo-Nakamura phenomenon) was first described in patients with Oguchi disease. However, distinct electroretinographic and clinical features of Oguchi disease easily differentiates both diseases.

2.2.3 Rod monochromatism

Congenital achromatopsia often called achromatopsia is a rare *non-progressive* cone dysfunction with an autosomal recessive or X-linked recessive inheritance pattern. It can be divided into complete (no functioning cones) and, incomplete (some functioning cones) forms. Complete rod monochromatism has a severe course and, adults have 20/200 visual acuity and no color vision, while the incomplete rod monochromatism is less severe, and adults have 20/50 to 20/200 acuity with abnormal color vision (Moskowitz et al, 2009; Godel et al, 1976; Auerbach et al, 1970). Patients generally complain of photophobia and frequently have nystagmus that usually improves with age. The patients may have blond fundi and, this finding may cause misdiagnosis as ocular albinism. ERG helps distinguish ocular albinism from rod monochromatism which causes a typically diminished ERG response (Heckenlively, 2006).

2.2.4 Blue-cone monochromatism

Normal trichromatic color vision is possible only in the presence of normal functioning blue, green and red cones in the retina. Blue visual pigment is coded by a gene on chromosome 7 (Nathans et al, 1986a), while the green and red visual pigments are coded by highly homologous red and green pigment genes located on the X chromosome (Nathans et al, 1986b).

Blue cone monochromatism is an X-chromosome linked incomplete achromatopsia characterized by the absence of red and green cone function. For this reason, all the color vision is processed by only the blue cones (Ladekjaer-Mikkelsen, 1996). Patients may not discriminate different wavelengths and, but only light intensity. Unlike rod monochromats, blue cone function is selectively preserved. However, ERG responses of blue cone monochromats are similar to those of complete achromats, because blue cones contribute only negligibly to ERG.

2.2.5 Congenital red-green color deficiency

Congenital red-green color deficiency has been routinely diagnosed by psychophysical examinations. The standard ERG responses were reported to be normal under both scotopic and photopic conditions (Fishman, 2001). Figure 8 shows typical examples of the averaged waveform of 40 responses to monochromatic stimuli. The ERG amplitude in a normal subject is maximal around 550 nm, while the maximal amplitude is obtained at 520 to 530 nm in a protane and at around 550 nm in a deutan. The amplitudes are smaller than normal at long wavelengths in the protan subject and larger than normal at long wavelengths in the deutan subject (Nakazato et al, 1986) (Figure 8).

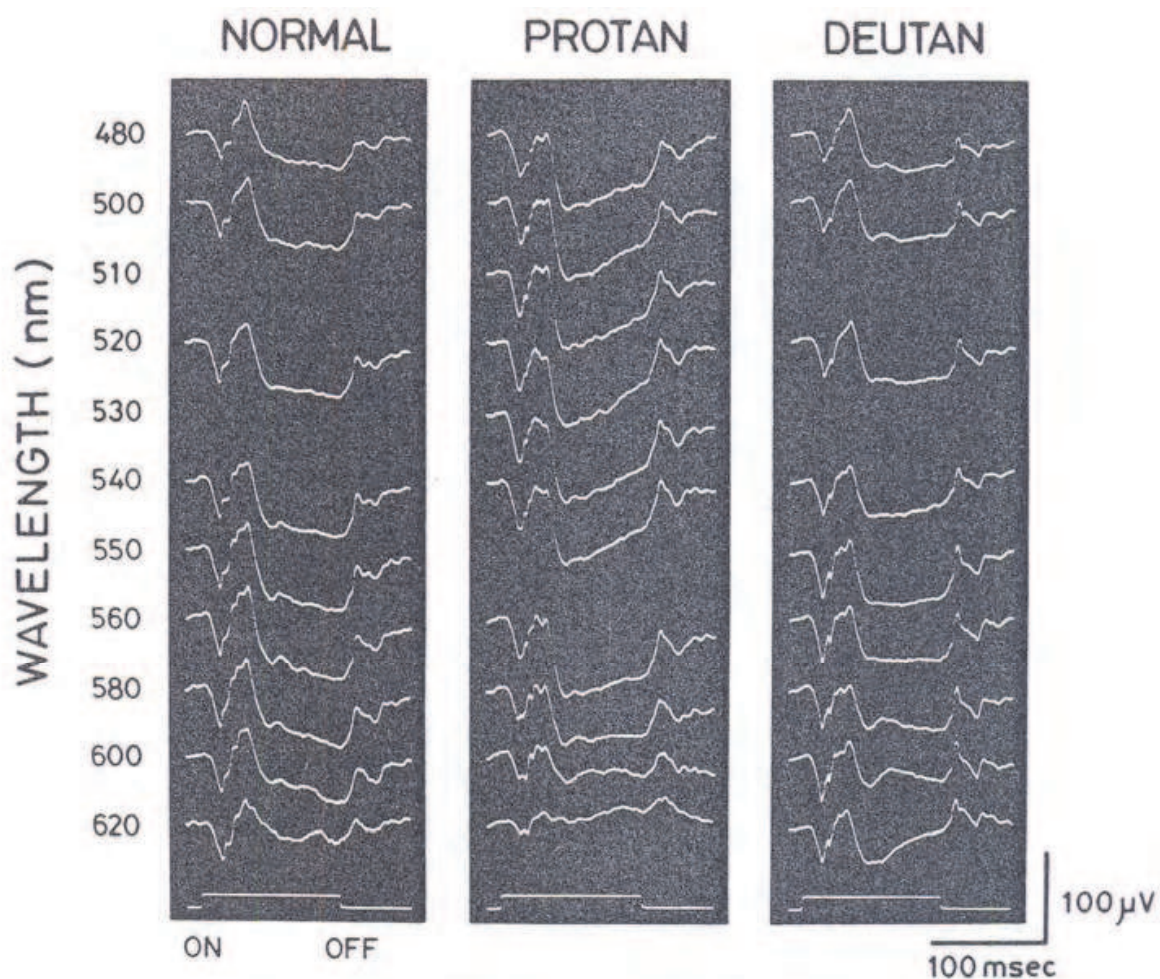


Fig. 8. Typical waveforms in normal subjects, protanopes and deuteranopes (Used with permission of Springer: Documenta Ophthalmologica, Vol 63, Number 2, Nakazato et al, Electroretinographic off-response in congenital red-green color deficiency and its genetic carrier, 1986, permission conveyed through Copyright Clearance Center, Inc).

2.2.6 Cone dystrophy with supernormal rod ERG

Cone dystrophy with supernormal rod electroretinogram was first described in 1983 (Gouras et al, 1983). This autosomal recessively inherited retinal dystrophy is characterized by reduced visual acuity, abnormal color vision, discrete macular changes, and specific alterations of ERG responses. ERG recordings typically show reduced and delayed cone responses, a reduction and marked delay of rod b-waves at low light intensities but elevated rod b-wave amplitudes at higher light intensities (Wissinger et al, 2008). The fundus appearance may be normal at the early stages, however in late stages there may be pigmentary disturbance at the macula and macular atrophy (Robson et al, 2010). This dystrophy was shown to be caused by mutations in *KCNV2* gene (Wu et al, 2006; Thiagalingam et al, 2007; Ben Salah et al, 2008), which encodes a subunit of a voltage-gated potassium channel expressed in both rod and cone photoreceptors (Wu et al, 2006). It was speculated that the rapid increase in b-wave amplitude over a short range of stimulus intensity may result from a "gated" mechanism, occurring only after an abnormally high threshold has been exceeded, enabling channel activation and ERG b-wave generation.

Robson et al. reported that the ERG to the bright-flash showed a broadened and delayed a-wave through with a rhomboid-like shape (Robson et al, 2010). Figure 9 shows a cone dystrophy patient with supernormal rod electroretinogram (Gundogan et al, 2011).

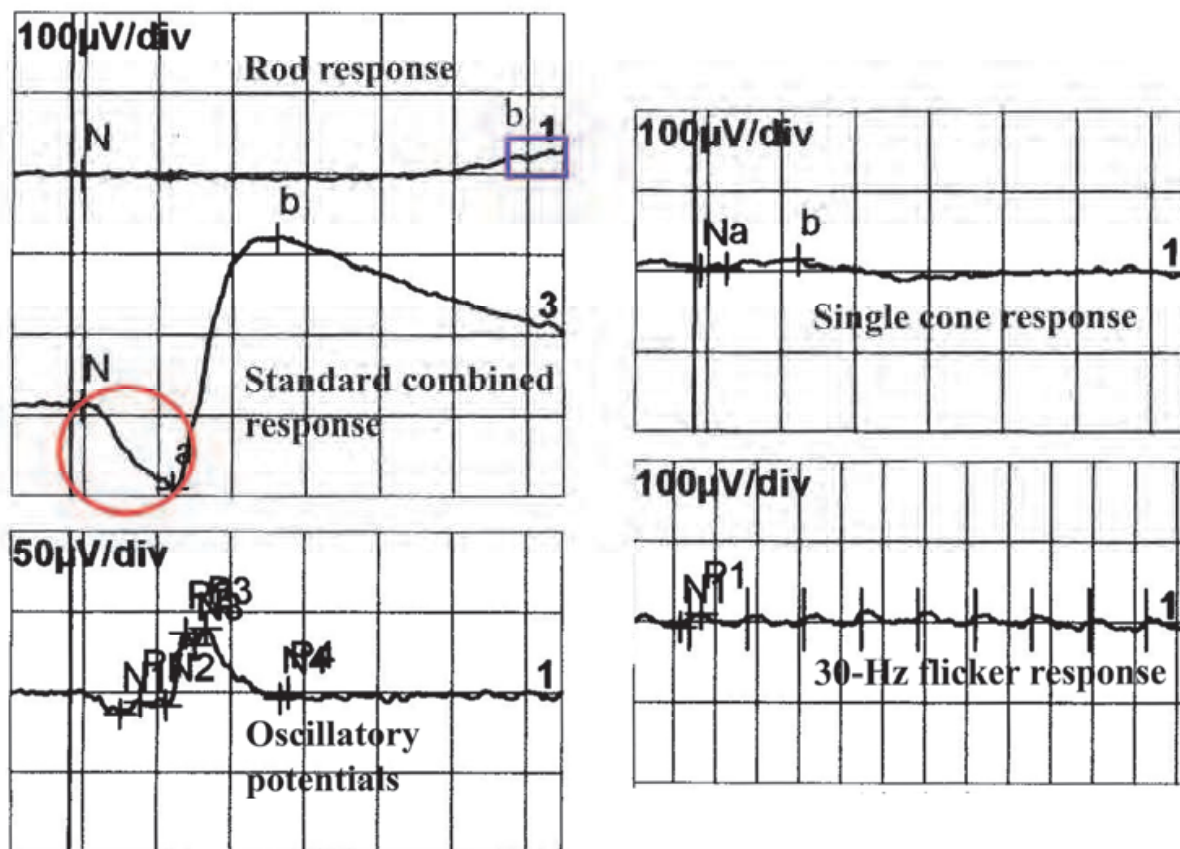


Fig. 9. Full-field electroretinogram with very delayed rod response, a rhomboid a-wave and supernormal b-wave in bright-flash rod-cone response and very reduced cone responses in a patient with KCNV2 mutation (Used with permission of Journal of Retina-Vitreus, 2011).

2.3 Juvenile X-linked retinoschisis

Juvenile X-linked retinoschisis is a hereditary vitreoretinal dystrophy that is the most common cause of macular degeneration in young males (The retinoschisis consortium, 1998). The disease affects 1/5000 to 1/25000 males worldwide and is one of the most common causes of juvenile macular degeneration in boys (George et al, 1995). The disease is thought to be a disorder of the retinal development in the intrauterine life. However visual loss is not recognized until preschool years (Eksandh et al, 2005). The disease is caused by mutations in the RS1 gene (Sauer et al, 1997; The retinoschisis consortium, 1998). Retinoschisin, encoded by RS1 gene, is a protein implicated in cell adhesion and signaling which maintains structural and functional integrity of the retina (Wu et al, 2005).

The disease manifests with cystic changes in the macula causing visual acuity loss. Most of the children are referred to the ophthalmologist because of a failure in school vision tests (Kjellström et al, 2010). The visual acuity loss progresses during the first two decades of life. There is slow progression of severity into the fifth and sixth decades. After the age of 50,

patients generally have a fundoscopic appearance of macular pigmentary changes and/or retinal pigment epithelium atrophy.

The defect in the production of retinoschisin causes lamellar splitting of the retina both in the nerve fiber layer and deeper in the retina. The retinal schisis most commonly occurs in the infero-temporal retina (Eksandh et al, 2000). Recent development of optical coherence tomography increased the clinical sensitivity for detection of retinal splitting (Gerth et al, 2008).

2.3.1 ERG in juvenile X-linked retinoschisis

The characteristic ERG in X-linked retinitis pigmentosa is a reduction in the scotopic b-wave amplitude. The b/a amplitude ratio is typically decreased, when it is below 1.0, a negative ERG pattern is found. However, normal b/a amplitude ratios were reported in the very early stages of the disease (Eksandh et al, 2005) (Figure 10). Therefore, a normal ERG does not absolutely exclude the diagnosis of X-linked retinoschisis.

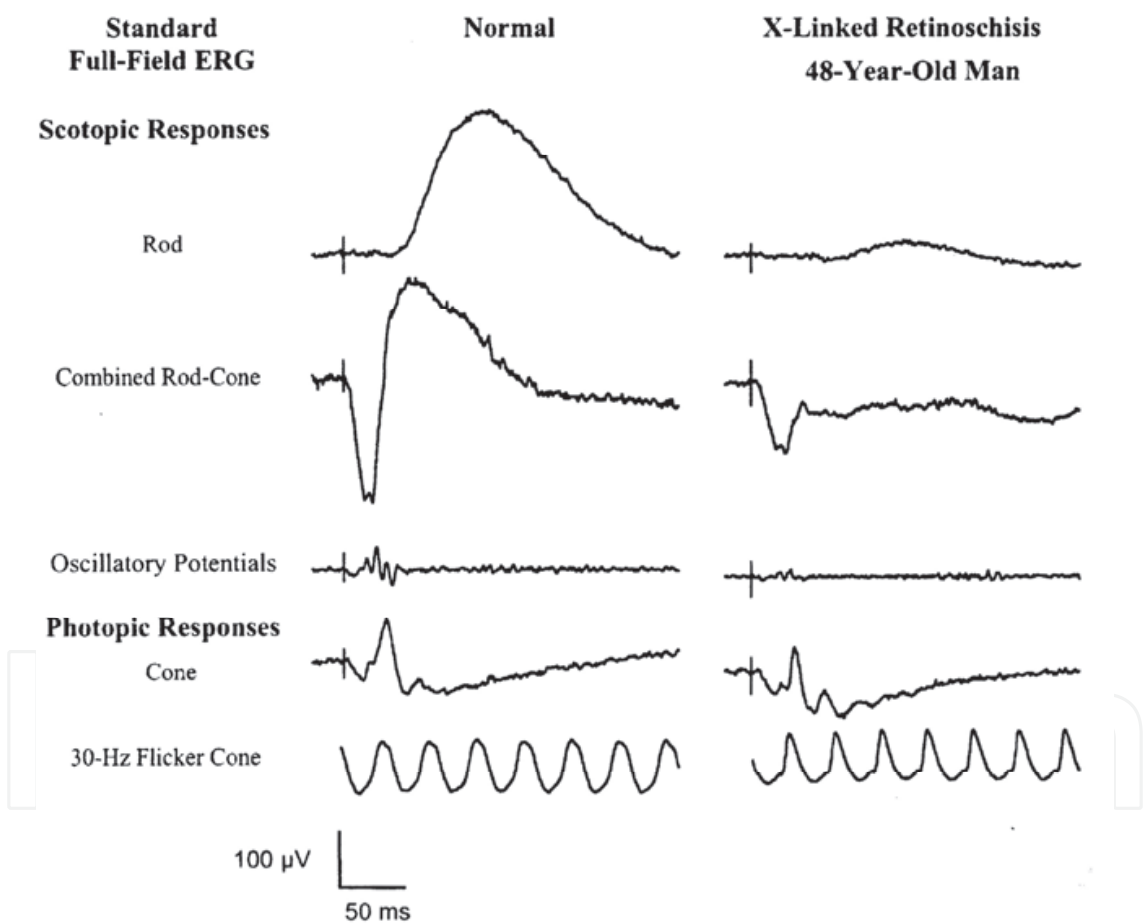


Fig. 10. Reduced and prolonged rod response and negative b-wave in X-linked retinoschisis (Used with permission of Taylor & Francis. From: Electrophysiology of Vision, ISBN: 0-8247-4068-8, Bryan Lam, 2005, permission conveyed through Copyright Clearance Center, Inc).

2.3.2 MfERG in X-linked juvenile retinoschisis

mfERG responses are more impaired in the central than peripheral retina in X-linked retinoschisis. In one study, mfERG measured at the follow-up demonstrated locally

subnormal cone function in the macular region in all patients, and significantly delayed implicit time in all ring areas compared with normal controls (Kjellström et al, 2010). Carriers of X-linked retinoschisis were also reported to have retinal dysfunction by mfERG in the presence of normal-appearing fundus (Kim et al, 2007).

2.4 Congenital stationary night blindness

Hereditary retinal disorders may be stationary or relatively mildly progressive rather than dystrophies with progressive degeneration. Among the stationary disorders, the ERG is an important diagnostic test particularly for congenital stationary night blindness and rod monochromatism. Stationary night blindness disorders may be classified as congenital stationary night blindness (CSNB), fundus albipunctatus, Oguchi disease and fleck retina of Kandori. Stationary cone dysfunction disorders may be classified as hereditary congenital color vision deficiencies, rod monochromatism and blue cone monochromatism (Lam, 2005). Stationary cone dysfunction disorders were mentioned under the title of cone dystrophies in this chapter.

Congenital stationary night blindness is the symptom of a group of hereditary retinal disorders characterized by *non-progressive* night-vision loss present since birth. Other ocular symptoms, such as nystagmus, decreased visual acuity, myopia and hyperopia are generally present (Weleber, 2002; Wutz et al, 2002; Zeitz et al, 2005). The prevalence of CSNB is approximately 1 in 10000 (Rosner et al, 1993). The classification of CSNB is based on both fundus appearance and, hereditary pattern. Some patients have *normal-appearing fundus*, others have some *distinctive fundus abnormalities* (Carr, 1974). Patients with a normal-appearing fundus and CSNB may have an autosomal dominant, autosomal recessive or X-linked recessive inheritance pattern. ERG is the key diagnostic test with distinct findings in CSNB.

2.4.1 Schubert-Bornschein type of CSNB

Schubert-Bornschein type of CSNB is characterized by a negative ERG response, that is, the amplitude of the b-wave is smaller than the amplitude of a-wave, causing a b-wave to a-wave amplitude ratio smaller than one (Figure 11). In general, this type of the disease has an autosomal recessive or, X-linked recessive pattern. However, autosomal dominant pedigrees were also reported (Hayakawa et al, 1992; Noble et al, 1990).

In 1986, Miyake studied on patients with X-linked Schubert-Bornschein type CSNB (Miyake, 1986). The author realized that the patients may be classified into two groups as complete and incomplete CSNB with respect to rod function in ERG and subjective dark adaptation testing. The patients with complete type CSNB (or CSNB1) lacks rod function, while the patients with incomplete type CSNB (or CSNB2) have residual rod function. Studies after the discovery of both types of CSNB have documented that both forms are originated from different mutations. Further studies on complete and incomplete type CSNB showed that the two types also differ with respect to cone ERG, long-flash photopic ERG (Miyake et al, 1987; Quigley et al, 1996) and scotopic threshold response (Miyake et al, 1994).

2.4.2 Riggs type CSNB

Riggs type CSNB was first described by Riggs in 1956. The author reported three CSNB patients with detectable, but markedly impaired dark-adaptation (Riggs, 1954). ERG responses of the patients showed reduced b-wave amplitude which was still greater than a-

wave amplitude. The b-wave to a-wave amplitude ratios were greater than 1, but still under normal data. Auerbach et al. reported the ERG results of 95 CSNB patients. Fifty-nine of the patients had Schubert-Bornschein type CSNB and 36 patients had Riggs type CSNB (Auerbach et al, 1969). The authors also reported that myopia and nystagmus were less common in Riggs type CSNB patients than Schubert-Bornschein type patients. Riggs type CSNB is inherited as X-linked or autosomal recessively.

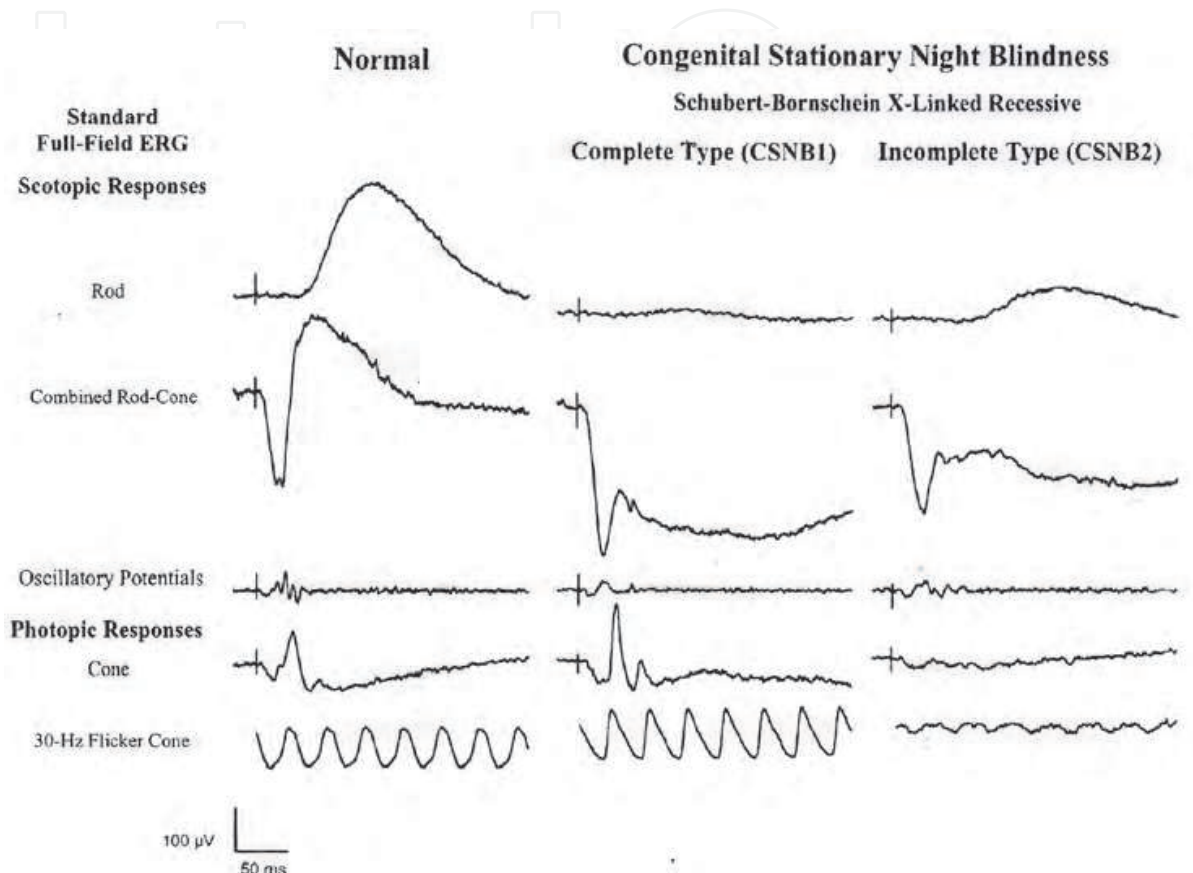


Fig. 11. Complete and incomplete types of X-linked recessively inherited Schubert-Bornschein congenital stationary night blindness. In both types, b/a ratio is below 1.0, however, incomplete type has residual rod function in contrast to complete type (Used with permission of Taylor & Francis. From: *Electrophysiology of Vision*, ISBN: 0-8247-4068-8, Bryan Lam, 2005, permission conveyed through Copyright Clearance Center, Inc).

2.4.3 Nougaret type CSNB

The first autosomal dominant type of CSNB, Nougaret type, derives its name from the first described patient, Jean Nougaret. Sandberg et al. reported non-detectable scotopic ERG response in a father and son with Nougaret CSNB (Sandberg et al, 1998). The scotopic white bright-flash combined rod-cone responses demonstrated decreased biphasic a-wave with a b-wave amplitude that was positive and at least 50% of normal indicating that the loss of rod function was not complete. The cone responses were only slightly impaired (Lam, 2005). One another autosomal dominant CSNB pedigree was reported by Rambusch in 1909 in a Danish family (Rosenberg et al, 1991). ERG responses in the Rambusch pedigree are similar to those of Nougaret CSNB and resemble the ERG responses of the Riggs CSNB type (Lam, 2005).

2.4.4 Fundus albipunctatus

Fundus albipunctatus is a type of congenital stationary night blindness with an autosomal recessive inheritance pattern. The typical clinical findings include multiple whitish yellow spots at the level of RPE with the exception of the macula, which tend to be scattered as an annulus around the macula. The fundoscopic appearance of the optic disc and retinal vessels are normal and there is no evidence of peripheral clumping of retinal pigment. Fundus albipunctatus is caused by mutations in the RDH5 gene, which encodes for the 11-cis retinal dehydrogenase of the retinal pigment epithelium (Nakamura & Miyake 2002; Nakamura et al, 2003).

The typical pathology is the delayed regeneration of the rod visual pigment. This results in reduced rod responses in ERG, which begin to recover around 30 minutes of dark adaptation and normalizes after 2-3 hours (Carr et al, 1974). Similar to rod responses, delays in the cone visual pigment regeneration was also demonstrated (Petzold & Gordon, 2006).

2.4.5 Oguchi disease

Oguchi disease is a distinct entity under CSNB with characteristic electroretinographic and clinical properties. The disease was first described by Oguchi in 1912. The night vision impairment is typically non-progressive. Typically, dark adaptation is 8-10 times slower than normal (Carr & Ripps, 1967; Cideciyan et al, 1998). Characteristically, fundus has a metallic, phosphorescent-like sheen which disappears after prolonged dark adaptation. This is called Mizuo phenomenon with respect to the author by which this condition was first described in 1913. Scotopic ERG responses were reported to be diminished in amplitude. Photopic ERG responses are normal which gives clue to differentiate Oguchi disease from complete CSNB (Miyake et al, 1996).

2.4.6 Fleck retina of Kandori

Fleck retina of Kandori is an autosomal recessively inherited retinal dystrophy characterized by relatively large yellow irregular shaped flecks in the peripheral retina, minimal dark adaptation abnormality, and normal visual field (Fishman, 2001). ERG responses show a negative pattern suggesting functional impairment within the proximal retina (Kandori et al, 1966).

2.5 Hereditary macular disorders

2.5.1 Stargardt macular dystrophy and fundus flavimaculatus

Stargardt disease which is the first described juvenile-onset hereditary macular degeneration was first defined by the German ophthalmologist Karl Stargardt in 1909, is a familial, progressive, bilateral, and symmetric macular disease leading to partial or complete loss of central vision (Itabashi et al, 1993). All seven patients reported by Stargardt were restricted to one generation suggesting an autosomal recessive inheritance pattern (Aaberg, 1986). The frequently cited incidence of stargardt disease is 1 in 10,000. The typical clinical features of the disease is characterized by the onset of decreased visual acuity, most frequently noted within the first two decades of life, often accompanied by an atrophic-appearing lesion of the macula and a varying degree of yellow-white linear, round, stellate, or pisciform (fishtail) shaped "flecks" at the level of the retinal pigment epithelium (Fishman, 1991). In the 1970s, and 1980s, diffuse blockage of choroidal filling on fluorescein angiography, the so-called 'choroidal silence' or 'dark choroids,' due in part to the accumulation of lipofuscin-like material in the retinal pigment epithelium were recognized

as a feature of Stargardt macular dystrophy. The retinal fleck-like lesions was noted to correspond to hypertrophic retinal pigment epithelial cells with extensive accumulation of lipofuscin-like material (Eagle et al, 1980; Fish et al, 1981).

Later, in 1962, Franceschetti described an autosomal recessively inherited retinal dystrophy characterized with subretinal yellow flecks, which were associated, in 50% of the cases, with macular changes to those seen in Stargardt disease. The author named this condition "fundus flavimaculatus" (Franceschetti, 1965; Franceschetti et al, 1965). However, as Franceschetti recognized, if the flecks are localized at the posterior pole with macular involvement it becomes almost impossible to clinically distinguish fundus flavimaculatus from Stargardt disease. These similar findings caused the investigators to suggest that stargardt macular disease and fundus flavimaculatus reflects the same disease process. For this reason, Deutman suggested the eponym "Stargardt flavimaculatus" as a more accurate identification (Lachapelle et al 1990). The attempts to classify patients into two distinct genetic disorders based on retinal appearance alone was not successful because of overlapping clinical and genetic findings between Stargardt macular dystrophy and fundus flavimaculatus.

In general, ERG rod and cone responses in patients with stargardt macular dystrophy are in the normal range, however, are variable among patients and may demonstrate impaired cone responses as well as impaired rod and cone responses especially in those with more widespread retinal atrophy and fleck-like lesions. In addition, some investigators found prolonged dark adaptation in patients with Stargardt macular dystrophy (Figure 12). For this reason, at least 45-min dark adaptation is suggested before ERG recordings (Fishman et al, 1991).

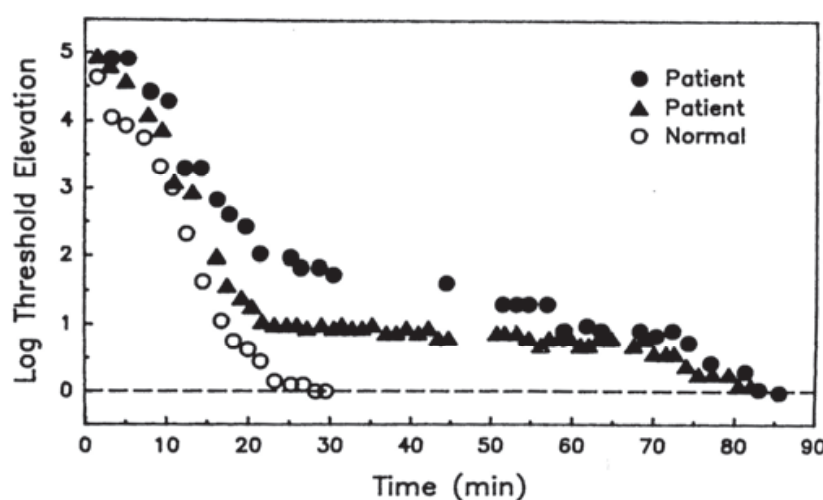


Fig. 12. Dark adaptation curves from a normal subject and two patients with Stargardt macular dystrophy. The initial portions of the slopes are similar, while the latter portion of the dark adaptation curve is prolonged in the patients (Used with permission of Elsevier Inc. From , 'Delayed rod dark adaptation in patients with Stargardt's disease', Fishman et al, Ophthalmology, Volume 98, Number 6, 1991; permission conveyed through Copyright Clearance Center, Inc)

PERG responses are typically diminished regardless of visual acuity (Lois et al, 2001). This striking PERG finding is rather unusual in other macular dystrophies. Multifocal ERGs show markedly diminished or non-detectable foveal response in almost all patients even in those with good visual acuity (Kretschmann et al, 1998) (Figure 13).

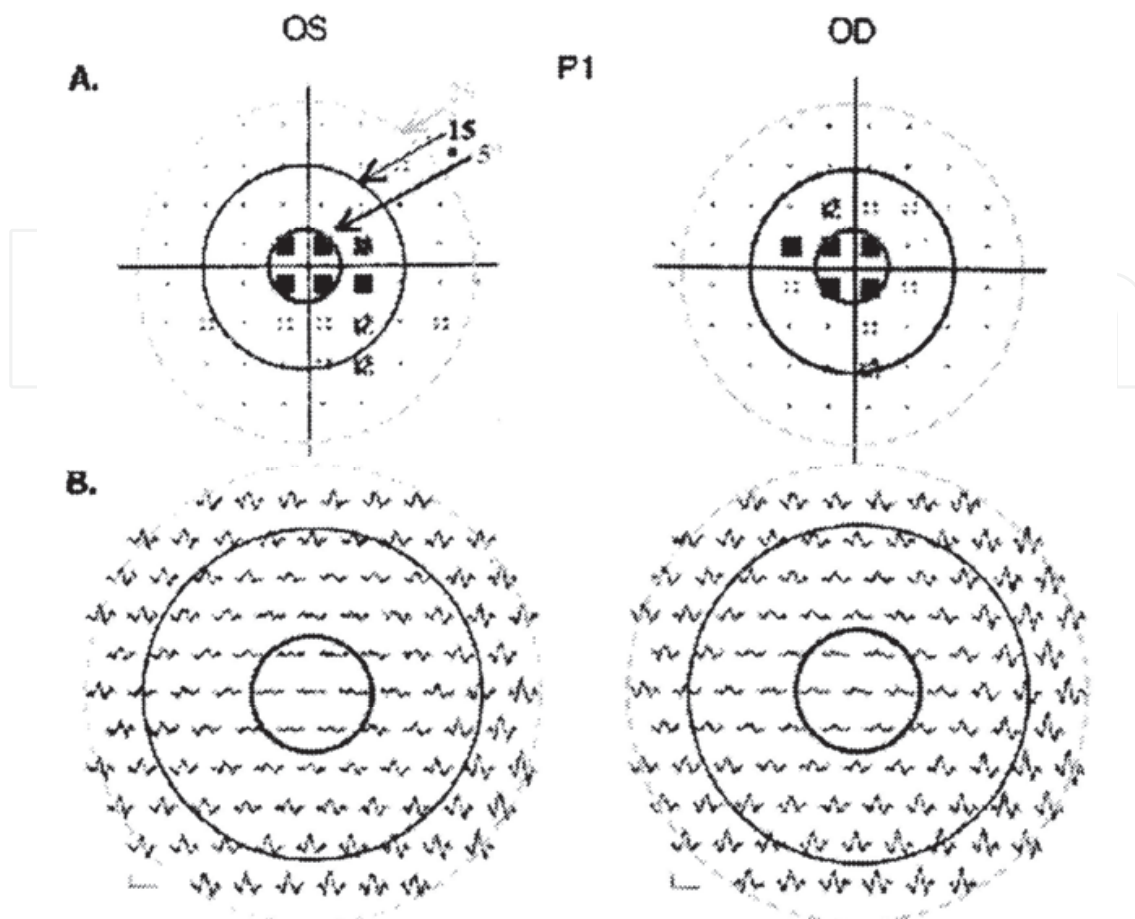


Fig. 13. Humphrey visual fields in Stargardt disease (A). Multifocal electroretinogram responses show reduced central amplitudes, but relatively unchanged implicit times, typical of early Stargardt disease (Used with permission of Wolters Kluwer Health. From 'The multifocal electroretinogram', Hood et al, Journal of Neuro-ophthalmology, Volume 23, Number 3, 2003; permission conveyed through Copyright Clearance Center, Inc)

2.5.2 Best vitelliform macular dystrophy

Best vitelliform macular dystrophy is an autosomal dominant, juvenile-onset disorder characterized by an egg-yellow, slightly elevated macular lesion surrounded by a darker border (Deutman, 1971, 1989). Best disease is associated with a mutation in the VMD2 gene (Palmowski et al, 2003). The macular changes have been staged according to the severity of the macular lesion: previtelliform stage, vitelliform stage, pseudo-hypopyon stage, vitelliruptive stage and atrophic stage. The lesions reflect abnormalities in the retinal pigment epithelium (Weingeist et al, 1982). Histopathologic examinations revealed excessive amounts of lipofuscin accumulation in the retinal pigment epithelium throughout the fundus. Visual acuity is only mildly affected in the early stages of the disease, and is typically better than expected with respect to the appearance of the foveal lesion. However, as the disease progresses, visual acuity decreases parallel to the appearance of macular atrophy.

The functional impairment of retinal pigment epithelium leads to abnormal electro-oculogram which is the key diagnostic test of the disease. The ERG is typically normal in Best vitelliform macular dystrophy. Palmowski et al. studied mfERG responses in three

patients and reported normal implicit times and reduced amplitudes in the central 6 degrees (Palmowski et al, 2003). In contrast, Scholl et al. found decreased amplitudes and delayed implicit times in mfERG in 18 patients with Best vitelliform macular dystrophy (Scholl et al, 2002) (Figure 14, Figure 15). The authors also reported that central mfERG amplitudes were significantly correlated with visual acuity loss and fundoscopic staging.

These findings document the impaired central retinal function which may not be revealed with ERG in these patients.

In one study, the authors divided the patients into two groups according to visual acuities (Jarc-Vidmar et al, 2001). The authors reported normal PERG responses in patients with 0.5 or higher visual acuities and abnormal PERG responses in approximately half of the patients with lower visual acuities. In that study, progression of the disease as assessed by visual acuity decreases and visual field defects were well correlated with the reduction of both PERG P50 and N95 amplitudes. However, there was no correlation with the visual acuity and electro-oculogram which is the key diagnostic test of Best vitelliform macular dystrophy.

2.5.3 Pattern dystrophies

Pattern dystrophies are a group of dominantly inherited retinal disorders which primarily affects the retinal pigment epithelium in the macula. The fundoscopic appearance of the macular lesion is variable and includes butterfly patterns as well as knotted fishnet patterns. The visual prognosis is generally good with a mild disturbance of central vision typically ranging from 20/20 to 20/70 and, metamorphopsia. Pattern dystrophies are divided into morphological subtypes including butterfly dystrophy, fundus pulverulentus, multifocal pattern dystrophy resembling Stargardt disease, and adult-onset vitelliform macular dystrophy (Deutman & Rümke, 1969; Deutman et al, 1970; Hsieh et al, 1972; Slezak & Hommer, 1969). However, some individual patients may not be precisely categorized into one of these groups with respect to fundus abnormalities.

PERG is abnormal due to macular involvement. ERG is generally undisturbed. EOG light-rise to dark-through amplitude ratio is usually reduced but not always abnormal (Hsieh et al, 1972; Daniele et al, 1996; Kingham et al, 1978; Shiono et al, 1990; Watzke et al, 1982). Central retinal dysfunction can be detected by focal ERG or multifocal ERG.

2.5.4 North Carolina macular dystrophy

North Carolina macular dystrophy is an autosomal dominant inherited disease which causes congenital bilateral macular degenerations (Rabb et al, 1998). The disease was first described by Lefler et al in 1972 in the descendants of a large family who lived in the 1800s (Lefler et al, 1971). Lefler reported that ERGs, electro-oculograms and color vision tests were normal in the patients. Lefler named this disease as "dominant macular degeneration and aminoaciduria", however a few years later, Frank et al. showed that aminoaciduria in the cases of Lefler was in fact unrelated to dominant macular degeneration and named the condition as "dominant progressive foveal dystrophy" without evidence of the progression (Frank et al, 1974). Frank et al. also expanded the family history and found that all of the patients were descendants of three Irish brothers who settled in the North Carolina mountains in 1800s.

The fundoscopic findings range from a few yellow drusen-like lesions in the macula to macular colobomas. The disease is generally stable and the visual acuity ranges from 20/20 to 20/800 (Rabb et al, 1998). As the Lefler reported in the first cases, ERG responses are generally normal (Small et al, 1993; Lefler et al, 1971; Frank et al, 1974).

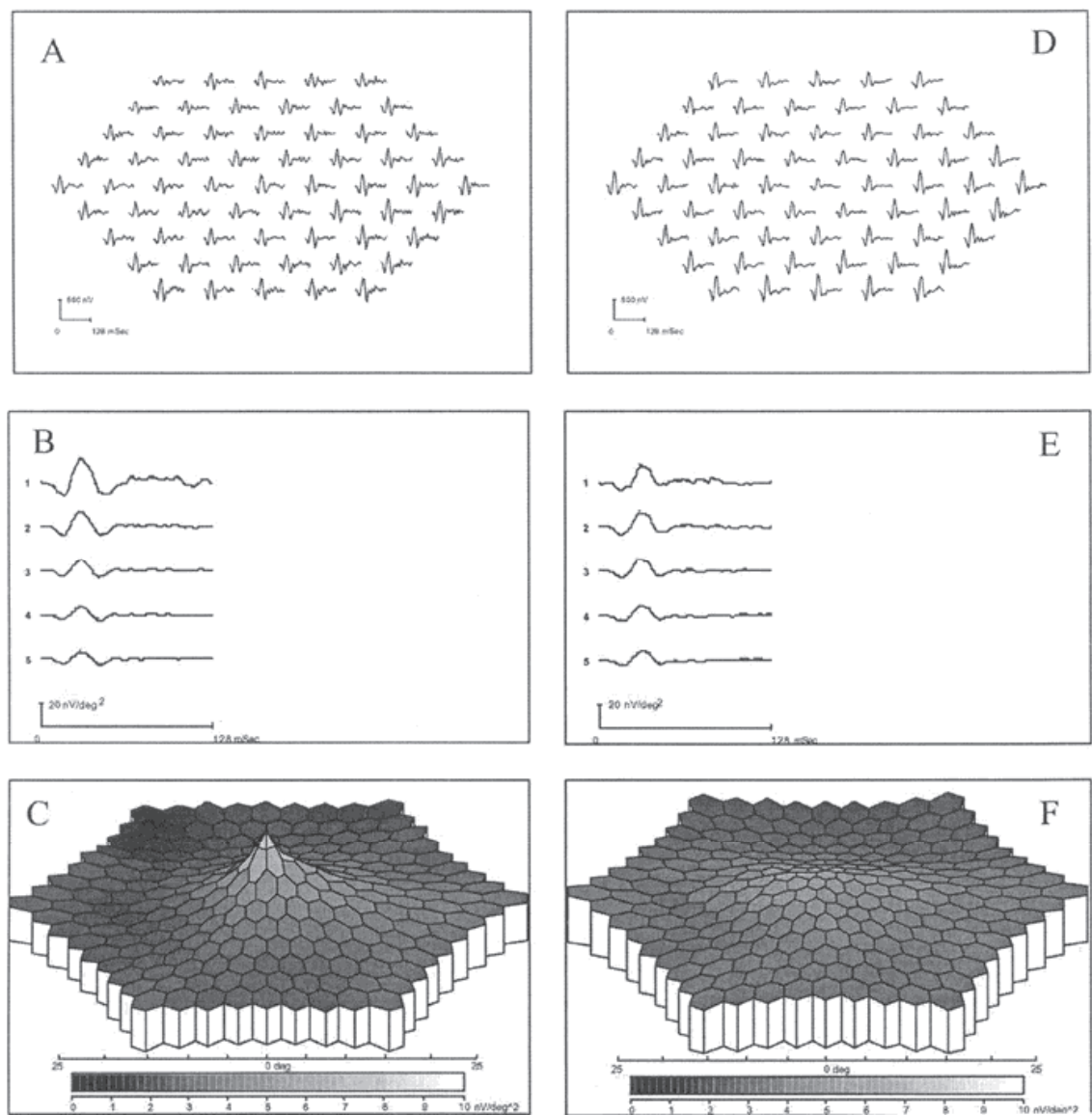


Fig. 14. Multifocal electroretinograms recorded from the left eye of one normal subject (A; representing the median for the central element within the control population of 55 subjects) and from the left eye of Best macular dystrophy patient (D; representing the median for the peak amplitude of the central element within the population of 18 Best macular dystrophy patient). The upper panel (A,D) shows the trace arrays with 61 mfERG waveforms. The patient has a visual acuity of 1.0, however, central peak amplitudes are markedly reduced (D). In the more concentric rings, the amplitudes are normal (E). The three dimensional plots of the response show markedly reduced amplitudes in the fovea (F) (Used with permission of Pergamon. From ,‘Mapping of retinal function in Best macular dystrophy using multifocal electroretinography’’, Scholl et al, Vision Research, Volume 42, Number 8, 2003; permission conveyed through Copyright Clearance Center, Inc)

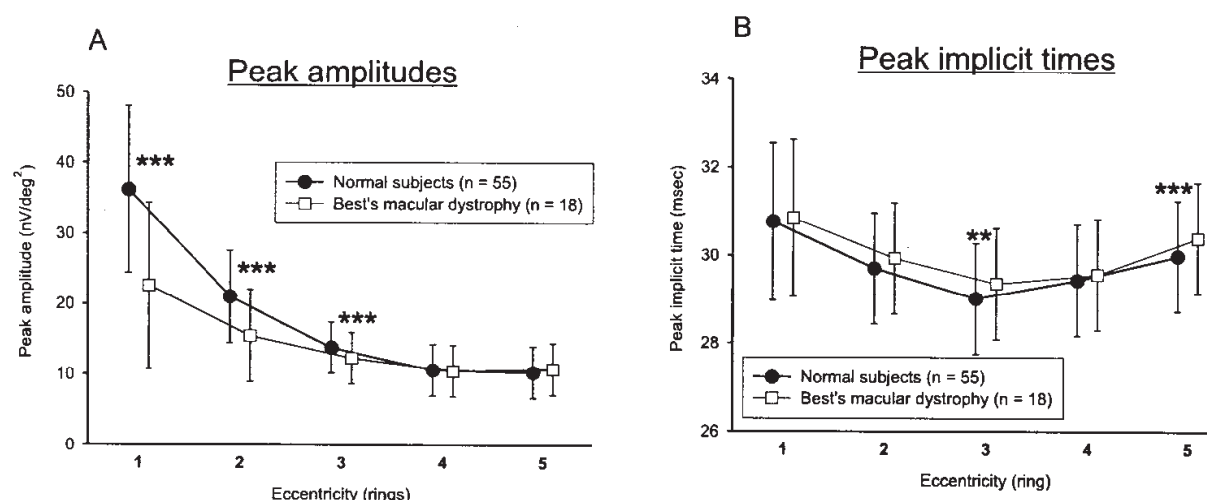


Fig. 15. Multifocal electroretinogram responses are significantly reduced in the central three rings and significantly delayed in the third and fifth rings in patients with Best macular dystrophy (Asterisks indicate significant differences. *** $p < 0.001$, ** $p < 0.01$) (Used with permission of Pergamon. From 'Mapping of retinal function in Best macular dystrophy using multifocal electroretinography', Scholl et al, Vision Research, Volume 42, Number 8, 2003; permission conveyed through Copyright Clearance Center, Inc).

2.5.5 Sorsby fundus dystrophy

Sorsby fundus dystrophy, first described by Sorsby and Mason in 1949, is a rare progressive, autosomal dominantly inherited retinal disease (Sivaprasad et al, 2008). Bilateral visual loss occurs generally in the adulthood (from the third to the seventh decade) due to subretinal neovascular membranes causing disciform scarring or chorioretinal atrophy at the macula (Sorsby & Mason, 1949). Night vision impairment may develop in some patients and may precede the development of visible fundus signs.

Both normal and reduced ERG responses were reported in Sorsby fundus dystrophy (Capon et al, 1988; Felbor U et al, 1996). However, Clarke et al. reported markedly abnormal PERG responses even in the presence of a small central island of vision (Clarke et al, 1997).

2.5.6 Central areolar choroidal dystrophy

Central areolar choroidal dystrophy, first described by Nettleship in 1884, is a macular dystrophy characterized by the development of fine, mottled, depigmented retinal pigment epithelium in the macula. After several decades the pathognomonic zone of circumscribed atrophy, affecting retina, retinal pigment epithelium and choriocapillaris, develops in the macular region of the eye (Carr, 1965; Hoyng & Deutman, 1996). Although, most cases are sporadic, autosomal dominant and recessive inheritance patterns have been reported (Nagasaka et al, 2003).

ERG responses are generally normal or subnormal in CACD. However, in some cases of central areolar choroidal dystrophy, generalized decrease in both scotopic and photopic ERG is found (Adachi-Usami et al, 1990; Carr, 1965; Noble, 1977). In a recent study, we have showed that mfERG responses were reduced corresponding to the areas of ophthalmoscopically visible lesion and there were significant correlations between foveal retinal sensitivity in the Humphrey visual field and mfERG P1/N1 amplitudes (Figure 16) (Gundogan et al, 2010).

2.5.7 Bietti's crystalline dystrophy

Bietti's crystalline dystrophy is characterized by tapetoretinal degeneration with small glistening crystals in the posterior pole. The first cases reported by Bietti in 1937 and 1942 also had corneal crystals (Richards et al, 1991). Later it was understood that paralimbal corneal crystals are found in only one third of the patients. For this reason, the disease are also named as "Bietti's corneal-retinal dystrophy". A study showed circulating crystals in the lymphocytes resembling cholesterol and cholesterol-ester crystals (Wilson et al, 1989). This finding suggested that Bietti's crystalline dystrophy may be due to a systemic abnormality of the lipid metabolism.

The ERG responses may be diminished or minimally abnormal due to the phenotypic heterogeneity of the disease (Fishman, 2001).

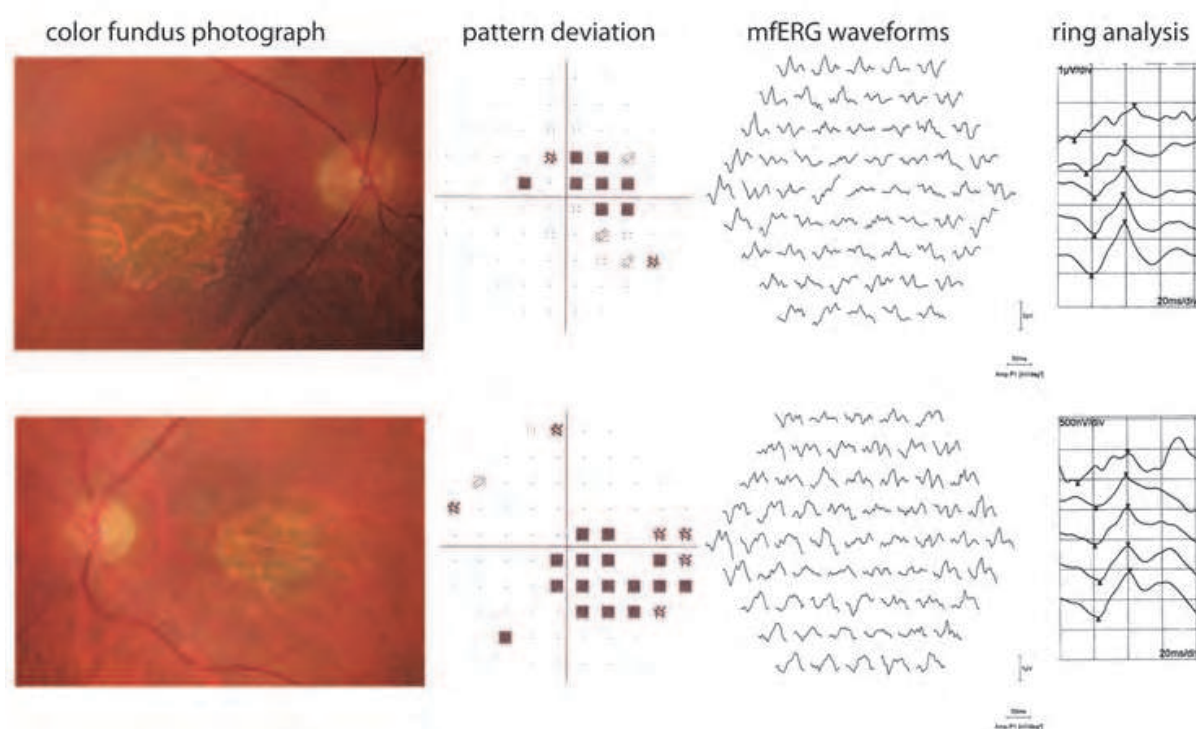


Fig. 16. Color fundus photographs, pattern deviation of Humphrey visual fields and multifocal electroretinogram results of a patient with central areolar choroidal dystrophy. Central responses are markedly reduced and delayed in multifocal electroretinogram (Used with permission of Wichtig Editore. From. 'Multifocal electroretinogram and central visual field testing in central areolar choroidal dystrophy', Gundogan et al, European Journal of Ophthalmology, Volume 20, Number 5, 2010).

2.6 Hereditary vitreoretinal disorders

Hereditary vitreoretinal disorders are a group of diseases with both retinal and vitreal involvement. Electrophysiologic responses typically reflect the degree of retinal involvement in this group of rare conditions.

2.6.1 Stickler syndrome

Stickler syndrome was first described in 1965 (Stickler et al, 1965). The syndrome is characterized by high myopia, premature vitreous syneresis, frequent retinal detachment

and premature degenerative changes of articular cartilage. This association of ocular and articular involvement caused to be termed as *hereditary progressive arthro-ophthalmopathy*. ERG responses are generally normal in Stickler syndrome, however, high myopia and retinal detachment may produce reduced amplitudes (Aylward et al, 2008).

2.6.2 Wagner syndrome

Wagner syndrome is a progressive autosomal dominant disorder characterized by vitreous changes including avascular strands and condensed bands, situs inversus of the retinal vessels and atrophic changes of the retinal pigment epithelium and choriocapillaris (Brown et al, 1995). ERG responses may be normal, however, may be reduced if the retinal and choroidal atrophy occurs (Hirose et al, 1973).

2.6.3 Familial exudative vitreoretinopathy

Familial exudative vitreoretinopathy is a rare autosomal dominant or X-linked hereditary pattern characterized by premature termination of retinal vessels in the peripheral temporal retina which causes the development of tractional fibrovascular masses. The clinical findings of familial exudative vitreoretinopathy are quite similar to premature retinopathy. ERG findings are correlated to the extent and severity of the retinal involvement (Ohkubo & Tamino, 1987; Van Nouhuys, 1982).

2.7 Hereditary chorioretinal dystrophies

Progressive chorioretinal dystrophies are a group of inherited diseases characterized by the progressive degenerations of the both retinal and choroidal layers. Choroideremia, gyrate atrophy and pigmented paravenous retinochoroidal atrophy are the three most common chorioretinal dystrophies.

2.7.1 Choroideremia

Choroideremia is a X-linked recessive dystrophy characterized by progressive atrophy of the photoreceptors, retinal pigment epithelium, and the choriocapillaris, leading to progressive visual loss (MacDonald et al, 2009). The disease is caused by mutations in the CHM gene, which encodes for the Rab escort protein 1 (REP-1) (Cremers et al, 1990). Night vision impairment and peripheral visual field loss is generally occurs during the first or second decade of life, however, central vision is affected in the late stages of the disease (Mukkamala et al, 2010). Night vision impairment usually progresses to tunnel vision or complete blindness by middle age. The retinas of female carriers are mosaics, containing patches of both mutant and normal cells. As a result of mosaicism, female carriers usually show patchy depigmentation of the retinal pigment epithelium, but can retain good visual function throughout life (Syed et al, 2001).

In the early stages of the disease, both a- and b-wave amplitudes are reduced and the implicit times delayed (Fishman, 2001). In the later stages of the disease, if the ERG responses are recordable, residual retinal function is mostly due to cone functions (Sieving et al, 1986). Female carriers generally have normal ERG responses (Mura et al, 2007).

2.7.2 Gyrate atrophy

Gyrate atrophy is an autosomal recessive dystrophy caused by mutations of the gene encoding ornithine aminotransferase, a vitamin B6 dependent mitochondrial enzyme which

catalyzes the conversion of ornithine to glutamate and proline (Mashima et al, 1992). The resultant biochemical abnormality is hypolysinemia, hyperornithinemia, and a marked reduction in ornithine aminotransferase activity in cultured skin fibroblasts and in lymphocytes (Simell & Takki, 1973).

The patients generally begin to experience night blindness between the age of 20 and 40 years. The peripheral fundus has multiple, discrete patches of chorioretinal atrophy areas. With time, these lesions progress toward both centrally and peripherally causing peripheral visual field and visual acuity loss. Myopia and posterior subcapsular cataract are common among patients (Kaiser-Kupfer et al, 1991).

ERG responses are indicative of the extent of the disease and diminishes as the chorioretinal atrophy progresses. In the advanced stages of the disease, the ERG may even be nondetectable.

2.7.3 Pigmented paravenous retinochoroidal atrophy

Pigmented paravenous retinochoroidal atrophy (PPRCA) is a rare bilateral stationary condition of the ocular fundus in which bone corpuscle pigmentation is seen in a paravenous distribution. The first cases were reported by Franceschetti under various names, however, the author concluded that the term "pigmented paravenous retinochoroidal atrophy" best describes the condition (Franceschetti, 1962). Although it is not a generalized retinal disorder, the extent and degree of retinal involvement varies significantly between affected patients (Noble & Carr, 1983; Traboulsi & Maumenee, 1986). The disease is usually asymptomatic and diagnosed incidentally during routine fundoscopic examinations. Most reported cases are sporadic, however, familial occurrences were also reported (Traboulsi & Maumenee, 1986; Skalka, 1979). ERG responses are generally variable depending on the extent of the disease (Lam, 2005). Miyake reported that the ERG amplitudes are smaller than normal, however, the implicit times are normal suggesting that the retina is not diffusely involved as it would be in retinitis pigmentosa. MfERG amplitudes are reduced in the affected retinal areas (Miyake, 2006).

3. Conclusion

Electroretinographic testing methods are indispensable parts of the evaluation of patients with hereditary retinal diseases. Full-field ERG has an important role in the diagnosis and follow-up of patients with retinal functional abnormalities and a normal-appearing fundus. In some clinical situations, full-field ERG may also help in the differential diagnosis. This chapter aimed to show some examples of ERGs in hereditary retinal disorders and to show the consistency between function and symptom and signs when appropriate method of ERG technique was chosen.

4. References

- Aaberg, TM. (1986). Stargardt's disease and fundus flavimaculatus: evaluation of morphologic progression and intrafamilial co-existence. *Transactions of the American Ophthalmological Society*. Vol.84, pp. 453-87. ISSN 0065-9533
- Abraham, FA. (1975). Sector retinitis pigmentosa. Electrophysiological and psychophysical study of the visual system. *Documenta Ophthalmologica*. Vol. 39, No.1, pp.13-28. ISSN 0012-4486

- Adachi-Usami, E., Murayama, K. & Yamamoto, Y. (1990). Electroretinograms and pattern visually evoked cortical potentials in central areolar choroidal dystrophy. *Documenta Ophthalmologica*. Vol.75, No.1, pp.33-40. ISSN 0012-4486
- Andréasson, SO., Sandberg, MA. & Berson, EL. (1988). Narrow-band filtering for monitoring low-amplitude cone electroretinograms in retinitis pigmentosa. *American Journal of Ophthalmology*. Vol.105, No.5, pp.500-3. ISSN: 0002-9394
- Auerbach, E., Godel, V. & Rowe, H. (1969). An electrophysiological and psychophysical study of two forms of congenital night blindness. *Investigative Ophthalmology & Visual Science*. Vol.8, No.3, pp.332-45. ISSN 1552-5783
- Auerbach, E. & Kripke, B. (1970). Some studies of rod monochromatism: a dominant pedigree. *Electroencephalography and Clinical Neurophysiology*. Vol.28, No.6, pp.643. ISSN:0013-4694
- Avigan, J., Steinberg, D., Gutman, A., Mize, CE. & Milne, GW. (1966). Alpha-decarboxylation, an important pathway for degradation of phytanic acid in animals. *Biochemical and Biophysical Research Communications*. Vol.24, No.6, pp.838-44. ISSN 0006-291X
- Aylward, B., daCruz, L., Ezra, E., Sullivan, P., MacLaren, RE., Charteris, D., Gregor, Z., Bainbridge, J. & Minihan, M. (2008). Stickler syndrome. *Ophthalmology*. Vol.115, No.9, pp.1636-7. ISSN 0161-6420
- Berson, EL. (1981). Retinitis pigmentosa and allied diseases: applications of electroretinographic testing. *International Ophthalmology*. Vol.4, No.1-2, pp.7-22. ISSN 0165-5701
- Berson, EL., Gouras, P. & Gunkel, RD. (1968). Progressive cone degeneration, dominantly inherited. *Archives of Ophthalmology*. Vol.80, No.1, pp.77-83. ISSN 0093-0326
- Berson, EL. & Howard, J. (1971). Temporal aspects of the electroretinogram in sector retinitis pigmentosa. *Archives of Ophthalmology*. Vol.86, No.6, pp.653-65. ISSN 0093-0326
- Berson, EL. (1987). Electroretinographic findings in retinitis pigmentosa. *Japanese Journal of Ophthalmology*. Vol.31, No.3, pp.327-48. ISSN 0021-5155
- Berson, EL. (1976). Retinitis pigmentosa and allied retinal diseases: electrophysiologic findings. *Transaction. Section on Ophthalmology. American Academy of Ophthalmology and Otolaryngology*. Vol.81, No.4 Pt 1, pp.659-666. ISSN 0002-7154
- Birch, DG. & Sandberg, MA. (1987). Dependence of cone b-wave implicit time on rod amplitude in retinitis pigmentosa. *Vision Research*. Vol.27, No.7, pp.1105-12. ISSN 0042-6989
- Birch, DG. (2006). Retinitis pigmentosa. In. *Principles and practice of clinical electrophysiology of vision*, Heckenlively, JR., Arden, GB., pp. (781-794), The MIT press, 0-262-08346-9, Cambridge.
- Bishara, S., Merin, S., Cooper, M., Azizi, E., Delpre, G. & Deckelbaum, RJ. (1982). Combined vitamin A and E therapy prevents retinal electrophysiological deterioration in abetalipoproteinaemia. *British Journal of Ophthalmology*. Vol.66, No.12, pp.767-70. ISSN 0007-1161
- Boughman, JA., Conneally, PM. & Nance, WE. (1980). Population genetic studies of retinitis pigmentosa. *American Journal of Human Genetics*. Vol.32, No.2, pp.223-35. ISSN 0002-9297
- Brown, DM., Graemiger, RA., Hergersberg, M., Schinzel, A., Messmer, EP., Niemeyer, G., Schneeberger, SA., Streb, LM., Taylor, CM., Kimura, AE., et al. (1995). Genetic

- linkage of Wagner disease and erosive vitreoretinopathy to chromosome 5q13-14. *Archives of Ophthalmology*. Vol.113, No.5, pp.671-5. ISSN 0093-0326
- Bunker, CH., Berson, EL., Bromley, WC., Hayes, RP. & Roderick, TH. (1984). Prevalence of retinitis pigmentosa in Maine. *American Journal of Ophthalmology*. Vol.97, No.3, pp.357-65. ISSN 0002-9394
- Capon, MR., Polkinghorne, PJ., Fitzke, FW. & Bird, AC. (1988). Sorsby's pseudoinflammatory macula dystrophy--Sorsby's fundus dystrophies. *Eye (London)*. Vol.2, No. Pt 1, pp.114-22. ISSN 0950-222X
- Carr, RE., Ripps, H., Siegel, IM. & Weale, RA. (1966). Rhodopsin and the electrical activity of the retina in congenital night blindness. *Investigative Ophthalmology & Visual Science*. Vol.5, No.5, pp.497-507. ISSN 1552-5783
- Carr, RE. (1965). Central Areolar Choroidal Dystrophy. *Archives of Ophthalmology*. Vol.73, pp.32-5. ISSN 0093-0326
- Carr, RE. (1974). Congenital stationary nightblindness. *Transactions of the American Ophthalmological Society*. Vol.72, pp.448-87. ISSN 0065-9533
- Chan, HL. & Brown, B. (1998). Investigation of retinitis pigmentosa using the multifocal electroretinogram. *Ophthalmic & Physiological Optics*. Vol.18, No.4, pp.335-50. ISSN 0275-5408
- Cideciyan, AV., Zhao, X., Nielsen, L., Khani, SC., Jacobson, SG. & Palczewski, K. (1998). Null mutation in the rhodopsin kinase gene slows recovery kinetics of rod and cone phototransduction in man. *Proceedings of the National Academy of Sciences of the United States of America*. Vol.95, No.1, pp.328-33. ISSN 0027-8424
- Clarke, MP., Mitchell, KW. & McDonnell, S. (1996-1997). Electroretinographic findings in macular dystrophy. *Documenta Ophthalmologica*. Vol.92, No.4, pp.325-39. ISSN 0303-6405
- Cremers, FP., van de Pol, DJ., van Kerkhoff, LP., Wieringa, B. & Ropers, HH. (1990). Cloning of a gene that is rearranged in patients with choroideraemia. *Nature*. Vol.347, No.6294, pp.674-7. ISSN 0028-0836
- Daniele, S., Carbonara, A., Daniele, C., Restagno, G. & Orcidi, F. (1996). Pattern dystrophies of the retinal pigment epithelium. *Acta Ophthalmologica Scandinavica*. Vol.74, No.1, pp.51-5. ISSN:1395-3907
- Deutman, AF. & Rümke, AM. (1969). Reticular dystrophy of the retinal pigment epithelium. Dystrophia reticularis laminae pigmentosa retinae of H. Sjogren. *Archives of Ophthalmology*. Vol.82, No.1, pp.4-9. ISSN 0093-0326
- Deutman, AF., van Blommestein, JD., Henkes, HE., Waardenburg, PJ. & Solleveld-van Driest, E. (1970). Butterfly-shaped pigment dystrophy of the fovea. *Archives of Ophthalmology*. Vol.83, No.5, pp.558-69. ISSN 0093-0326
- Deutman, AF. (1989) Macular dystrophies. In *Retina*. Vol.2(Ed.Ryan, SJ.) pp.264-268. CV Mosby, St. Louis, MO USA.
- Deutman, AF. (1971) *The hereditary Dystrophies of the posterior pole of the eye*. pp.198-299. Thomas CC, Springfield.
- Eagle, RC Jr., Lucier, AC., Bernardino, VB Jr. & Yanoff, M. (1980). Retinal pigment epithelial abnormalities in fundus flavimaculatus: a light and electron microscopic study. *Ophthalmology*. Vol.87, No.12, pp.1189-200. ISSN 0161-6420

- Eksandh, L., Andréasson, S. & Abrahamson, M. (2005). Juvenile X-linked retinoschisis with normal scotopic b-wave in the electroretinogram at an early stage of the disease. *Ophthalmic genetics*. Vol.26, No.3, pp.111-7. ISSN 1381-6810
- Eksandh, LC., Ponjavic, V., Ayyagari, R., Bingham, EL., Hiriyanna, KT., Andréasson, S., Ehinger, B. & Sieving, PA. (2000). Phenotypic expression of juvenile X-linked retinoschisis in Swedish families with different mutations in the XLR51 gene. *Archives of Ophthalmology*. Vol.118, No.8, pp.1098-104. ISSN 0093-0326
- Eldjarn, L., Stokke, O. & Try, K. (1966). Alpha-oxidation of branched chain fatty acids in man and its failure in patients with Refsum's disease showing phytanic acid accumulation. *Scandinavian Journal of Clinical and Laboratory Investigation*. Vol.18, No.6, pp.694-5. ISSN:0036-5513
- Felbor, U., Stöhr, H., Aman, T., Schönherr, U., Apfelstedt-Sylla, E. & Weber, BH. (1996). A second independent Tyr168Cys mutation in the tissue inhibitor of metalloproteinases-3 (TIMP3) in Sorsby's fundus dystrophy. *Journal of Medical Genetics*. Vol.33, No.3, pp.233-6. ISSN 0022-2593
- Felius, J. & Swanson, WH. (1999). Photopic temporal processing in retinitis pigmentosa. *Investigative Ophthalmology & Visual Sciences*. Vol.40, No.12, pp.2932-44. ISSN 0146-0404
- Fish, G., Grey, R., Sehmi, KS. & Bird, AC. (1981). The dark choroid in posterior retinal dystrophies. *British Journal of Ophthalmology*. Vol.65, No.5, pp.359-63. ISSN 0007-1161
- Fishman, GA., Alexander, KR. & Anderson, RJ. (1985). Autosomal dominant retinitis pigmentosa. A method of classification. *Archives of Ophthalmology*. Vol.103, No.3, pp.366-74. ISSN 0093-0326
- Fishman, GA., Farbman, JS. & Alexander, KR. (1991). Delayed rod dark adaptation in patients with Stargardt's disease. *Ophthalmology*. Vol.98, No.6, pp.957-62. ISSN 0161-6420
- Fishman, GA., Kumar, A., Joseph, ME., Torok, N. & Anderson, RJ. (1983). Usher's syndrome. Ophthalmic and neuro-otologic findings suggesting genetic heterogeneity. *Archives of Ophthalmology*. Vol.101, No.9, pp.1367-74. ISSN 0093-0326
- Fishman, GA. (2001). The electroretinogram, In: *Electrophysiologic testing in disorders of the retina, optic nerve, and visual pathways*, Fishman GA, Birch DG, Holder GE, Brigell MG, pp. (1-155), American Academy of Ophthalmology, 1-56055-198-4, Singapore.
- Franceschetti, A. & François, J. (1965). Fundus flavimaculatus. *Archives d'ophtalmologie et revue générale d'ophtalmologie*. Vol.25, No.6, pp.505-30. ISSN 0003-973X
- Franceschetti, A. (1962). A curious affection of the fundus oculi: helicoid peripapillar chorioretinal degeneration. Its relation to pigmentary paravenous chorioretinal degeneration. *Documenta Ophthalmologica*. Vol.16, pp.81-110. ISSN 0012-4486
- Franceschetti, A. (1965). A special form of tapetoretinal degeneration: fundus flavimaculatus. *Transaction. Section on Ophthalmology. American Academy of Ophthalmology and Otolaryngology*. Vol.69, No.6, pp.1048-53. ISSN 0002-7154
- Frank, HR., Landers, MB 3rd., Williams, RJ. & Sidbury, JB. (1974). A new dominant progressive foveal dystrophy. *American Journal of Ophthalmology*. Vol.78, No.6, pp.903-16. ISSN: 0002-9394
- George, ND., Yates, JR. & Moore, AT. (1995). X linked retinoschisis. *British Journal of Ophthalmology*. Vol.79, No.7, pp.697-702. ISSN 0007-1161

- Gerth, C., Zawadzki, RJ., Werner, JS. & Héon, E. (2008). Retinal morphological changes of patients with X-linked retinoschisis evaluated by Fourier-domain optical coherence tomography. *Archives of Ophthalmology*. Vol.126, No.6, pp.807-11. ISSN 0093-0326
- Godel, V., Regenbogen, L., Adam, A. & Stein, R. (1976). Rod monochromatism -- an incomplete form. *Journal of Pediatric Ophthalmology*. Vol.13, No.4, pp.221-5. ISSN 0022-345X
- Goodman, G., Ripps, H. & Siegel, IM. (1963). Cone Dysfunction Syndromes. *Archives of Ophthalmology*. Vol.70, pp.214-31. ISSN 0093-0326
- Gouras, P., Carr, RE & Gunkel, RD. (1971). Retinitis pigmentosa in abetalipoproteinemia: Effects of vitamin A. *Investigative Ophthalmology & Visual Sciences*. Vol. 10, Number.10, pp. 784-793. ISSN 0146-0404.
- Gouras, P., Eggers, HM. & MacKay, CJ. (1983). Cone dystrophy, nyctalopia, and supernormal rod responses. A new retinal degeneration. *Archives of Ophthalmology*. Vol.101, No.5, pp.718-24. ISSN 0093-0326
- Gregory-Evans, K., Kelsel, RE., Gregory-Evans, CY., Downes, SM., Fitzke, FW., Holder, GE., Simunovic, M., Mollon, JD., Taylor, R., Hunt, DM., Bird, AC. & Moore, AT. (2000). Autosomal dominant cone-rod retinal dystrophy (CORD6) from heterozygous mutation of GUCY2D, which encodes retinal guanylate cyclase. *Ophthalmology*. Vol.107, No.1, pp.55-61. ISSN 0161-6420
- Gundogan, FC., Dinç, UA., Erdem, U., Ozge, G. & Sobaci, G. (2010). Multifocal electroretinogram and central visual field testing in central areolar choroidal dystrophy. *European Journal of Ophthalmology*. Vol. 20, Number. 5, pp.919-24. ISSN 1120-6721.
- Gundogan, FC., Tas, A & Sobaci G (2011). Cone dystrophy with supernormal rod electroretinogram. In print *Journal of Retina Vitreous*. ISSN 1300-1256
- Haider, NB., Jacobson, SG., Cideciyan, AV., Swiderski, R., Streb, LM., Searby, C., Beck, G., Hockey, R., Hana, DB., Gorman, S., Duhl, D., Carmi, R., Bennett, J., Weleber, RG., Fishman, GA., Wright, AF., Stone, EM. & Sheffield, VC. (2000). Mutation of a nuclear receptor gene, NR2E3, causes enhanced S cone syndrome, a disorder of retinal cell fate. *Nature Genetics*. Vol.24, No.2, pp.127-31. ISSN 1061-4036.
- Hamel, C. (2006). Retinitis pigmentosa. *Orphanet Journal of Rare Disease*. Vol.11, pp.1:40. ISSN 1750-1172.
- Hayakawa, M., Imai, Y., Wakita, M., Kato, K., Yanashima, K., Miyake, Y. & Kanai, A. (1992). A Japanese pedigree of autosomal dominant congenital stationary night blindness with variable expressivity. *Ophthalmic Paediatrics and Genetics*. Vol.13, No.4, pp.211-7. ISSN 0167-6784.
- Heckenlively, JR. & Weleber, RG. (1986). X-linked recessive cone dystrophy with tapetal-like sheen. A newly recognized entity with Mizuo-Nakamura phenomenon. *Archives of Ophthalmology*. Vol.104, No.9, pp.1322-8. ISSN 0093-0326.
- Heckenlively, JR. (2006). Cone dystrophies and degenerations, In: *Principles and practice of clinical electrophysiology of vision*, Heckenlively, JR., Arden, GB., pp. (795-802), The MIT press, 0-262-08346-9, Cambridge.
- Hirose, T., Lee, KY. & Schepens, CL. (1973). Wagner's hereditary vitreoretinal degeneration and retinal detachment. *Archives of Ophthalmology*. Vol.89, No.3, pp.176-85. ISSN 0093-0326

- Holder, GE. (2001). Pattern electroretinography (PERG) and an integrated approach to visual pathway diagnosis. *Progress in Retinal and Eye Research*. Vol.20, No.4, pp.531-61. ISSN 1350-9462
- Holder, GE. (2001). The pattern electroretinogram, In: *Electrophysiologic testing in disorders of the retina, optic nerve, and visual pathways*, Fishman GA, Birch DG, Holder GE, Brigell MG, pp. (197-235), American Academy of Ophthalmology, 1-56055-198-4, Singapore.
- Holopigian, K., Seiple, W., Greenstein, VC., Hood, DC. & Carr, RE. (2001). Local cone and rod system function in patients with retinitis pigmentosa. *Investigative Ophthalmology & Visual Sciences*. Vol.42, No.3, pp.779-88. ISSN 0146-0404
- Hood, DC., Holopigian, K., Greenstein, V., Seiple, W., Li, J., Sutter, EE. & Carr, RE. (1998). Assessment of local retinal function in patients with retinitis pigmentosa using the multi-focal ERG technique. *Vision Research*. Vol.38, No.1, pp.163-79. ISSN 0042-6989
- Hoyng, CB. & Deutman, AF. (1996). The development of central areolar choroidal dystrophy. *Graefe's Archive for Clinical and Experimental Ophthalmology*. Vol.234, No.2, pp.87-93. ISSN 0721-832X
- Hsieh, RC., Fine, BS. & Lyons, JS. (1977). Patterned dystrophies of the retinal pigment epithelium. *Archives of Ophthalmology*. Vol.95, No.3, pp.429-35. ISSN 0093-0326
- Humphries, P., Kenna, P. & Farrar, GJ. (1992). On the molecular genetics of retinitis pigmentosa. *Science*. Vol.256, No.5058, pp.804-8. ISSN 0036-8075
- Iijima, H., Yamaguchi, S. & Hosaka, O. (1993). Photopic electroretinogram implicit time in retinitis pigmentosa. *Japanese Journal of Ophthalmology*. Vol.37, No.2, pp.130-5. ISSN 0021-5155
- Itabashi, R., Katsumi, O., Mehta, MC., Wajima, R., Tamai, M. & Hirose, T. (1993). Stargardt's disease/fundus flavimaculatus: psychophysical and electrophysiologic results. *Graefe's Archive for Clinical and Experimental Ophthalmology*. Vol.231, No.10, pp.555-62. ISSN 0721-832X
- Jacobson, SG., Román, AJ., Román, MI., Gass, JD. & Parker, JA. (1991). Relatively enhanced S cone function in the Goldmann-Favre syndrome. *American Journal of Ophthalmology*. Vol.111, No.4, pp.446-53. ISSN: 0002-9394
- Jarc-Vidmar, M., Popović, P., Hawlina, M., Breclj, J (2001). Pattern ERG and psychophysical functions in Best's disease. *Documenta Ophthalmologica*. Vol. 103, No: 1, pp: 47-61. ISSN 0012-4486
- Kaiser-Kupfer, MI., Caruso, RC. & Vale, D. (1991). Gyrate atrophy of the choroid and retina. Long-term reduction of ornithine slows retinal degeneration. *Archives of Ophthalmology*. Vol.109, No.11, pp.1539-48. ISSN 0093-0326
- Kandori, F., Setogawa, T. & Tamai, A. (1966). Electroretinographical studies on "fleck retina with congenital nonprogressive nightblindness". *Yonago Acta Medica*. Vol.10, No.2, pp.98-108. ISSN 0513-5710
- Kandori, F., Tamai, A., Watanabe, T. & Kurimoto, S. (1968). Unilateral pigmentary degeneration of the retina. Report of two cases. *American Journal of Ophthalmology*. Vol.66, No.6, pp.1091-101. ISSN: 0002-9394
- Keating, D., Parks, S. (2006). Multifocal Techniques, In: *Principles and practice of clinical electrophysiology of vision*, Heckenlively, JR., Arden, GB., pp. (319-351), The MIT press, 0-262-08346-9, Cambridge.

- Kellner, U. & Foerster, MH. (1993). Cone dystrophies with negative photopic electroretinogram. *British Journal of Ophthalmology*. Vol.77, No.7, pp.404-9. ISSN 0007-1161
- Kim, LS., Seiple, W., Fishman, GA & Szlyk, JP (2007). Multifocal ERG findings in carriers of X-linked retinoschisis. *Documenta Ophthalmologica*. Vol. 114, Number. 1, pp.:21-26. ISSN 0012-4486
- Kimberling, WJ., Möller, CG., Davenport, SL., Lund, G., Grissom, TJ., Priluck, I., White, V., Weston, MD., Biscione-Halterman, K. & Brookhouser, PE. (1989). Usher syndrome: clinical findings and gene localization studies. *The Laryngoscope*. Vol.99, No.1, pp.66-72. ISSN 0023-852X
- Kingham, JD., Fenzl, RE., Willerson, D. & Aaberg, TM. (1978). Reticular dystrophy of the retinal pigment epithelium. A clinical and electrophysiologic study of three generations. *Archives of Ophthalmology*. Vol.96, No.7, pp.1177-84. ISSN 0093-0326
- Kjellström, S., Vijayasarathy, C., Ponjavic, V., Sieving, PA. & Andréasson, S (2010). Long-term 12 year follow-up of X-linked congenital retinoschisis. *Ophthalmic genetics*. Vol.31, No.3, pp.114-25. ISSN 1381-6810
- Kolb, H. & Galloway, NR. (1964). Three Cases Of Unilateral Pigmentary Degeneration. *British Journal of Ophthalmology*. Vol.48, pp.471-9. ISSN 0007-1161
- Kondo, M., Miyake, Y., Horiguchi, M., Suzuki, S. & Tanikawa, A. (1995). Clinical evaluation of multifocal electroretinogram. *Investigative Ophthalmology & Visual Sciences*. Vol.36, No.10, pp.2146-50. ISSN 0146-0404
- Kretschmann, U., Seeliger, MW., Ruether, K., Usui, T., Apfelstedt-Sylla, E. & Zrenner, E. (1998). Multifocal electroretinography in patients with Stargardt's macular dystrophy. *British Journal of Ophthalmology*. Vol.82, No.3, pp.267-75. ISSN 0007-1161
- Lachapelle, P., Little, JM. & Roy, MS. (1989). The electroretinogram in Stargardt's disease and fundus flavimaculatus. *Documenta Ophthalmologica*. Vol.73, No.4, pp.395-404. ISSN 0012-4486
- Ladekjaer-Mikkelsen AS, Rosenberg T, Jørgensen AL. A new mechanism in blue cone monochromatism. *Hum Genet*. 1996 Oct;98(4):403-8.
- Lam BL. (2005). *Electrophysiology of Vision: Clinical testing and applications*, Taylor & Francis, 0-8247-4068-8, New York.
- Lefler, WH., Wadsworth, JA. & Sidbury, JB Jr. (1971). Hereditary macular degeneration and amino-aciduria. *American Journal of Ophthalmology*. Vol.71(1 Pt 2), pp.224-30. ISSN: 0002-9394
- Lois, N., Holder, GE., Bunce, C., Fitzke, FW. & Bird, AC. (2001). Phenotypic subtypes of Stargardt macular dystrophy-fundus flavimaculatus. *Archives of Ophthalmology*. Vol.119, No.3, pp.359-69. ISSN 0093-0326
- MacDonald, IM., Russell, L. & Chan, CC. (2009). Choroideremia: new findings from ocular pathology and review of recent literature. *Survey of Ophthalmology*. Vol.54, No.3, pp.401-7. ISSN 0039-6257
- Marmor, MF., Jacobson, SG., Foerster, MH., Kellner, U. & Weleber, RG. (1990). Diagnostic clinical findings of a new syndrome with night blindness, maculopathy, and enhanced S cone sensitivity. *American Journal of Ophthalmology*. Vol.110, No.2, pp.124-34. ISSN: 0002-9394
- Marmor, MF. (1989). Large rod-like photopic signals in a possible new form of congenital night blindness. *Documenta Ophthalmologica*. Vol.71, No.3, pp.265-9. ISSN 0012-4486

- Marmor, MF. (1979). The electroretinogram in retinitis pigmentosa. *Archives of Ophthalmology*. Vol.97, No.7, pp.1300-4. ISSN 0093-0326
- Marmor, MF., Fulton, AB., Holder, GE., Miyake, Y. & Brigell, M. (2009). ISCEV Standard for full-field clinical electroretinography (2008 update). *Documenta Ophthalmologica*, Vol. 118, No. 1, pp. 69-77. ISSN 0012-4486
- Mashima, Y., Murakami, A., Weleber, RG., Kennaway, NG., Clarke, L., Shiono, T. & Inana, G. (1992). Nonsense-codon mutations of the ornithine aminotransferase gene with decreased levels of mutant mRNA in gyrate atrophy. *American Journal of Human Genetics*. Vol.51, No.1, pp.81-91. ISSN 0002-9297
- Miyake, Y., Horiguchi, M., Suzuki, S., Kondo, M. & Tanikawa, A. (1996). Electrophysiological findings in patients with Oguchi's disease. *Japanese Journal of Ophthalmology*. Vol.40, No.4, pp.511-9. ISSN 0021-5155
- Miyake, Y., Horiguchi, M., Terasaki, H. & Kondo, M. (1994). Scotopic threshold response in complete and incomplete types of congenital stationary night blindness. *Investigative Ophthalmology & Visual Sciences*. Vol.35, No.10, pp.3770-5. ISSN 0146-0404
- Miyake, Y., Yagasaki, K., Horiguchi, M., Kawase, Y. & Kanda, T. (1986). Congenital stationary night blindness with negative electroretinogram. A new classification. *Archives of Ophthalmology*. Vol.104, No.7, pp.1013-20. ISSN 0093-0326
- Miyake, Y., Yagasaki, K., Horiguchi, M. & Kawase, Y. (1987). On- and off-responses in photopic electroretinogram in complete and incomplete types of congenital stationary night blindness. *Japanese Journal of Ophthalmology*. Vol.31, No.1, pp.81-7. ISSN 0021-5155
- Miyake, Y. (2006). Chorioretinal disorders, In: *Electrodiagnosis of retinal diseases*, Miyake, Y, pp. (331-342), Springer, 4-431-25466-8, Japan.
- Miyake, Y. (2006). Retinitis pigmentosa and pigmentary retinopathies In: *Electrodiagnosis of retinal diseases*, Miyake, Y, pp. (191-242), Springer, 4-431-25466-8, Japan.
- Moore, AT. (1992). Cone and cone-rod dystrophies. *Journal of Medical Genetics*. Vol.29, No.5, pp.289-90. ISSN 0022-2593
- Moskowitz, A., Hansen, RM., Akula, JD., Eklund, SE. & Fulton, AB. (2009). Rod and rod-driven function in achromatopsia and blue cone monochromatism. *Investigative Ophthalmology & Visual Sciences*. Vol.50, No.2, pp.950-8. ISSN 0146-0404
- Mukkamala, K., Gentile, RC., Willner, J. & Tsang, S. (2010). Choroideremia in a woman with ectodermal dysplasia and complex translocations involving chromosomes X, 1, and 3. *Ophthalmic genetics*. Vol.31, No.4, pp.178-82. ISSN 1381-6810
- Mura, M., Sereda, C., Jablonski, MM., MacDonald, IM. & Iannaccone, A. (2007). Clinical and functional findings in choroideremia due to complete deletion of the CHM gene. *Archives of Ophthalmology*. Vol.125, No.8, pp.1107-13. ISSN 0093-0326
- Nagasaka, K., Horiguchi, M., Shimada, Y. & Yuzawa, M. (2003). Multifocal electroretinograms in cases of central areolar choroidal dystrophy. *Investigative Ophthalmology & Visual Sciences*. Vol.44, No.4, pp.1673-9. ISSN 0146-0404
- Nakamura, M. & Miyake, Y. (2002). Macular dystrophy in a 9-year-old boy with fundus albipunctatus. *American Journal of Ophthalmology*. Vol.133, No.2, pp.278-80. ISSN: 0002-9394
- Nakamura, M., Skalet, J. & Miyake, Y. (2003). RDH5 gene mutations and electroretinogram in fundus albipunctatus with or without macular dystrophy: RDH5 mutations and

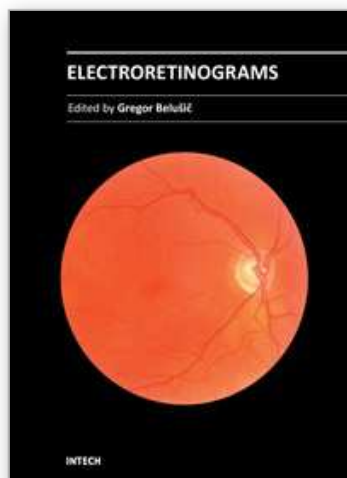
- ERG in fundus albipunctatus. *Documenta Ophthalmologica*. Vol.107, No.1, pp.3-11. ISSN 0012-4486
- Nakazato, H., Hanazaki, H., Kawasaki, K., Tanabe, J & Yonemura D (1986). Electroretinographic off-response in congenital red-green color deficiency and its genetic carrier. *Documenta Ophthalmologica* Vol. 63, No.2 , pp. 179-186 ISSN 0012-4486
- Nathans, J., Piantanida, TP., Eddy, RL., Shows, TB. & Hogness, DS. (1986). Molecular genetics of inherited variation in human color vision. *Science*. Vol.232, No.4747, pp.203-10. ISSN 0036-8075
- Nathans, J., Thomas, D. & Hogness, DS. (1986). Molecular genetics of human color vision: the genes encoding blue, green, and red pigments. *Science*. Vol.232, No.4747, pp.193-202. ISSN 0036-8075
- Noble, KG., Carr, RE. & Siegel, IM. (1990). Autosomal dominant congenital stationary night blindness and normal fundus with an electronegative electroretinogram. *American Journal of Ophthalmology*. Vol.109, No.1, pp.44-8. ISSN: 0002-9394
- Noble, KG. & Carr, RE. (1983). Pigmented paravenous chorioretinal atrophy. *American Journal of Ophthalmology*. Vol.96, No.3, pp.338-44. ISSN: 0002-9394
- Noble, KG. (1977). Central areolar choroidal dystrophy. *American Journal of Ophthalmology*. Vol.84, No.3, pp.310-8. ISSN: 0002-9394
- Nussbaum, JJ., Ferencz, JR., Maeda, K. & Weiss, L. (1991). Autosomal dominant crystalline dystrophy. Richards BW, Brodstein DE. *Ophthalmology*. Vol.98, No.5, pp.658-65. ISSN 0161-6420
- Ohkubo, H. & Tanino, T. (1987). Electrophysiological findings in familial exudative vitreoretinopathy. *Documenta Ophthalmologica*. Vol.65, No.4, pp.461-9. ISSN 0012-4486
- Palmowski, AM., Allgayer, R., Heinemann-Vernaleken, B., Scherer, V. & Ruprecht, KW. (2003). Detection of retinal dysfunction in vitelliform macular dystrophy using the multifocal ERG (MF-ERG). *Documenta Ophthalmologica*. Vol.106, No.2, pp.145-52. ISSN 0012-4486
- Petzold, A. & Plant, GT. (2006). Clinical disorders affecting mesopic vision. *Ophthalmic & Physiological Optics*. May;26(3):326-41. ISSN 0275-5408
- Ponjavic, V., Andréasson, S. & Ehinger, B. (1994). Full-field electroretinograms in patients with central areolar choroidal dystrophy. *Acta Ophthalmologica (Copenh)*. Vol.72, No.5, pp.537-44. ISSN 0001-639X
- Quigley, M., Roy, MS., Barsoum-Homsy, M., Chevrette, L., Jacob, JL. & Milot, J. (1996-1997). On- and off-responses in the photopic electroretinogram in complete-type congenital stationary night blindness. *Documenta Ophthalmologica*. Vol.92, No.3, pp.159-65. ISSN 0012-4486
- Rabb, MF., Mullen, L., Yelchits, S., Udar, N. & Small, KW. (1998). A North Carolina macular dystrophy phenotype in a Belizean family maps to the MCDR1 locus. *American Journal of Ophthalmology*. Vol.125, No.4, pp.502-8. ISSN 0002-9394
- Refsum, S. (1981). Heredopathia atactica polyneuritiformis phytanic-acid storage disease, Refsum's disease:" a biochemically well-defined disease with a specific dietary treatment. *Archives of Neurology*. Vol.38, No.10, pp.605-6. ISSN 0003-9942
- Riggs, LA. (1954). Electroretinography in cases of night blindness. *American Journal of Ophthalmology*. Vol.38, No.1:2, pp.70-8. ISSN: 0002-9394

- Robson, AG., Webster, AR., Michaelides, M., Downes, SM., Cowing, JA., Hunt, DM., Moore, AT. & Holder, GE. (2010). "Cone dystrophy with supernormal rod electroretinogram": a comprehensive genotype/phenotype study including fundus autofluorescence and extensive electrophysiology. *Retina*. Vol.30, No.1, pp.51-62. ISSN 0275-004X
- Rosenberg, T., Haim, M., Piczenik, Y. & Simonsen, SE. (1991). Autosomal dominant stationary night-blindness. A large family rediscovered. *Acta Ophthalmologica (Copenh)*. Vol.69, No.6, pp.694-702. ISSN 0001-639X
- Rosner, M., Hefetz, L. & Abraham, FA. (1993). The prevalence of retinitis pigmentosa and congenital stationary night blindness in Israel. *American Journal of Ophthalmology*. Vol.116, No.3, pp.373-4. ISSN: 0002-9394
- Runge, P., Muller, DP., McAllister, J., Calver, D., Lloyd, JK. & Taylor, D. (1986). Oral vitamin E supplements can prevent the retinopathy of abetalipoproteinaemia. *British Journal of Ophthalmology*. Vol.70, No.3, pp.166-73. ISSN 0007-1161
- Sandberg, MA., Pawlyk, BS., Dan, J., Arnaud, B., Dryja, TP. & Berson, EL. (1998). Rod and cone function in the Nougaret form of stationary night blindness. *Archives of Ophthalmology*. Vol.116, No.7, pp.867-72. ISSN 0093-0326
- Sankila, EM., Pakarinen, L., Kääriäinen, H., Aittomäki, K., Karjalainen, S., Sistonen, P. & de la Chapelle, A. (1995). Assignment of an Usher syndrome type III (USH3) gene to chromosome 3q. *Human Molecular Genetics*. Vol.4, No.1, pp.93-8. ISSN 0964-6906
- Scholl, HP., Schuster, AM., Vonthein, R. & Zrenner, E. (2002). Mapping of retinal function in Best macular dystrophy using multifocal electroretinography. *Vision Research*. Vol.42, No.8, pp.1053-61. ISSN 0042-6989
- Seeliger, MW., Zrenner, E., Apfelstedt-Sylla, E. & Jaissle, GB. (2001). Identification of Usher syndrome subtypes by ERG implicit time. *Investigative Ophthalmology & Visual Sciences*. Vol.42, No.12, pp.3066-71. ISSN 0146-0404
- Shiono, T., Ishikawa, A., Hara, S. & Tamai, M. (1990). Pattern dystrophy of the retinal pigment epithelium. *Retina*. Vol.10, No.4, pp.251-4. ISSN 0275-004X
- Sieving, PA., Niffenegger, JH. & Berson, EL. (1986). Electroretinographic findings in selected pedigrees with choroideremia. *American Journal of Ophthalmology*. Vol.101, No.3, pp.361-7. ISSN 0002-9394
- Simell, O. & Takki, K. (1973). Raised plasma-ornithine and gyrate atrophy of the choroid and retina. *Lancet*. Vol.1, No.7811, pp.1031-3. ISSN 0140-6736
- Simunovic, MP. & Moore, AT. (1998). The cone dystrophies. *Eye (London, England)*. Vol.12, No. (Pt 3b), pp.553-65. ISSN 0950-222X
- Sivaprasad, S., Webster, AR., Egan, CA., Bird, AC. & Tufail, A. (2008). Clinical course and treatment outcomes of Sorsby fundus dystrophy. *American Journal of Ophthalmology*. Vol.146, No.2, pp.228-234. Epub 2008 May 23. ISSN: 0002-9394
- Skalka, HW. (1979). Hereditary pigmented paravenous retinochoroidal atrophy. *American Journal of Ophthalmology*. Vol.87, No.3, pp.286-91. ISSN 0002-9394
- Slezak, H. & Homer, K. (1969). [Fundus pulverulentus]. *Albrecht Von Graefe's Archive for Clinical and Experimental Ophthalmology*. Vol.178, No.2, pp.176-82. ISSN 0065-6100
- Small, KW., Weber, J., Roses, A. & Pericak-Vance, P. (1993). North Carolina macular dystrophy (MCDR1). A review and refined mapping to 6q14-q16.2. *Ophthalmic Paediatrics and Genetics*. Vol.14, No.4, pp.143-50. ISSN 0167-6784

- Sorsby, A. & Mason, ME. (1949). A fundus dystrophy with unusual features. *British Journal of Ophthalmology*. Vol.33, No.2, pp.67-97. ISSN 0007-1161
- Stickler, GB., Belau, PG., Farrell, FJ., Jones, JD., Pugh, DG., Steinberg, AG. & Ward, LE. (1965). Hereditary Progressive Arthro-Ophthalmopathy. *Mayo Clinic Proceedings*. Vol.40, pp.433-55. ISSN 0025-6196
- Sutter, EE. & Tran, D. (1992). The field topography of ERG components in man--I. The photopic luminance response. *Vision Research*. Vol.32, No.3, pp.433-46. ISSN 0042-6989
- Swain, PK., Chen, S., Wang, QL., Affatigato, LM., Coats, CL., Brady, KD., Fishman, GA., Jacobson, SG., Swaroop, A., Stone, E., Sieving, PA. & Zack, DJ. (1997). Mutations in the cone-rod homeobox gene are associated with the cone-rod dystrophy photoreceptor degeneration. *Neuron*. Vol.19, No.6, pp.1329-36. ISSN 0896-6273
- Syed, N., Smith, JE., John, SK., Seabra, MC., Aguirre, GD. & Milam, AH. (2001). Evaluation of retinal photoreceptors and pigment epithelium in a female carrier of choroideremia. *Ophthalmology*. Vol.108, No.4, pp.711-20. ISSN 0161-6420
- The Retinoschisis Consortium. (1998). Functional implications of the spectrum of mutations found in 234 cases with X-linked juvenile retinoschisis. *Human Molecular Genetics*. Vol.7, No.7, pp.1185-92. ISSN 0964-6906
- Van Aarem, A., Wagenaar, M., Pinckers, AJ., Huygen, PL., Bleeker-Wagemakers, EM., Kimberling, BJ. & Cremers, CW. (1995). Ophthalmologic findings in Usher syndrome type 2A. *Ophthalmic genetics*. Vol.16, No.4, pp.151-8. ISSN 1381-6810
- van Nouhuys, CE. (1982). Dominant exudative vitreoretinopathy and other vascular developmental disorders of the peripheral retina. *Documenta Ophthalmologica*. Vol.54, No.(1-4), pp.1-414. ISSN 0012-4486
- Watzke, RC., Folk, JC. & Lang, RM. (1982). Pattern dystrophy of the retinal pigment epithelium. *Ophthalmology*. Vol.89, No.12, pp.1400-6. ISSN 0161-6420
- Weingeist, TA., Kobrin, JL. & Watzke, RC. (1982). Histopathology of Best's macular dystrophy. *Archives of Ophthalmology*. Vol.100, No.7, pp.1108-14. ISSN 0093-0326
- Weleber, RG. (2002). Infantile and childhood retinal blindness: a molecular perspective (The Franceschetti Lecture). *Ophthalmic genetics*. Vol.23, No.2, pp.71-97. ISSN 1381-6810
- Weleber, RG., Francis, P. (2006). Differential diagnosis of the electronegative electroretinogram, In: *Principles and practice of clinical electrophysiology of vision*, Heckenlively, JR., Arden, GB., pp. (809-822), The MIT press, 0-262-08346-9, Cambridge.
- Wilson, DJ., Weleber, RG., Klein, ML., Welch, RB. & Gren, WR. (1989). Bietti's crystalline dystrophy. A clinicopathologic correlative study. *Archives of Ophthalmology*. Vol.107, No.2, pp.213-21. ISSN 0093-0326
- Wissinger, B., Dangel, S., Jägle, H., Hansen, L., Baumann, B., Rudolph, G., Wolf, C., Bonin, M., Koepfen, K., Ladewig, T., Kohl, S., Zrenner, E. & Rosenberg, T. (2008). Cone dystrophy with supernormal rod response is strictly associated with mutations in KCNV2. *Investigative Ophthalmology & Visual Sciences*. Vol.49, No.2, pp.751-7. ISSN 0146-0404
- Wu, WW., Wong, JP., Kast, J., Molday, RS. (2005). RS1, a discoidin domain-containing retinal cell adhesion protein associated with X-linked retinoschisis, exists as a novel disulfide-linked octamer. *The Journal of Biological Chemistry*. Vol.280, No.11, pp.10721-30. ISSN 0021-9258

- Wutz, K., Sauer, C., Zrenner, E., Lorenz, B., Alitalo, T., Broghammer, M., Hergersberg, M., de la Chapelle, A., Weber, B.H., Wissinger, B., Meindl, A. & Pusch, C.M. (2002). Thirty distinct CACNA1F mutations in 33 families with incomplete type of XLCSNB and Cacna1f expression profiling in mouse retina. *European Journal of Human Genetics*. Vol.10, No.8, pp.449-56. ISSN 1018-4813
- Zeitig, C., van Genderen, M., Neidhardt, J., Luhmann, U.F., Hoeben, F., Forster, U., Wycisk, K., Mátyás, G., Hoyng, C.B., Riemsdag, F., Meire, F., Cremers, F.P. & Berger, W. (2005). Mutations in GRM6 cause autosomal recessive congenital stationary night blindness with a distinctive scotopic 15-Hz flicker electroretinogram. *Investigative Ophthalmology & Visual Sciences*. Vol.46, No.11, pp.4328-35. ISSN 0146-0404

IntechOpen



Electroretinograms

Edited by Dr. Gregor Belusic

ISBN 978-953-307-383-5

Hard cover, 238 pages

Publisher InTech

Published online 09, August, 2011

Published in print edition August, 2011

Electroretinography (ERG) is a non-invasive electrophysiological method which provides objective information about the function of the retina. Advanced ERG allows to assay the different types of retinal receptors and neurons in human and animal models. This book presents contributions on the recent state of the ERG. The book is divided into three parts. The first, methodological part, reviews standard methods and normatives of human ERG, reports about the advanced spatial, temporal and spectral methods of stimulation in human ERG, and deals with the analysis of the multifocal ERG signal. The second part deals with the ERG in different diseases of the human visual system and in diabetes. The third part presents the ERG in the standard animal models of human retinal disease: mouse, rat, macaque and fruitfly.

How to reference

In order to correctly reference this scholarly work, feel free to copy and paste the following:

Fatih Cakir Gundogan, Ahmet Tas and Gungor Sobaci (2011). Electroretinogram in Hereditary Retinal Disorders, *Electroretinograms*, Dr. Gregor Belusic (Ed.), ISBN: 978-953-307-383-5, InTech, Available from: <http://www.intechopen.com/books/electroretinograms/electroretinogram-in-hereditary-retinal-disorders>

INTECH
open science | open minds

InTech Europe

University Campus STeP Ri
Slavka Krautzeka 83/A
51000 Rijeka, Croatia
Phone: +385 (51) 770 447
Fax: +385 (51) 686 166
www.intechopen.com

InTech China

Unit 405, Office Block, Hotel Equatorial Shanghai
No.65, Yan An Road (West), Shanghai, 200040, China
中国上海市延安西路65号上海国际贵都大饭店办公楼405单元
Phone: +86-21-62489820
Fax: +86-21-62489821

© 2011 The Author(s). Licensee IntechOpen. This chapter is distributed under the terms of the [Creative Commons Attribution-NonCommercial-ShareAlike-3.0 License](https://creativecommons.org/licenses/by-nc-sa/3.0/), which permits use, distribution and reproduction for non-commercial purposes, provided the original is properly cited and derivative works building on this content are distributed under the same license.

IntechOpen

IntechOpen