

We are IntechOpen, the world's leading publisher of Open Access books Built by scientists, for scientists

6,900

Open access books available

185,000

International authors and editors

200M

Downloads

Our authors are among the

154

Countries delivered to

TOP 1%

most cited scientists

12.2%

Contributors from top 500 universities



WEB OF SCIENCE™

Selection of our books indexed in the Book Citation Index
in Web of Science™ Core Collection (BKCI)

Interested in publishing with us?
Contact book.department@intechopen.com

Numbers displayed above are based on latest data collected.
For more information visit www.intechopen.com



Informatics and Computerized Tomography Aiding Detection and Diagnosis of Solitary Lung Cancer

Aristófanês Corrêa Silva¹, Anselmo Cardoso Paiva², Rodolfo Acatauassu Nunes³ and Marcelo Gattass⁴

^{1,2}*Federal University of Maranhão, Applied Computing Group NCA/UFMA, Av. dos Portugueses, S/N, Campus do Bacanga, Bacanga, CEP 65085-580, São Luís - MA*

³*State University of Rio de Janeiro - UERJ, São Francisco de Xavier, 524, Maracanã, CEP 20550-900, Rio de Janeiro, RJ*

⁴*Pontifical Catholic University of Rio de Janeiro - PUC-Rio, R. São Vicente, 225, Gávea, CEP 22453-900, Rio de Janeiro, RJ
Brazil*

1. Introduction

From all malignant tumors, except for non-melanoma skin cancer, lung cancer is the second most common type among men and the most frequent among women. The most worrying characteristic of this kind of cancer, however, is that it has caused more deaths than the sum of the deaths caused by prostate, breast and rectal cancer in developed countries. Patients with lung cancer have a five-year survival rate varying from 13% to 21% in developed countries and varying from 7% to 10% in emerging countries. Only in 2005, 1.3 million deaths were caused by lung cancer throughout the world. In this very same year, the National Institute of Cancer (INCA) registered on the official statistics that lung cancer caused the death of 14,715 people in Brazil. Estimations of this specialized Brazilian organism point that the number of new cases in 2010 will be 17,810 among men and 9,460 among women. Such incidence is still the result of the large consumption of tobacco in the past, and does not reflect the present scenario of reduction of the smoking habit by the people as a result of the preventive actions more recently implemented (INCA, 2009).

Such incidence is still the result of the large consumption of tobacco in the past, and does not reflect the present scenario of reduction of the smoking habit by the people as a result of the preventive actions more recently implemented through the world. One of the causes of the low survival rate from lung cancer is related to difficulty of its precocious diagnosis due to the absence of symptoms and to the poor diagnosis at more advanced stages of the disease (Jamnik et al., 2002). Due to these characteristics, several efforts have been made targeting precocious diagnosis of lung cancer.

The detection of lung cancer in an initial stage has been improved by a wider use of noninvasive image techniques, such as radiography and computerized chest tomography (CT). However, invasive techniques are still necessary to the diagnostic definition that occurs through the cytological and histopathological study of materials obtained via suction puncture or biopsy. In this scenario, where the application of non-invasive techniques gains

special relevance, a large number of computational tools have been employed, such as Computer-aided Detection (CAD) and Computer-aided diagnosis (CADx), developed from image processing and computer vision techniques.

Using digital images generated in the process of acquisition of the CT, it is possible to identify the lung nodule and execute a series of measurements on it, in order to find some correlation among these measurements and its diagnose of malignancy or benignity (Silva et al., 2009). The need to obtain a precise diagnose of the lung nodule in order to provide longer survival to the patient, specially at the starting stage when the tumor still has small dimensions, has incited many researchers to look for new forms of detection and diagnosing with help of a computer (Matsuoka et al., 2005), (Khan et al., 1991), (Vittitoe et al., 1997) and (Wolf et al., 2005). The idea present in those tools is to provide an aid to the specialist doctor, whether to evince suspicious radiological artifacts or to offer a second opinion to the specialist in the diagnosing.

Works as those of (Jeong et al., 2005) and (Reeves & Kostis, 2000) have well demonstrated this task of detection and diagnosing of the lung nodule. There is a set of works in the area of pattern recognition that use texture and morphology as discriminative features of benign and malignant nodules in the diagnosing, such as in (Iwano et al., 2005) and (Seemann et al., 1999), that use the form of the nodule and in (Lo et al., 2003) that use morphology and texture together, aiming to classify the nodule as malignant or benign. Recent researches in the area of image processing with adoption of techniques of exploratory analysis of areas, largely used in geostatistics, have presented promising works, such as (Silva et al., 2005), (Silva et al., 2009) and (Silva et al., 2008), which extract certain texture measurements associated to the lung nodules and are able to discriminate them as malignant and benign with accuracy varying from 80% to 100%. However, this behavior is not perfectly noticed when using more than one CT image database containing a sufficiently large number of lung nodule cases. Given this, new measurements are being adapted to be used in lung nodule diagnosis, aiming to obtain the same behavior when using several CT image databases.

This work presents a methodology for recognition of directional patterns of spatial distribution, having the computer as a tool for diagnose aiding, especially in a precocious manner, when the classic initial characteristics of malignancy are not well defined

The chapter is divided in the following way: Section 2 gives the medical viewpoint of the characteristics of a lung nodule. In Section 3 we show the state of the art of works that do the detection and/or diagnosis of lung nodules. Section 4 exemplifies a tentative of our research team to automatically detect the lung nodule in a CT exam. In Section 5 we show the application of one geostatistical measure and geometric measurements to suggest a diagnosis for the lung nodule. In Section 6 we will give an idea of how we expect CAD/CADx to be applied to CT images in the next years. Finally, in Section 7, we present some final considerations.

2. Medical viewpoint of the diagnosing of the solitary lung nodules by computerized tomography

Lung cancer, associated to the smoking habit in more than 90% of cases, is the leading cause of deaths and, in developed countries, it is responsible for a mortality rate bigger than that of breast, prostate and rectal-colon cancer together, which, despite the large incidence, are more controllable tumors from the therapeutic viewpoint. Perhaps the large amount of cancerous substances carried by the smoke of cigarettes propitiates multiple molecular ways, which represent a greater biological aggressiveness and more difficult therapeutic response. On

the other hand, paradoxically, lung cancer is easier to prevent and decreases in parallel with the reduction of the use of tobacco, such as has been seen world-wide. Unfortunately, in less developed countries, the use of cigars has been increasing, bringing a disease of difficult control, whose five-year survival, after diagnosis, is about 10%, in those locations where health systems are weaker. The best chance to improve the survival in lung cancer is the precocious diagnosis, occasionally done by the detection of anomalies in the bronchial mucosa, the bronchoscopy and, more frequently, by finding the image of a lung nodule.

The solitary lung nodule is defined as an spherical image of up to 3 cm of diameter, not accompanied by lesions that could suggest metastasis or invasion of neighbor structures, traditionally obtained with a simple pulmonary radiography. Nevertheless, since the rise of the first Computerized Tomography prototypes, evolving to the helical technique with a detector and, more recently, multiple detectors (multi slice), it has been possible to diagnose lung nodules which were invisible to simple X-rays.

In general, the more frequent diagnosing, which correspond to more than 80% of the cases of lung nodules, but which can vary according to the characteristics of the population under study, are the tuberculous or fungal granulomas, primary or metastatic lung cancer, the hamatoma and the carcinoid tumor (Franquet et al., 2003). The main consequence of the diagnosing of small nodules is the increase of the possibility of catching lung cancer in a recent stage, what is known to increase the possibility of cure (Hanley & Rubins, 2003), (Lillington & Caskey, 2003). This fact has already its reflections in the present TNM staging system for lung cancer, modified in 2010, and which now covers the so called T1 (tumor with up to 3 cm in diameter) in two sub-categories: T1a (up to 2 cm) and T1b (ranging from 2 to 3 cm), created with the hope of stratify different survivals (Rami-Porta et al., 2009).

Together with all this benefic repercussion in the precocious detection of lung cancer, there appears, on the other hand, a greater diagnostic difficulty, since benign nodules constitute the majority of small nodules. Naturally, if there is not a correct judgment of the lung nodule image, there will be an unnecessary increase of the number of invasive diagnosing procedures, such as punctures with thin and cutting needles, transbronchial biopsy, video-assisted thoracic surgery (VATS) and thoracotomy, methods with several possibilities of complications, but in most cases with no mortality. Thus, all of the attributes of the image must be well evaluated, not only to detect the nodule, but also to help determining its nature. In this context, we may give emphasis to the screening of lung cancer, the measurement of texture and density of the nodule, the dynamical evaluation by the volumetry and contrast impregnation and the fusion of the images obtained by CT and positron emission (PET/CT). The computerized methods for aiding detection and diagnosis, central object of this chapter, are analyzed in the next section.

2.1 Tracking lung cancer through computerized tomography

Despite there is not a definitive proof that the screening by Computerized Tomography decreases the global mortality by lung cancer, various findings tend to serve as a indication that this goal can be achieved, maybe with the association to more than on advanced screening method, such as looking for antibodies in the peripheral blood (Patel et al., 2010).

Studies about screening lung cancer using low-dosage helical computerized tomography have advanced mainly in the USA, especially in New York City, which in a pioneer manner showed the first results in 1999, from an experiment started in 1993. Other studies have also been developed in Canada, Europe and Japan (I.Henschke & Yankelevitz, 2000). Despite some criticisms about the cost-effectiveness of the method and the lack of a control group, the works

have been multiplying and make clear the intention of coming to a standard of effectiveness in order to reduce the mortality by lung cancer (Bellomi et al., 2006).

Detection aiding software can, through well established algorithms, perform the automatic tracking of images with nodular profile, but still find difficulties in the segmentation of nodules close to vessels and the thoracic wall, which demand special techniques. A special advantage would be the diminishment of the errors caused by the radiologist's tiredness, since with modern devices the number of images to be analyzed increased significantly. However, a relatively large number of false positives have been observed and this also testifies that it will always be necessary the radiologist's interpretation. Selecting the group of risk for lung cancer, and in which can be different inclusion criteria, the percentage of lung nodules per patient has been very variable in the literature, achieving even 50%, due to the endemic pulmonary disorders. Nevertheless, most part of these nodules is constituted by benign nodules, about 90% of cases, and so the need for observation has been increasing. In parallel, new diagnosing programs (CADx systems) have been adopted, always intending to increase sensibility, specificity and accuracy in order to make the final judgment easier for the responsible medical (Way et al., 2010).

2.2 Texture of the lung nodule to the computerized tomography

With the rise of the tomographers with multiple detectors, the discovery of nodules has become more and more frequent. These nodules, besides small, have diverse textures. Screening programs have surprise entirely solid, non-solid (fosco glass texture) and mixed nodules, which may have different biological behaviors (Hasegawa et al., 2000). This way, for example, solid nodules are comprised into the whole spectrum between the carcinoma (small and non-small cells) while the non-solid ones are usually represented by adenocarcinomas of the bronchoalveolar subtype, with different biological behavior, normally more indolent. Recent works have showed that the frosted glass texture, though being unspecific, can be the starting form of lung cancer for computerized tomography. On the other hand nodules heavily calcified, with central calcification or popcorn-like calcifications are inherently benign. Nodules which alternate regions of fat density and rough calcifications suggest hamartoma, a benign nodule composed of cartilagenous, osseous and fat tissues, with normal histological aspect.

Nodules with predominance of density of soft parts, where cancer is more incident, need a deeper study, because the human sight is unable to observe the minimal differences on gray tones, which are actually the expression of a certain X-ray attenuation coefficient. Computer programs can do this separation by analyzing the texture of the lung nodules through the statistical study of the component voxels or eventual arrangements they form, each one with its value or intensity. Despite these programs are very promising, they remain under study in the literature being tested against a lung nodule database with known histopathological, cytological or microbiological diagnosis.

2.3 Dynamic evaluation of the lung nodule by the computerized tomography

The dynamic evaluation is characterized by a study in two distinct moments of the same nodule, with or without use of intravenous contrast. The commonest dynamic evaluation without use of contrast is the calculation of the so called doubling time, which implies two volumetric determinations after a certain time interval.

The volumetry of the lung nodule has been considered as an important attribute to study undetermined nodules, especially if there is a screening program. Due to the tri-dimensional

evaluation of the nodule, it establishes more precisely if there was a growing, involution or stabilization, conclusions which have traditionally been taken by the analysis of the diameters of a central tomographic cut, whose limitation is the incapacity to detect variations in other cuts and specially in the z axis. Given the sensibility of the CT, it is possible to make a second measurement in a short period, inclusively in the range below 30 days, and surprise the nodules with doubling time in the spectrum of growing of neoplastic disorders, indicating, so, its resection (Winer-Muram et al., 2002). Classically, doubling times inferior to 45 days have been associated to inflammatory processes and those ranging from 45 to 450 days have been associated to neoplasm (Nathan et al., 1962). Above 450 days the nodules have been considered benign. However, certain tumors of germinative genealogy can have doubling times below 45 days. For a neoplastic lesion, the smaller the doubling time the bigger the biological aggressiveness of the tumor.

The computerized tomography with contrast injection is based on the fact that the vascularization of the malignant nodule is much more prominent than that of the benign one, especially in its central portion, occurrence demonstrated in immunohistochemistry techniques with the use of antibodies anti-factor VIII. Made under standardization, the method featured by Swensen and partners, in 1996, showed, with a cutoff point of 20 Hounsfield Units, a sensibility of 98%, a specificity of 73% and an accuracy of 85% (Christensen et al., 2006). Presently, in a general manner, we consider that a raise of more than 15 to 25 Hounsfield Units (HU), after a contrast injection in standardized conditions to enable comparison, suggests malignancy, but some benign conditions, inflammatory, such as tuberculous granuloma and cryptogenic pneumonia, can also raise the radiologic intensity (Jeong et al., 2005). Lately, more value has been given to the impregnation curve (wash-in) and disimpregnation (wash-out) of contrast as a way to detail and help distinguishing the benign nodules from the malignant one. In practical terms, the absence of impregnation is the most useful dynamic feature, because it decreases significantly the possibility of malignancy, having elevated negative predictive value (Christensen et al., 2006). These conclusions are relativized in nodules smaller than 1 cm.

2.4 Association between computerized tomography and the positron emission tomography (PET)

It has been demonstrated that the PET/CT association (PET integrated to CT) is more adequate than the separate exams to diagnose the nature of the lung nodule. The same way as in other methods, with PET, one has been giving more value to the quantification obtained for the diagnosing, through the so called SUV max (Standardized Uptake Value) which measures the maximum intensity of consumption of the agent marked by the tumored cells in the region of interest. In the case of glucose it is used the 18-deoxy-fluoroglucose (FDG), admitting, usually, as cutoff point the value 2.5 (Martins et al., 2008). Nevertheless, despite the high sensibility, above 90%, the specificity in zones of high incidence of tuberculosis and histoplasmosis stay between 70% and 80%, revealing still a reasonable possibility of false positives, represented specially by the tuberculous granuloma. There has been some research aiming to change glucose, the commonest energetic substrate, by an amino acid to be incorporated to the DNA, as, for example, methionine (11-¹¹C-Methionine), obtaining a smaller incidence of false positives, without sensibility loss (Sasaki et al., 1999). What is special about the value of the PET is its contribution for the simultaneous staging in the case of the malignant nodule, since it has the capability of pointing metastasis in places where other image methods cannot find them. The incorporation of the study with PET

has been recommended in the evaluation of the probability of malignancy by the Bayesian method (Meert, 2010).

3. CAD/CADx lung systems

The development of medical images acquisition techniques, in particular Computerized Tomography (CT), which may furnish more detailed information about the human body, has increased the capability and fidelity in the diagnosing of many diseases. On the other hand, the dimensions of these images are becoming bigger and bigger, increasing the need for computer vision techniques that can make interpretation easier. This Section aims to provide an overview of literature in automatic CT image analysis in the lung region.

The work of (Beigelman-Aubry et al., 2007) presented an evaluation of nodule detection and its response time when performed by radiologists with and without use of a computerized system. The work showed that the system improves the sensibility of the detection, what raised the trust interval in 2%. Among the experiments with 109 patients, there was a nodule which was not detected by one of the radiologists, but was detected by the system. Besides, the use of the system decreases considerably the time required by the specialists to analyze the exams.

This way, nodule detection systems have great importance in this process, despite they don't give the final diagnosis.

Nodule detection systems usually involve 4 steps: pre-processing, extraction of nodule candidates, reduction of false positives and classification. Pre-processing normally consists in restricting the search space, delimiting the lung, and reducing noises in the image. The region of the lung is segmented and nodule candidate objects are identified. Among these objects most of the non-nodules are discarded in the false positive reduction stage. The remaining objects are then classified into nodule and non-nodule. In some methods, the false positive reduction is performed after classification. Some works found in the literature involving these steps are presented next.

(III & Sensakovic, 2004) showed the importance of adequate segmentation of lungs in computer aided detection and/or diagnosing systems. His studies indicated that up to 17% of lung nodules can be lost during lung segmentation if the algorithm is not adjusted to the task of nodule detection.

A great challenge is the segmentation of lungs affected by high density pathologies connected to their bounds. Due to the lack of contrast between these pathologies and the tissues adjacent to the lung, density-based methods fail in this region. In this case, it is necessary some edition technique, but, even so, part of the lung is normally lost (Sluimer et al., 2006).

Due to the large amount of air in the lung, its interior has dark tonality in CT images, differing from the region around it. This way, contrast between lung and neighbor tissues is the basis for most lung segmentation methods. Most methods are based on rules (Hu et al., 2001), (Zheng et al., 2003), (Leader et al., 2003). The lung region can be found in two ways (Sluimer et al., 2006). The first one is by means of region growing starting at trachea. The second one, more usual, used thresholdings and constraints in size and location.

To find nodule candidates, the main techniques used are: multiple thresholding (Armato et al., 1999), (Ko & Betke, 2001), (Zhao & Yankelevitz, 1999), (Zhao et al., 2004), mathematical morphology (Ezoe et al., 2002), (Fetita et al., 2003), (Tanino et al., 2003), (Awai et al., 2004), clustering (Kanazawa et al., 1998), (Gurcan et al., 2002) (Kubo et al., 2002), (Yamada et al., 2003), analysis of connected elements in thresholded images (Oda et al., 2002), (Saita et al., 2004), detection of circles in thresholded images (Wiemker et al., 2002) and use of emphasis

filter with spherical structure elements (Chang et al., 2004), (Li & Doi, 2004), (Paik et al., 2004), (Paik, 2002).

In (Osman et al., 2007), for each slice, regions of interest (ROI) were found by using density values of the pixels and analyzing their eight directions. The joining of all slices formed 3D ROIs, which allows identifying the nodules when compared to a nodule model (template). Sensibility reached 100%, but the test data were restricted to six cases.

(Retico et al., 2008) proposed a system based on emphasis filters for spherical objects and a neural classification based on voxels of selected regions to reduce false positives. The system performance was evaluated in a set of data from 39 CT and reached 80-85% of sensibility and 10-13 FP/exam.

(Bae et al., 2005) developed a Computer Aided Diagnosis (CADx) for high-resolution CT images (HRCT - High-resolution computed tomography) using bi-dimensional and tri-dimensional analysis algorithms. This technique was tested in eight lung cancer cases and obtained 95% of sensibility and 0.91 FP/slice.

To improve the sensibility of the detection, (Li et al., 2008) used an emphasis filter in the identification stage and, to reduce false positives, used a rule-based classifier.

After the nodule candidate objects have been generated, characteristic features of these objects are calculated. Classifiers are then applied. These classifiers use the features to identify candidate objects either in the nodules set or in the non-nodule set.

Several techniques can be used as classifiers in the final stage of nodule detection: based on either rules or linear classifiers (Lee et al., 2001), (Mekada et al., 2003), (Chang et al., 2004), by combining models (template matching) (Brown et al., 2003), analysis of the nearest cluster (Ezoe et al., 2002), (Tanino et al., 2003), support vector machine (Lu et al., 2004), (Mousa & Khan, 2002), (Sousa et al., 2007), neural networks (Suzuki et al., 2008), (Lo et al., 2003), (Zhang et al., 2004) and Bayesian classifier (Farag et al., 2004), (McCulloch et al., 2004). The features mostly used for classification are those based on the density of voxels, description of shapes, spatial relation and size information.

(Sousa et al., 2007) proposed a set of three morphological features specially developed for characterization of lung nodules with which matching rates of 100% were achieved using support vector machine, despite this work used a small database.

In some works, the classifier presents good sensibility, but also a high number of false positives. This way, techniques have been sought, in order to reduce this number after the identification which, in some cases, work as filters before classification.

(Armato et al., 1999) presented a methodology for detection of lung nodules with just the pre-processing stages, detection of candidates and classification. Nodule candidates were found by through multiple thresholding and, next, using shape and density attributes and discriminant linear analysis, the classification detected 70% of the nodules indicated by specialists and 3 false positives per slice in average (approximately 80-90 false positives per exam). In later papers, Armato and co-authors has focused in rules to reduce the number of false positives: rule-based (III et al., 2001), (Arimura et al., 2004), discriminant analysis (Arimura et al., 2004), (III et al., 2002) and neural networks (Arimura et al., 2004), (Suzuki, 2003). The best result obtained by these techniques was of 80.3% in detection rate with 4.8 false positives per exam against 27.4 without false positives reduction (Suzuki, 2003).

(Saita et al., 2004) added to the nodules detection methodology proposed by (Oda et al., 2002) a false positives reduction stage.

(Lee et al., 2004) added the false positive reduction stage to the nodules detection method initially proposed by (Lee et al., 2001). To do this, they added five density attributes and

adjusted the thresholding parameters to the original model. The sensibility continued the same in 72.4% but the FP rate decreases from 30.8 to 5.5 per exam.

False positives reducing is important, because, even if sensibility keeps unaltered, the radiologist's final amount of work is reduced.

4. Lung nodule detection

This section presents, under the form of a sequence of stages, the procedures proposed to perform the detection of lung nodules in a CT in an incremental manner. Another important aspect of the methodology is the adoption of specific strategies for nodule detection in particular conditions, such as nodules linked to the chest wall, aggregated to the bronchi or blood trees, and the single ones.

The proposed methodology corresponds to the application of several successive stages of processing to CT images, eliminating portions of them which do not correspond to interesting areas, in this case, lung nodules. Figure 1 shows the methodology stages. Figure 2 presents a CT slice consecutively submitted to this process. More details about this method in (Sousa et al., 2010)

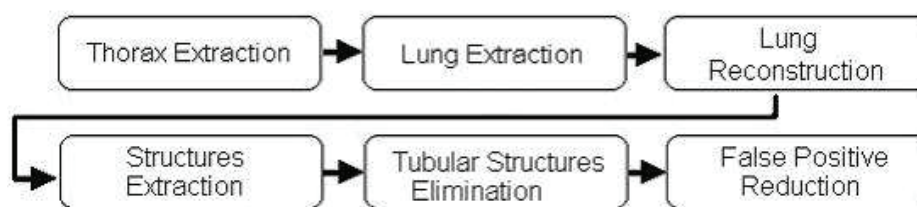


Fig. 1. Methodology Stages.

4.1 Thorax extraction

The process is started with thorax extraction. This stage comprises the removal of all artifacts external to the patient's body, among which are: bed sheets, the air that involves the patient and the surface on which he lies, as example of the items numbered in Figure 2(a).

These structures are identified by a region growing algorithm whose seeds are initially put on the four corners of each slice. The similarity criterion for the algorithm is based on gray tones of the voxels, since great part of the external region of the thorax (which we want to identify) is formed by low intensity voxels.

4.2 Lung extraction

The objective of lung extraction is to identify the thoracic wall and mediastinum voxels, making possible the work on the next stages with just the region which forms the pulmonary parenchyma. That is achieved again with use of the region growing algorithm, this time, however, identifying the high-intensity voxels with values greater than the threshold and with no need for tolerance. The final result, after the growing and elimination of the high intensity voxels can be seen in Figure 2(c).

4.3 Lung reconstruction

Occasionally the lung extraction stage erroneously eliminates some voxels which belong to the pulmonary parenchyma. These mistakes can lead to elimination, inclusively, of

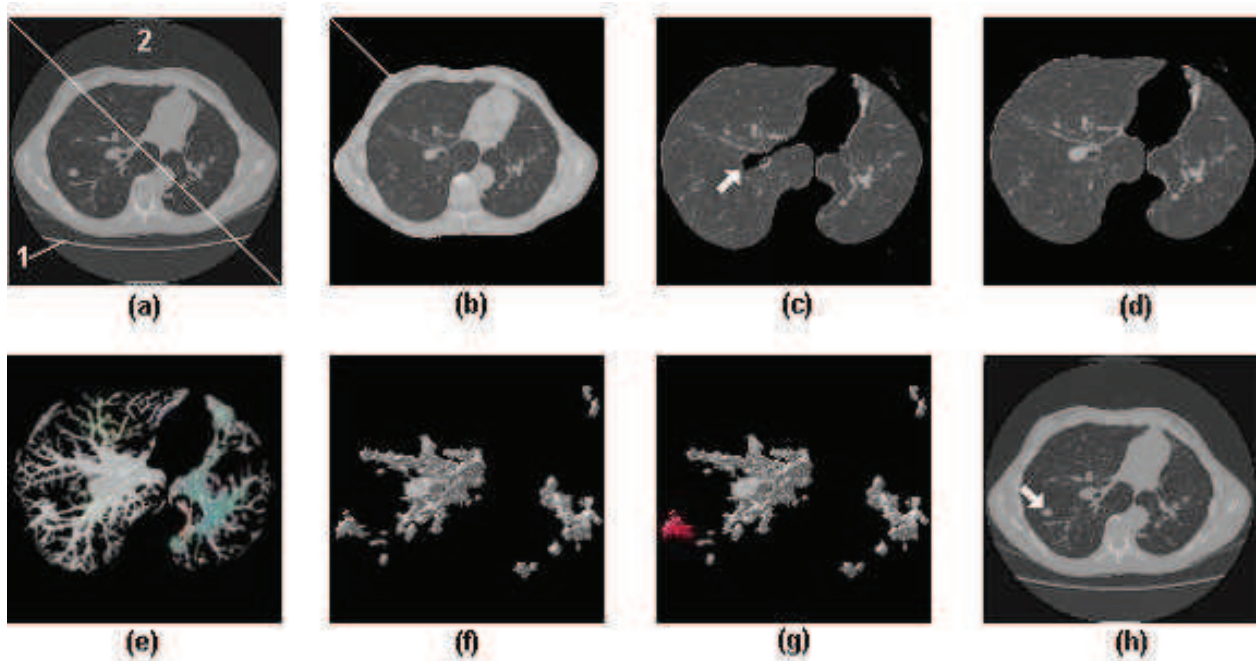


Fig. 2. Automatic lung nodule detection sequence. (a) Eliminates of all artifacts external to the patient's body, identified as 1 and 2 in the figure. (b) Removal of thorax, leaving just the parenchyma. (c) Shows an example of the internal lung region and the thoracic wall erroneously eliminated. (d) Parenchyma reconstructed with rolling-ball algorithm. (e) 3D visualization of the remaining structures after threshold application and identified with different colors. (f) 3D visualization of the structures after tubular elimination. (g) Shows the correct identification of a lung nodule among other normal lung structures which came from the previous stage. (h) Presents the same nodule identified in the original tomography image by an arrow.

possible nodules, inducing an error in detection. This way, the reconstruction stage has great importance for preservation of peripheral nodules.

Figure 2(c) shows an example of an internal lung region and the thoracic wall erroneously eliminated together, due to its high intensity voxels.

In order to recover the correct lungs outlines, this stage uses the rolling-ball algorithm (Gurcan et al., 2002), a mathematical morphology technique based on closing operations executed with a circular structuring element, whose radius, in this specific case, was of thirty pixels. Figure 2(d) shows the result after application this stage.

4.4 Parenchyma structures extraction

The previous stages had the main objective of detecting the pulmonary region, but only in this stage, in fact, the search for internal lung regions occurs. This stage is performed in two steps: the first one identifies and removes the less dense parenchyma tissue out from the image, keeping only its internal structures; the second one isolates each of the tri-dimensional structures found so that they can be individually processed.

The elimination of less dense tissues is performed by means of a thresholding process. The proper threshold is again obtained from the volume voxels histogram, being considered only the parenchyma-internal ones.

Nevertheless, these structures need to be separated individually, before the nodules can be identified. So, each tri-dimensionally connected structure is identified through a region growing algorithm which starts in each voxel of the structures which are not isolated yet. The result of this stage is that every tri-dimensionally connected region can be individually processed from this point. Figure 2(e) shows each tri-dimensional structure identified with distinguished colors. Each color was randomly chosen and has no special meaning. We can notice on it that structures such as blood vessels, bronchi and nodules are preserved, while the major part of the parenchyma is suppressed.

4.5 Tubular structures elimination

We observed that among the objects identified by the 3D connectivity property, there are structures that correspond to the bronchial and vascular trees. Besides, there are cases where each nodule is connected to one or more of these structures. This creates a problem for detection of these nodules, generating the need for identifying the bronchial and vascular trees of the pulmonary parenchyma so that distinguishing these trees from possible nodules can be possible.

Blood vessels are, as a rule, tubular. The depth of the medial axis varies very gradually, inclusively in ramifications. In other words, blood vessels have thickness almost constant in a certain location. Nodules have totally different characteristics. As they are compact structures, they present an abrupt increase in the depth of the medial axis. This is perceived more clearly in spicular nodules. The process consists in verifying to which of both patterns the structures match better. With this objective, observing the structures to be identified, we use an analysis based on their skeleton. This is possible since they resemble very much their medial axis, obtained by means of the 3D skeletonization algorithm proposed in (Sousa et al., 2007).

The bifurcations among the vessels possibly present an increase in the depth of the medial axis, but this increase, besides being small when compared with the diameter of the vessel, is gradual. On the other hand, in the case of aggregated nodules, the increase in the depth of the media axle is much more abrupt and intense. With the correct balance of cutoff thresholds it is possible to come to a stage that results in few false positives or false negatives, with a good sensibility. Anyway, errors generally occur in this stage, making necessary the posterior stage of reducing false negatives and false positives, which, in our case, was based on Support Vector Machine (SVM).

For each individual structure, the skeleton is calculated. After that, all of its segments are scanned sequentially. During the scan of each segment the maximum value of depth is selected and its neighborhood with the same pattern is also selected. The selection of the neighborhood must consider the average depth of the adjacent medial voxels and the variation from one to another, in sequence.

After the region is selected, it is previously evaluated. A very large rate between the length of the selected part of the branch and its thickness clearly indicates a tubular region. However, a great thickness in relation to the length indicates a compact structure, possibly a nodule. An example can be seen in Figure 3(a) where we can notice a nodule connected to several blood vessels. Figure 3(b), on the other hand, presents the same region after the elimination of these vessels.

4.6 False positives reduction

False positives reduction is the stage in which the detection is refined by eliminating the false lung nodules. For that, we used the SVM (Vapnik, 1998) previously trained to recognize the




Fig. 3. Tubular Structures Elimination.

true nodules with basis on a series of descriptive features. This work used features commonly used in other works (Agam et al., 2005), (Lu et al., 2004) and (Peldschus et al., 2005) with the same objective, but with new features as well, especially developed for describing lung nodules and distinguishing them from other pulmonary structures.

The complete list of the studied features is: Geometry (spherical disproportion, spherical density, pondered radial distance, sphericity, elongation, Boyce-Clark radial shape index), Texture (contrast, energy, entropy, homogeneity, moment), histogram (average, standard deviation, skewness, kurtosis, energy, entropy), Gradient (average, standard deviation, skewness, kurtosis, energy, entropy) and Spatial (location of the candidate). More details for all those measurements can be found in (Sousa et al., 2007).

The set of features extracted from every candidate generates a vector which characterizes them. As each features, however, bears on one isolate aspect of the candidate, it occurs that many of them are in different units and frequently in disproportional scales.

To minimize the complexity of the model and speed up the process, we attempted to select a subset of features which are more significant for classification. We empirically tested several subsets of features and verified which one had the best performance. The starting model had 24 variables and after selecting the best subset, there were 8 variables left: geometry (spherical disproportion, spherical density), histogram (standard deviation, skewness, entropy), gradient (standard deviation, kurtosis), spatial (location of candidate).

The adoption of the vector, such as obtained after calculating these features would cause some of them to be overestimated by the SVM classifier due to the numerically greater value, while others, because they vary in smaller intervals, would be underestimated. This way, the features vector must be normalized so that all the features have the same representativeness.

After all candidates have been completely measured and described, each one by a normalized features vector, these vectors are passed to the SVM, which uses the previous knowledge, obtained by the analysis of other seemingly cases, to identify the real nature of each candidate, recognizing them as lung nodules or as normal lung structures. As SVM kernel, we used the radial basis function. The library LIBSVM (Chang et al., 2004) was used for training and validation of the SVM classifiers.

Figure 2(g) shows the correct identification of a lung nodule among other normal lung structures which came from the previous stage. Figure 2(h) presents the same nodule identified in the original tomography image by an arrow.

5. Lung nodule diagnosis

The proposed methodology aims to classify single lung nodules into two groups: benign and malignant. To perform this task, this methodology was based on the steps seen in Figure 4.

The first step is the acquisition of the image, which was obtained from a patient’s chest CT exam. Step 2 is the segmentation of the tri-dimensional volume of the nodule using method describe in Section 4. Right after that, the representative features of the nodules are obtained by the use of the Simpson’s Index, that is, the texture analysis stage combined with the geometric features extraction. This index has not been used in applications of analysis of medical images in order to diagnose. The last step is the classification of the nodules as either benign or malignant by a One-Class SVM. One-Class SVM was chosen because it was little used in such applications. For more information about this method see (Silva et al., 2009).

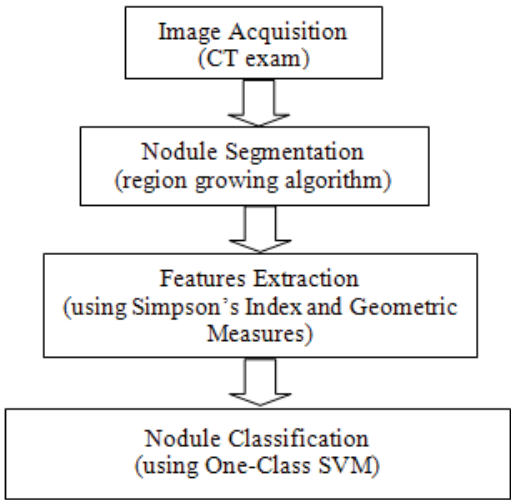


Fig. 4. Methodology Steps.

5.1 Simpson’s index

Simpson’s Index is a second order statistical spatial feature that has been used by Ecology specialists to determine the biodiversity of species in a region (Simpson, 1949). Its main functionality is to summarize the representation of this diversity in a single value capable of qualifying this region as either very heterogeneous or uniform. Simpson’s Index takes into consideration the richness of the species, that is, the number of species present in an area, and still, the regularity of such species, what is a measurement of the relative abundance of each species (Hill, 1973). With these considerations it is possible to analyze which community in a region is more diversified. The Simpson’s Index is the measurement of the probability of two individuals, randomly selected from a sample, to belong to the same species *i* among the existing species *j* in the sample, as in Equation 1 (Ricklefs, 1997).

$$D = \sum_{i=1}^j p_i^2 \tag{1}$$

where $p_i = \frac{n_i}{N}$. For each *i*, it is found the probability (*p_i*) for the occurrence of the species *i*; *n_i* represents the occurrence of individuals from the species *i* and *N* is the total of individuals in the sample. The index is normally used according to Equation 1 when the sample is obtained by sampling process, not being possible to exactly determine the number of individuals in this sample. For a finite sample, where the total amount of individuals is known, the Simpson’s

Index can be obtained, still, through Equation 2 (Lyons et al., 2008).

$$D = \frac{\sum_{i=1}^j n_i(n_i - 1)}{N(N - 1)} \tag{2}$$

The values obtained for the Simpson’s Index are in the interval from 0 to 1, where the value 0 represents infinite diversity in the sample and 1 means that there’s no diversity.

Our proposal is the extraction of Simpson’s Index, as a measurement for texture, taking each voxel found in the volume a possible species under analysis. The distinguishing can be possible due to the morphological behavior of each kind of nodule: benign nodules present, in most cases, a round or well defined shape, while malignant nodules, due to their capability of spreading to other organs present a spicate or less defined shape. As the obtaining of the index will occur in areas of interest, the small occurrence of voxels in a certain area of interest can be related to the shape of this nodule. This way, the benign nodules have a tendency to show a more homogeneous behavior, that is, less diversified in a certain region of study.

5.2 Geometrical measures

The shape of a lung nodule may represent an important indicator of its malignancy or benignity, as we said before. With features geometrical measures is possible to extract and analyze further information identified or not identified by doctors. In this work, three 3D geometry features extracted from each nodule in our database. They are: Spherical Disproportion, Spherical Density and Sphericity. Spherical Disproportion is described in the Equation 3, Spherical Disproportion in Equation 4 and Sphericity in Equation 5. Other information about these measurements can be found in (Sousa et al., 2007).

$$S = \frac{A}{4\pi R^2} \tag{3}$$

$$\varphi = \frac{100.n}{V} \tag{4}$$

$$E = \frac{(6V)^{\frac{2}{3}} \pi^{\frac{1}{3}}}{A} \tag{5}$$

5.3 Validation the classification method

In order to evaluate the methodology with regard to its power of characterizing the proposed groups, we tried to obtain the sensibility (Se), specificity (Sp) and accuracy (Ac) measurements for all analysis performed in the study. Sensibility is given by $TP/(TP + FN)$, specificity is obtained by $TN/(TN + FP)$, and accuracy is given by $(TP + TN)/(TP + TN + FP + FN)$, where TP is true-positive, TN is true-negative, FP is false-positive and FN is false-negative. This way, the malignant lung nodules correctly computed are reported as true positives.

5.4 Experimental tests

We performed the extraction of the texture features by applying Simpson’s Index where the area of interest was represented by circular rings as in Figure 5. Our objective with these forms of extraction is to evaluate the diversity in the edge regions determined by two concentric circles.

We have determined the size of the circles by finding the central point, mass center, of each nodule and then, calculated the distance of this central point to the most distant point of each




Fig. 5. Analysis applied to the nodule by means of circular rings containing 6 external radius.

nodule. This way, we get a R radius that represents a greater possible measurement for the construction of a circle or still, in the analysis by rings, the maximum allowed radius. From the radius R , we got the others values of radiuses as $1/6R$, $1/3R$, $1/2R$, $2/3R$ and $5/6R$. These are represented as $R1$, $R2$, $R3$, $R4$, $R5$ e $R6$ (value of R).

Next, Simpson’s Index of Equation 2 was calculated in each region for a certain ring. We made use of this index because we have quantitative and exact knowledge of the total number of individuals in the sample, that is, the total of voxels in each nodule. In order to increase the discriminatory power of the methodology, we obtained geometry measurements of the nodules which were reported in Section 5.2. Then, we performed the classification considering the Simpson’s Index extracted in each ring, for the analysis by rings aggregating to each analysis the geometry measurements.

A library for SVM, called LIBSVM (Chang & Lin, 2003), was used for training and testing the One-Class SVM classifier (Schölkopf et al., 2001). During the classification stage, four different proportions for the training and test subgroups were used: 50/50, 60/40, 70/30 and 80/20, where the first number represents the percentage of cases used in training(Tr) and the second number represents the percentage of cases used in test(Te). The cases used in each subgroup were randomly selected from the total number of database.

The results shown in Table 1 were obtained in each Tr/Te proportion for each region in analysis in rings and indicate that in ring A1 the best values of sensibility, specificity and accuracy were found: 100%, 80% and 90%, respectively in Tr/Te proportion of 80/20. The use of geometry aided to put this boundary region in evidence as discriminant between malignant and benign nodules.

	Tr/Te = 50/50			Tr/Te = 60/40			Tr/Te = 70/30			Tr/Te = 80/20		
	Se %	Sp %	Ac %	Se %	Sp %	Ac %	Se %	Sp %	Ac %	Se %	Sp %	Ac %
R1	0	100	50	50	70	60	100	3.33	51.67	100	80	90
R2	50	76.67	63.33	75	73.33	74.17	66.67	83.33	75	100	46.67	73.33
R3	25	90	57.5	25	90	57.5	100	63.33	81.67	100	63.33	81.67
R4	75	60	67.5	75	60	67	33.33	66.67	50	100	43.33	71.67
R5	50	63.33	56.67	75	63.33	69.17	66.67	40	53.33	50	83.33	66.67

Table 1. Results found for all group Tr/Te in each region in the analysis in rings.

The Table 2 display the results of the sensibility averages, specificity and accuracy obtained in each group Tr/Te for the analysis in rings. The best found result was of the group 80/20, which obtained values of 90% of sensibility, 63.33% of specificity and 76.67% of accuracy.

Tr/Te	Se (%)	Sp (%)	Ac (%)
50/50	40.00	78.00	59.00
60/40	60.00	71.33	65.67
70/30	73.33	51.33	62.33
80/20	90.00	63.33	76.67

Table 2. Results found to averages of the sensibility, specificity and accuracy obtained in group Tr/Te for the analysis in rings.

6. Future directions

Several researchers believe that Computer-aided Detection (CAD) and Computer-aided Diagnosis (CADx) systems will become an increasingly important tool for radiologists in the early detection of lung cancer using CT images. Besides this feeling, we may see that there are several challenges in the development and use of such systems.

One of the main challenges is the use of these systems for early detection of lung cancer reducing the number of false positive, that often lead to unnecessary invasive medical procedures and produce high levels of anxiety among patients who fear they have a tumor.

The challenges posed by CT-based lung CAD are exponential. With multidetector chest CT, which generates hundreds of images, lung CAD highlights multiple findings for each study. But we can notice that the newer developments in lung CAD technology for CT images have dramatically reduced the false positive rates.

The challenges posed by CT-based lung CAD are exponential. With multidetector chest CT, which generates hundreds of images, lung CAD highlights multiple findings for each study. But we can notice that the newer developments in lung CAD technology for CT images have dramatically reduced the false positive rates.

Eliminating the nuisance of false-positives makes the technology much more manageable in the clinical setting, especially with preferences for increased sensitivity.

Decreasing the false positive rate while maintaining a high degree of sensitivity in these systems is also a problem facing CAD/CADx systems. We may observe that in general the CAD/CADx systems report good sensitivity but at the expense of high false positive rates.

These systems are satisfactorially used as second readers. But, the sensibility must be improved if we intend, in the future, to use these systems as the first reader.

Although the introduction of low-dose helical computed tomography (CT) is considered to be one of the most promising clinical research developments, another direction in the development of CAD/CADx systems is the introduction of other imaging modalities for lung cancer detection, diagnosis, staging, and treatment monitoring.

Hence, great efforts have been made to develop new bronchoscopic imaging techniques (Yasufuku, 2010). Bronchoscopic imaging techniques capable of detecting preinvasive lesions and currently available in clinical practice include autofluorescence bronchoscopy (AFB), high magnification bronchovideoscope, and narrow band imaging (NBI). And also the combination of PET and CT.

Finally, we believe that CAD/CADx systems must be integrated into radiology training programs to help radiologists getting comfortable with such systems.

7. Final remarks

We have presented here a methodology to use CT images combined with computational methods (image processing, computational vision and pattern recognition) to aid the specialists in the detection and another for diagnosis of lung cancer.

The matching rates discussed demonstrate that there is technical viability for implantation of the methodologies. Concerning the needs for it, statistics related to lung cancer clearly indicate that methods for helping in precocious diagnosis of lung nodule may increase the patient's survival chances.

Due to the high sensitivity per exam, this tool has triage exam characteristics, that is, belongs to the first set of exams to be required, which identify the suspicious cases, but need to be confirmed later, by more strict exams, in this case, the medical analysis.

Since precocious diagnosis represents a considerable increase in the patient's survival chances, the proposal of methodologies that promotes this increase, as it is shown as a very useful tool for the specialist in the attempt to anticipate more and more the nodule identification.

Another point is that the public network of hospitals in some places suffers from the lack of specialists. The resources to increase the staff, however, are also limited. Redirecting qualified craft of the available specialists to less repetitive tasks may mean making better use of their skills. One step in that direction is to use the methodologies like these in the preliminary analysis of CT exams, being the specialist just in charge of validating the result.

Finally, we may verify that methodologies as described here in also is a financially attractive solution because it works on simple microcomputers, many of which are already available in the hospitals. Large investments in infrastructure would not be necessary for its implantation. Actually, there is a debate on the magnitude of the impact of such systems currently in clinical use. But, on the other hand we may also see that we cannot afford to ignore their potential benefits.

We may observe that more emphasis must be given to the CAD/CADx observed studies, in order to allow them to reach their full potential. Also, we need the development of novel methods for reducing the number of false positive detections, and integrate these systems into medical education.

These systems are intended to assist radiologists, but not replace them. The radiologist should be the final judge in determining the final assessment. But all the effort to develop technologies that assist then in making more accurate interpretations should be encouraged, as this will generate several benefits to women's health.

8. References

- Agam, G., III, S. G. A. & Wu, C. (2005). Vessel tree reconstruction in thoracic ct scans with application to nodule detection., *IEEE Trans. Med. Imaging* 24(4): 486–499.
- Arimura, H., Katsuragawa, S., Suzuki, K., Li, F., Shiraishi, J., Sone, S. & Doi, K. (2004). Computerized scheme for automated detection of lung nodules in low-dose CT images for lung cancer screening, *Academic Radiology* 11: 617–629.
- Armato, S. G., Giger, M. L., Moran, C. J., Blackburn, J. T., Doi, K. & MacMahon, H. (1999). Computerized detection of pulmonary nodules on CT scans, *Radiographics* 19(5): 1303–1311.
- Awai, K., Murao, K., Ozawa, A., Komi, M., Hayakawa, H., Hori, S. & Nishimura, Y. (2004). Pulmonary nodules at chest ct: Effect of computer-aided diagnosis on radiologists detection performance, *Radiology* 230: 347–352.

- Bae, K. T., Kim, J.-S., Na, Y.-H., Kim, K. G., & Kim, J.-H. (2005). Pulmonary nodules at chest ct: Effect of computer-aided diagnosis on radiologists detection performance, *Radiology* 236: 286–293.
- Beigelman-Aubry, C., Raffy, P., Yang, W., Castellino, R. A. & Grenier, P. A. (2007). Computer-aided detection of solid lung nodules on follow-up mdct screening: evaluation of detection, tracking, and reading time., *AJR. American journal of roentgenology* 189(4): 948–955.
URL: <http://dx.doi.org/10.2214/AJR.07.2302>
- Bellomi, M., Rampinelli, C., Funicelli, L. & Veronesi, G. (2006). Screening for lung cancer, *Cancer Imaging* 6: S9–S12.
- Brown, M. S., Goldin, J. G., Suh, R. D., McNitt-Gray, M. F., Sayre, J. W. & Aberle, D. R. (2003). Lung micronodules: Automated method for detection at thin-section CT-initial experience 1, *Radiology* 226: 256–262.
- Chang, C.-C. & Lin, C.-J. (2003). LIBSVM – a library for support vector machines. Available at <http://www.csie.ntu.edu.tw/~cjlin/libsvm/>.
- Chang, S., Emoto, H., Metaxas, D. & A., L. (2004). Pulmonary micronodule detection from 3-d chest ct, *Lecture Notes in Computer Science - Medical Image Computing and Computer-Assisted Intervention* 3217: 821–828.
- Christensen, J. A., Nathan, M. A., Mullan, B. P., Hartman, T. E., Swensen, S. J. & Lowe, V. J. (2006). Characterization of the solitary pulmonary nodule: 18-fdg pet versus nodule enhancement CT., *Am J Roentgenology* 187(5): 1361–1367.
- Ezoe, T., Takizawa, H., Yamamoto, S., Shimizu, A., Matsumoto, T., Tateno, Y., Iimura, T. & Matsumoto, M. (2002). Automatic detection method of lung cancers including ground-glass opacities from chest x-ray ct images, Vol. 4684, SPIE, pp. 1672–1680.
URL: <http://link.aip.org/link/?PSI/4684/1672/1>
- Farag, A., El Baz, A., Gimel'farb, G. & Falk, R. (2004). Detection and recognition of lung nodules in spiral ct images using deformable templates and bayesian post-classification, *ICIP04*, pp. V: 2921–2924.
- Fetita, C. I., Prêteux, F., Beigelman-Aubry, C. & Grenier, P. (2003). 3d automated lung nodule segmentation in hrct, *Medical Image Computing and Computer-Assisted Intervention - MICCAI 2003* 2878(2878): 626–634.
- Franquet, T., Muller, N., Gimenez, A., Martinez, S., Madrid, M. & Domingo, P. (2003). Infectious pulmonary nodules in immunocompromised patients: usefulness of computed tomography in predicting their etiology., *J Comput Assist Tomogr* 27: 461–8.
- Gurcan, M. N., Sahiner, B., Petrick, N., Chan, H. P., Kazerooni, E. A., Cascade, P. N. & Hadjiiski, L. M. (2002). Lung nodule detection on thoracic computed tomography images: Preliminary evaluation of a computer-aided diagnosis system, *Medical Physics* pp. 2552–2558.
- Hanley, K. S. & Rubins, J. B. (2003). Classifying solitary pulmonary nodules. new imaging methods to distinguish malignant, benign lesions, *Postgraduate medicine* 114(2): 29–35.
- Hasegawa, M., Sone, S., Takashima, S., Li, F., Yang, Z.-G., Maruyama, Y. & Watanabe, T. (2000). Growth rate of small lung cancers detected on mass CT screening, *The British Journal of Radiology* 73: 1252–1259.
- Hill, M. O. (1973). Diversity and evenness: a unifying notation and its consequences., *Ecology* 54: 427–432.

- Hu, S., Hoffman, E. A. & Reinhardt, J. M. (2001). Automatic lung segmentation for accurate quantitation of volumetric x-ray ct images, *IEEE Transactions on Medical Imaging* 20: 490–498.
- I.Henschke, C. & Yankelevitz, D. F. (2000). Ct screening for lung cancer, *Radiologic Clinics of North America* 38(3): 487–495.
- III, S. G. A., Giger, M. L. & MacMahon, H. (2001). "Automated detection of lung nodules in CT scans: Preliminary results", *Medical Physics* 28: 1552–1561.
- III, S. G. A., Li, F., Giger, M. L., MacMahon, H., Sone, S. & Doi, K. (2002). Lung cancer: Performance of automated lung nodule detection applied to cancers missed in a CT screening program, *Radiology* 225: 685–692.
- III, S. G. A. & Sensakovic, W. F. (2004). Automated lung segmentation for thoracic ct: Impact on computer-aided diagnosis, *Academic radiology* 11: 1011–1021.
- INCA, N. I. (2009). Estimativa 2008: Incidência de câncer no Brasil. Instituto Nacional do Cancer. In Portuguese. URL: www.inca.gov.br.
- Iwano, S., Nakamura, T., Kamioka, Y. & Ishigaki, T. (2005). Computer-aided diagnosis: A shape classification of pulmonary nodules imaged by high-resolution ct, *Computerized Medical Imaging and Graphics* 29(7): 565–570.
- Jamnik, S., Santoro, I. L. & Uehara, C. (2002). Comparative study of prognostic factors among longer and shorter survival patients with bronchogenic carcinoma, *Pneumologia [online]* 28(5): 245 – 249.
- Jeong, Y. J., Lee, K. S., Jeong, S. Y., Chung, M. J., Shim, S. S., Hojoong, K., Kwon, O. J. & S, K. (2005). Solitary pulmonary nodule: characterization with combine wash-in and washout features of dynamic multidetector row CT., *Radiology* 2(237): 675–683.
- Kanazawa, K., Kawata, Y., Niki, N., Satoh, H., Ohmatsu, H., Kakinuma, R., Kaneko, M., Moriyama, N. & Eguchi, K. (1998). Computer-aided diagnosis for pulmonary nodules based on helical CT images, *Computerized Medical Imaging and Graphics* 22: 157–167.
- Khan, A., Herman, P. G., Vorwerk, P., Stevens, P., Rojas, K. A. & Graver, M. (1991). Solitary pulmonary nodules: comparison of classification with standard, thin-section, and reference phantom ct, *Radiology* 179(2): 477–481.
URL: <http://radiology.rsna.org/content/179/2/477.abstract>
- Ko, J. P. & Betke, M. (2001). Chest CT : Automated nodule detection and assessment of change over time - preliminary experience, *Radiologic Clinics of North America* 218: 267–273.
- Kubo, M., Kubota, K., Yamada, N., Kawata, Y., Niki, N., Eguchi, K., Ohmatsu, H., Kakinuma, R., Kaneko, M., Kusumoto, M., Mori, K., Nishiyama, H. & Moriyama, N. (2002). Cad system for lung cancer based on low-dose single-slice ct image, in M. Sonka & J. M. Fitzpatrick (eds), *Society of Photo-Optical Instrumentation Engineers (SPIE) Conference Series*, Vol. 4684 of *Presented at the Society of Photo-Optical Instrumentation Engineers (SPIE) Conference*, pp. 1262–1269.
- Leader, J. K., Zheng, B., Rogers, R. M., Sciurba, F. C., Perez, A., Chapman, B. E., Patel, S., Fuhrman, C. R. & Gur, D. (2003). Automated lung segmentation in x-ray computed tomography: development and evaluation of a heuristic threshold-based scheme, *Academic Radiology* 10(11): 1224–1236.
- Lee, Y., Hara, T., Fujita, H., Itoh, S. & Ishigaki, T. (2001). Automated detection of pulmonary nodules in helical ct images based on an improved template-matching technique.
- Lee, Y., Tsai, D.-Y., Hara, T., Fujita, H., Itoh, S. & Ishigaki, T. (2004). Improvement in automated detection of pulmonary nodules on helical x-ray ct images, in J. M. Fitzpatrick & M. Sonka (eds), *Society of Photo-Optical Instrumentation Engineers (SPIE) Conference*

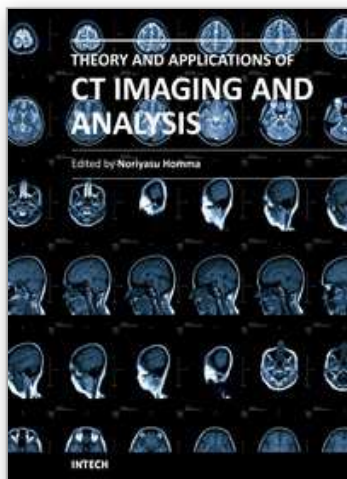
- Series, Vol. 5370 of *Presented at the Society of Photo-Optical Instrumentation Engineers (SPIE) Conference*, pp. 824–832.
- Li, Q. & Doi, K. (2004). "New selective nodule enhancement filter and its application for significant improvement of nodule detection on computed tomography", in J. M. Fitzpatrick & M. Sonka (eds), *Society of Photo-Optical Instrumentation Engineers (SPIE) Conference Series*, Vol. 5370 of *Presented at the Society of Photo-Optical Instrumentation Engineers (SPIE) Conference*, pp. 1–9.
- Li, Q., Li, F. & Doi, K. (2008). Computerized detection of lung nodules in thin-section ct images by use of selective enhancement filters and an automated rule-based classifier, *Academic radiology* 15(2): 165–175.
- Lillington, G. A. & Caskey, C. I. (2003). Evaluation and management of solitary and multiple pulmonary nodules, *Clinics in chest medicine* 114: 111–9.
- Lo, S.-C. B., Hsu, L.-Y., Freedman, M. T., Lure, Y. M. F. & Zhao, H. (2003). Classification of lung nodules in diagnostic ct: an approach based on 3d vascular features, nodule density distribution, and shape features, Vol. 5032, SPIE, pp. 183–189.
URL: <http://link.aip.org/link/?PSI/5032/183/1>
- Lu, X., Wei, G.-Q., Qian, J. Z. & Jain, A. K. (2004). Learning-based pulmonary nodule detection from multislice ct data, *CARS*, p. 1356.
- Lyons, D. J., P.M.Dunworth & Tilbury, D. W. (2008). Simpson's diversity index, Available at <http://www.countrysideinfo.co.uk/simpsons.htm>.
- Martins, R. D. C., Almeida, S. A. A. D., Siciliano, A. A. A. D. O., Landesmann, M. C. P. P., Silva, F. A.-c. B.D., Franco, C. A. d. B. & Fonseca, L. M. B. d. (2008). Valor do fdg [18f]-pet/tc como preditor de ca em nódulo pulmonar solitário, *Jornal Brasileiro de Pneumologia* 34: 473 – 480. In Portuguese.
URL: <http://www.scielo.br/>
- Matsuoka, S., Kurihara, Y., Yagihashi, K., Niimi, H. & Nakajima, Y. (2005). Peripheral solitary pulmonary nodule: Ct findings in patients with pulmonary emphysema1, *Radiology* 235(1): 266–273.
URL: <http://radiology.rsna.org/content/235/1/266.abstract>
- McCulloch, C. C., Kaucic, R. A., Mendonça, P. R., Walter, D. J. & Avila, R. S. (2004). Model-based detection of lung nodules in computed tomography exams1: Thoracic computer-aided diagnosis, *Academic radiology* 11(3): 258–266.
- Meert, A.-P. (2010). Pulmonary nodule: a bayesian approach, *Revue medicale de Bruxelles* pp. 117–21.
- Mekada, Y., Kusanagi, T., Hayase, Y., Mori, K., ichi Hasegawa, J., ichiro Toriwaki, J., Mori, M. & Natori, H. (2003). Detection of small nodules from 3d chest x-ray ct images based on shape features, *CARS*, pp. 971–976.
- Mousa, W. & Khan, M. (2002). Lung nodule classification utilizing support vector machines, *ICIP02*, pp. III: 153–156.
- Nathan, M. H., Collins, V. P. & Adam, R. A. (1962). Differentiation of benign and malignant pulmonary nodules by growth rate, *Radiology* 79: 221–32.
- Oda, T., Kubo, M., Kawata, Y., Niki, N., Eguchi, K., Ohmatsu, H., Kakinuma, R., Kaneko, M., Kusumoto, M., Moriyama, N., Mori, K. & Nishiyama, H. (2002). "Detection algorithm of lung cancer candidate nodules on multislice CT images", in M. Sonka & J. M. Fitzpatrick (eds), *Society of Photo-Optical Instrumentation Engineers (SPIE) Conference Series*, Vol. 4684 of *Presented at the Society of Photo-Optical Instrumentation Engineers (SPIE) Conference*, pp. 1354–1361.

- Osman, O., Ozekes, S. & Ucan, O. N. (2007). Lung nodule diagnosis using 3d template matching, *Comput. Biol. Med.* 37(8): 1167–1172.
- Paik, D., Beaulieu, C., Rubin, G., Acar, B., Jeffrey, R., Yee, J., Dey, J. & Napel, S. (2004). Surface normal overlap: A computer-aided detection algorithm with application to colonic polyps and lung nodules in helical ct, *MedImg* 23(6): 661–675.
- Paik, D. S. (2002). *Computer Aided Interpretation of Medical Images*, PhD thesis, Stanford University.
- Patel, K., EC, F., AW, K., BS, L., S, B., JS, C., D, D., L, T., KA, W., C, F., C, C., SH, C., LP, F., P, B., MJ, L. & JA, B. (2010). Enhancement of a multi-analyte serum biomarker panel to identify lymph node metastases in non-small cell lung cancer with circulating autoantibody biomarkers, *International journal of cancer. Journal international du cancer*.
- Peldschus, K., Herzog, P., Wood, S. A., Cheema, J. I., Costello, P. & Schoepf, U. J. (2005). Computer-aided diagnosis as a second reader: Spectrum of findings in ct studies of the chest interpreted as normal, *Chest* 128: 1517–1523.
- Rami-Porta, R., Iey, J. J., JJ, C. & Goldstraw, P. (2009). The revised tnm staging system for lung cancer., *Ann Thor. Cardiovasc. Surg.* 15: 4–9.
- Reeves, A. P. & Kostis, W. J. (2000). Computer-aided diagnosis of small pulmonary nodules, *Seminars in Ultrasound, CT, and MRI* 21(2): 116 – 128. The Solitary Pulmonary Nodule.
- Retico, A., Delogu, P., Fantacci, M. E., Gori, I. & Preite Martinez, A. (2008). Lung nodule detection in low-dose and thin-slice computed tomography, *Comput. Biol. Med.* 38(4): 525–534.
- Ricklefs, R. E. (1997). *Estrutura da comunidade*, 3 edn, Guanabara Koogan, Rio de Janeiro, chapter 22, pp. 344–346.
- Saita, S., Oda, T., Kubo, M., Kawata, Y., Niki, N., Sasagawa, M., Ohmatsu, H., Kakinuma, R., Kaneko, M., Kusumoto, M., Eguchi, K., Nishiyama, H., Mori, K. & Moriyama, N. (2004). "Nodule detection algorithm based on multislice CT images for lung cancer screening", in J. M. Fitzpatrick & M. Sonka (eds), *Society of Photo-Optical Instrumentation Engineers (SPIE) Conference Series*, Vol. 5370 of *Presented at the Society of Photo-Optical Instrumentation Engineers (SPIE) Conference*, pp. 1083–1090.
- Sasaki, M., Kuwabara, Y., Ichiya, Y., Akashi, Y., Yoshida, T., Nakagawa, M., Murayama, S. & Masuda, K. (1999). Differential diagnosis of thymic tumors using a combination of ¹¹c-methionine pet and fdg pet., *J Nucl Med* 40(10): 1595–601.
- Schölkopf, B., Platt, J., Shawe-Taylor, J., Smola, A. & Williamson, R. (2001). Estimating the Support of a High-Dimensional Distribution, *Neural Computation* 13(7): 1443–1471.
- Seemann, M. D., Staebler, A., Beinert, T., Dienemann, H., Obst, B., Matzko, M., Pistitsch, C. & Reiser, M. F. (1999). Usefulness of morphological characteristics for the differentiation of benign from malignant solitary pulmonary lesions using hrct, *European Radiology* 9(3): 409–417.
- URL: <http://www.springerlink.com/content/bwmmf72udk9nfa4x/>
- Silva, A. C., da Silva, E. C., de Paiva, A. C. & Nunes, R. A. (2005). Diagnosis of lung nodule using Moran's Index and Geary's Coefficient in computerized tomography images. Submitted to Pattern Analysis and Applications.
- Silva, C. A., Silva, A. C., Netto, S. M. B., de Paiva, A. C., Junior, G. B. & Nunes, R. A. (2009). Lung nodules classification in ct images using simpson's index, geometrical measures and one-class svm, *MLDM*, pp. 810–822.

- Silva, E. C., Silva, A. C., de Paiva, A. C., Nunes, R. A. & Gattass, M. (2008). Diagnosis of solitary lung nodules using the local form of ripley's k function applied to three-dimensional ct data, *Computer Methods Programs in Biomedicine*. 90(3): 230–239.
- Simpson, E. H. (1949). Mensurement of diversity., *Nature* 163: 688.
- Sluimer, I., Schilham, A., Prokop, M. & van Ginneken, B. (2006). Computer analysis of computed tomography scans of the lung: a survey, *Medical Imaging, IEEE Transactions on* 25(4): 385–405.
URL: <http://dx.doi.org/10.1109/TMI.2005.862753>
- Sousa, J. R. F. S., Silva, A. C. & Paiva, A. C. (2007). Lung structure classification using 3d geometric measurements and svm., *Progress in Pattern Recognition, Image Analysis and Applications*, Vol. 4756, Springer Berlin / Heidelberg, pp. 783–792. Book Series: Lecture Notes in Computer Science.
- Sousa, J. R. F. (2007). *Metodologia automática para detecção de nódulos pulmonares*, Master's thesis, Universidade Federal do Maranhão. In Portuguese.
- Sousa, J. R. F., Silva, A. C., de Paiva, A. C. & Nunes, R. A. (2010). Methodology for automatic detection of lung nodules in computerized tomography images, *Computer Methods and Programs in Biomedicine* 98(1): 1 – 14.
URL: <http://www.sciencedirect.com/science/article/B6T5J-4X30C13-1/2/a002a6f4726e17552c7290b1d27ed137>
- Suzuki, K. (2003). Massive training artificial neural network (mtann) for reduction of false positives in computerized detection of lung nodules in low-dose computed tomography, *Medical Physics* 30: 1602–+.
- Suzuki, K., Shi, Z. & Zhang, J. (2008). Supervised enhancement of lung nodules by use of a massive-training artificial neural network (mtann) in computer-aided diagnosis (cad), *ICPR08*, pp. 1–4.
- Tanino, M., Takizawa, H., Yamamoto, S., Matsumoto, T., Tateno, Y. & Iinuma, T. (2003). A detection method of ground glass opacities in chest x-ray ct images using automatic clustering techniques, in M. Sonka & J. M. Fitzpatrick (eds), *Society of Photo-Optical Instrumentation Engineers (SPIE) Conference Series*, Vol. 5032 of Presented at the Society of Photo-Optical Instrumentation Engineers (SPIE) Conference, pp. 1728–1737.
- Vapnik, V. N. (1998). *Statistical Learning Theory*, Wiley-Interscience.
URL: <http://www.amazon.ca/exec/obidos/redirect?tag=citeulike04-20&path=ASIN/0471030031>
- Vittitoe, N. F., Baker, J. A. & Floyd, C. E. (1997). Fractal texture analysis in computer-aided diagnosis of solitary pulmonary nodules, *Academic Radiology* 4(2): 96–101.
- Way, T., Chan, H.-P., Hadjiiski, L., Sahiner, B., Chughtai, A., Song, T. K., Poopat, C., Stojanovska, J., Frank, L., Attili, A., Bogot, N., Cascade, P. N. & Kazerooni, E. A. (2010). Computer-aided diagnosis of lung nodules on ct scans: Roc study of its effect on radiologists' performance, *Academic radiology* 17(3): 323–332.
- Wiemker, R., Rogalla, P., Zwartkruis, A. & Blaffert, T. (2002). Computer-aided lung nodule detection on high-resolution ct data, in M. Sonka & J. M. Fitzpatrick (eds), *Society of Photo-Optical Instrumentation Engineers (SPIE) Conference Series*, Vol. 4684 of Presented at the Society of Photo-Optical Instrumentation Engineers (SPIE) Conference, pp. 677–688.
- Winer-Muram, H. T., Jennings, S. G., Tarver, R. D., Aisen, A. M., Tann, M., Conces, D. J. & Meyer, C. A. (2002). Volumetric growth rate of stage i lung cancer prior to treatment: serial ct scanning, *Radiology* pp. 798–805.

- Wolf, M., Krishnan, A., Salganicoff, M., Bi, J., Dundar, M., Fung, G., Stoeckel, J., Periaswamy, S., Shen, H., Herzog, P. & Naidich, D. P. (2005). Cad performance analysis for pulmonary nodule detection on thin-slice mdct scans, *International Congress Series* 1281: 1104–1108. CARS 2005: Computer Assisted Radiology and Surgery.
- Yamada, N., Kubo, M., Kawata, Y., Niki, N., Eguchi, K., Omatsu, H., Kakinuma, R., Kaneko, M., Kusumoto, M., Nishiyama, H. & Moriyama, N. (2003). Roi extraction of chest ct images using adaptive opening filter, in M. Sonka & J. M. Fitzpatrick (eds), *Society of Photo-Optical Instrumentation Engineers (SPIE) Conference Series*, Vol. 5032 of Presented at the Society of Photo-Optical Instrumentation Engineers (SPIE) Conference, pp. 869–876.
- Yasufuku, K. (2010). Early diagnosis of lung cancer, *Clinics in Chest Medicine* 31(1): 39–47.
- Zhang, X., McLennan, G., Hoffman, E. A. & Sonka, M. (2004). Computerized detection of pulmonary nodules using cellular neural networks in ct images, *Medical Imaging 2004: Image Processing*, San Diego, CA, USA.
- Zhao, B., Ginsberg, M. S., Lefkowitz, R. A., Jiang, L., Cooper, C. & Schwartz, L. H. (2004). Application of the ldm algorithm to identify small lung nodules on low-dose msct scans, Vol. 5370, SPIE, pp. 818–823.
URL: <http://link.aip.org/link/?PSI/5370/818/1>
- Zhao, B. & Yankelevitz, D. (1999). Two-dimensional multi-criterion segmentation of pulmonary nodules on helical CT images, *Medical Physics* 26(6): 889–895.
- Zheng, B., III, J. K. L., Maitz, G. S., Chapman, B. E., Fuhrman, C. R., Rogers, R. M., Sciurba, F. C., Perez, A., Thompson, P., Good, W. F. & Gur, D. (2003). A simple method for automated lung segmentation in x-ray ct images, Vol. 5032, SPIE, pp. 1455–1463.
URL: <http://link.aip.org/link/?PSI/5032/1455/1>

IntechOpen



Theory and Applications of CT Imaging and Analysis

Edited by Prof. Noriyasu Homma

ISBN 978-953-307-234-0

Hard cover, 290 pages

Publisher InTech

Published online 04, April, 2011

Published in print edition April, 2011

The x-ray computed tomography (CT) is well known as a useful imaging method and thus CT images have continually been used for many applications, especially in medical fields. This book discloses recent advances and new ideas in theories and applications for CT imaging and its analysis. The 16 chapters selected in this book cover not only the major topics of CT imaging and analysis in medical fields, but also some advanced applications for forensic and industrial purposes. These chapters propose state-of-the-art approaches and cutting-edge research results.

How to reference

In order to correctly reference this scholarly work, feel free to copy and paste the following:

Aristófanés Corrêa Silva, Anselmo Cardoso Paiva, Rodolfo Acatauassu Nunes and Marcelo Gattass (2011). Informatics and Computerized Tomography Aiding Detection and Diagnosis of Solitary Lung Cancer, Theory and Applications of CT Imaging and Analysis, Prof. Noriyasu Homma (Ed.), ISBN: 978-953-307-234-0, InTech, Available from: <http://www.intechopen.com/books/theory-and-applications-of-ct-imaging-and-analysis/informatics-and-computerized-tomography-aiding-detection-and-diagnosis-of-solitary-lung-cancer>

INTECH
open science | open minds

InTech Europe

University Campus STeP Ri
Slavka Krautzeka 83/A
51000 Rijeka, Croatia
Phone: +385 (51) 770 447
Fax: +385 (51) 686 166
www.intechopen.com

InTech China

Unit 405, Office Block, Hotel Equatorial Shanghai
No.65, Yan An Road (West), Shanghai, 200040, China
中国上海市延安西路65号上海国际贵都大饭店办公楼405单元
Phone: +86-21-62489820
Fax: +86-21-62489821

© 2011 The Author(s). Licensee IntechOpen. This chapter is distributed under the terms of the [Creative Commons Attribution-NonCommercial-ShareAlike-3.0 License](https://creativecommons.org/licenses/by-nc-sa/3.0/), which permits use, distribution and reproduction for non-commercial purposes, provided the original is properly cited and derivative works building on this content are distributed under the same license.

IntechOpen

IntechOpen