

We are IntechOpen, the world's leading publisher of Open Access books Built by scientists, for scientists

6,900

Open access books available

185,000

International authors and editors

200M

Downloads

Our authors are among the

154

Countries delivered to

TOP 1%

most cited scientists

12.2%

Contributors from top 500 universities



WEB OF SCIENCE™

Selection of our books indexed in the Book Citation Index
in Web of Science™ Core Collection (BKCI)

Interested in publishing with us?
Contact book.department@intechopen.com

Numbers displayed above are based on latest data collected.
For more information visit www.intechopen.com



Object and Scene Recognition Impairments in Patients with Macular Degeneration

Muriel Boucart¹ (PhD) and Thi Ha Chau Tran^{1,2} (MD)

¹*Laboratoire de Neurosciences et Pathologies Fonctionnelles, CNRS, université Lille Nord de France*

²*Service d'Ophtalmologie, Hôpital Saint Vincent de Paul, Lille France*

1. Introduction

1.1 Macular degeneration: clinical aspects

Age-related macular degeneration (AMD) is the leading cause of irreversible blindness. (Klaver, et al 1998, Klein 2007). The disease adversely affects quality of life and activities of daily living, causing many affected individuals to lose their independence in their retirement years. It is estimated that, in the USA, over 8 million people have some stage of AMD, with hundred of thousands of people aged 75 or over developing some stage of AMD over any 5-year period. (Klein, et al 1997) Preventive measures are needed to reduce the burden of this disease. AMD affects the region with the highest density of photoreceptors: the macula, about 6 mm in diameter, covering the central 15-20° of the visual field. International classification and grading system for AMD proposes to separate features termed either early, and late age-related macular degeneration (Klein, et al 1992) with the term age-related macular degeneration (AMD) being reserved for late AMD. Early AMD is defined as degenerative disorder in individuals over 50 years of age. Ophthalmoscopy reveals yellow subretinal deposits called soft drusen (large, $\geq 63\mu\text{m}$), or retinal pigment epithelial irregularities including hyperpigmentation or hypopigmentation changes. (Bird, et al 1995). Many aspects of visual function, not just visual acuity, show a decline with normal aging, including dark adaptation, stereopsis, contrast sensitivity, sensitivity to glare, and visual field tests. Late AMD is associated with visual loss, and divided into a non-neovascular atrophic type (dry AMD, geographic atrophy), and a neovascular (wet) type. In atrophic AMD, gradual disappearance of the retinal pigment epithelium results in one or more patches of atrophy that slowly enlarge and coalesce. Geographic atrophy is defined as any sharply delineated round or oval area of hypo or hyperpigmentation or apparent absence of the retinal pigment epithelium, in which choroidal vessels are more visible than the surrounding areas and which is $\geq 1\text{mm}$ in diameter in funduscopy. (Sarks, et al 1988). An illustration is shown in Figure 1. Geographic atrophy involving the center of the macula leads to progressive visual loss. Development of geographic atrophy is associated with subsequent further growth of atrophy. For instance, a study by Lindblad et al (2009) showed that from a median initial lesion size of 4.3 mm^2 , average change from baseline geographic atrophy was 2.03 mm^2 at 1 year, 3.78 mm^2 at 2 years, 5.93 mm^2 at 3 years (1.78 mm^2 per year). Average visual acuity decreased by 22 letters after 5 years. Affected areas

have no visual function since loss of the retinal pigment epithelium is associated with fallout of photoreceptors. The only proven treatment available for the dry forms of the disease, compassing 85% of cases, is an antioxidants/mineral supplement that can slow the progression of the disease by 25% over 5 years (Age-Related Eye Disease Study Research Group 2001)

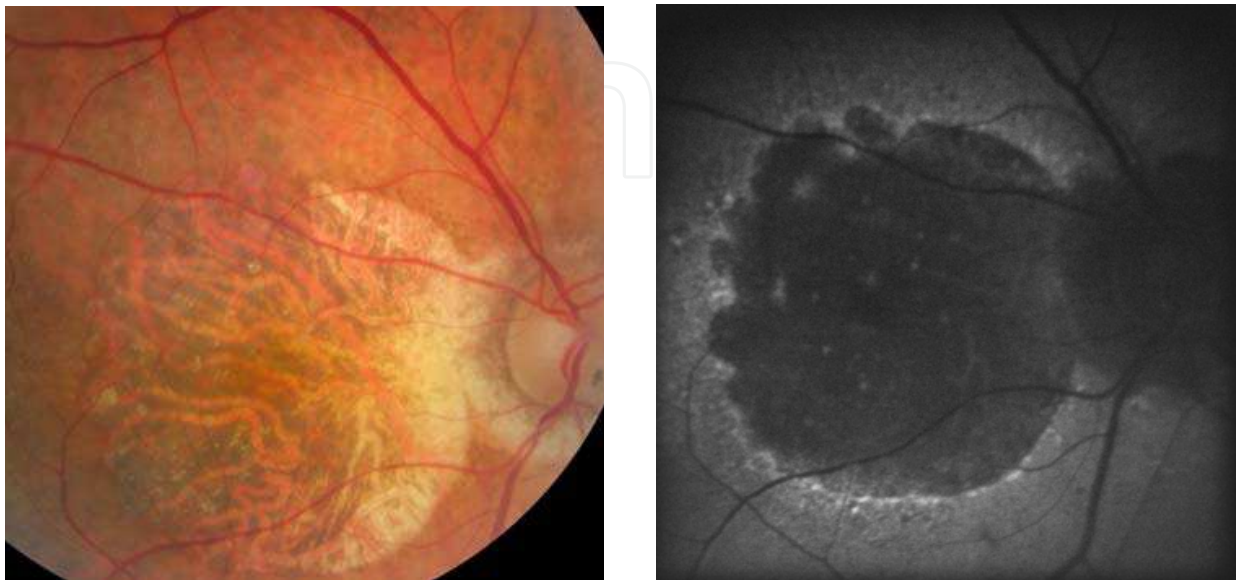


Fig. 1. Fundus photography (left) and fundus autofluorescence (right) of a patient suffering from advanced atrophic AMD. Visual acuity was reduced to “counting fingers” at 1m.

In the wet AMD (or exudative or neovascular), vision loss appear suddenly, when a choroidal neovascular membrane leaks fluid or blood into the subpigment epithelial or subretinal space. Approximately 10% to 15% of AMD manifest the neovascular form of the disease (Ferris, *et al* 1984). Patients complain of decreased vision, micropsia, metamorphopsia, the presence of a scotoma, see a simulation on Figure 2.

Macular degeneration is associated with severe vision loss at advanced stages. If the advanced stage of both types of AMD is noted in one or both eyes, then rehabilitation with a low-vision department should be considered to determine which activity or device will help the individual to cope with the visual loss. At advanced stage, once the spatial resolution of the fovea cannot be used, and fixation is controlled, a preferred retinal location (PRL) is developed. The location of the PRL depends upon the geographic distribution of the lesion although it tends to develop in a functional retinal area near the edge of the scotoma (Crossland *et al* 2004; 2005; Cheung & Legge, 2005 for a review). At the end of its evolution, AMD affects all the functions of central vision: acuity, color vision, high spatial resolution, contrast sensitivity, posture and mobility (Wood *et al* 2009; Hassan *et al.*, 2002).

AMD leads to a central scotoma, a region of diminished vision within the visual field, which can be absolute or relative depending on the degree of central vision loss. The scotoma may cause centrally presented images to appear darker, blurred, and even contain black or grey holes (see Figure 2) (Schumacher *et al.* 2008). As the macula is responsible for high spatial resolution the patients' ability to obtain information about the environment is reduced. Patients with visual loss resulting from AMD often report AMD as the worst medical problem and have a diminished quality of life (Alexander, *et al* 1988, Mangione, *et al* 1999). The lower quality of life in patients with AMD is related to greater emotional distress, worse

self reported general health, and greater difficulties carrying out daily activities. These people report increased difficulty for everyday tasks like reading, driving, cooking, watching TV, recognizing faces and facial expressions, pictures and finding objects especially when the illumination level is low and during the transition from bright to dim illumination (Hart et al., 1999; Brody et al., 2001; Holzschuch et al 2002; Hassan et al., 2002; Bullimore et al 1991; Peli et al 1991; Tejeira et al., 2002; Boucart et al 2008a). Vision-related Quality of Life questionnaires (Mangione et al 2001; Cahill et al 2005) report that patients suffering from AMD also encounter more difficulties than do age matched normally sighted individuals when shopping (i.e., finding objects on shelves), managing money and performing light housework. Therefore, understanding the visual processes impaired, and those spared, is critical for efficient cognitive re-habilitation and for maintaining a relative autonomy in this population.




Fig. 2. Simulation of a view of a scene : (left) a scene as viewed by a person with normal vision. Middle: a scene as viewed by a person with metamorphopsia. Right: a scene as viewed by a person with central scotoma. Picture taken from: www.canadian-health.ca

In the present chapter we will focus on the cognitive aspects of the visual impairments encountered by people with low vision consecutive to macular degeneration, and particularly on visual object and scene perception. Indeed, with only few exceptions (Hogervorst & van Damme 2008; Boucart et al 2008b), research on people with AMD has been focused on investigations of low-level processes with simple static stimuli like gratings, shapes, letters and in word perception and reading (Legge et al., 1985; 1992; Wang et al 2002). Yet, the natural environment is made of dynamic scenes, which put different requirements on the observer in terms of selecting relevant features (colors, contours, texture, spatial layout, figure/ground discrimination,...) that are necessary to quickly understand the meaning of a scene (gist) as well as object search for instance. How do people with central vision loss recognize objects and scenes? Is central vision necessary for scene gist recognition? Does color and context (the surrounding of objects) facilitate or impair object and scene recognition? We summarize three studies (Boucart et al., 2008b; Tran et al 2010; Tran et al 2011) addressing these questions.

Visual acuity is not uniform across the visual field. Neurophysiological studies show that the density of cone photoreceptors, responsible for high resolution perception, decreases considerably as eccentricity increases. The fovea contains the highest density of cones. Their number drops to about 50% at 1.75° from the fovea and to less than 5% at 20° from the fovea (Curcio et al, 1991). The receptive fields are larger in periphery leading to loss of spatial resolution. As a consequence of its low spatial resolution, peripheral vision is far less capable of fine discrimination even after its low spatial resolution has been compensated for

by increase in size (M-Scaling, Saarinen, et al. 1987; Näsänen & O'Leary 1998), contrast enhancement (Makela et al, 2001) and increased temporal integration (Swanson et al. 2008). Moreover, crowding is known to be more pronounced in the periphery (Pelli et al 2004). Crowding refers to the decreased visibility of a visual target in the presence of nearby objects or structures (Levi 2008; Pelli 2008). It impairs the ability to recognize objects in clutters. This has been demonstrated with letters, digits, bars and gabor stimuli (Bouma 1970; Strasburger et al 1991; Fellisbert et al 2005). Figure/ground segregation is also impaired in peripheral vision (Thompson et al 2007). In daily life normally sighted people are not aware of the limitations in spatial resolution in peripheral vision because eye movements place the high resolution of foveal vision in different parts of the visual field. In people with AMD the central scotoma follows eye movements and only the low resolution of peripheral vision remains.

We (Tran et al 2010) examined whether scene gist recognition can be accomplished by low resolution peripheral vision in people with central vision loss. The question of the contribution of central versus peripheral vision on scene gist recognition has been addressed by Larson and Loschky (2009) in normally sighted observers. They presented participants with photographs of real world scenes ($27^\circ \times 27^\circ$ of visual angle) for 106 ms each. Each scene was followed by a name (e.g., river). Participants were asked to decide if the scene matched the name. Performance was compared in two conditions: a window condition showing the central portion of the scene and blocking peripheral information and a scotoma condition blocking out the central portion and showing only the periphery. The radii of the window and scotoma were 1, 5, 10.8 and 13.6° . Performance was barely above chance in the 1° window condition suggesting that foveal vision is not useful for recognizing scene gist. Accuracy increased as the radius of the window increased. Conversely, when participants had information from everything but not foveal vision (in the 1° scotoma condition), performance was equal to seeing the entire image. Based on these data the authors suggested that peripheral (and parafoveal vision) is more useful than high resolution foveal vision for scene gist recognition.

We investigated scene categorization in people with central vision loss. Performance was compared for two spatial properties: a categorization based on naturalness (natural versus urban scenes) and a categorization in terms of indoor versus outdoor scenes. Though these two properties are considered as holistic or global (i.e, the categorization can be based on the overall layout; Greene & Oliva 2009a; 2009b), studies on young normally sighted observers have shown longer categorization times for indoor vs outdoor scenes than for naturalness (Joubert et al 2007); likely due to the fact that a more local (object) analysis is required to discriminate between indoor and outdoor scenes whilst a coarse perception based on orientation and color is sufficient to decide if a scene is natural or urban.

27 patients with a confirmed diagnosis of wet and dry AMD and 17 age matched controls were recruited. Inclusion and exclusion criteria and clinical and demographic data are detailed in Tran et al (2010). Participants were tested monocularly, on the best eye for patients and on the preferred eye for controls.

The stimuli were photographs of natural scenes. Two scene properties were selected: naturalness (natural/urban scenes) and indoor/outdoor scenes. Examples are shown in Figure 3. The angular size of the photographs was $15^\circ \times 15^\circ$ at a viewing distance of 1 m. A black fixation cross (5°) was centrally displayed for 500 ms and followed by a single photograph of a scene centrally displayed for 300 ms. Participants were given a target for each categorization task. For naturalness, urban scenes were chosen as target for half of the

participants and natural scenes for the other half of the participants. The same procedure was used for indoor/outdoor scenes. A scene appeared every 3 seconds. Participants were asked to press a key as soon as they saw a picture corresponding to the pre-defined target. There were 100 trials/category (50 targets (e.g. natural scenes) and 50 distractors (e.g., urban scenes)).



Fig. 3. Examples of indoor/outdoor scenes and natural/urban scenes used in the scene categorization task.

The percentage of correct detections of the target is displayed in Figure 4. The results show that patients with AMD were on average more accurate for natural/urban scenes than for indoor/outdoor scenes whilst performance did not differ significantly between the two categories for age matched controls. False alarms were higher in the indoor/outdoor category than for natural/urban category in both groups of participants but, on average, did not exceed 11%. A detailed description of the results can be found in Tran et al (2010).

The results indicate that scene gist recognition can be accomplished with low resolution peripheral vision as patients with central vision loss were able to recognize scenes with high accuracy in two types of categorization : natural vs urban scenes and indoor vs outdoor scenes. The results therefore confirm Larson and Loschky's (2009) data with artificial scotomas in normally sighted people, and extend them to real scotomas varying from 5° to 30° eccentricity in our patients. The head was not fixed in our study. As the stimuli always appeared at the same spatial location patients with a large scotoma might have moved their head to place the image in their preferred retinal location which is adjacent to the scotoma in AMD (see Cheung & Legge 2005 for a review). This means that scene gist is available at low spatial resolution (in peripheral vision) and even when local information, object

identification, might help to distinguish between the two categories (i.e., a bed is more likely to be found indoor and a bike is more likely to be found outdoor). No correlation was found between performance and clinical variables such as the size of the lesion, visual acuity and the type of AMD. Performance is usually found to be related to the size of absolute scotoma when high spatial resolution is required to perform a task, in reading speed and in reading acuity for instance (Ergun et al 2003).

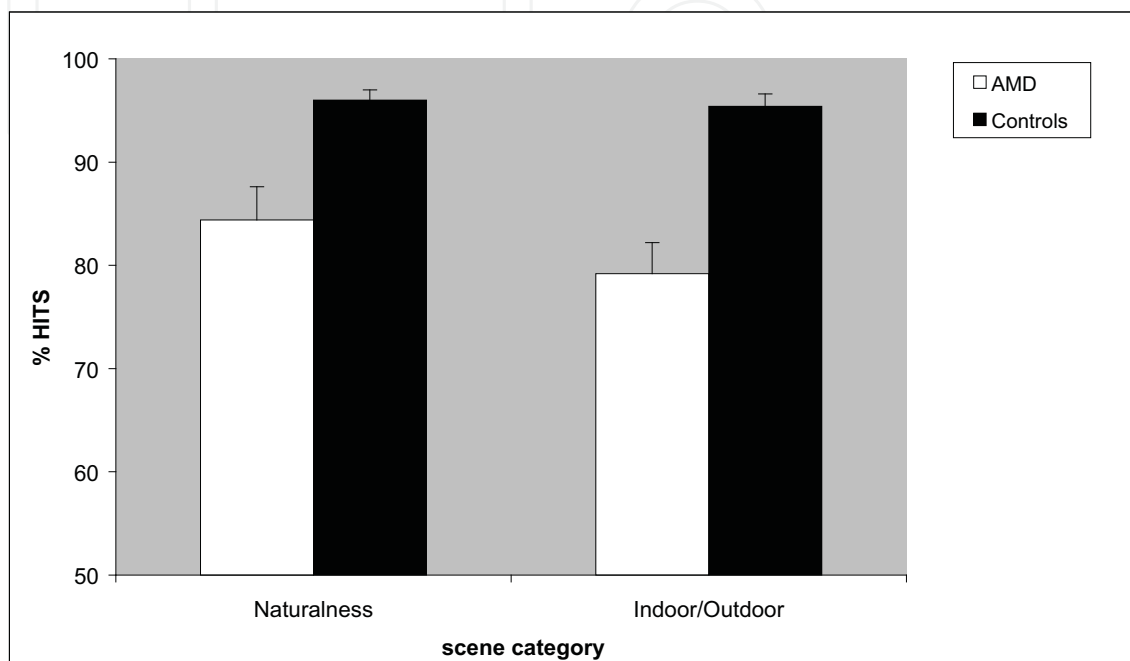


Fig. 4. Percentage of correct detections (Hits) of the target scenes as a function of the category of scene (natural/urban and indoor/outdoor) for patients with AMD and age matched normally sighted controls (adapted from Tran et al 2010).

The scene-centered approach (Oliva, 2005; Greene and Oliva 2009a; 2009b) suggests that the initial visual representation constructed by the visual system is at the level of the whole scene and not at the level of objects. Instead of local geometric and part based visual primitives this account posits that global properties reflecting scene structure, layout and function act as primitives for scene categorization. Processing is considered as global if it builds a representation that is sensitive to the overall layout and structure of a visual scene. Many properties in the natural environment can be global and holistic in nature. For instance, the processing of orientation is sufficient to discriminate a urban from a natural landscape. Consistent with this proposal modelling work has shown success in identifying complex photographs of real world scenes from low level features, such as orientation, and color, or more complex spatial layout properties such as texture, mean depth and perspective (Oliva & Torralba, 2001, Torralba & Oliva, 2002, 2003 Fei-Fei et al 2005; Vogel & Schiele 2007).

Greene and Oliva (2009a) suggested the possibility that the brain is able to rapidly calculate robust statistical summaries of features like the average orientation of a pattern in an automatic fashion and outside the focus of attention. This might explain the advantage observed, in patients with AMD, for naturalness as compared to indoor/outdoor scenes, and also that, within naturalness, urban scenes were categorized faster and more accurately

than natural scenes. Indeed, urban scenes (cities with high buildings in our set of images cf Figure 3) were more homogeneous than natural scenes which included rivers, mountains, deserts, forests, beach.... An advantage for naturalness, over indoor/outdoor scenes, has been reported in other studies. Naturalness classification had the fastest categorization threshold in Greene and Oliva's (2009b) study and the fastest response times in Joubert et al. (2007) study. An explanation for this difference is that a low resolution is sufficient to discriminate between natural and urban scenes but a higher resolution is needed for basic level scene categorization such as discrimination between sea, mountain, forests, indoor and outdoor scenes. Our results are consistent with the notion that the initial scene representation is based on global properties and not on the objects it contains as central vision is reduced in AMD and object recognition is impaired.

2. The effect of color on object and scene perception

In normally sighted people there is disagreement about whether color facilitates object recognition or not. Ostergaard and Davidoff (1988) reported that objects were recognized equally fast irrespective of whether they were properly colored or not. Biederman and Ju (1988) failed to find any advantage of color over black and white outline drawings of objects in a naming task and an object verification task, thus supporting edge-based models of object recognition. Delorme et al. (2000) asked normally sighted young participants to make a rapid categorization (animal/non animal or food/non food objects) of briefly displayed (32 ms) colored or achromatic grey level photographs of natural scenes. They found no effect of color leading to the suggestion that the first wave of visual information is essentially coarse and achromatic. Other studies have attempted to determine the conditions in which color information might help object recognition. Three main factors have been investigated: structural similarity, color diagnosticity and degraded shape information. Price and Humphreys (1989) reported that object naming and categorization were facilitated by color, as compared with grey levels, when objects were structurally similar in shape (e.g. orange vs. grapefruit). Rossion and Pourtois (2004) also found that the advantage provided by color was larger for objects structurally similar in shape and for natural objects with a diagnostic color (e.g., a red strawberry) but they reported that man-made objects also benefited from color irrespective of whether they had a single diagnostic color (e.g. a fire engine) or not. The effect of color diagnosticity has been demonstrated in several other studies both with objects (Tanaka & Presnell, 1999; Theriault et al 2009) and with photographs of natural scenes (Oliva & Schyns, 2000), but Gegenfurtner and Rieger (2000) found that recognition accuracy was higher for colored images than for luminance-matched grey level images for all categories: natural scenes and scenes including man-made objects such as cities. Color has been found to help object recognition or object categorization under degraded visual conditions. For instance, at 60° eccentricity where spatial resolution is very low Naili et al (2006) reported a better performance for colored than for grey level photographs of objects in a task requiring participants to decide whether an object was edible or not. Other studies have reported that observers profit from color for recognizing photographs of natural scenes degraded by low pass filtering (Oliva & Schyns, 2000) or by visual noises made by combining the Fourier phase spectra of the natural images with a random phase spectrum using the inverse Fourier transform at different coherence levels (Liebe et al 2009).

Few studies have examined how people with low vision perceive and recognize objects and scenes. Ebert et al. (1986) examined functional visual performance in 52 patients with low

vision. The participants were tested with practical tasks such as currency discrimination, color recognition, reading a clock and reading large prints. They found a correlation between Snellen acuity and functional vision. Owsley and Sloane, (1987) measured contrast thresholds for gratings varying on spatial frequencies and contrast thresholds for both the detection and identification of three categories of stimuli (faces, road signs and various common objects). Participants increased the contrast by key pressing until something was just detectable on the screen, and then, they were asked to continue to increase the contrast until identification. The pictures had been seen at optimal contrast before threshold measurement. They found that, for real world targets, acuity was poorly correlated to threshold performance. In contrast the best predictors of contrast thresholds were age and decreased contrast sensitivity at middle-to-low spatial frequencies (i.e., 0.5 to 6 cpd). Wurm et al (1993) examined whether people with low vision benefit from color in object recognition. They compared performance in a naming task for isolated colored vs achromatic pictures of objects in normally sighted people and in people with various types of retinopathies including macular degeneration, cataract, glaucoma and diabetic retinopathy. They reported that people with low vision exhibit a greater advantage in terms of accuracy and response times than normally sighted participants for colored objects, showing that color improves object recognition in low vision. This result was confirmed, and extended to photographs of natural scenes by Boucart et al (2008b). Patients with AMD (including wet and dry AMD) and age matched controls were tested in a categorization task in which they were asked to press a response key when they saw either a target animal or a target face (faces and animals were presented in separate blocks of trials). The stimuli were displayed centrally for 300 ms each. Target animals or faces appeared randomly within photographs containing neither animals nor faces. Performance was compared in four experimental conditions: colored versus grey level photographs of natural scenes and colored versus grey level photographs of isolated object extracted from the photographs of scenes. As can be seen from Figure 5 normally sighted people were not affected by whether the stimuli were colored or not. In contrast, people with low vision benefited significantly from color for both faces and animals.

Wurm et al (1993) used food objects for which color is diagnostic (e.g., to discriminate a tomato from a peach). Our results show that color facilitated the detection of both types of targets (faces and animals) in participants with low vision whilst it had less effect on performance in normally sighted people.

Color perception is classically considered as a function of central vision because the highest density of cones is located in the fovea. However, several studies (Newton & Eskew, 2003; Sakurai et al., 2003; Naili et al 2006) have shown that, at large eccentricities (above 20°) color perception is better than what should be expected from the distribution of L, M and S cones in the retina, likely due to post-receptoral cortical processes. Psychophysical, electrophysiological and histopathological findings indicate that the loss of rods is greater than the loss of cones in the macula of patients with AMD (Curcio et al 2000; Owsley et al, 2000) and post mortem examination of the retina of patients with AMD show that only cones remained at a late stage (Curcio et al. 1996; Jackson et al. 2002). This might explain why patients with AMD benefited from color in our experiment.

It has been reported that the visual system tends to perceive chromatic information at coarser scales better than luminance information. For instance, Oliva and Schyns (2000) measured the gain in categorization performance that arose from the addition of color cues to luminance information at different spatial scales. Normally sighted young participants were asked to categorize filtered (0.5 to 8 cycles per degree) color-diagnostic scenes (e.g.,

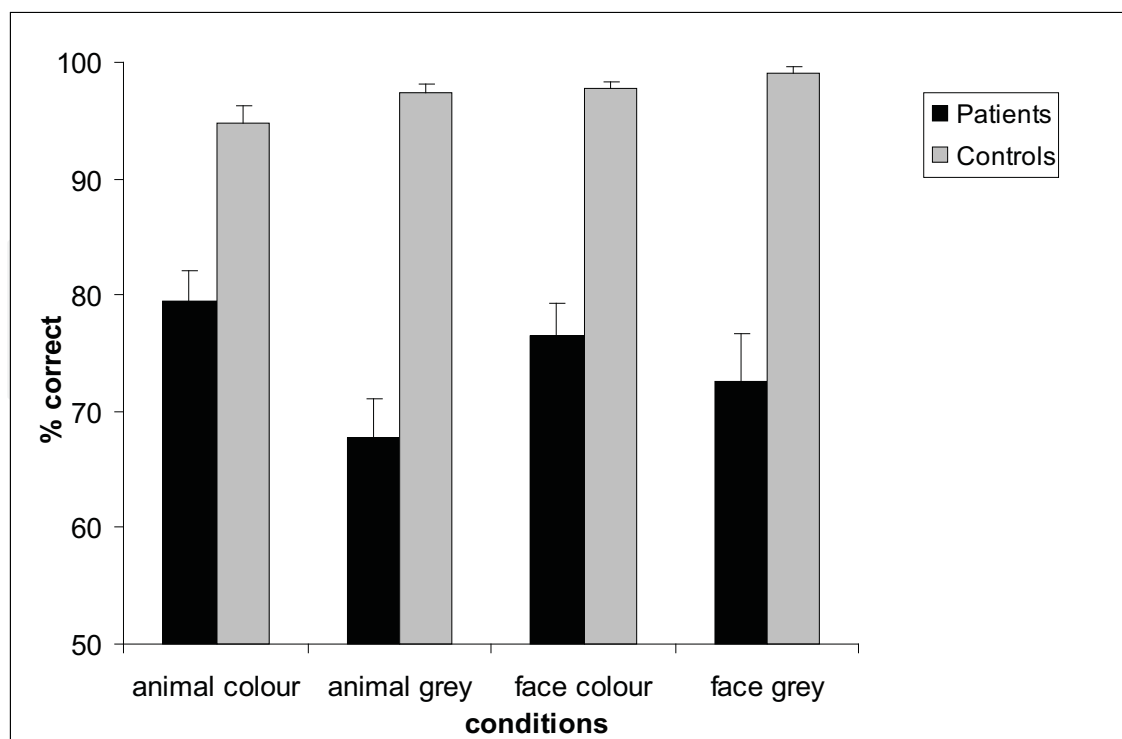


Fig. 5. Performance of patients with AMD and age matched controls for colored and grey level target animals and faces. From Boucart et al (2008b) with permission from Visual Neuroscience.

forest, desert, canyon...), non diagnostic color scenes (e.g., highway, shopping area, bedroom...) and grey levels scenes. They found that color enhances categorization at coarse spatial scales suggesting that color facilitates the initial segmentation of the image. Segmentation refers to the process of segregating a complex scene into its constituent regions, surfaces and objects. Two mechanisms have been suggested to underlie the advantage of color for image recognition: at early stages color helps define spatial contours, surfaces and boundaries, irrespective of what the exact color of the object is (Fine et al 2003; Hansen & Gegenfurtner 2006). The role of color for segmentation is particularly important in cases in which contours and regions are poorly defined by variations in luminance alone, as when visual noise is added (Liebe et al 2009). At a later stage of visual processing it has been proposed that color can act as an additional retrieval cue (Gegenfurtner & Rieger 2000; Wichmann et al 2002; Spence et al 2006).

Our results are consistent with Oliva and Schyns (2000) and Liebe et al (2009) suggestion. As perception of shapes, and particularly perception of detailed information conveyed by high spatial frequencies is degraded in AMD (Sjostrand & Frisue, 1977; Kleiner et al., 1988; Midena et al., 1997; Faubert & Overbury, 2000) people with AMD seem to rely more on color than normally sighted people for contour extraction and scene segmentation.

3. The effect of background on object recognition

As mentioned above some studies have examined object perception in people with low vision (e.g., Wurm et al, 1993; Ebert et al, 1986; Owsley & Sloane 1987) but with pictures of objects in isolation on a white background. Yet, objects in the world rarely appear without

some background. Objects are always located within a setting and within other objects. Boucart et al (2008b) explored how low vision affects perception of objects in scenes. They compared performance for photographs of isolated objects and for the same objects in their natural environments in patients with AMD and age-matched normally sighted people. Photographs were presented for 300 ms each and observers were asked to press a key when they saw an animal or a face in separate sessions. The results showed that people with AMD were more accurate for isolated objects, or faces, than for the same objects, or faces, in their natural setting. Normally sighted people were equally accurate for the two versions of images but they were faster for objects in their natural setting than for isolated objects. This better performance for isolated objects in people with AMD was interpreted in terms of a higher sensitivity to crowding in people with central vision loss who must rely on their peripheral vision as the detrimental effect of crowding is more pronounced in peripheral vision (Bouma 1970, Leat et al 1999, Levi 2008; Pelli et al 2004).

We (Tran et al. 2011) explored further the nature of the impairment in discriminating a figure from its background in patients with AMD. Crowding has been suggested as a contributor to slow and difficult peripheral reading in previous studies on people with central vision loss. However, two studies (Chun et al. (2008) and Calabrese et al (2010)) in which line spacing was increased reported little benefit in patients with AMD, as long as line separation is approximately 1 to 1.25X the standard line separation. We examined whether introducing a space between an object and its background would reduce crowding, as it does in reading, and help figure/ground discrimination in people with low vision. To this aim we compared performance for detecting a target object in a photograph of a scene, for detecting a target object when it is isolated on a white background and for detecting a target object when it is separated from the background by a white space.

It has been reported that the magnitude of crowding is affected by the configural properties of the surrounding. For instance, Livne and Sagi (2007) found that crowding was reduced, and even disappeared, when the flankers of a target stimulus were arranged in a continuous complete circular configuration as compared to the same configuration without closure. Based on this finding we compared performance for a target object located in a structured background (a natural setting) versus for a target object located in a non-structured shapeless background. Studies on normally sighted young observers have shown that an object is more easily detected on a structured background that is consistent with the object (e.g., a toaster in a kitchen) than when the object is located on a non structured meaningless background (Biederman et al, 1972; Boyce et al 1989; Boyce & Pollatsek, 1992). If the background, appearing in peripheral vision, is processed efficiently in people with AMD then we expected a better performance for a target located on a structured background than for the same object in a noise background. We also examined whether exploration time facilitates object recognition and figure ground segregation in patients with central vision loss in manipulating the exposure time of the stimuli (300 ms versus 3000 ms).

The participants were 17 patients with a confirmed diagnosis of neovascular AMD and 17 normally sighted age-matched controls. The inclusion and exclusion criteria and the clinical and ophthalmologic examination are described in Tran et al (2011). Both patients and controls were tested monocularly on the eye with the best corrected visual acuity for patients and the preferred eye for controls.

The stimuli were colored photographs of natural scenes taken from a large commercial CD database (Corel) displayed on a light gray background. Half of the scenes contained an

animal (the target) and the other half contained no animal. At a viewing distance of 1 meter, the angular size of the pictures was 20° horizontally and 15° vertically. The original photographs (called “scene” condition) were manipulated with the software Adobe Photoshop CS (version 8.01) to generate three new versions of each image: one in which the target animal or a distractor object was extracted from the scene and presented at the same spatial location on a white background (called “isolated» condition), one in which the target or the distractor object was surrounded by a white rectangle in the scene (called “structured background”), and one in which the target or the distractor object was surrounded by a white rectangle and placed in a modified disorganized version of the original background (called “non structured background”). Examples are shown in Figure 6.

A black (5°) central fixation cross was displayed for 500 ms, followed by a blank interval of 500 ms, and followed by a centrally presented stimulus. A Go/Nogo paradigm was used. Participant were asked to press a key when they saw an animal and to refrain from responding when a non animal object was present. Responses were given on a box containing two keys connected to the computer. They were told that an animal would be present in 50% of the images. Participants were tested in two sessions separated by a pause of 10 minutes: one short exposure duration session in which each stimulus was displayed for 300 ms and one long exposure duration session in which the stimulus was displayed for 3000ms. Half of the participants in each group started with the short duration exposure and the other half started with the long duration exposure session. Each session was composed of 200 trials determined by 50 scenes (25 animals and 25 non animal objects).

The percentage of correct detections of the target is displayed in Figure 7. Performance was lower for patients with AMD than for controls at both exposure durations but, except for photographs of real world scenes at the short exposure time, target detection was highly above chance (> 70% correct) for patients. Patients with AMD detected more easily the target when it was separated from the background by a white rectangle or when it was isolated than when it was located in a scene. The background condition did not significantly affect performance in normally sighted controls whose performance was at ceiling. The number of errors (false alarms) was higher in the non structured background than in the structured background for people with AMD, but remained very low on average (maximum: 6.1%). Performance improved with the increase in exposure time for patients with AMD but remained lower than that of normally sighted controls. Correlations were found between visual acuity, lesion size, and sensitivity in all conditions and at both short and long exposure times. A more detailed description of the results can be found in Tran et al (2011).

In contrast to normally sighted people, patients with AMD benefited significantly from the separation of the target from its background as compared to objects in scenes. This was more pronounced when the exposure time did not allow exploration (300 ms) but the same tendency was present when exploration was possible (3000ms). This result replicates previous data (Boucart et al, 2008b) and extend them in showing that the target object does not have to be completely isolated on a white background. A white space surrounding the object is sufficient to improve its detection and to facilitate figure/ground discrimination. The detrimental effect of scene background (without white space surrounding the object) likely reflects impaired figure/ground segregation in patients with AMD. A higher sensitivity to crowding does not necessarily affect figure/ground segregation. Levi (2007) reported that people with amblyopia, who showed strong crowding, performed nearly normally in a figure/ground segregation task in which they had to discriminate the




Fig. 6. Example of the four background used in a categorization task in which participants were asked to detect and animal and ignore pictures without animals.

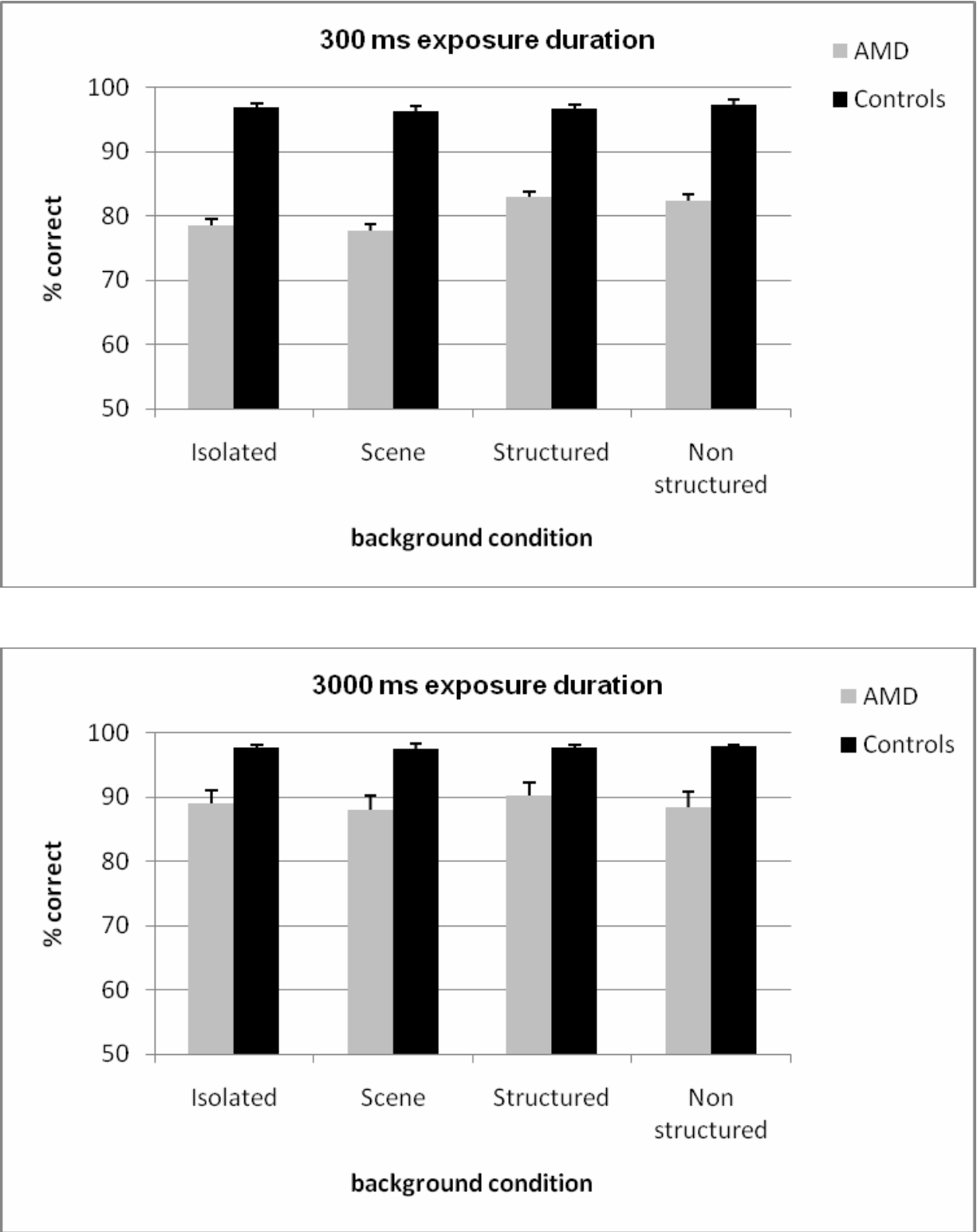


Fig. 7. Accuracy (hits and correct rejections) for the detection of a target animal in various background conditions as a function of exposure time for patients with AMD and age matched controls (adapted from Tran et al 2011).

orientation of a figure (an E made of horizontal gabor patches embedded in a variable number of distracters which were vertical gabor patches).

The visual system arranges the elements of a visual scene into coherent objects and background. Objects are formed by grouping elements and by segregating them from surrounding elements. For something to be identified and represented as a figure its contours need to be identified. Therefore figure/ground segregation is associated with efficient perception of contours which do not have to be physically present. Indeed, brain imaging studies show that the lateral occipital cortex (LOC) responds to real contours and to illusory contours with a similar level of activation (Mendola et al 1999, Stanley & Rubin 2003). The neural mechanisms underlying figure/ground segregation are still unclear. The traditional view is that low level areas (e.g., the primary visual cortex) extract simple features and that the binding of these features into objects occurs at higher level areas (i.e., in the LOC). In monkeys response modulations related to figure/ground segregation are observed in the primary visual cortex but in the late part of the stimulus response (contextual modulation starts approximately 80 ms after stimulus onset whilst in the primary visual cortex the classical response starts about 30 ms after stimulus onset; Supér & Lamme 2007). For other authors figure/ground segregation involves higher level processes in which an object has to be identified (i.e., access its representation in memory) to be identified as figure. Peterson et al (1991; Peterson & Gibson 1994) showed that changing the orientation of the figure (from upright to upside down) changes the quickness with which figure/ground segregation can be accomplished suggesting contributions to figure assignment from memories of object structure. Other behavioral and neuroimaging studies need to be conducted to understand the level of processing impaired in figure/ground segregation in people with AMD (contour perception, binding processes, impaired structural representations).

4. Conclusion and future research

As reading and face perception are the most common clinical complaints of patients with AMD seeking visual rehabilitation few investigations have been conducted on how these people perceive objects and scenes. We have reported a series of studies showing that people with central visual field loss are able to categorize scenes and objects embedded in scenes with high accuracy. Though scene categorization on the basis of global properties (e.g., natural or urban) and detection of an animal in a scene do not reflect common daily activities, the results may be considered for adaptation of the environment of people with low vision, in order to improve their object recognition capacity. Indeed, our results indicate that contrast enhancement (Tran et al submitted), colour (Boucart et al 2008b) and the introduction of a white space between the picture of an object and its surrounding (Tran et al 2011) improve performance in patients with macular degeneration, even at a duration allowing a single fixation. The studies presented in this chapter are only the beginning of investigations on the perception of natural environments in people with low vision in general, and in people with macular degeneration in particular. A lot of questions remain to be investigated like, for instance, what are the mechanisms underlying impaired recognition of an object in a scene by people with AMD: figure/ground segregation, the association of an object to its proper context, object identification? What level of representation is impaired in the ventral stream? Would the deficit be stronger in a task requiring recognition rather than detection or categorization? Are spatial representations impaired in people with central

vision loss? Answers to these questions will require both behavioral and brain imaging studies. Studies of functional cortical remapping in people with maculopathy have produced inconsistent results with some works (Nguyen et al 2004; Sunnes et al 2004) reporting a lack of reorganization and others (Baker et al. 2005; Schumacher et al 2008) reporting a functional reorganization. Alterations of visual stimulation may also result in modifications of the cortical structure (Johansson, 2004; Merzenich et al., 1984). Indeed, there is evidence that developmental visual disorders such as amblyopia (Mendola et al., 2005) and albinism (von dem Hagen et al., 2005) affect the structure of the human occipital cortex. A reduced size of the lateral geniculate nuclei has been reported in patients with glaucoma (Gupta et al. 2009) and reduction in grey matter density was found in the retinal lesion projection zones of the visual cortex in patient with age-related macular degeneration (Boucard et al. 2009).

As the proportion of individuals over the age of 65 increases, institutions serving the housing needs of people with degenerative diseases are becoming more numerous. Research on how people with central vision loss perceive objects and scenes can serve as the basis for developing new strategies for adapting the physical environment in which individuals with impaired spatial vision live and interact.

5. Acknowledgements

Parts of the chapter refers to articles published in Investigative Ophthalmology and Vision Science. The authors are grateful to ARVO for permission to use the reprinted material.

6. References

- Age-Related Eye Disease Study Research Group. (2001a) A randomized, placebo-controlled, clinical trial of high-dose supplementation with vitamins C and E, beta carotene, and zinc for age-related macular degeneration and vision loss: AREDS report no. 8. *Arch Ophthalmol*, 119, 1417-1436.
- Alexander, M.F., Maguire, M.G., Lietman, T.M., Snyder, J.R., Elman, M.J. & Fine, S.L. (1988) Assessment of visual function in patients with age-related macular degeneration and low visual acuity. *Arch Ophthalmol*, 106, 1543-1547.
- Baker CI, Peli E, Knouk N & Kanwisher N (2005) Reorganization of visual processing in macular degeneration. *The Journal of Neuroscience*, 25(3), 614-618.
- Biederman I. (1972) Perceiving real-word scenes. *Science*;177 :77-80.
- Biederman I, Ju G. (1988) Surface versus edge-based determinants of visual recognition. *Cogn Psychol*; 20:38-64.
- Bird, A.C., Bressler, N.M., Bressler, S.B., Chisholm, I.H., Coscas, G., Davis, M.D., de Jong, P.T., Klaver, C.C., Klein, B.E., Klein, R. & et al. (1995) An international classification and grading system for age-related maculopathy and age-related macular degeneration. The International ARM Epidemiological Study Group. *Surv Ophthalmol*, 39, 367-374.
- Boucard CC, Hernowo AT, Maguire RP, Jansonius NM, Roerdink JB, Hooymans JM, Cornelissen FW. (2009) Changes in cortical grey matter density associated with long-standing retinal visual field defects. *Brain*. 132(Pt 7):1898-906.


- Boucart M, Dinon JF, Despretz P, Desmettre T, Hladiuk K, & Oliva A. (2008a) Recognition of facial emotion in age related macular degeneration (AMD): a flexible usage of facial features. *Visual Neuroscience*, 25(4):603-9.
- Boucart M, Despretz P, Hladiuk K, & Desmettre T (2008b) Does context or color improve object recognition in patients with macular degeneration? *Visual Neuroscience*, 25, 685-91.
- Bouma H. (1970) Interaction effects in parafoveal letter recognition. *Nature* ;226(5241):177-8.
- Boyce SJ, Pollatsek A, Rayner K. (1989) Effect of background information on object identification. *J Exp Psychol Hum Percept Perform*. 15(3):556-66.
- Boyce SJ, Pollatsek A.(1992) Identification of objects in scenes: the role of scene background in object naming. *J Exp Psychol Learn Mem Cogn*. 18(3):531-43.
- Bullimore, MA, Bailey, IL, & Wacker, RT (1991) Face recognition in age-related maculopathy. *Invest Ophthalmol Vis Sci*, 32, 2020-29.
- Brody, B. L., A. C. Gamst, et al. (2001) Depression, visual acuity, comorbidity, and disability associated with age-related macular degeneration. *Ophthalmology* 108(10): 1893-900; discussion 1900-1.
- Cahill MT, Banks AD, Stinnett SS, Toth CA (2005): Vision-related quality of life in patients with bilateral severe age-related macular degeneration. *Ophthalmology*;112:152-158.
- Calabrèse A, Bernard JB, Hoffart L, Faure G, Barouch F, Conrath J, Castet E (2010) Small effect of interline spacing on maximal reading speed in low-vision patients with central field loss irrespective of scotoma size. *Invest Ophthalmol Vis Sci*. 51(2):1247-54
- Chung, S.T., Mansfield, J.S., & Legge, G.E. (1998). Psychophysics of reading. XVIII. The effect of print size on reading speed in normal peripheral vision. *Vision Res*, 38 (19), 2949-2962.
- Crossland, M.D., Sims, M., Galbraith, R.F., & Rubin, G.S. (2004). Evaluation of a new quantitative technique to assess the number and extent of preferred retinal loci in macular disease. *Vision Res*, 44 (13), 1537-1546.
- Crossland, M.D., Culham, L.E., Kabanarou, S.A., & Rubin, G.S. (2005). Preferred retinal locus development in patients with macular disease. *Ophthalmology*, 112 (9), 1579-1585.
- Cheung, S.H. & Legge, G.E. (2005). Functional and cortical adaptations to central vision loss. *Visual Neuroscience* 22, 187-201.
- Chung ST, Jarvis SH, Woo SY, Hanson K, Jose RT. (2008) Reading speed does not benefit from increased line spacing in AMD patients. *Optom Vis Sci*. 85(9):827-33
- Curcio CA, Kimberley AA, Sloan KR, Lerea CL, Hurley JB, Klkock IB, (1991) et al. Distribution and morphology of human cone photoreceptors stained with anti-blue opsin. *J Comp Neurol* 312:610-624.
- Curcio CA, Medeiros NE & Millican CL (1996) Photoreceptor loss in age related macular degeneration. *Invest Ophthalmol Vis Sci*. , 37, 1236-49.
- Curcio CA, Owsley C & Jackson GR (2000) Spare the rods, save the cones in aging and age related maculopathy. *Invest Ophthalmol Vis Sci*. , 41(8), 2015-18.
- Delorme A, Richard G & Fabre-Thorpe M (2000) Ultra-rapid categorization of natural scenes does not rely on color cues: a study in monkeys and humans. *Vis Res*, 40, 2187-2200.
- Ebert EM, Fine AM, Markowitz J, et al. (1986) Functional vision in patients with neovascular maculopathy and poor visual acuity. *Arch Ophthalmol*.;104(7):1009-12.

- Ergun E, Maar N, Radner W, et al. Scotoma size and reading speed in patients with subfoveal occult choroidal neovascularization in age-related macular degeneration. *Ophthalmology*. 2003;110(1):65-9.
- Faubert, J., & Overbury, O. (2000) Binocular vision in older people with adventitious visual impairment: Sometimes one eye is better than two. *JAGS*, Vol 48, N°. 4, 375-380.
- Fei-Fei, L., Iyer, A., Koch, C., & Perona, P. (2007). What do we perceive in a glance of a real-world scene? *Journal of Vision*, 7(1), 1-29.
- Felisbert FM, Solomon JA, Morgan MJ. (2005) The role of target salience in crowding. *Perception*.;34(7):823-33.
- Ferris, F.L., 3rd, Fine, S.L. & Hyman, L. (1984) Age-related macular degeneration and blindness due to neovascular maculopathy. *Arch Ophthalmol*, 102, 1640-1642.
- Fine I, MacLeod DI, & Boynton GM (2003) Surface segmentation based on the luminance and color statistics of natural scenes. *J of the Optical Soc of America*, 20, 1283-91.
- Gegenfurtner KR, Rieger J. (2000) Sensory and cognitive contributions of color to the recognition of natural scenes. *Curr Biol*; 10:805-808.
- Greene, M. R. and A. Oliva (2009a). Recognition of natural scenes from global properties: seeing the forest without representing the trees. *Cogn Psychol* 58(2): 137-76.
- Greene MR, Oliva A. Recognition of natural scenes from global properties: seeing the forest without representing the trees. *Cogn Psychol*. 2009b;58(2):137-76.
- Gupta N, Greenberg G, de Tilly LN, Gray B, Polemidiotis M, Yücel YH. (2009) Atrophy of the lateral geniculate nucleus in human glaucoma detected by magnetic resonance imaging. *Br J Ophthalmol*.;93:56-60.
- Hansen T & Gegenfurtner KR (2006) Higher level chromatic mechanisms for image segmentation. *Journal of Vision*, 6(3) 239-59.
- Hart, P.M., Chakravarthy, U., Stevenson, M.R. & Jamison, J.Q. (1999). A vision specific functional index for use in patients with age related macular degeneration. *British Journal of Ophthalmology* 83, 1115-1120.
- Hassan, S.E., Lovie-Kitchin, J.E. & Woods, R.L. (2002). Vision and mobility performance of subjects with age-related macular degeneration. *Optometry and Vision Science* 79, 697-707.
- Hogervorst MA & van Damme WJM (2008) Visualizing the Limits of Low Vision in Detecting Natural Image Features. *Optometry and Vision Science*, 85(10), E951-E962
- Holzschuch, C., Mourey, F. & Manie`re, D. (2002). *Geriatric et basse vision: Pratiques interdisciplinaires*. Paris, Edition Masson.
- Jackson GR, Owsley C, Curcio CA (2002) Photoreceptor degeneration and dysfunction in aging and age-related maculopathy. *Ageing Res Rev*. 1(3):381-96.
- Johansson BB. (2004) Brain plasticity in health and disease. *Keio J Med*.;53:231-46.
- Joubert OR, Fize D, Rousselet GA, Fabre-Thorpe M. (2007) Early interference of context congruence on object processing in rapid visual categorization of natural scenes. *J Vis*.;8(13):11 1-8.
- Klaver, C.C., Wolfs, R.C., Vingerling, J.R., Hofman, A. & de Jong, P.T. (1998) Age-specific prevalence and causes of blindness and visual impairment in an older population: the Rotterdam Study. *Arch Ophthalmol*, 116, 653-658.
- Klein, R., Klein, B.E. & Linton, K.L. (1992) Prevalence of age-related maculopathy. The Beaver Dam Eye Study. *Ophthalmology*, 99, 933-943.
- Klein, R., Klein, B.E., Jensen, S.C. & Meuer, S.M. (1997) The five-year incidence and progression of age-related maculopathy: the Beaver Dam Eye Study. *Ophthalmology*, 104, 7-21.

- Klein, R. (2007) Overview of progress in the epidemiology of age-related macular degeneration. *Ophthalmic Epidemiol*, 14, 184-187.
- Kleiner, R. C., Enger, C., Alexander, M. E., & Fine, S. L. Contrast sensitivity in age-related macular degeneration. *Arch Ophthalmol*, 1988, Vol 106, N°. 1, 55-57.
- Larson AM, Loschky LC. The contributions of central versus peripheral vision to scene gist recognition. *J Vis.* 2009;9(10):6 1-16.
- Leat SJ, Li W, Epp K. (1999) Crowding in central and eccentric vision: the effects of contour interaction and attention. *Invest Ophthalmol Vis Sci.*;40(2):504-12.
- Legge, G.E., Rubin, G.S., Pelli, D.G., & Schleske, M.M. (1985). Psychophysics of reading--II. Low vision. *Vision Res*, 25 (2), 253-265.
- Legge, GE, Ross, JA, Isenberg, LM, & LaMay, JM (1992) Psychophysics of reading.XII. Clinical predictors of low vision reading speed. *Invest Ophtalmol Vis Sci.*, 33, 677-87.
- Levi DM. (2007) Image segregation in strabismic amblyopia. *Vision Res.* 2007;47(13):1833-8.
- Levi DM. (2008) Crowding--an essential bottleneck for object recognition: a mini-review. *Vision Res.* ;48(5):635-54.
- Liebe S, Fischer E, Logothetis NK & Rainer G (2009) Color and shape interactions in the recognition of natural scenes by human and monkey observers *Journal of Vision*, 9(5) :14, 1-16
- Lindblad, A.S., Lloyd, P.C., Clemons, T.E., Gensler, G.R., Ferris, F.L., 3rd, Klein, M.L. & Armstrong, J.R. (2009) Change in area of geographic atrophy in the Age-Related Eye Disease Study: AREDS report number 26. *Arch Ophthalmol*, 127, 1168-1174.
- Livne T, Sagi D. Configuration influence on crowding. *J Vis.* 2007;7(2):4 1-12.
- Makela, P., Nasanen, R., Rovamo, J., & Melmoth, D. (2001) identification of facial images in peripheral vision. *Vision Research*, 41, 599-610.
- Mangione, CM Gutierrez PR., Lowe, G, Orav EJ & Seddon JM. (1999) Influence of age-related Maculopathy on visual functioning and health-related quality of life. *Am J Ophthalmol* 128: 45-53.
- Mangione CM, Lee PP, Gutierrez PR, Spritzer K, Berry S, Hays RD (2001) Development of the 25-item National Eye Institute Visual Function Questionnaire. *Arch Ophthalmol*;119:1050-1058.
- Mendola JD, Dale AM, Fischl B, et al. (1999) The representation of illusory and real contours in human cortical visual areas revealed by functional magnetic resonance imaging. *J Neurosci.*;19(19):8560-72.
- Merzenich MM, Nelson RJ, Stryker MP, Cynader MS, Schoppmann A, Zook JM. Somatosensory cortical map changes following digit amputation in adult monkeys. *J Comp Neurol.* 1984;224:591-605.
- Midena, E., Degli Angeli, C., Blarzino, M. C., Valenti, M., & Segato, T (1997) Macular function impairment in eyes with early age-related macular degeneration. *Invest Ophtalmol Vis Sci*, Vol 38, N°. 2, 469-477.
- Näsänen R, O'Leary C. (1998) Recognition of band-pass filtered hand-written numerals in foveal and peripheral vision. *Vision Res.* 38(23):3691-701.
- Naïli F., Despretz P & Boucart M. (2006) Color recognition at large visual eccentricities in normal observers and patients with low vision *Neuroreport*, 17, 1571-74.
- Newton JR, Eskew RT Jr. (2003) Chromatic detection and discrimination in the periphery: a postreceptoral loss of color sensitivity. *Vis Neurosci.* ;20(5):511-21.
- Nguyen TH, Stievenart JL, Saucet JC, Le Gargasson JF, Cohen YS, Pelegrini-Issac M, Burnod Y, Iba-Zizen MT, Cabanis EA. (2004) Cortical response in age-related macular

- degeneration (part I). Methodology and subject specificities. *J Fr Ophtalmol*. 27(9 Pt 2):3S65-71.
- Oliva, A. (2005). Gist of the scene. In the *Encyclopedia of Neurobiology of Attention*. L. Itti, G. Rees, and J.K. Tsotsos (Eds.), Elsevier, San Diego, CA (pages 251-256)
- Oliva A, Schyns P. (2000) Diagnostic colors mediate scene recognition. *Cognitive Psychology*;41:176-210.
- Oliva A, Torralba A. (2001) Modeling the shape of the scene: A holistic representation of the spatial envelope. *International of Computer Vision*;42:145-75
- Owsley, C & Sloane, ME (1987) Contrast sensitivity, acuity, and the perception of « real-world » targets. *British Journal of Ophthalmology*, 71, 791-96.
- Ostergaard AL, Davidoff JB. (1985) Some effects of color on naming and recognition of objects. *J Exp Psychol Learn Mem Cogn* ; 11:579-587.
- Owsley C, Jackson GR, Cidecyyan AV et al. (2000) Psychophysical evidence for rods vulnerability in age related macular degeneration. *INVEST OPHTHALMOL VIS SCI*. , 41, 267-73.
- Peli, E., Goldstein, R.B., Young, G.M., Trempe, C.L. & Buzney, S.M. (1991). Image enhancement for the visually impaired. *Invest Ophthalmol Vis sci*. 32, 337-2351.
- Pelli DG, Palomares M, Majaj NJ. (2004) Crowding is unlike ordinary masking: distinguishing feature integration from detection. *J Vis*;4(12):1136-69.
- Pelli DG (2008) Crowding: a cortical constraint on object recognition. *Current Opinion in Neurobiology*, 18, 445-451.
- Peterson MA, Harvey EM, Weidenbacher HJ. . (1991) Shape recognition contributions to figure-ground reversal: which route counts? *J Exp Psychol Hum Percept Perform*.17(4):1075-89.
- Peterson MA, Gibson BS. (1994) Object recognition contributions to figure-ground organization: operations on outlines and subjective contours. *Percept Psychophys*;56(5):551-64.
- Price CJ, Humphreys GW. (1989) The effects of surface detail on object categorization and naming. *Q J Exp Psychol A*; 41:797-827.
- Righart R, de Gelder B. (2006) Context influences early perceptual analysis of faces--an electrophysiological study. *Cereb Cortex* 16(9):1249-57.
- Rossion B, Pourtois G. (2004) Revisiting Snodgrass and Vanderwart's object pictorial set: the role of surface detail in basic-level object recognition. *Perception*; 33:217-236.
- Saarinen, J., Rovamo, J., & Virsu, V. (1987) Texture discrimination at different eccentricities. *Investigative Ophthalmology and Vision Science*, 30, 293-296.
- Sakurai M, Ayama M, Kumagai T. (2003) Color appearance in the entire visual field: color zone map based on the unique hue component. *J Opt Soc Am A Opt Image Sci Vis*; 20:1997-2009.
- Sarks, J.P., Sarks, S.H. & Killingsworth, M.C. (1988) Evolution of geographic atrophy of the retinal pigment epithelium. *Eye (Lond)*, 2 (Pt 5), 552-577.
- Schumacher EH, Jacko JA, Primo SA, Main KL, Moloney KP, Kinzel EN, Ginn J. (2008) Reorganization of visual processing is related to eccentric viewing in patients with macular degeneration. *Restor Neurol Neurosci*;26(4-5):391-402.
- Spence I, Wong P, Rusan M, & Rastegar N (2006) How color enhances visual memory for natural scenes. *Psychological Science*, 17, 1-6.
- Strasburger, H., Harvey, L.O., & Rentschler, I. (1991) Contrast threshold for identification of numeric characters in direct and eccentric view. *Perception & Psychophysics*, 49, 495-508.

- Stanley DA, Rubin N. (2003) fMRI activation in response to illusory contours and salient regions in the human lateral occipital complex. *Neuron*;37(2):323-31.
- Sjostrand, J., & Frisue, L. (1977) Contrast sensitivity in macular report. A preliminary report. *Acta Ophthalmol (copenh)*, , Vol 55, N°. 3, 507-514.
- Sunnes JS, Liu T & Yantis S (2004). Retinotopic mapping of the visual cortex using functional magnetic resonance imaging in a patient with central scotomas from atrophic macular degeneration. *Ophthalmology*, 111, 1595-98.
- Supèr H, Lamme VA. (2007) Altered figure-ground perception in monkeys with an extra-striate lesion. *Neuropsychologia*. 45(14):3329-34.
- Tanaka JW, Presnell LM. (1999) Color diagnosticity in object recognition. *Percept Psychophysiol*; 61:1140-1153.
- Tejeria, L., Harper, R.A., Artes, P.H. & Dickinson, C.M. (2002). Face recognition in age related macular degeneration: Perceived disability, measured disability, and performance with a bioptic device. *British Journal of Ophthalmology* 86, 1019-1026.
- Therriault DJ, Yaxley RH & Zwaan RA (2009) The role of color diagnosticity in object recognition and representation. *Cogn Process*, 10(4) : 335-42.
- Thompson B, Hansen BC, Hess RF, Troje NF. (2007) Peripheral vision: good for biological motion, bad for signal noise segregation? *J Vis*.7(10):12.1-7.
- Torralba, A., & Oliva, A. (2002). Depth estimation from image structure. *IEEE Pattern Analysis and Machine Intelligence*, 24,1226-1238.
- Torralba A, Oliva A. Statistics of natural image categories. *Network: Computational in Neural Systems*. 2003;14(3):391-412.
- Tran THC, Guyader N , Guerin A, Despretz P, & Boucart M (2011) Figure/ground discrimination in age related macular degeneration. *Invest Ophthalmol Vis Sci*. 2010 Nov 18.
- Tran THC, Rambaud C, Despretz P, & Boucart M (2011) Scene perception in age-related macular degeneration. *Invest Ophthalmol Vis Sci*. 2010 Dec;51(12):6868-74.
- Vogel, J., & Schiele, B. (2007). Semantic scene modeling and retrieval for content-based image retrieval. *International Journal of Computer Vision*, 72(2), 133-157.
- von dem Hagen EA, Houston GC, Hoffmann MB, Jeffery G, Morland AB. (2005) Retinal abnormalities in human albinism translate into a reduction of grey matter in the occipital cortex. *Eur J Neurosci*;22:2475-80.
- Wang YZ, Wilson E, Locke KG, & Edwards AO (2002) Shape discrimination in age-related macular degeneration. *Invest Ophthalmol Vis Sci*, 43(6), 2055-62.
- Wichmann FA, Sharpe LT, & Gegenfurtner KR (2002) the contribution of color to recognition memory for natural scenes. *Journal of Experimental Psychology: Learning, Memory & Cognition*, 28, 509-20.
- Wood JM, Lacherez PF, Black AA, Cole MH, Boon MY, Kerr GK. (2009) Postural stability and gait among older adults with age-related maculopathy. *Invest Ophthalmol Vis Sci*;50(1):482-7
- Wurm LH, Legge GE, Isenberg LI, Luebker A. (1993) Color improves object recognition in normal and low vision. *J Exp Psychol Hum Percept Perform*; 19:899-911.



Object Recognition

Edited by Dr. Tam Phuong Cao

ISBN 978-953-307-222-7

Hard cover, 350 pages

Publisher InTech

Published online 01, April, 2011

Published in print edition April, 2011

Vision-based object recognition tasks are very familiar in our everyday activities, such as driving our car in the correct lane. We do these tasks effortlessly in real-time. In the last decades, with the advancement of computer technology, researchers and application developers are trying to mimic the human's capability of visually recognising. Such capability will allow machine to free human from boring or dangerous jobs.

How to reference

In order to correctly reference this scholarly work, feel free to copy and paste the following:

Muriel Boucart and Thi Ha Chau Tran (2011). Object and Scene Recognition Impairments in Patients with Macular Degeneration, Object Recognition, Dr. Tam Phuong Cao (Ed.), ISBN: 978-953-307-222-7, InTech, Available from: <http://www.intechopen.com/books/object-recognition/object-and-scene-recognition-impairments-in-patients-with-macular-degeneration>

INTech
open science | open minds

InTech Europe

University Campus STeP Ri
Slavka Krautzeka 83/A
51000 Rijeka, Croatia
Phone: +385 (51) 770 447
Fax: +385 (51) 686 166
www.intechopen.com

InTech China

Unit 405, Office Block, Hotel Equatorial Shanghai
No.65, Yan An Road (West), Shanghai, 200040, China
中国上海市延安西路65号上海国际贵都大饭店办公楼405单元
Phone: +86-21-62489820
Fax: +86-21-62489821

© 2011 The Author(s). Licensee IntechOpen. This chapter is distributed under the terms of the [Creative Commons Attribution-NonCommercial-ShareAlike-3.0 License](https://creativecommons.org/licenses/by-nc-sa/3.0/), which permits use, distribution and reproduction for non-commercial purposes, provided the original is properly cited and derivative works building on this content are distributed under the same license.

IntechOpen

IntechOpen